

Surgery for Locked Cervical Facets: A Technical Note

Sumit Sinha¹ Shashank S. Kale¹

¹Department of Neurosurgery, All India Institute of Medical Sciences, Ansari Nagar, New Delhi, India

Indian J Neurosurg 2016;5:124–128.

Address for correspondence Dr. Sumit Sinha, MS, DNB, MCh, Department of Neurosurgery, All India Institute of Medical Sciences, Ansari Nagar, New Delhi 110029, India (e-mail: sumitneuro@gmail.com).

Abstract

Cervical facet dislocations represent a severe form of cervical spine injury and can be present unilaterally or bilaterally. They are invariably associated with neurological compromise, with complete spinal cord injury seen in 65 to 87% and the incomplete injury seen in 13 to 25% of the cases. The facet dislocations represent hyperflexion–distraction injuries and are classified as type B in the AO classification system. These are unstable injuries and necessitate some form of surgical stabilization. A variety of surgical procedures can be performed to effect the reduction of the locked facets which can be performed anteriorly, posteriorly, and by combined approaches. The article focuses on the indications, contraindications, and on the surgical management and the techniques used in the reduction of unilateral or bilateral locked facets.

Keywords

- ▶ fracture
- ▶ facet
- ▶ treatment
- ▶ injury

Introduction

Cervical facet fractures and dislocations represent approximately 6% of all cervical spine fractures.¹ The clinical spectrum of these injuries ranges from patient being neurologically intact to complete neurological deficits. They can be unilateral or bilateral and may be associated with subluxation or dislocations. The unilateral facet dislocations are produced because of flexion, hyperextension, lateral tilt, and rotation; while bilateral dislocations are due to flexion, axial loading, and anterior shear stress forces. The facets are subluxed when there is some contact between the two articular surfaces of the facet joint; while in dislocation, there is no residual contact (→Fig. 1A–D).

The most common site of facet injuries is C5–C6 (25–60%), followed by C6–C7 (25–30%).^{2,3} This is because of the inherent anatomy of superior facets of the lower cervical spine, which are smaller with less height and more horizontal, as compared with the cranial facets. The majority (73%) of the bilateral facet dislocations are associated with facet fractures.⁴

The presence of midline cervical pain and tenderness with restriction of motion demands a thorough investigation. A large number of facet injuries (33%) can be missed at initial presentation.⁵ The majority (90%) of facet dislocations are associated with some degree of neurological compromise. The incidence of complete cord injury has been reported to be present in 16% in unilateral and 84% in bilateral dislocations.^{1,6}

Allen et al have proposed a four-staged classification of lower cervical spine fractures, which includes facet subluxation, 25% translation of the cranial vertebral body with respect to the caudal body with unilateral locked facets, 50% translation with bilateral locked facets and complete dislocation.⁷

Treatment of Cervical Locked Facets

1. Nonoperative: Closed reduction
2. Operative: Anterior or posterior approach

Nonoperative Treatment: Closed Reduction

The contraindications for the closed reduction are:

1. Fracture fragments in foramen
2. Herniated disc
3. Inability to monitor patients neurological and radiographic status

Technique of Closed Reduction

Closed reduction (→Fig. 2) is achieved by applying traction using cranial tongs, starting with a weight of 10 lb initially. An average weight of 9.4 to 9.8 lb is required per segment above the injury level, for the reduction of unilateral or bilateral dislocations.¹ The weight can be increased to 140 lb.⁸ Serial neurological and radiological evaluations are mandatory during this procedure. The traction is stopped

received
June 14, 2016
accepted
June 21, 2016
published online
August 23, 2016

DOI <http://dx.doi.org/10.1055/s-0036-1586740>.
ISSN 2277-954X.

© 2016 Neurological Surgeons' Society of India

License terms



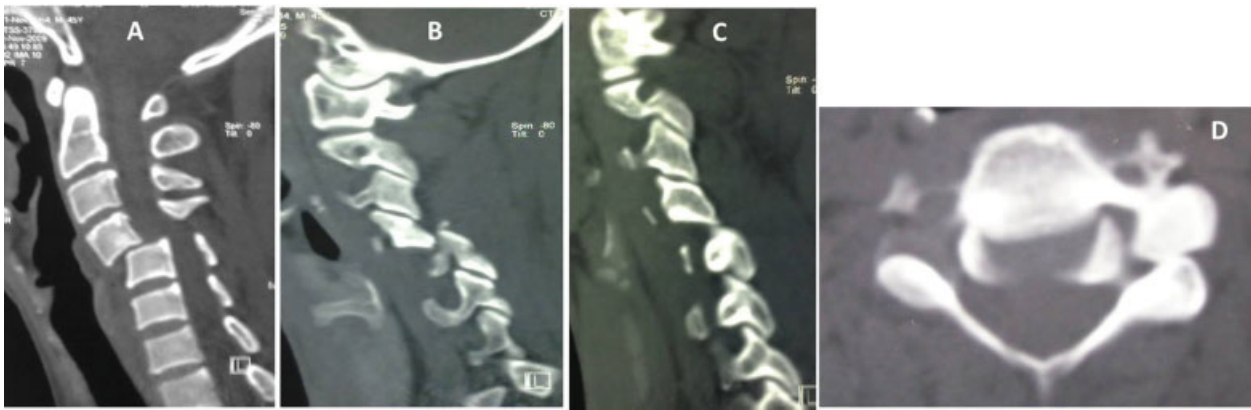


Fig. 1 (A–C) C4, 5 type C2 AO spine fracture with right-locked facet and left-perched facet. (D) Classical bow-tie sign indicative of facet dislocation with one lateral mass lying in front of the other.

at any point of time whenever there is evidence of distraction of > 10 mm between the affected spine segments. Bilateral facet dislocations reduce more commonly than unilateral dislocations. The traction should be applied in flexion and direction of the rotation should be opposite to the dislocated facet. The reduction is suggested by an audible click. Once the reduction has been achieved, the neck is held in extension to hold the reduction. The application of traction alone is successful in reducing unilateral dislocations in 25% of the cases.⁹

Controversy of Magnetic Resonance Imaging before Closed Reduction

In cases of complete cord injury, the consensus is to achieve a reduction in the emergency room followed by a magnetic resonance imaging (MRI). However, in cases of no neurological injury, it is always advisable to perform a MRI before reduction or a surgical exploration to take care of the associated herniated disc, which might otherwise cause cord compression with closed reduction. The status of MRI in cases of incomplete injuries is controversial.

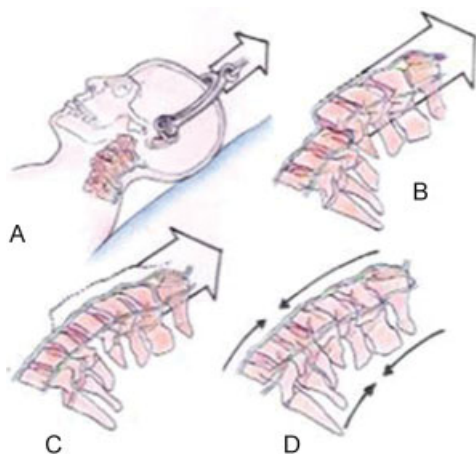


Fig. 2 Technique for closed reduction of cervical locked facets.

Operative Treatment

Surgical treatment achieves neural decompression and fixation achieves early stabilization, reduction, and maintenance of normal anatomy. Various series in literature recommend surgery as the best option for unilateral and bilateral facet dislocations.^{10–12}

Surgical Indications⁶

1. Absolute
 - Presence of herniated disc
 - Unsuccessful closed reduction
 - Delayed presentation of dislocation
 - Fractures with cord/root compression
2. Relative
 - Fractures displacing with closed reduction
 - Facet fracture with root compression
 - Delayed presentation of fracture

Surgical Approaches

Anterior, posterior, and combined anterior–posterior approaches have been advocated for the treatment of facet dislocations. The factors influencing the choice of the surgical approach are the patient's neurological status, the presence of herniated disc, the success of closed reduction, unilateral or bilateral facet dislocation, and the presence of facet and other fractures (► **Figs. 3** and **4**).

The anterior approach is favored in the presence of a herniated disc and in unilateral or bilateral dislocations without extensive vertebral or posterior element fractures. The anterior approach is less likely to be successful in the presence of a severely comminuted facet fracture. The posterior approach may be used when there is an extensive vertebral comminution or when the anterior approach is not necessary or failed.

Techniques for Reduction of Locked Facets

The key principle in achieving the reduction of the locked facets is recreating the injury mechanism, followed by manipulation of the affected segments into normal position.

A good general anesthesia ensuring adequate muscle relaxation should be accomplished. Fiberoptic intubation

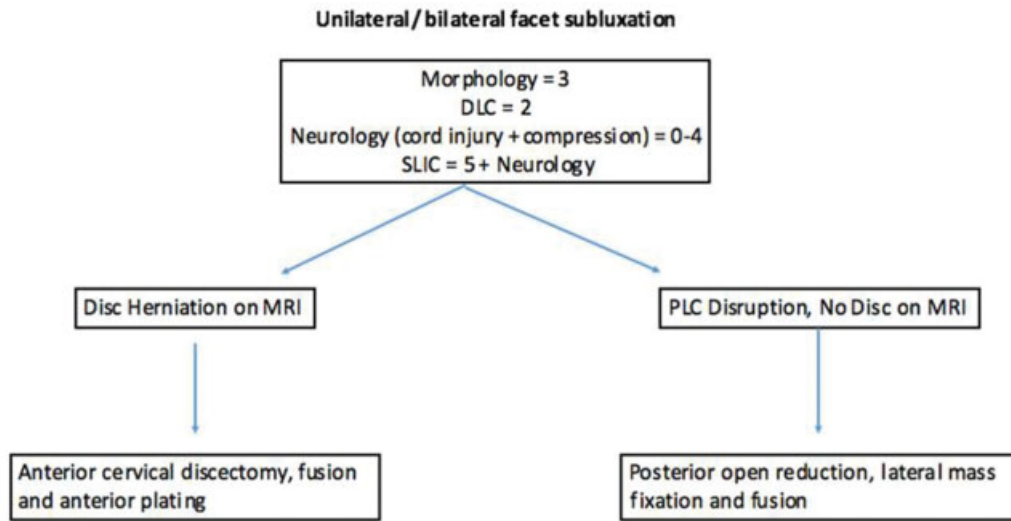


Fig. 3 Subaxial injury classification algorithm (SLIC) for unilateral or bilateral facet subluxation/perched facets.

when awake is desirable as it allows neurological examination during and after intubation. Excessive extension of the cervical spine should be avoided. Neurophysiological monitoring with somatosensory-evoked potential and motor-evoked potentials are mandatory during the reduction procedure, and the procedure should be abandoned immediately, if significant neurophysiological changes are noticed during the reduction maneuver. The patient is placed in traction with Gardner-Wells tongs, which will be useful during the reduction.

Anterior Approach

A standard anterior cervical discectomy approach is performed and a complete discectomy is achieved first.

Thereafter, the posterior longitudinal ligament is completely excised to facilitate the reduction of facets. There are several techniques to effect facet reduction by the anterior approach:

1. Caspar distraction pins (► **Fig. 5B**): One pin each is inserted into the vertebral bodies of the affected segment, at divergent angles. The pins are then made parallel to each other to disengage the locked facets. Next, the pins are engaged in a distracter device and controlled gentle distraction is applied to further distract the facets. The cranial vertebra is then pushed dorsally to restore normal anatomy. In case of osteopenia and poor bone stock, longer pins with a bicortical purchase may be required.

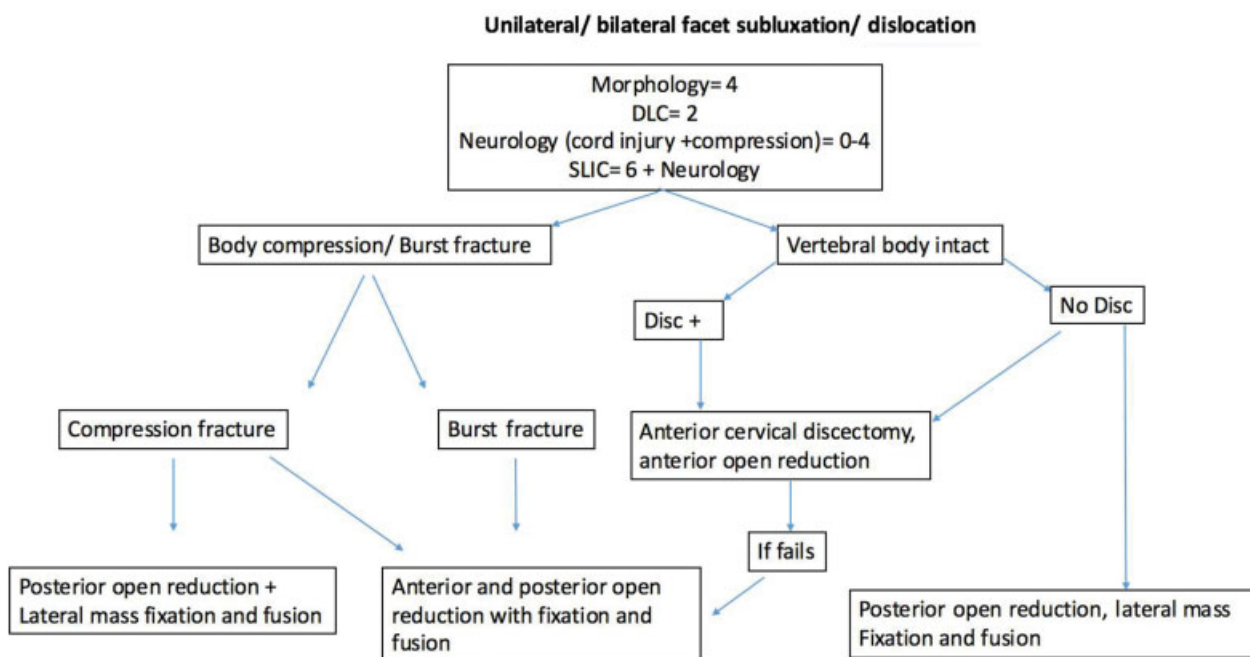


Fig. 4 Subaxial injury classification algorithm (SLIC) for bilateral facet fracture dislocation/subluxation.

In a unilateral locked facet, the required rotational force vector may be provided by applying the distractor pins in divergent angles in the coronal plane (►Fig. 5C).

2. Vertebral spreader (►Fig. 5D): After the discectomy at the affected level, the vertebral spreader is inserted into the disc space up to approximately half the depth of the vertebral bodies. The spreader is then opened to distract the disc space and then angled rostrally to effect the disengagement and the reduction of the affected facets.
3. The distraction can be achieved by using a vertebral spreader. A curette can then be used to disengage the facets by placing the end of the curette against the dorsal aspect of the caudal vertebral endplate. The curette is then levered ventrally by using the cranial body as the fulcrum. At the same time, the assistant gently forces the cranial vertebra dorsally. The facet reduction can actually be felt by the surgeon.
4. In extreme spondyloptosis of one body over the other, resection of the ventrocaudal aspect of the cranial vertebral body might be required to visualize the disc space.

Posterior Approach

A midline skin incision is given from approximately two levels above the affected segment to two levels down. A standard subperiosteal dissection of the posterior cervical spine is performed exposing the concerned lateral masses and facet joints. The affected level can be appreciated by feeling a step off between the two spinous processes or using an image intensifier. Once the affected level is identified, the involved caudal and cranial spinous processes are held with an artery forceps. The cranial spinous process is now gently pulled cranially and the caudal one pulled caudally, thereby recreating the injury mechanism (►Fig. 6). The unilateral dislocations require a rotational pull along the direction of the locked facets. The procedure is continued till the reduction is complete, that is, an inferior articular facet of the cranial vertebra is freed from

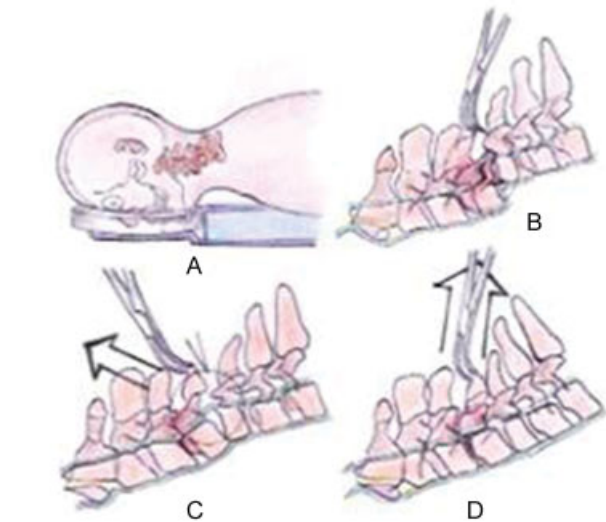


Fig. 6 Surgical technique for posterior approach for the reduction of locked facets.

the superior facet of the caudal vertebra. The affected segment can then be fixed by mean of lateral mass screws and rods or wiring to maintain reduction and stabilization.

The reduction procedure utilizing the spinous processes is not possible in the case of a spinous process or lamina fractures. In these cases, the reduction can be affected by means of lateral mass screws in a similar fashion. However, extreme care has to be taken during this procedure to avoid fracturing the lateral masses and damaging them for future use in fixation.

Combined Anterior and Posterior Approach

A circumferential fusion is advisable when there are concerns about the fracture segment stability due to severe comminution of the fracture fragments or when the fixation by one approach

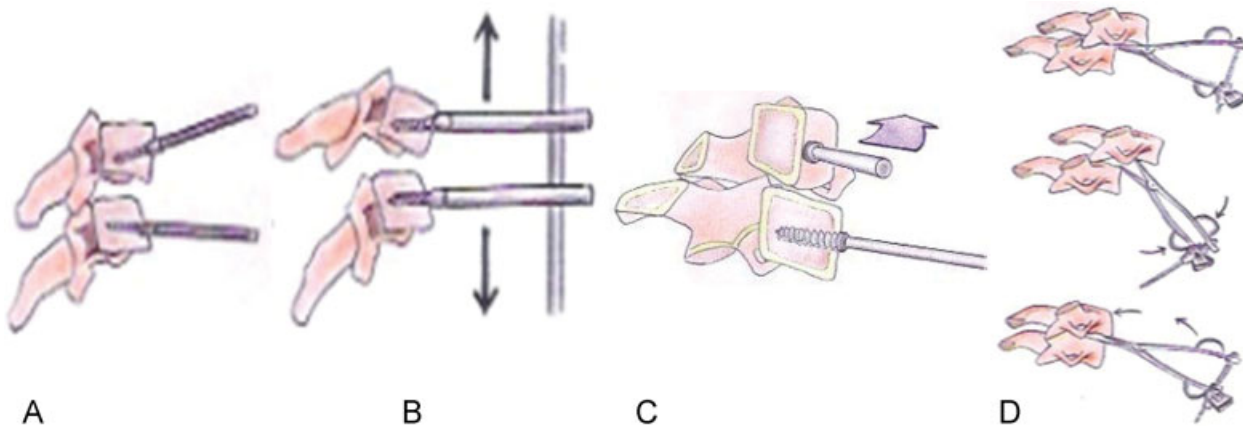


Fig. 5 Surgical technique for open reduction of cervical locked facets. (A, B) Reduction of cervical locked facets using Caspar retraction pins applied at 10 to 20-degree angle in the sagittal plane. Subsequent distraction then causes the facets to disengage. Force applied to the rostral vertebra dorsally aids in the reduction. (C) Reduction of the locked facets using a vertebral spreader placed in the interbody space at an angle. Distraction is then applied to disengage the facets followed by rotation (in unilateral locked facets) or ventral (in bilateral locked facets) angulation to reduce the deformity.

appears to be suboptimal. Mostly, the combined approach is performed when the anterior approach fails in reducing the dislocation, after the discectomy. This necessitates the posterior approach for the reduction and stabilization, with a second anterior approach for the space left after the discectomy. However, fitting an undersized graft and placing a buttress plate anteriorly can curtail the second anterior approach.

In summary, either of the above-mentioned approaches can be used for a majority of patients with some possible exceptions. The surgical approach is dictated by the pathology present such as the disc herniation, neurological compromise, and the extent of the bony injury. The anterior approach is appropriate in dislocations not involving vertebral or posterior element fractures or when there is a need for spinal canal decompression before bone manipulation. The posterior approach achieves a better correction of the deformity and is used when there is an extensive vertebral comminution or when anterior approaches are unnecessary or have failed to reduce the deformity. The combined approaches provide the greatest stability at the cost of being more invasive and extensive.

References

- 1 Hadley MN, Fitzpatrick BC, Sonntag VK, Browner CM. Facet fracture-dislocation injuries of the cervical spine. *Neurosurgery* 1992;30(5):661–666
- 2 Shapiro SA. Management of unilateral locked facet of the cervical spine. *Neurosurgery* 1993;33(5):832–837, discussion 837
- 3 Dvorak MF, Fisher CG, Aarabi B, et al. Clinical outcomes of 90 isolated unilateral facet fractures, subluxations, and dislocations treated surgically and nonoperatively. *Spine* 2007;32(26):3007–3013
- 4 Burke DC, Berryman D. The place of closed manipulation in the management of flexion-rotation dislocations of the cervical spine. *J Bone Joint Surg Br* 1971;53(2):165–182
- 5 Lifeso RM, Colucci MA. Anterior fusion for rotationally unstable cervical spine fractures. *Spine* 2000;25(16):2028–2034
- 6 Andreshak JL, Dekutoski MB. Management of unilateral facet dislocations: a review of the literature. *Orthopedics* 1997;20(10):917–926
- 7 Allen BL Jr, Ferguson RL, Lehmann TR, O'Brien RP. A mechanistic classification of closed, indirect fractures and dislocations of the lower cervical spine. *Spine* 1982;7(1):1–27
- 8 Braakman R, Vinken PJ. Unilateral facet interlocking in the lower cervical spine. *J Bone Joint Surg Br* 1967;49(2):249–257
- 9 Rorabeck CH, Rock MG, Hawkins RJ, Bourne RB. Unilateral facet dislocation of the cervical spine. An analysis of the results of treatment in 26 patients. *Spine* 1987;12(1):23–27
- 10 Vaccaro AR, Hulbert RJ, Patel AA, et al; Spine Trauma Study Group. The subaxial cervical spine injury classification system: a novel approach to recognize the importance of morphology, neurology, and integrity of the disco-ligamentous complex. *Spine* 2007;32(21):2365–2374
- 11 Dvorak MF, Fisher CG, Fehlings MG, et al. The surgical approach to subaxial cervical spine injuries: an evidence-based algorithm based on the SLIC classification system. *Spine* 2007;32(23):2620–2629
- 12 Nassr A, Lee JY, Dvorak MF, et al. Variations in surgical treatment of cervical facet dislocations. *Spine* 2008;33(7):E188–E193