

# Spontaneous Rectus Sheath Hematoma in Pregnancy Complicated by the Development of Transfusion Related Acute Lung Injury: A Case Report and Review of the Literature

Jennifer Gibbs, DO<sup>1</sup> Firas Bridges, MD<sup>2</sup> Kiran Trivedi, DO<sup>1</sup> John Vullo, DO<sup>1</sup>

<sup>1</sup> Department of Obstetrics and Gynecology, Good Samaritan Hospital Medical Center, West Islip, New York

<sup>2</sup> Department of General Surgery and Bariatric Surgery, Good Samaritan Hospital Medical Center, West Islip, New York

Address for correspondence Jennifer Gibbs, DO, Department of Obstetrics and Gynecology, Good Samaritan Hospital Medical Center, West Islip, NY 11795-4958 (e-mail: jennifer.mceachron@gmail.com).

Am J Perinatol Rep 2016;6:e325–e328.

## Abstract

**Background** Rectus sheath hematoma (RSH) represents a rare, but serious cause of abdominal pain.

**Case** Here we discuss the case of a healthy multigravida female who presented at 28 weeks gestation with spontaneous RSH. Conservative management with multiple blood transfusions led to the development of transfusion related acute lung injury (TRALI) and intensive care unit admission. She was managed with noninvasive ventilatory support, gradually improved, and was weaned of ventilation. After hospital discharge, she progressed to full term and delivered a viable male infant vaginally at 37 weeks gestation.

**Conclusion** Review of the literature demonstrates 13 cases of RSH in pregnancy, including our own. No other cases were complicated by transfusion related morbidity. RSH and TRALI are rare, but life threatening entities that can complicate pregnancy.

## Keywords

- ▶ pregnancy
- ▶ rectus sheath hematoma
- ▶ respiratory failure
- ▶ transfusion

The differential diagnosis of abdominal pain in pregnancy is broad and can be secondary to obstetric or nonobstetric etiologies. Rectus sheath hematoma (RSH) is a rare cause of abdominal pain.<sup>1,2</sup> In cases of RSH, conservative management is preferred when the patient is stable, consisting of close observation and blood transfusion to maintain hematocrit above 6 g/dL. The leading cause of transfusion related mortality in the United States is TRALI (transfusion related acute lung injury). Mortality rates of TRALI are as high as 25%.<sup>3,4</sup> Additionally, mortality rates associated with RSH are approximately 4% in the general population and as high as 13% in pregnancy.<sup>5</sup> Here we will discuss the case of a healthy multiparous female who presented at 28 weeks gestation with spontaneous RSH and was managed conservatively with observation and blood transfusions. She

subsequently developed TRALI and required admission to the critical care unit.

## Case

A 35-year-old G3P2002 female at 28 4/7 weeks gestation presented to labor and delivery with complaints of abdominal pain and fatigue for 3 days duration. She described the pain as severe, pressure-like in quality, and isolated to the right side of the abdomen. On exam, she was found to have exquisite tenderness from the right subcostal margin extending to the right lower quadrant. Review of symptoms elicited history of recent bronchitis with multiple bouts of coughing.

Blood work was significant for anemia, with a hemoglobin of 9 g/dL. MRI was performed, revealing a large RSH (→ Fig. 1),

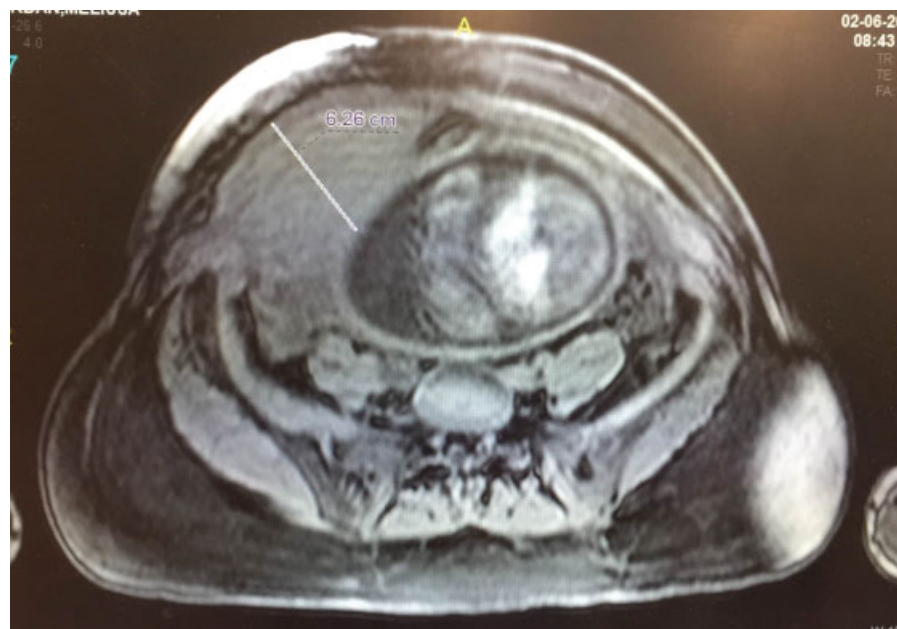
received  
July 20, 2016  
accepted after revision  
August 13, 2016

DOI <http://dx.doi.org/10.1055/s-0036-1593353>.  
ISSN 2157-6998.

Copyright © 2016 by Thieme Medical Publishers, Inc., 333 Seventh Avenue, New York, NY 10001, USA.  
Tel: +1(212) 584-4662.

License terms





**Fig. 1** MRI abdomen/pelvis demonstrating large rectus sheath hematoma anterior to gravid uterus. Motion artifact present. (Image obtained with permission from Good Samaritan Hospital Medical Center Radiology Department.)

measuring 26.0 × 6.3 × 7.7 cm. Surgical consultation was obtained and in conjunction with obstetric and maternal–fetal medicine teams, a decision was made to proceed with conservative management. Serial hematocrits and abdominal exams were performed to monitor hemodynamic status and expansion of the hematoma. Over the first 48 hours of hospitalization, hemoglobin continued to decline to 6 g/dL, prompting transfusion of multiple blood products, including six units of packed RBCs, two units of fresh frozen plasma (FFP), and one donor unit of platelets. Despite normal platelet count and coagulation studies, FFP and platelets were administered with packed red cells to avoid dilutional coagulopathy. Several hours after completion of transfusions, the patient developed acute shortness of breath with oxygen desaturation to 71 to 76% on room air. The patient was promptly evaluated by the critical care team, placed on noninvasive ventilatory support, and subsequently transferred to the intensive care unit. Echocardiogram was performed, and found to be normal with no signs of right heart strain. This essentially ruled out other etiologies of acute respiratory distress, including massive pulmonary embolism and circulatory overload.

Oxygen saturation rapidly improved with ventilatory support and she was gradually weaned off ventilation over the following 24 hours. Concurrently, hemoglobin and hematocrit levels stabilized, and no further transfusions were required. The patient was discharged home on hospital day 6 and followed closely as an outpatient by obstetric, maternal–fetal medicine, and surgical teams.

At 37 weeks gestation, an amniocentesis was performed. After the results confirmed fetal lung maturity, a decision was made to proceed with induction of labor. Induction was planned once fetal lung maturity was documented, to allow for delivery in a controlled situation with appropriate staff on

standby. The patient underwent a successful induction of labor with Pitocin; she progressed to complete cervical dilatation and delivered a viable male infant, weighing 8 lb 8 oz. Postpartum she recovered well and was discharged home on postpartum day 2.

## Discussion

Accurate diagnosis of acute abdominal pain in pregnancy can be challenging. Etiologies are diverse and include obstetric causes such as preterm labor, placental abruption, and uterine rupture; as well as nonobstetric causes such as appendicitis, intestinal obstruction, biliary disease, and many others. RSH is an uncommon cause of abdominal pain.<sup>1</sup> Of all patients presenting to emergency departments with abdominal pain, RSH was identified as the etiology in only 1.8% of cases.<sup>5</sup>

The blood supply to the rectus abdominis muscles consists of the superior and inferior epigastric arteries.<sup>3,5</sup> Disruption of these vessels or their tributaries can lead to massive hemorrhage. The pregnant uterus exerts significant strain on the anterior abdominal wall with advancing gestational age. Diastasis recti is a separation of the rectus muscles, leading to weakening of the anterior abdominal wall. This can leave the abdominal wall more susceptible to minor trauma. Over half of multiparous women were found to have diastasis recti at time of hysterectomy.<sup>6</sup> Risk factors for RSH include anticoagulation, trauma, and excessive abdominal straining. Symptoms include abdominal pain, palpable abdominal mass, and, in its most severe form, hypotension and hemorrhagic shock. Fothergill sign, palpable abdominal mass that is unchanged with contraction of rectus muscles, may be present.<sup>1,3,5</sup>

The differential diagnosis for abdominal pain in pregnancy is broad. Imaging is often necessary to clarify the picture.

Computed tomography (CT) scan is 100% sensitive in the diagnosis of RSH, but comes at the expense of radiation exposure to the mother and fetus.<sup>1</sup> Magnetic resonance imaging avoids ionizing radiation and can be employed in the setting of pregnancy. A classification system of RSH based on CT imaging was described by Berna et al to help aid in management.<sup>1-3,5</sup>

- Type I: Hematoma is intramuscular; an increase in the size of the muscle is present. Ovoid or fusiform hyperdensity may be present. Hematoma is unilateral and does not dissect along facial planes.
- Type II: Hematoma is intramuscular but with blood between the muscle and the transversalis fascia. May be unilateral or bilateral, but no blood is present in the prevesical space. Fall in hematocrit may be observed.
- Type III: Hematoma may or may not affect the muscle, and blood is observed between the transversalis fascia and the muscle, in the peritoneum, and in the prevesical space. Hemoperitoneum may be present.

Type I hematomas can be managed expectantly and do not necessarily require hospitalization. Type II and III hematomas most always require hospitalization with possible transfusion and close monitoring of hemodynamic parameters. Our patient was classified as a type II hematoma. When the patient is hemodynamically stable, conservative management with pain medication, fluid resuscitation, and transfusions as needed are preferred.

The goal of transfusion should be to maintain hemodynamic stability, and also to maintain adequate maternal hematocrit for fetal well being. Total blood volume increases by 50% in pregnancy, with a 30% increase in red cell mass producing a physiologic dilutional anemia.<sup>7,8</sup> Severe maternal anemia with hemoglobin levels less than 6 g/dL has been associated with abnormal fetal oxygen status, resulting in nonreassuring fetal heart tracing, cerebral vasodilatation, and ultimately fetal death.<sup>9</sup>

The most common cause of transfusion related mortality in the United States is TRALI. Almost all cases of TRALI will develop within 6 hours of transfusion of blood products. Symptoms include tachypnea, cyanosis, dyspnea, and fever. Physiologic findings of acute lung injury will be present, including PaO<sub>2</sub>/FiO<sub>2</sub> less than 300 mm Hg, diffuse bilateral pulmonary infiltrates, and normal cardiac function.<sup>4</sup>

The differential diagnosis of acute respiratory distress in a patient receiving transfusions also includes transfusion associated circulatory overload (TACO). As the name implies, TACO is purely secondary to volume overloaded state and is most commonly seen in patients who are rapidly transfused with concurrent conditions such as congestive heart failure (CHF), leaving them susceptible to volume changes.<sup>3,4</sup> On the other hand, the pathophysiology of TRALI is complex and involves neutrophil activation, endothelial damage, and capillary leak within pulmonary circulation.<sup>4</sup> Treatment for both conditions centers around respiratory support, but those patients affected by TACO will also benefit from aggressive diuresis to eliminate excess intravascular fluid. Patients with TRALI will require continued aggressive ventilatory support

with gradual weaning and will benefit less from diuretic therapy. The cornerstone for treatment of TRALI is supportive care, including aggressive respiratory support with oxygen and mechanical ventilation. The overall mortality rate with TRALI ranges from 5 to 25%. Most TRALI patients who are identified early and managed aggressively will improve with supportive therapy within 72 hours.<sup>3,4</sup>

Pregnancy leads to anatomic and physiologic changes that leave women at higher risk for the development of respiratory failure. These include pulmonary changes such as decreased functional residual capacity and increased tidal volume, and minute ventilation and oxygen consumption. Additional physiologic changes include decreased serum colloid oncotic pressure, decreased vascular resistance, and a state of physiologic respiratory alkalosis.<sup>7,10</sup> Together, these changes leave gravid patients particularly sensitive to large fluid shifts and at higher risk for the development of pulmonary edema than the nonpregnant population.<sup>7,8,10</sup> The goal of oxygenation in pregnancy should be to maintain maternal oxygen saturation >95% or PaO<sub>2</sub> 70 mm Hg or higher. Hypoxia is poorly tolerated by the fetus and can lead to rapid deterioration and acidemia in the fetus. If these goals cannot be achieved by supplemental oxygen, mechanical ventilation should be initiated aggressively.<sup>10</sup> There is lack of data regarding mechanical ventilation in pregnant patients, and most theories that exist are based on animal studies and case reports. Ventilation can be in the form of invasive or noninvasive ventilation. Extreme caution should be used when choosing noninvasive ventilation in pregnant patients who are at increased risk of aspiration secondary to decreased tone of the lower esophageal sphincter and increased intra-abdominal pressure. Aspiration in a patient who is already in a state of respiratory compromise could be devastating to the recovery process.<sup>10</sup>

When our patient initially presented and was diagnosed with RSH, the goal of treatment was conservative therapy and avoidance of surgery. During treatment, our patient developed a life threatening transfusion reaction. It is unlikely that surgical evacuation would not have eliminated the need for transfusion completely.

## Review of the Literature

An extensive review of the literature was performed using PubMed database. Only 13 cases of spontaneous RSH in pregnancy were identified from 1990 to present, including our case. As in our case, the precipitating factor was identified as a cough or sneeze in 61.5% of cases. Correct preoperative diagnosis was only made in 38.5% of cases. Fetal and maternal mortality were each limited to only one case in which massive hemorrhage ensued at time of cesarean delivery and surgical exploration. Unlike our case, 69.2% of all cases were managed with surgical evacuation. Although our case had the only transfusion associated morbidity, 70% of cases required blood product administration to maintain hemodynamic stability. Importantly, only five cases were correctly diagnosed preoperatively, and of those five cases, expectant management was employed in three cases with successful prolongation of pregnancy. Of the six cases that were not correctly diagnosed

preoperatively/anteartum, all underwent immediate surgical management of the hematoma with cesarean delivery, leading to one maternal and one fetal death, illustrating the importance of correct preoperative diagnosis.

Although several cases of TRALI have been associated with postpartum hemorrhage and massive transfusion, in a review of the literature, no cases complicating the antepartum period were identified.<sup>11</sup> There are few antepartum situations that warrant massive transfusion and most cases of massive transfusion in obstetrics are associated with immediate postpartum hemorrhage. Multiple reports of acute respiratory distress syndrome complicating pregnancy were identified, but none specifically related to transfusions. The treatment of pregnant women with respiratory failure is essentially the same as for the nonpregnant patient. Ventilatory support and management of the underlying etiology of respiratory failure is key and early aggressive management should not be altered secondary to the pregnant state.<sup>10</sup>

## Conclusions

Rectus sheath hematoma is a rare cause of abdominal pain that can lead to massive hemorrhage. Prompt recognition is key and is illustrated by multiple case reports demonstrating that the majority of morbidity and mortality associated with RSH is due to delay in correct diagnosis. TRALI is the most common transfusion related mortality in the United States, but no documented cases in the antepartum period were identified. Our patient's antenatal course was complicated by both of these uncommon entities. With a multidisciplinary

approach and conservative management, our patient progressed to full term and delivered a viable male infant without complication.

## References

- 1 Tolcher MC, Nitsche JF, Arendt KW, Rose CH. Spontaneous rectus sheath hematoma pregnancy: case report and review of the literature. *Obstet Gynecol Surv* 2010;65(8):517-522
- 2 Wai C, Bhatia K, Clegg I. Rectus sheath haematoma: a rare cause of abdominal pain in pregnancy. *Int J Obstet Anesth* 2015;24(2):194-195
- 3 Brunicaudi F. Charles. *Schwartz Essentials of Surgery*. 10th ed. New York: McGraw-Hill, Health Pub. Division; 2015. Print
- 4 Silliman CC, Ambruso DR, Boshkov LK. Transfusion-related acute lung injury. *Blood* 2005;105(6):2266-2273
- 5 Chang W, Dronen SC. Rectus Sheath Hematoma. *Medscape* 2014
- 6 Turan V, Colluoglu C, Turkyilmaz E, Korucuoglu U. Prevalence of diastasis recti abdominis in the population of young multiparous adults in Turkey. *Ginekol Pol* 2011;82(11):817-821
- 7 Cunningham GF. *Williams Obstetrics*. 24th ed. New York: McGraw-Hill Professional; 2014. Print
- 8 Creasy RK, Resnik R. *Maternal-Fetal Medicine Principles and Practice*. 7th ed. Philadelphia, PA: Saunders/Elsevier; 2014. Print
- 9 American College of Obstetricians and Gynecologists. *ACOG Practice Bulletin No. 95: anemia in pregnancy*. *Obstet Gynecol* 2008;112(1):201-207
- 10 Schwaiberger D, Karcz M, Menk M, Papadakos PJ, Dantoni SE. Respiratory Failure and Mechanical Ventilation in the Pregnant Patient. *Crit Care Clin* 2016;32(1):85-95
- 11 Teofili L, Bianchi M, Zanfini BA, et al. Acute lung injury complicating blood transfusion in post-partum hemorrhage: incidence and risk factors. *Mediterr J Hematol Infect Dis* 2014;6(1):e2014069