

Large Cervical Vagus Nerve Tumor in a Patient with Neurofibromatosis Type 1 Treated with Gross Total Resection: Case Report and Review of the Literature

David P. Bray^{1,*} Andrew K. Chan^{2,*} Cynthia T. Chin³ Line Jacques²

¹Department of Neurological Surgery, Columbia University, New York, New York, United States

²Department of Neurological Surgery, University of California, San Francisco, California, United States

³Department of Neuroradiology, University of California, San Francisco, California, United States

Address for correspondence Andrew K. Chan, MD, Department of Neurological Surgery, University of California, San Francisco, 505 Parnassus Avenue, M780, San Francisco, CA 94143, United States (e-mail: andrew.chan@ucsf.edu).

J Brachial Plex Peripher Nerve Inj 2016;11:e48–e54.

Abstract

Keywords

- ▶ vagus nerve tumor
- ▶ cervical vagus nerve
- ▶ neurofibromatosis type 1
- ▶ neurofibroma
- ▶ neck mass
- ▶ diffusion tensor imaging

Neurofibromas are benign peripheral nerve sheath tumors that occur commonly in individuals with neurocutaneous disorders such as neurofibromatosis type 1. Vagal nerve neurofibromas, however, are a relatively rare occurrence. We present the case of a 22-year-old man with neurofibromatosis type 1 with a neurofibroma of the left cervical vagal nerve. The mass was resected through an anterior approach without major event. In the postoperative course, the patient developed left vocal cord paralysis treated with medialization with injectable gel. We then present a comprehensive review of the literature for surgical resection of vagal nerve neurofibromas.

Introduction

Neurofibromas are benign peripheral neural sheath tumors composed of Schwann cells, fibroblast-like cells, and perineurial-like cells.^{1–3} They can occur in a sporadic fashion, or in association with a genetic neurocutaneous disorder such as neurofibromatosis type 1 (NF1), formerly referred to as von Recklinghausen disease. NF1 is an autosomal dominant genetic disease and is estimated to occur in 1 per 3,000 to 4,000 individuals.^{1,4,5} Neurofibromas that are associated with NF1 are thought to arise from loss of *NF1* gene expression from the long arm of chromosome 17 (17q) which leads to increased levels of activated RAS.^{1,2} Activated RAS is an oncogene which promotes unregulated growth. Loss of *NF1* leads to increased occurrence of neurofibromas and optic gliomas, as well as pathognomonic findings of pigmented nodules of the iris (Lisch nodules) and pigmented skin lesions (café au lait spots).

* David P. Bray and Andrew K. Chan contributed equally into this article.

Here we present the rare case of a large vagus nerve neurofibroma that was resected in a patient with NF1. We present the case report of the patient, including imaging findings and a technical note of a gross total resection (GTR). We also provide a review of the literature, including a discussion on the treatment algorithm of a patient with a vagus nerve neurofibroma.

Case Description

History and Examination

The patient is a 22-year-old man with a history of NF1 and more than 25 previous neurofibroma resections including a left below-the-knee amputation who presented with a growing mass in his left anterior neck. He first noticed the mass 5 years ago and noted that it has been steadily growing during that time. The mass was associated with mild discomfort and tenderness. He was without dysphagia, dysphonia, hearing changes, or other cranial nerve and brachial plexus symptoms.

Physical examination revealed a large left anterior cervical mass that was tender, hard, and not mobile to palpation.

received
May 17, 2016
accepted
October 4, 2016

DOI <http://dx.doi.org/10.1055/s-0036-1594010>.
ISSN 1749-7221.

© 2016 Georg Thieme Verlag KG
Stuttgart · New York

License terms



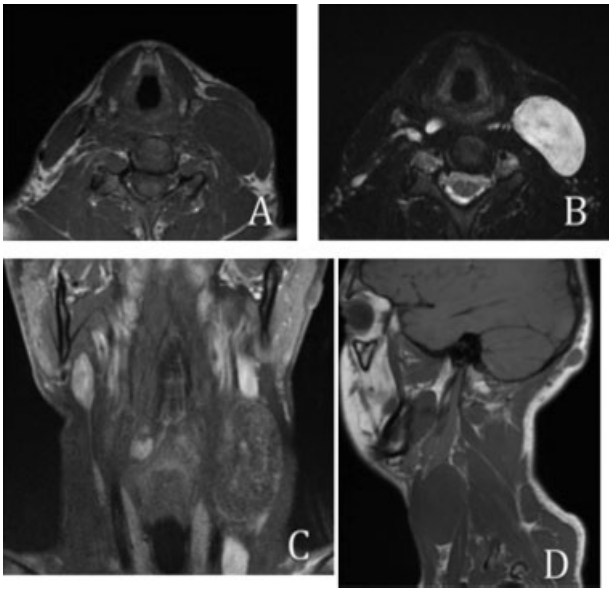


Fig. 1 Preoperative magnetic resonance imaging from left, right, to below: (A) Axial T1 without contrast shows isointense mass; (B) Axial T2 shows hyperintense mass; (C) Coronal T1 with contrast shows heterogeneously enhancing mass; (D) Sagittal T1 without contrast shows isointense mass.

Neuroimaging

Magnetic resonance imaging (MRI) with and without gadolinium contrast revealed a well-circumscribed, T2 hyperintense, T1 isointense mass deep to the left sternocleidomastoid muscle (SCM) (► **Fig. 1**). The mass demonstrated heterogenous contrast enhancement and was measured to be $2.6 \times 4.4 \times 6.2$ cm.

Diffusion imaging demonstrated a mass with an apparent diffusion coefficient (ADC) of 2×10^{-3} mm²/sec (► **Fig. 2**). Imaging was consistent with a neurofibroma.

In addition to the left cervical mass, there were innumerable smaller T2 hyperintense, avidly enhancing lesions throughout the superficial and deep soft tissues of the neck consistent with neurofibromas.

Because of concern for progressive increase in size of the mass, patient discomfort, cosmetic appearance, and diagnosis purposes, we proceeded with surgical resection. Otolaryngology was consulted and assisted with the neck dissection.

Operation

After induction with general endotracheal anesthesia, the patient was placed in the supine position. The endotracheal tube was fit with the neural integrity monitor EMG (NIM-Response 3.0 System; Medtronic, Jacksonville, FL). Other electrodes for neuromonitoring were applied by the electrophysiologist. The anterior left neck was prepped and sterilized in the usual fashion. A shoulder roll was placed, and a horizontal skin incision was marked (► **Fig. 3**). The neck was injected with 3 mL of lidocaine with epinephrine. The superficial skin incision was made with a 5 blade, and subplatysmal skin flaps were elevated superiorly to the mandible and inferiorly to the clavicle.

The mass was palpated anteriorly and deep to the SCM. The external jugular vein (EJV) was preserved along with the greater auricular nerve. The SCM was elevated along its lateral surface and the omohyoid identified. The internal jugular vein (IJV) was identified and the carotid artery was palpated deep

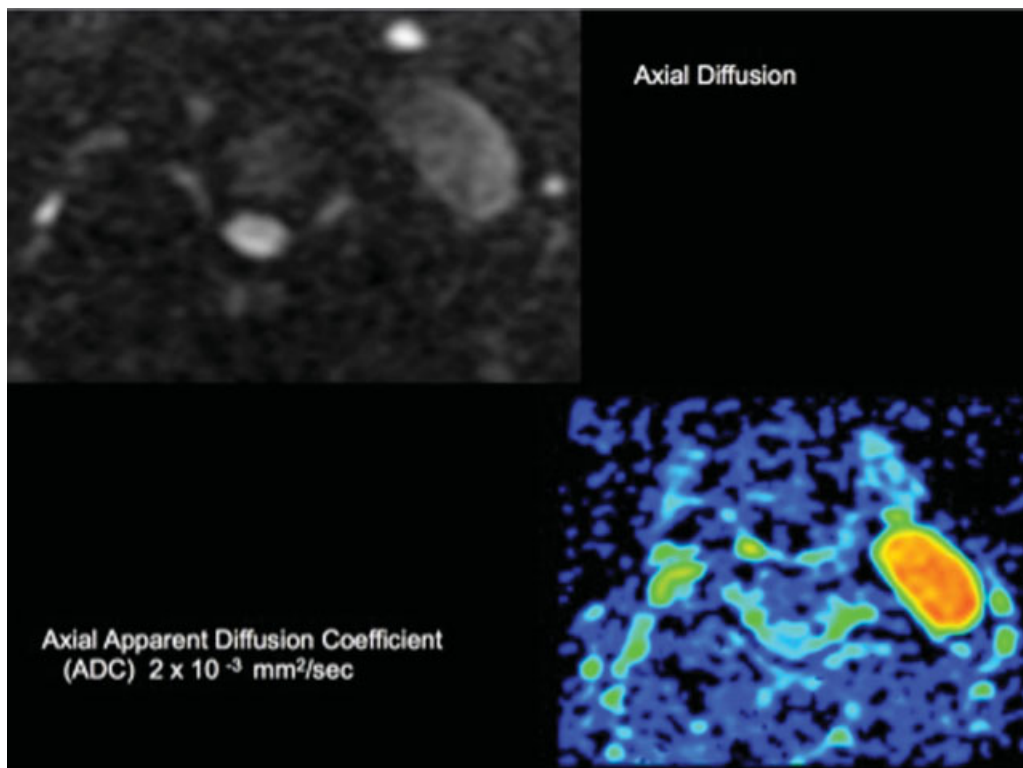


Fig. 2 Preoperative magnetic resonance imaging: axial diffusion-weighted imaging (DWI) and apparent diffusion coefficient (ADC) map through the left vagal neurofibroma demonstrate increased signal on DWI with relative increased diffusivity on the ADC map measuring 2×10^{-3} mm²/sec.

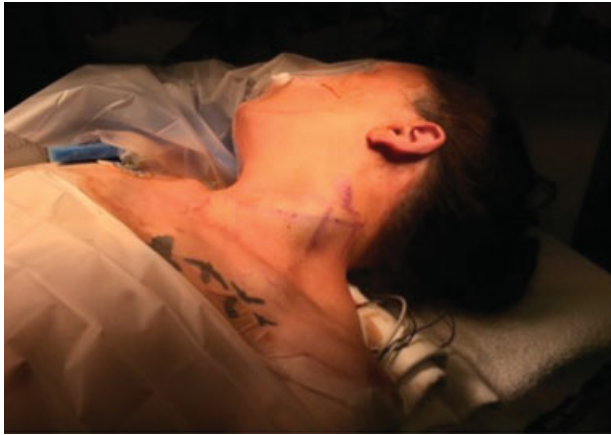

Fig. 3 Patient positioning: The patient is supine and marked for an oblique anterior neck incision.

and medial to the mass. The mass was greatly displacing the vessels around it, including the IJV, which was distended.

The mass was dissected along its posterior border and an attempt was made to identify the cranial nerve (CN) XI; CN XII was above the superior edge of the mass. The mass was dissected down to the prevertebral muscles and off of the deep cervical fascia. The inferior aspect of the tumor was identified and was connected to a nerve travelling along the EJV and IJV. This nerve was stimulated and was found to be the vagus nerve with stimulation of the laryngeal muscles on the NIM EMG.

Next, the great vessels were isolated off the mass with gentle dissection along the IJV and the carotid artery. The vessels were freed from the base of the mass and then from the superior edge of the mass. The final remaining fascial attachments were freed and the tumor capsule was identified (► Fig. 4).

The tumor was resected while preserving the vagal nerve. One branch going to the tumor was not functional (determined by stimulation) and was removed. We were able to stimulate at 0.5 mV and had a strong response of the laryn-

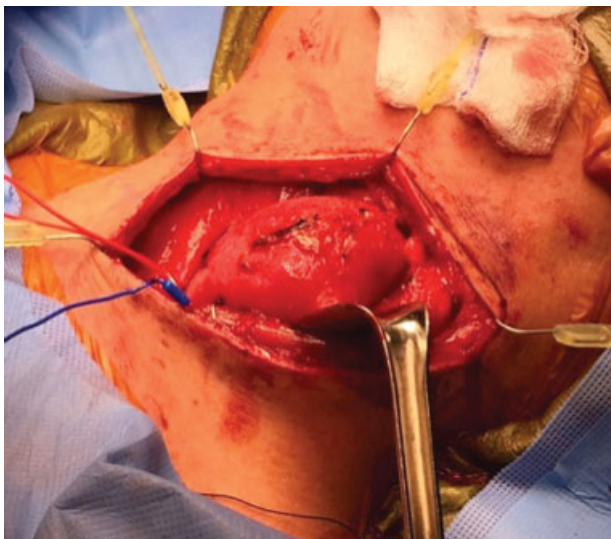


Fig. 4 Vagus nerve tumor mass visualized after wide anterior neck dissection. The sternocleidomastoid muscle is retracted laterally.

geal musculature prior to resection of the tumor. However, the preserved nerve was not able to be stimulated at 1.5 mV at the end of the resection. Elements of the removed tumor were sent to the pathology laboratory for permanent assessment. The mass was consistent with a myxoid, cystic neurofibroma, without areas of hemorrhage, necrosis, or induration (► Figs. 5 and 6). The resection cavity was inspected for residual tumor and it was concluded that a near GTR was achieved (► Fig. 7). A Jackson-Pratt drain was placed in the inferior neck and under the SCM. The platysma was closed with 3–0 vicryl and the skin with 4–0 subcuticular monocryl.

Postoperative Course

The patient noted a change in the quality of his voice after surgery that had not improved by his 1-month postoperative office visit. He noted intermittent coughing and choking with swallowing while supine. He had no difficulty swallowing while sitting upright. He was frustrated with the quality of his voice and felt that he could not be heard clearly over the phone.

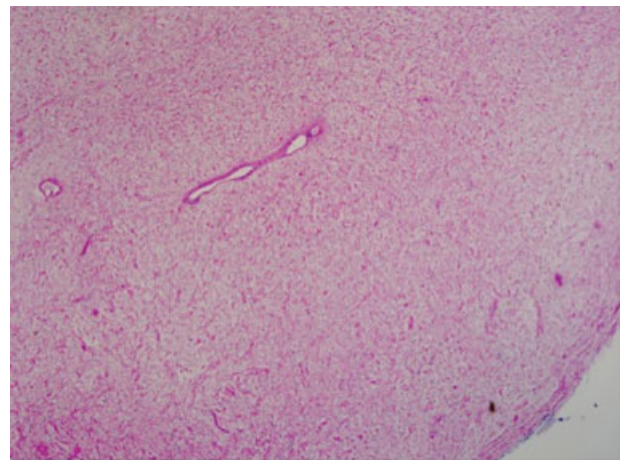


Fig. 5 Hematoxylin and eosin stain of resected mass. Findings consistent with a myxoid, cystic neurofibroma, without areas of hemorrhage, necrosis, or induration ($\times 10$ magnification).

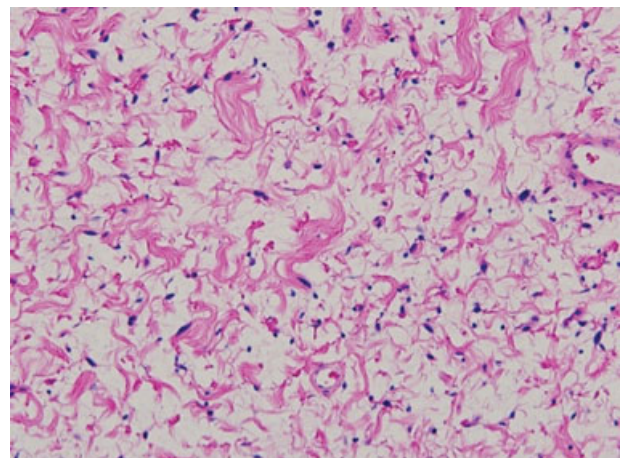


Fig. 6 Hematoxylin and eosin stain of resected mass, magnified. Wire-like collagen resembles “shredded carrots” ($\times 40$ magnification).

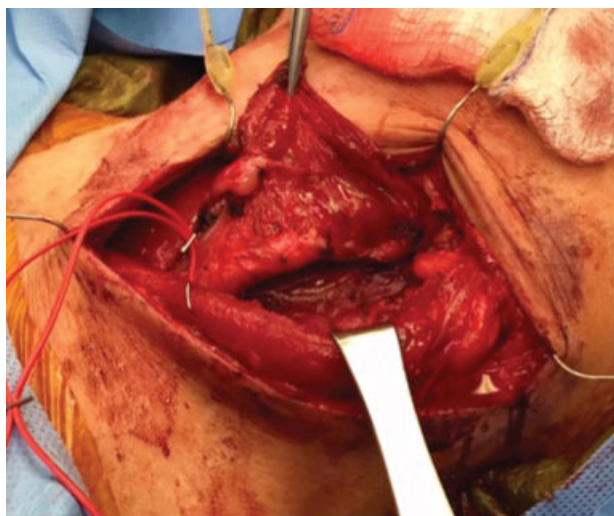


Fig. 7 Vagus nerve tumor resected. Vagus nerve tumor with nearly gross total resection. Sternocleidomastoid muscle retracted laterally.

Laryngoscopy 1-month postoperative confirmed a left vocal cord paralysis. He was scheduled to receive medialization of the left vocal cord with Prolarynx Gel (Merz North America, Inc., Raleigh, North Carolina (NC), USA).

Discussion

Neoplasms of the vagus nerve are rare. Most of our literature on the subject of epidemiology and management of these lesions is composed of case studies and series. Within these series, the majority of neoplasms of the vagus nerve are schwannomas.⁶⁻¹¹

Neurofibromas can theoretically arise from any peripheral nerve. It is thought that approximately 25% of symptomatic neurofibromas occur in the head and neck region.¹² Occasionally, they can cause cranial neuropathies by direct compression on CN IX, XI, and XII or a Horner syndrome via superior cervical ganglion compression.^{6,8,13,14} They are generally asymptomatic until they are large enough to cause discomfort or disfigurement. About one-half of neurofibromas present with pain.^{3,7} Vagus nerve tumors can present with dysphagia.¹⁵ One case study of a vagus nerve sheath tumor described percussion of the mass causing a cough.^{7,16} Most studies of vagus nerve neurofibromas have not borne out a sex-related predilection for occurrence. Peetermans et al¹² found that the age occurrence of vagus nerve neoplasms followed a bimodal distribution with peaks at the ages of 33 and 55. Physical exam maneuvers that are characteristic of peripheral nerve sheath tumors are a laterally mobile mass that cannot be manipulated superiorly or inferiorly. While the overwhelming majority of neurofibromas of the head and neck are benign, slow-growing tumors, it has been reported that they can degenerate into becoming malignant masses.¹⁷ Interestingly, a major risk factor for the development of malignant peripheral nerve sheath tumors in the head and neck is an antecedent history of radiation.¹⁷

The management of a neurofibroma in a patient with NF1 should differ from the management of a patient with a spontaneous nerve sheath tumor. First, neurofibromas occur with greater prevalence in individuals with NF1, vis-à-vis schwannomas, which are the most common neoplasms of the vagal nerve. Dabir et al studied intrathoracic vagal nerve tumors and found that 28% of all tumors were associated with NF1.¹⁸ Histological examination determined that all NF1 intrathoracic vagal nerve tumors were neurofibromas. Second, patients with NF1 generally have multiple nerve sheath tumors. Indeed, as McClatchey lamented in his review of neurofibromatosis, the true challenge in managing patients with NF1 is the “sheer multiplicity of tumors.”² Fifty-four percent of individuals with the NF1 diagnosis have one or more neurofibromas.¹⁹ Our patient is representative of this problem as he had at least 25 prior surgeries for neurofibromas by the age of 22 years. It is generally advised to delay surgery for excision of neurofibromas unless they are rapidly growing or are symptomatic due to size or compression on other neurovascular structures.

Additionally complicating the surgical management of NF1 neurofibromas, patients with NF1 have a higher prevalence of developing *plexiform* neurofibromas. Case series demonstrate that 27 to 43% of patients with NF1 will develop neurofibromas of the plexiform variety.¹⁹⁻²² While schwannomas and sporadic localized neurofibromas tend to be either encapsulated or circumscribed, plexiform neurofibromas involve multiple fascicles of the same nerve and are more diffuse in nature.¹ Plexiform neurofibromas tend to be infiltrative and grow along tissue planes.^{7,23} They often cannot be completely excised without sacrifice of much of the nerve and therefore resection can lead to significant loss of neurological function.^{7,23} An obvious solution to this dilemma is to leave behind remnants of tumor that cannot be resected without sacrificing neurological function; however, neurofibromas in patients with NF1 have a rate of 10 to 15% malignant degeneration.^{7,23-25} Studies have suggested that 50 to 60% of malignant peripheral nerve sheath tumors observed in clinical practice are associated with patients with NF1. These tumors have high morbidity and high rates of recurrence if GTR is not achieved.²⁶⁻²⁹

Often, clinicians tend to approach any mass in the neck as “malignant until proven otherwise.” Ultrasonography can be helpful in the initial assessment of a suspicious neck mass due to its availability, ease of use, and real-time results it provides.³⁰ Additionally, the dynamic nature of the ultrasound imaging modality can let the surgeon determine the interaction of the mass with surrounding neurovascular components. If a peripheral nerve sheath tumor is suspected by history and physical exam/ultrasound findings, it is reasonable to pursue MR imaging of the mass. MRI is accepted as the best imaging modality to characterize peripheral nerve sheath tumors.^{31,32} As demonstrated with this case report, neurofibromas are usually T1 isointense, T2 hyperintense, and heterogeneously enhancing on T1 post-gadolinium contrast.^{31,32} In at least one prospective trial, MR diffusion tensor imaging (DTI) has allowed for direct visualization of specific nerve tracts entering and leaving a peripheral nerve sheath tumor.³³

Benign and malignant primary nerve sheath tumors demonstrate overlapping features on MR imaging, including T2 hyperintensity, focal enlargement, and enhancement.^{34,35} Diffusivity measurements from diffusion-weighted imaging (DWI) may be helpful in differentiating malignant and benign peripheral nerve sheath tumors.³⁶

Diffusivity, or microscopic mobility of water protons in tissue, inversely correlates with tumor cellularity and tumor grade in general.³⁶ The ADC is a measure of the diffusivity. Statistically significant differences in mean ADC values have been demonstrated between benign and malignant peripheral nerve lesions with malignant lesions demonstrating $ADC \leq 1.08 \times 10^{-3} \text{ mm}^2/\text{sec}$, and benign lesions demonstrating $ADC \geq 1.30 \times 10^{-3} \text{ mm}^2/\text{sec}$.³⁷ The relatively high ADC value of this particular vagal nerve neurofibroma ($2 \times 10^{-3} \text{ mm}^2/\text{sec}$) was supportive of benign histology, correlating with the final pathology.

The difference in ADC values may reflect tumor cellularity, integrity of cell membranes, nuclear-to-cytoplasmic ratio, and water content of the extracellular matrix. These features

have been postulated to account for relatively low diffusivity within malignant solid tumors in prior studies.^{38,39}

As mentioned previously, the gold-standard treatment for a symptomatic vagus nerve tumor is an attempt for GTR with preservation of neurological function as radiosurgery is not effective on these tumors.^{7,8,23,40} Neurofibromas often prove to be the most difficult nerve sheath tumors to achieve GTR.⁴¹ Surgery for resection of a vagus tumor mass should be a multiple disciplinary endeavor.¹⁵ In our case, both otolaryngologists and neurosurgeons were employed to treat this tumor in a complicated anatomical area. Otolaryngologists performed a large neck dissection in our patient to create a wide operative field, which is critical to avoid injury to the important neurovascular structures that traverse the anatomical area. While imaging can help with diagnosis and inform safe operative corridors for the surgeon, electromyography (EMG) for nerve action potentials (NAP) must be used intraoperatively for safe tumor resection.⁴² In our case, after the tumor mass was visualized following the neck dissection, NAP was used to identify on which nerve the tumor was

Table 1 Cervical vagus nerve neurofibromas treated with resection

Author	Age	Sex	NF1	Presenting symptom(s)	Pathology	Complication/Significant follow-up
Katz et al ⁴⁶	47	M	Yes	Neck mass	Benign neurofibroma	None
Brandenburg ⁴⁷	35	F	Yes	Neck mass	Benign neurofibroma	Vocal cord palsy
Maisel and Ogura ⁴⁸	11	F	Yes	Neck mass, dysphagia, hoarseness	Benign plexiform neurofibroma	Transient vocal cord palsy
Andrioli et al ⁴⁹	25	M	Yes	Dysphonia, unilateral tongue palsy	Benign neurofibroma	None
Moore et al ¹⁴	34	M	No	Neck mass	Benign neurofibroma	Vocal cord palsy
Green et al ⁶	N/A	N/A	N/A	N/A	N/A	None provided
Green et al ⁶	20	M	Yes	Neck mass	Benign neurofibroma	Transient vocal cord palsy
Kuniak and Strelka ⁵⁰	29	M	Yes	Neck mass	Malignant neurofibroma	Reoccurrence and death
Peetermans et al ¹²	24	F	No	Dysphagia, hoarseness	Benign neurofibroma	None
Shimizu et al ⁵¹	48	F	Yes	Neck mass	Benign neurofibroma	None provided
Gilmer-Hill and Kline ⁸	64	F	No	Neck mass, hoarseness	Benign neurofibroma	Occasional hoarseness
Fujino et al ⁵²	26	M	Yes	Neck mass	Benign neurofibroma	6 mo vocal cord palsy
Fujino et al ⁵²	63	M	No	Incidentally found on chest X-ray	Benign neurofibroma	None
Ilgner et al ⁵³	39	N/A	No	N/A	Malignant neurofibroma	None provided
Ozcan et al ⁵⁴	19	F	Yes	Neck mass	Benign neurofibroma	None provided
Kuzu et al ⁵⁵	45	F	No	Rapidly enlarging neck mass	Malignant neurofibroma	None provided
Cihangioglu et al ⁵⁶	32	F	No (NF2 +)	Dysphonia, hoarseness	Benign plexiform neurofibroma	None
Molina et al ⁵⁷	23	F	Yes	Neck mass, cough, hoarseness	Malignant neurofibroma	Horner, vocal cord palsy, tongue fasciculation
Matejcek et al ⁵⁸	33	F	Yes	Neck mass, dysphagia, hoarseness	Benign neurofibroma	None
Scheithauer et al ¹⁷	32	M	Yes	Dysphagia, hoarseness	Malignant neurofibroma	Received radiotherapy
Scheithauer et al ¹⁷	44	M	No	Neck mass	Malignant neurofibroma	Dead 6 mo after surgery
Scheithauer et al ¹⁷	23	F	Yes	Neck mass, dysphagia	Malignant neurofibroma	Reoccurrence, death shortly after surgery
Guler et al ⁵⁹	10	M	Yes	Neck mass	Benign neurofibroma	None
Sesenna et al ⁶⁰	16	F	Yes	Neck mass	Malignant neurofibroma	8-mo vocal cord palsy
Yazar et al ⁶¹	46	F	Yes	Neck mass, dysphagia	Benign plexiform neurofibroma	None
Current study	22	M	Yes	Neck mass	Benign neurofibroma	Vocal cord palsy

attached. NAP was assessed throughout the operation to delineate which nerve fascicles were nonfunctional, and therefore appropriate to sacrifice.

While schwannomas have one entering and one leaving fascicle to the tumor mass, allowing for fascicle excision, neurofibromas have multiple fascicles travelling to and from the tumor mass. Many different approaches have been advocated for the treatment of neurofibromas, from a trial of watchful waiting⁴³ to en bloc excision with end-to-end nerve grafting.⁴⁴ Donner et al advised for the surgical treatment of intracapsular enucleation for neurofibromas.⁷ This technique was employed in treating the patient in this case study. The tumor capsule should be longitudinally incised and entered. Microsurgical techniques should be used to meticulously separate each fascicle from tumor. Gentle retraction on surrounding fascicles is applied to delicately remove the tumor mass from viable nerve. NAP is consulted throughout the case to ensure preservation of neurological function. Resected tumor should be sent for histopathological evaluation during the operative case. If the tumor is determined to be benign, surgeons should strike a balance between preserving neurological function and achieving GTR. Using this technique, we were able to accomplish a near GTR for this patient.

Possible complications from vagus nerve neurofibroma resection surgery include injury to important neurovascular structures in the neck, especially injury to the vagus nerve. This could lead to vocal cord paralysis, arrhythmias, and dysphagia. In their large series that included neurofibroma resections in NF1 patients with multifocal nerve lesions, Donner et al reported a 16% decrease in motor function using the intracapsular enucleation technique. Up to 10% of these patients developed pain syndromes in the sensory distribution associated with the nerve that was operated upon.⁷ Green et al reported a 40% occurrence of dysphagia and 46% occurrence of aspiration after vagus nerve tumor surgery.⁶ Gilmer-Hill and Kline stated that nearly all patients who have vagus nerve tumor resections will develop transient hoarseness postoperatively.⁸ Our patient noticed a change in voice that did not resolve within a month postoperatively. Laryngoscopic examination revealed a paralyzed left vocal cord which was treated with injection of Prolaryn Gel. At least one study has shown that by 12 months after injection laryngoplasty, 71% of patients experienced at least compensated function of the paralyzed vocal cord.⁴⁵

► **Table 1** shows cervical vagus nerve neurofibromas treated with surgical resection. A PubMed search was completed using search terms “vagus(al) nerve neurofibroma” and “vagus(al) nerve neurilemmoma” from March 1947 to October 2015. Cases of histologically confirmed neurofibromas arising from the cervical level of the vagus nerve (angle of mandible to sternoclavicular joint) were included from English-written abstracts and articles that were retrievable through PubMed. Cases that did not have adequate demographic/histologic information were not translated into English, or were not retrievable through PubMed were not included.

This search found 25 other reported cervical vagus nerve neurofibromas in the literature. The average age of presentation in these cases was 32.8 (± 14.2) years. Sixty percent of patients had NF1; 75% of patients presented with a neck mass; and 46% had dysphagia, hoarseness, or another neurological deficit. After surgery, 45% of patients developed at least transient vocal cord palsy. It appears that postoperative hoarseness and vocal paralysis occur at a relatively high rate after vagus nerve neurofibroma resection, and patients should be counseled about this outcome.

Conclusion

Vagus nerve neurofibromas are rare, but are more common in patients with NF1. Gold-standard treatment of symptomatic benign vagus nerve masses is an attempt at GTR with minimal loss of nerve function. Postoperative hoarseness and vocal paralysis are difficult to avoid in vagus nerve neurofibroma resection.

Source of Funding

None.

References

- 1 Kumar V, Abbas AK, Aster JC, Robbins SL. Robbins Basic Pathology. 9th ed. Philadelphia, PA: Elsevier/Saunders; 2013
- 2 McClatchey AI. Neurofibromatosis. *Annu Rev Pathol* 2007; 2:191–216
- 3 Marocchio LS, Oliveira DT, Pereira MC, Soares CT, Fleury RN. Sporadic and multiple neurofibromas in the head and neck region: a retrospective study of 33 years. *Clin Oral Investig* 2007;11(2): 165–169
- 4 Friedman JM. Epidemiology of neurofibromatosis type 1. *Am J Med Genet* 1999;89(1):1–6
- 5 Packer RJ, Gutmann DH, Rubenstein A, et al. Plexiform neurofibromas in NF1: toward biologic-based therapy. *Neurology* 2002; 58(10):1461–1470
- 6 Green JD Jr, Olsen KD, DeSanto LW, Scheithauer BW. Neoplasms of the vagus nerve. *Laryngoscope* 1988;98(6, Pt 1):648–654
- 7 Donner TR, Voorhies RM, Kline DG. Neural sheath tumors of major nerves. *J Neurosurg* 1994;81(3):362–373
- 8 Gilmer-Hill HS, Kline DG. Neurogenic tumors of the cervical vagus nerve: report of four cases and review of the literature. *Neurosurgery* 2000;46(6):1498–1503
- 9 Chang SC, Schi YM. Neurilemmoma of the vagus nerve. A case report and brief literature review. *Laryngoscope* 1984;94(7): 946–949
- 10 St Pierre S, Theriault R, Leclerc JE. Schwannomas of the vagus nerve in the head and neck. *J Otolaryngol* 1985;14(3):167–170
- 11 Kline DG, Hudson AR. Nerve Injuries: Operative Results for Major Nerve Injuries, Entrapments, and Tumors. 1st ed. Philadelphia, PA: W.B. Saunders; 1995
- 12 Peetermans JF, Van de Heyning PH, Parizel PM, et al. Neurofibroma of the vagus nerve in the head and neck: a case report. *Head Neck* 1991;13(1):56–61
- 13 Persson AV, Frusha JD, Dial PF, Jewell ER. Vagal body tumor: paraganglioma of the head and neck. *CA Cancer J Clin* 1985; 35(4):232–237
- 14 Moore G, Yarrington CT Jr, Mangham CA Jr. Vagal body tumors: diagnosis and treatment. *Laryngoscope* 1986;96(5):533–536

- 15 Latham K, Buchanan EP, Suver D, Gruss JS. Neurofibromatosis of the head and neck: classification and surgical management. *Plast Reconstr Surg* 2015;135(3):845–855
- 16 Park CS, Suh KW, Kim CK. Neurilemmomas of the cervical vagus nerve. *Head Neck* 1991;13(5):439–441
- 17 Scheithauer BW, Erdogan S, Rodriguez FJ, et al. Malignant peripheral nerve sheath tumors of cranial nerves and intracranial contents: a clinicopathologic study of 17 cases. *Am J Surg Pathol* 2009;33(3):325–338
- 18 Dabir RR, Piccione W Jr, Kittle CF. Intrathoracic tumors of the vagus nerve. *Ann Thorac Surg* 1990;50(3):494–497
- 19 Friedman JM, Birch PH. Type 1 neurofibromatosis: a descriptive analysis of the disorder in 1,728 patients. *Am J Med Genet* 1997;70(2):138–143
- 20 Créange A, Zeller J, Rostaing-Rigattieri S, et al. Neurological complications of neurofibromatosis type 1 in adulthood. *Brain* 1999;122(Pt 3):473–481
- 21 Riccardi VM. *Neurofibromatosis: Phenotype, Natural History, and Pathogenesis*. 2nd ed. Baltimore, MD: Johns Hopkins University Press; 1992
- 22 Huson SM, Harper PS, Compston DA. Von Recklinghausen neurofibromatosis. A clinical and population study in south-east Wales. *Brain* 1988;111(Pt 6):1355–1381
- 23 Kim DH, Murovic JA, Tiel RL, Moes G, Kline DG. A series of 397 peripheral neural sheath tumors: 30-year experience at Louisiana State University Health Sciences Center. *J Neurosurg* 2005;102(2):246–255
- 24 Pacelli J, Whitaker CH. Brachial plexopathy due to malignant peripheral nerve sheath tumor in neurofibromatosis type 1: case report and subject review. *Muscle Nerve* 2006;33(5):697–700
- 25 McGaughan JM, Harris DI, Donnai D, et al. A clinical study of type 1 neurofibromatosis in north west England. *J Med Genet* 1999;36(3):197–203
- 26 Ducatman BS, Scheithauer BW, Piepgras DG, Reiman HM, Ilstrup DM. Malignant peripheral nerve sheath tumors. A clinicopathologic study of 120 cases. *Cancer* 1986;57(10):2006–2021
- 27 Hruban RH, Shiu MH, Senie RT, Woodruff JM. Malignant peripheral nerve sheath tumors of the buttock and lower extremity. A study of 43 cases. *Cancer* 1990;66(6):1253–1265
- 28 Kourea HP, Bilsky MH, Leung DH, Lewis JJ, Woodruff JM. Subdiaphragmatic and intrathoracic paraspinal malignant peripheral nerve sheath tumors: a clinicopathologic study of 25 patients and 26 tumors. *Cancer* 1998;82(11):2191–2203
- 29 Woodruff JM. Pathology of tumors of the peripheral nerve sheath in type 1 neurofibromatosis. *Am J Med Genet* 1999;89(1):23–30
- 30 Giovagnorio F, Martinoli C. Sonography of the cervical vagus nerve: normal appearance and abnormal findings. *AJR Am J Roentgenol* 2001;176(3):745–749
- 31 Singh T, Kliot M. Imaging of peripheral nerve tumors. *Neurosurg Focus* 2007;22(6):E6
- 32 Kuntz C IV, Blake L, Britz G, et al. Magnetic resonance neurography of peripheral nerve lesions in the lower extremity. *Neurosurgery* 1996;39(4):750–756, discussion 756–757
- 33 Cage TA, Yuh EL, Hou SW, et al. Visualization of nerve fibers and their relationship to peripheral nerve tumors by diffusion tensor imaging. *Neurosurg Focus* 2015;39(3):E16
- 34 Stoll G, Bendszus M, Perez J, Pham M. Magnetic resonance imaging of the peripheral nervous system. *J Neurol* 2009;256(7):1043–1051
- 35 Li CS, Huang GS, Wu HD, et al. Differentiation of soft tissue benign and malignant peripheral nerve sheath tumors with magnetic resonance imaging. *Clin Imaging* 2008;32(2):121–127
- 36 Chhabra A, Thakkar RS, Andreisek G, et al. Anatomic MR imaging and functional diffusion tensor imaging of peripheral nerve tumors and tumorlike conditions. *AJNR Am J Neuroradiol* 2013;34(4):802–807
- 37 Yuh EL, Jain Palrecha S, Lagemann GM, et al. Diffusivity measurements differentiate benign from malignant lesions in patients with peripheral neuropathy or plexopathy. *AJNR Am J Neuroradiol* 2015;36(1):202–209
- 38 Yamasaki F, Kurisu K, Satoh K, et al. Apparent diffusion coefficient of human brain tumors at MR imaging. *Radiology* 2005;235(3):985–991
- 39 Nagata S, Nishimura H, Uchida M, et al. Diffusion-weighted imaging of soft tissue tumors: usefulness of the apparent diffusion coefficient for differential diagnosis. *Radiat Med* 2008;26(5):287–295
- 40 Russell SM. Preserve the nerve: microsurgical resection of peripheral nerve sheath tumors. *Neurosurgery* 2007;61(3, Suppl):113–117, discussion 117–118
- 41 Safaee M, Parsa AT, Barbaro NM, et al. Association of tumor location, extent of resection, and neurofibromatosis status with clinical outcomes for 221 spinal nerve sheath tumors. *Neurosurg Focus* 2015;39(2):E5
- 42 Maniker AH. Diagnostic steps, imaging, and electrophysiology. *Neurosurg Clin N Am* 2004;15(2):133–144, v
- 43 Ball JR, Biggs MT. Operative steps in management of benign nerve sheath tumors. *Neurosurg Focus* 2007;22(6):E7
- 44 Kline DG, Judice DJ. Operative management of selected brachial plexus lesions. *J Neurosurg* 1983;58(5):631–649
- 45 Arviso LC, Johns MM III, Mathison CC, Klein AM. Long-term outcomes of injection laryngoplasty in patients with potentially recoverable vocal fold paralysis. *Laryngoscope* 2010;120(11):2237–2240
- 46 Katz AD, Passy V, Kaplan L. Neurogenous neoplasms of major nerves of face and neck. *Arch Surg* 1971;103(1):51–56
- 47 Brandenburg JH. Neurogenic tumors of the parapharyngeal space. *Laryngoscope* 1972;82(7):1292–1305
- 48 Maisel RH, Ogura JH. Neurofibromatosis with laryngeal involvement. *Laryngoscope* 1974;84(1):132–140
- 49 Andrioli G, Rigobello L, Mingrino S, Toso V. Tapia's syndrome caused by a neurofibroma of the hypoglossal and vagus nerves: case report. *J Neurosurg* 1980;52(5):730–732
- 50 Kuniak B, Strelka J. Malignant neurofibroma of the cervical portion of the vagus nerve [in Slovak]. *Cesk Otolaryngol* 1990;39(5):313–317
- 51 Shimizu H, Yoshihara T, Sakurai H, Nozaki M. Cervical neurofibroma in a patient with von Recklinghausen's disease. *Auris Nasus Larynx* 1994;21(4):253–257
- 52 Fujino K, Shinohara K, Aoki M, Hashimoto K, Omori K. Intracapsular enucleation of vagus nerve-originated tumors for preservation of neural function. *Otolaryngol Head Neck Surg* 2000;123(3):334–336
- 53 Ilgner J, Rojas W, Biesterfeld S, Schürmann K, Zimny M, Westhofen M. Low-grade malignant peripheral nerve sheath tumor of the neck soft tissues [in German]. *Laryngorhinootologie* 2001;80(1):39–42
- 54 Ozcan M, Tuncel U, Unal A, Erdogan A, Han O, Nalca Y. Concomitant vagal neurofibroma and aplasia of the internal carotid artery in neurofibromatosis type 1. *Ear Nose Throat J* 2001;80(10):730–732, 734, 737
- 55 Kuzu Y, Beppu T, Sibanai K, Ogasawara K, Ogawa A, Kurose A. A case of malignant peripheral nerve sheath tumor originating from the cervical vagus nerve [in Japanese]. *No Shinkei Geka* 2002;30(5):523–526
- 56 Cihangiroglu M, Yilmaz S, Topsakal C, Gok U, Altinsoy B, Cobanoglu B. Laryngeal neurofibroma associated with neurofibromatosis type 2. *AJNR Am J Neuroradiol* 2002;23(10):1637–1639
- 57 Molina AR, Brasch H, Tan ST. Malignant peripheral nerve sheath tumour of the cervical vagus nerve in a neurofibromatosis type 1 patient. *J Plast Reconstr Aesthet Surg* 2006;59(12):1458–1462
- 58 Matejcek V, Steno J, Haviarova Z, Mravec B. Neurofibroma of the vagus nerve in the cervical portion. *Bratisl Lek Listy (Tlacene Vyd)* 2008;109(10):455–458
- 59 Guler AK, Gunaldi O, Alis H, Tugcu B, Tanriverdi O, Colluoglu B. Cervical segment nervus vagus neurofibroma with associated neurofibromatosis type 1: a case report. *Minim Invasive Neurosurg* 2009;52(5–6):246–249
- 60 Sesenna E, Magri AS, Corradi D, Ferri T, Ferri A. Malignant peripheral nerve sheath tumor of the vagus nerve in a teenager with the neurofibromatosis 1 gene mutation: a case report. *J Pediatr Surg* 2011;46(8):e9–e12
- 61 Yazar O, Topal H, Streukens S. A painless neck swelling and von Recklinghausen. *Acta Chir Belg* 2014;114(1):84–86