

Disorders of Consciousness: Practical Management in an Emergency Room

Distúrbios da consciência: Abordagem prática na sala de emergência

Daniel Damiani¹ 

¹ Department of Neuroscience, Universidade Anhembi Morumbi, São Paulo, SP, Brazil

Address for correspondence Daniel Damiani, MD, Department of Neuroscience, Universidade Anhembi Morumbi, Sao Paulo, SP 04705-000, Brazil (e-mail: damiani.neuroscience@gmail.com).

Arq Bras Neurocir 2019;38:263–271.

Abstract

Keywords

- ▶ coma
- ▶ coma in emergency room
- ▶ reversible causes of coma
- ▶ ascending reticular activating system
- ▶ consciousness and coma
- ▶ brainstem

Lowering of the level of consciousness is a very common presentation at the emergency room, often without any history that helps finding an etiology. This emergency requires quick empirical measures to reduce neuronal mortality, with additional protection against sequelae. According to the Advanced Cardiac Life Support (ACLS) guidelines, there are current emergency neurological support protocols, such as the Emergency Neurological Life Support (ENLS) created by the Neurocritical Care Society. The present paper shows how to approach unconscious patients, highlighting possible etiologies and proposed treatments.

Resumo

Palavras-chave

- ▶ coma
- ▶ coma na sala de emergência
- ▶ causas reversíveis de coma
- ▶ sistema reticular ativador ascendente
- ▶ consciência e coma
- ▶ tronco encefálico

O rebaixamento do nível de consciência é uma situação frequente na sala de emergência, muitas vezes sem qualquer história prévia que auxilie no esclarecimento etiológico. Trata-se de uma situação de emergência que exige medidas empíricas imediatas no intuito de reduzir a mortalidade neuronal com proteção adicional à zona de penumbra. A exemplo do preconizado pelo Suporte Avançado da Vida Cardiovascular (SAVC), atualmente estão disponíveis os protocolos de suporte neurológico de emergência (ENLS, na sigla em inglês) preconizados pela Neurocritical Care Society. O presente artigo apresenta os princípios gerais no manejo inicial do paciente com rebaixamento do nível de consciência, destacando as suas possíveis etiologias e seus tratamentos propostos.

Introduction

Coma is an unconsciousness state defined by the inability to respond to external stimuli, in which the patient remains unaware, ignorant of the self and of other people. Didactically,

consciousness has two components: the level and the content of consciousness. The level of consciousness (also referred as arousal) reflects the most primordial central nervous system (CNS) structures belonging to the reptilian brain from the MacLean model, represented by the brainstem and by the

received
June 8, 2016
accepted
July 27, 2016

DOI <https://doi.org/10.1055/s-0036-1594251>.
ISSN 0103-5355.

Copyright © 2020 by Thieme Revinter Publicações Ltda, Rio de Janeiro, Brazil

License terms



diencephalic structures (the thalamus and the hypothalamus), collectively referred to as the ascending reticular activating system (ARAS). The content of consciousness concerns higher cortical functions, such as gnosis, praxis, memory, learning, reasoning, and orientation in time and space, and it is represented by the neocortex. Therefore, coma represents the involvement of the brainstem and/or of any diencephalic structure, which are primordial for maintaining arousal.¹⁻³ Variations of the classic coma are described and collectively referred to as disorders of consciousness: minimally conscious state, vegetative state, hypersomnia, abulia, and akinetic mutism. The minimally conscious state is characterized by content impairment and unconsciousness, with some preservation of awareness of the self and of the environment. The vegetative state occurs when the comatose patient presents sleep-wake cycles, with autonomic control (including respiratory drive), and spontaneous ocular opening, but deep unconsciousness of the self and of the environment. These two situations refer to bilateral cortical lesions or to extensive lesions affecting the cortical connectivity. Hypersomnia consists in excessive sleepiness or fatigue during the day, and is primarily idiopathic or results from structural or metabolic changes. Abulia is a decrease in initiative along with apathy; it can occur after frontal lobe damage, and it may evolve with akinetic mutism.⁴⁻⁸ In the clinical practice, many patients arrive at the emergency room with a lower level of consciousness: the patient may be disoriented, sleepy, obtunded (sleepy and disoriented), apathic, or already comatose. Since there are many possible causes for this clinical picture, the clinical history and a proper physical examination are fundamental to establish an etiological diagnosis. The physician should be aware of possible acute causes that require emergency procedures to reduce their morbidity and mortality.¹ Huff et al recommend an algorithm for the management of comatose patients in the emergency room based on the conventional algorithms Advanced Cardiac Life Support (ACLS) and Advanced Trauma Life Support (ATLS), called Emergency Neurological Life Support (ENLS). This algorithm, like the traditional ATLS and ACLS protocols, guides emergency professionals and intensivists on the critical measures to be adopted as priorities for the treatment of patients with acute neurological injury.^{2,9}

Objectives

The author describes the current knowledge on the physiology of the level and content of consciousness, as well as the pathophysiology of unconsciousness, including coma, highlighting its major etiological factors, both acute and reversible at the first emergency room visit, following an emergency approach protocol to acute neurological injuries.

Methodology

A quantitative and descriptive research was performed per a narrative literature review in the Latin American and Caribbean Literature in Health Sciences (LILACS) and in the National Library of Medicine (PubMed) databases in May, 2016, using the following descriptors: *coma*, *emergency*

room, *intensive care*, *consciousness*, *brainstem*, and *ascending reticular system*. The following combinations were used in the search: *coma in emergency room*, *reversible causes of coma*, *consciousness and coma*, and *ascending reticular system and brainstem*.

The present study asks the following question: how to correctly manage the patient in a coma at the emergency room?

The inclusion criteria for papers were updated publications from the period between 2001 and 2016, with rare exceptions, in Portuguese and English, and with online access to the full text. As exclusion criteria, in addition to papers that did not comply with the inclusion criteria, duplicate papers were eliminated.

For the analysis of the papers included in the present review, the following aspects were observed: year of publication, journal, place of study, methodology used, and main results.

Development

Pathophysiology of the lowering of the level of consciousness. Consciousness is a complex of neuronal interconnections involving cortical, subcortical, and deep nuclei areas, influenced by inhibitory and excitatory neurotransmitters. The ARAS, located in the brainstem, is responsible for the maintenance of the level of consciousness, and it consists of several nuclei in the brainstem, in the thalamus, and in the hypothalamus. The content of consciousness is represented by the cerebral cortex, as already mentioned. Moruzzi et al, in 1949, were the first to describe the ARAS, using experimental brainstem transections in cats. After midbrain lesions, the animals were unable to maintain their level of consciousness, becoming comatose (→ Fig. 1).¹⁰

Brainstem. The structures related to the maintenance of the level of consciousness are the raphe nuclei, the locus coeruleus, the reticular formation, the pars compacta of the substantia nigra, the ventral tegmental area, and the mesopontine tegmentum, which includes the tegmental pedunculo-pontine nucleus and the laterodorsal tegmental nucleus. The dendrites of these neurons form true integrative networks between the afferent and efferent synaptic outflow. Unsynchronized discharges to the cerebral cortex, alternating low and high amplitudes, are responsible for maintaining the level of consciousness with the possible expression of its content. Physiologically, when the structures of the brainstem, of the hypothalamus, and of the thalamus synchronize their electrical discharges to the cortex, with slow waves of higher amplitude, the level of consciousness is reduced.^{11,12} The cholinergic system acts at the entire cerebral cortex both during wakefulness and rapid eye movement (REM) sleep. These neurons stimulate directly the cerebral cortex and inhibit the reticular nucleus of the thalamus (responsible for slow-wave sleep induction), leading to a desynchronization of the cortical waves. Cholinergic activity, in turn, promotes cortical activation by stimulating glutamatergic, noradrenergic, serotonergic, and histaminergic neurons present in the ARAS structures. Gamma-aminobutyric acid (GABA)ergic neurons also

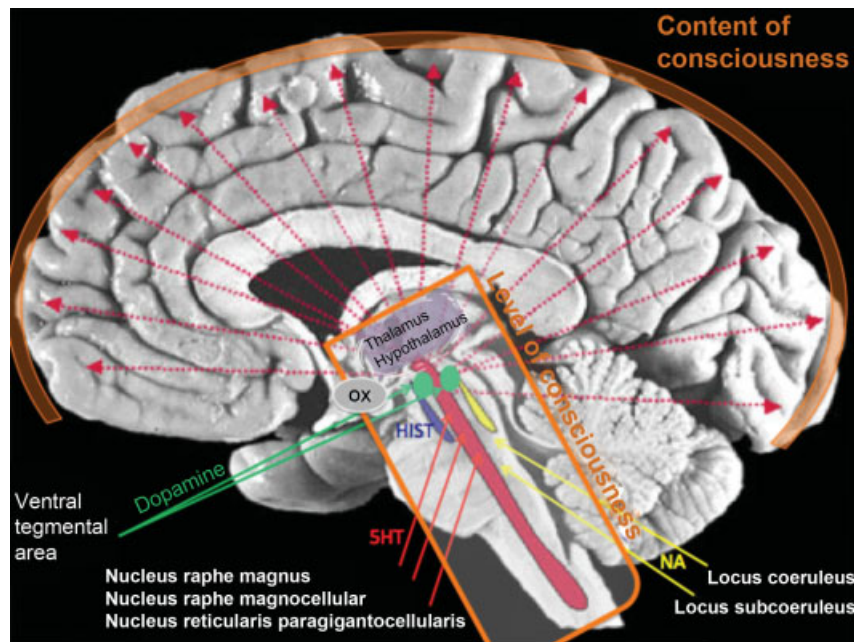


Fig. 1 Structures responsible for the content and level of consciousness. The content of consciousness requires the functioning of the cerebral cortex, which cannot generate the level of consciousness. The latter depends on subcortical structures, such as the hypothalamus and the thalamus, as well as the brainstem. Abbreviations: 5HT, 5-hydroxytryptamine (serotonin); HIST, histamine (arising from the tuberomammillary nucleus); NA, norepinephrine; OX, orexin (present in the hypothalamic periventricular nucleus).

project themselves together with cholinergic fibers through thalamic irradiation, promoting ascending disinhibition and neuronal activation. Lesions in the ventral tegmental areas and in the substantia nigra present with akinesia with no impairment of the cortical activation.¹¹

Posterior Hypothalamus. This heterogeneous region, composed of histaminergic, dopaminergic, glutamatergic, and GABAergic neurons, is associated with neuropeptides such as orexin, enkephalin and substance P, and it has a great influence on the wakefulness process. During the influenza epidemic in 1918, Von Economo¹¹ described lesions in the posterior and in the anterior hypothalamus, respectively, associated with hypersomnia (including drowsiness and coma), and insomnia. Recently, a hypothalamic-cortical projection system, deemed responsible for maintaining the level of consciousness, has been described. Histamine and the neuropeptide orexin have great relevance in this arousal-activating mechanism. Histamine acts on its H1 receptor, activating the Gq/11 protein, causing depolarization with sodium and calcium influx; on its H2 receptor, β -adrenergic receptor and 5HT₂, it activates Gs protein (adenylate cyclase-coupled), increasing the expression of the cAMP response element binding protein (CREB) transcription factor; and on its H3 receptor (a self-receptor coupled to a Gq protein and to high-voltage calcium channels), it is responsible for the negative feedback to the production and release of histamine itself (**Fig. 1**). The excitatory neurotransmitter for orexinergic neurons is glutamate, and their inhibitory neurotransmitter is dynorphin.¹¹⁻¹⁴

Some CNS lesions may compromise the structures responsible for the maintenance of arousal, such as traumatic brain

injury (TBI), intracranial hemorrhage (ICH), subarachnoid hemorrhage (SAH), ischemic stroke, and global hypoxic-ischemic brain injury. In ICH, arousal is often preserved at the beginning of the clinical picture; however, as the hematoma expands, the level of consciousness is impaired. If the origin of the ICH affects the infratentorial space, the risk of impaired consciousness is higher, due to anatomical reasons. In the supratentorial space, the bleeding affecting the medial thalamic nuclei often results in unconsciousness. Lobar lesions that deviate the midline will compromise the level of consciousness by compression of thalamic nuclei, of the brainstem, and/or of thalamic projection structures. In SAH, either traumatic or spontaneous, the intracranial pressure increases abruptly, whereas the cerebral perfusion pressure is reflexively reduced, resulting in swelling, transient ischemia, and cytotoxic edema. Subarachnoid hemorrhage can indirectly damage the hypothalamus. Indirect hypothalamic lesions (due to increased intracranial pressure and/or to vascular lesions) reduce orexin (hypocretin) levels, resulting in unconsciousness. It is not uncommon for SAH survivors to present changes in the wake-sleep cycle, including excessive daytime fatigue. In ischemic stroke, unconsciousness is not common, except in cases involving correlated structures. The decreased level of consciousness results from cerebral edema with midline deviation due to already mentioned factors. A malignant infarction of the middle cerebral artery classically presents with a major cerebral edema; decompressive craniectomy is commonly indicated, reducing its mortality by up to 50%.¹ Lastly, the global hypoxic-ischemic brain injury is due to brain hypoperfusion, often following prolonged cardiorespiratory arrest. Neuronal damage starts within 2 minutes of cerebral blood hypoperfusion. Some structures

are more sensitive to hypoxia: the hippocampus (CA1 and CA4 regions); pyramidal cells from layers 3, 5 and 6; the amygdaloid complex; the cerebellar worm; the caudate nucleus; and the brainstem nuclei. The reticular nucleus, the intralaminar nuclei of the thalamus, and the medial geniculate nucleus are particularly sensitive to ischemia. The return of the spontaneous circulation causes reperfusion injury. Several components of the anaerobic metabolism may damage neurons, including free radicals, extracellular glutamate causing excitotoxicity by calcium influx, changes in glial morphology, and astrocytic activation by increased levels of proinflammatory interleukins and tissue necrosis factor α .^{4,15,16}

Reversible causes of lowered level of consciousness.

There are innumerable possible causes of lowered level of consciousness, and some of them can be immediately reversed with emergency intervention. As already mentioned, the three major mechanisms responsible for disorders of the level of consciousness are: structural brain lesions, diffuse neuronal dysfunctions (resulting from various metabolic conditions that may compromise neuronal function), and, rarely, psychiatric causes. Except for the latter, the other mechanisms will somehow involve the ARAS and its connections, the diencephalic structures (the hypothalamus and/or the thalamus) and/or the cerebral cortex (► **Table 1**). After immediate clinical stabilization, which will be described later, the emergency physician or intensivist should consider the reversible causes of coma and actively try, even if initially empirically, to reduce the neurological damage.

Clinical management in the emergency room. The proposed creation of an algorithm for the management of the critical neurological patient in the emergency room follows the model of the traditional algorithms of the American Heart Association, namely ATLS and ACLS. It is a sequence of emergency measures for rapid diagnosis and prompt therapy, minimizing secondary neurological lesions. The 1st 60 minutes are critical for the neurological patient, and there are rare times when a neurologist and/or neurosurgeon are available in the emergency department within that time frame. In this context, the Neurocritical Care Society develops algorithms for the care of critical neurological patients.¹⁷

The neurological examination is the 1st step in evaluating patient with a lowered level of consciousness in the emergency room. The Glasgow coma scale was described in 1974, and it has been widely used in these situations.¹⁸ In 2005, however, a scale called Full Outline of UnResponsiveness (FOUR) was published to better evaluate intubated patients, and it includes an evaluation of brainstem reflexes, not considered by the Glasgow scale (► **Fig. 2**). The examination of the motor and ocular functions indicates the neurological prognosis; the ocular examination seems to have a better predictive value compared with the motor examination. The absence of pupillary reflexes following cardiorespiratory arrest, for example, represents a very poor prognosis. Oculovestibular and oculocephalic reflexes also have prognostic values. The electroencephalogram (EEG) value was also

studied and associated with the prognosis for neurological damage: the presence of periodic and/or generalized epileptiform discharges, generalized suppression patterns, lack of activity, or even the presence of alpha and theta waves in coma represent a worse prognosis. Somatosensory evoked potentials (SSEP) with identification of cortical N20 response after median nerve stimulation were studied: the absence of the N20 response represents a higher mortality, while a slow N20 response is associated with a persistent vegetative state and brain death. It is, therefore, a good predictor of coma prognosis; however, there are some disadvantages, including the need for specialized professionals to perform and interpret the test; electrical interference; and the required exclusion of subcortical, medullary and/or peripheral lesions that may affect cortical response. Biomarkers of neural glial lesions are now available, including a neuron-specific enolase and S100B protein. In diffuse axonal lesions, the elevated levels of these markers in 72 hours are predictors of a worse prognosis.

Proposed Algorithm for Comatose Patient Approach: Emergency Neurological Life Support

In emergency medicine, the patient is classified as comatose when he presents closed eyes, preserved reflexes, and reduced or absent response to external stimuli (► **Fig. 3**). The level of responsiveness, as well as its response pattern, is assessed by the examiner and graded by the Glasgow coma scale and by the FOUR scale.¹⁹ Verbal and tactile-painful stimuli are performed to elicit the response of the patient. The attempt to open the eyelids of the patient is a simple and effective test; the arm drop test on the face is often used. The recommended protocol for these patients includes the initial stages of ACLS and ATLS resuscitation (cervical stability, airway viability), the assessment of respiratory rate, oxygen saturation, heart rate, and blood pressure, the establishment of one or two large-bore venous access to immediately draw blood samples for serum biochemistry analysis, blood sugar level, toxicology (including alcohol), coagulation profile, electrolytes (mainly sodium and calcium), arterial blood gases, urine and cultures.¹ If an orotracheal intubation (OT) is required, it should be performed with adequate analgesia, sedation, and neuromuscular paralysis (when indicated). There are four classic indications for OT in neurological lesions: (1) respiratory failure confirmed by oximetry (with caution regarding methodological limitations), arterial blood gas analysis and/or cyanosis; (2) inability to ensure a safe airway (absence of protective reflexes); (3) severe clinical injury with cardiopulmonary function compromise; (4) failure of noninvasive methods, such as catheters, masks, and noninvasive ventilation (NIV). Ideally, a rapid and objective neurological examination should be performed prior to the administration of sedative, hypnotic, and/or neuromuscular paralytic agents. The level and content of consciousness, the function of the cranial nerves, motor limb activity, deep osteotendinous tonus and reflexes, convulsive activity, cervical stability, and sensory level

Table 1 Some brain lesions caused by mass effect and classified as structural versus diffuse neuronal lesions

Structural brain injury	Usual treatment	Comments
Brain tumor, mass effect	Neurosurgery and corticosteroids	Intracranial pressure reduction
Status epilepticus	Anticonvulsive drugs	Sedation and induced coma may be required
Central nervous system infections, sepsis	Antibiotics, steroids and abscesses drainage	Immediate empirical treatment
Intracranial hypertension	Elevate head bed, hyperosmolar solution, hyperventilation, corticoids	Intracranial pressure monitoring should be considered
Subdural and extradural hematoma	Neurosurgical drainage	Multimodal monitoring
Intracranial hemorrhage	Neurosurgical hemostatic therapy, drainage, blood pressure control	Clinical and vascular research: angiography
Ischemic stroke	Thrombolytic therapy	Clinical and vascular research
Hydrocephalus	Ventriculostomy with drainage	Acetazolamide: inhibitor of cerebrospinal fluid production
Brain edema	Decompressive craniectomy	On a per case basis
Cerebral venous thrombosis	Anticoagulants	Etiologic search: contraceptive use, Leiden factor V mutation, prothrombin gene mutation, immune and rheumatologic markers
Diffuse neuronal lesions	Usual treatment	Comments
Hypoglycemia	Hypertonic glucose 50%, intravenously	Clinical emergency!
Hyperglycemia, DKA, HHS	Hydration and insulin therapy	Search for precipitating factor
Hyponatremia	Sodium replacement: always with 3% NaCl: 3 mEq/3 h + 9 mEq/21 h	Investigate other electrolytes
Hypercalcemia	Hydration, furosemide, intravenous bisphosphonates, calcitonin, dialysis	Investigate precipitating causes: PTH, paraneoplastic syndrome, lymphoma
Renal failure	Dialysis	Investigate cause
Hyperammonemia	According to etiology	Hepatic failure: high lactate level, hypoglycemia, coagulopathy
Hepatic failure, hepatic encephalopathy	Lactulose, mannitol, vitamin K or FFP, prophylactic antibiotic therapy, flumazenil	Head CT: cerebral edema; protein restriction: 1.0-1.5 g/kg/day via NET
Thyrotoxicosis	Beta-blockers, PTU, inorganic iodine, dexamethasone	Etiological investigation
Myxedema coma	Hormonal replacement: levothyroxine + hydrocortisone	Perform associated hydric and electrolyte corrections and correct hypothermia
Hypocortisolism (Addisonian crisis)	Hydration + steroid therapy	
Wernicke encephalopathy	Thiamin (vitamin B1)	Associated with thiamine-free glucose replacement in alcoholism
Serotonergic syndrome	Benzodiazepines	Consider neuromuscular paralysis
Cholinergic poisoning	Atropine, pralidoxime	Poisons, organophosphates, carbamates
Opioids	Naloxone	Caused by morphine, heroin, phenylethyl, tramadol
Benzodiazepines	Flumazenil	Suicide attempts with diazepam, lorazepam, alprazolam

Abbreviations: DKA, diabetic ketoacidosis; HHS, hyperosmolar hyperglycemic state; FFC, fresh frozen plasma; PTH, parathyroid hormone; PTU, propylthiouracil; NET, nasoenteral tube.









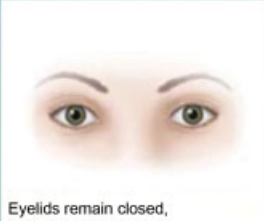



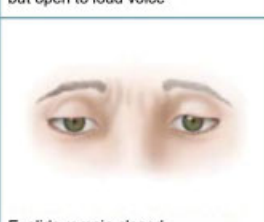
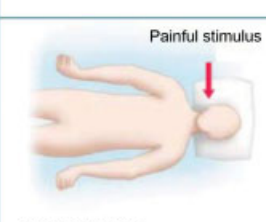



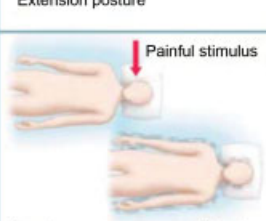

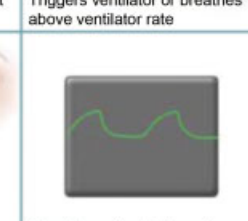
	Eye response (E)	Motor response (M)	Brainstem reflexes (B)	Respiration (R)
4	 Eyelids open or remain opened; eyes track movement; blinking to command	 Thumbs up, fist or peace sign to command	 Pupillary and corneal reflexes present	 With no intubation, regular breathing pattern
3	 Eyelids open, but eyes do not track movement	 Painful stimulus Pain localization	 One pupil is fixed and dilated	 With no intubation, Cheyne-Stokes breathing pattern
2	 Eyelids remain closed, but open to loud voice	 Stimulus Flexion response to pain	 Pupillary or corneal reflexes absent	 With no intubation, irregular breathing pattern
1	 Eyelids remain closed, but open to pain	 Painful stimulus Extension posture	 Pupillary and corneal reflexes absent	 Triggers ventilator or breathes above ventilator rate
0	 Eyelids remain closed at pain	 Painful stimulus No pain response or generalized myoclonic epilepticus status	 Absent pupillary, corneal or cough reflexes	 Breathing at ventilator rate or apnea

Fig. 2 FOUR (Full Outline of UnResponsiveness) coma scale.

should be evaluated in cases with suspicion of spinal cord injury. The rapid intubation sequence is the method of choice for cases with suspicion of intracranial hypertension, reducing the risk of its reflexive increase (mediated by the autonomic sympathetic nervous system) during laryngoscopy. The presence of coma is not an indication for the nonuse of hypnotic and analgesic agents. Even a comatose patient may present laryngoscopy reflexes that increase the intracranial pressure due to a higher neuroendocrine and immunological response. The mean arterial blood pressure (MAP) and the intracranial pressure (ICP) should be carefully controlled to maintain the cerebral perfusion pressure (CPP) ~ between 60 and 70 mm Hg.^{20,21}

Three preintubation medications can prevent the increase of the ICP: lidocaine (1.5 mg/kg intravenously [IV], adminis-

tered 1 minute before OT); fentanyl (2-3 µg/kg IV, administered 30 seconds to 1 minute prior to OT), but it must be avoided in hypotensive patients; and esmolol (1-2 mg/kg IV, 3 minutes before OT), which acts as a short-term β-blocker for heart rate and blood pressure control during OT, but which it is rarely used due to coexistent hypotension. The hypnotic agents recommended due to their little interference with ICP are etomidate (0.2-0.4 mg/kg IV), which promotes sedation and neuromuscular relaxation without hemodynamic damage (this is the hypnotic of choice in cases with increased ICP); propofol (0.5-3.0 mg/kg IV), despite its potent vasodilator effect; and thiopental (3 mg/kg IV), which is considered a brain protective agent for reducing the basal cerebral metabolic rate and the fraction of oxygen extraction by brain tissue, diminishing the ICP (however, it has a

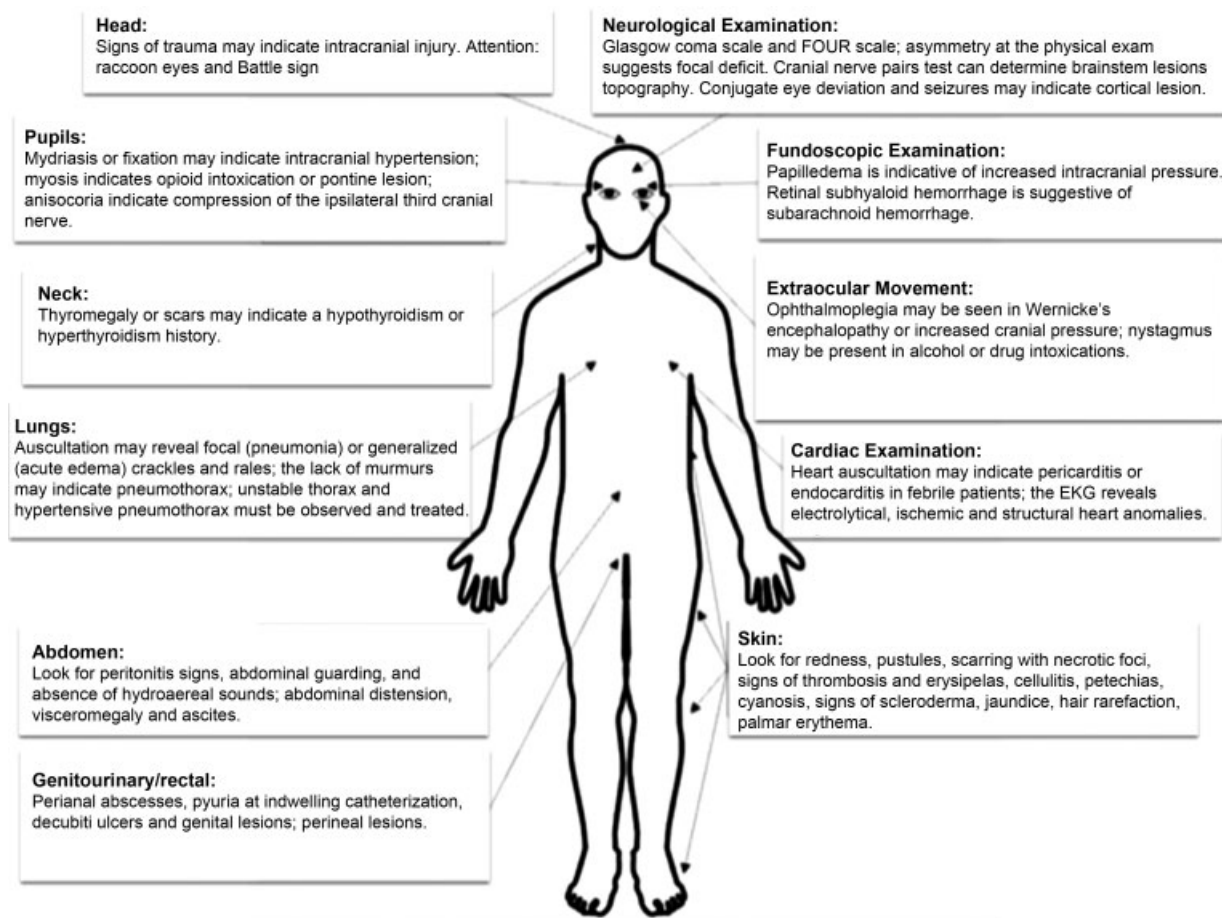


Fig. 3 Physical examination of the comatose patient in the emergency room. Modified from Han et al.²⁷

negative inotropic effect and is a venous dilator with major hypotensive potential). Ketamine (0.5-2.0 mg/kg IV) is also a good option in cases with increased ICP with little influence over the hemodynamic pattern. Succinylcholine (1.0-1.5 mg/kg IV) is the depolarizing neuromuscular blocking agent of choice in patients with elevated ICP. Even though there are reports of slight ICP increases, the very short half-life of succinylcholine does not appear to impair nerve cells. However, studies have shown that patients with brain injuries, spinal cord injuries, major atrophies, and prolonged immobility are more susceptible to succinylcholine-induced hyperkalemia. In such high-risk patients, the use of non-depolarizing neuromuscular blockers, such as rocuronium (0.5-0.6 mg/kg IV), and vecuronium (0.2 mg/kg IV), seems to be a good alternative.²²⁻²⁶

Immediately after the bedside determination of the capillary blood sugar level, if it is < 70 mg/dL, 40 mL of hypertonic glucose at 50% should be infused intravenously. If there is suspicion of alcohol intoxication or a history of use, malnutrition or a history of bariatric surgery, the emergency physician should administer 100 mg of thiamine IV. The suspicion of opioid intoxication should be based on unconsciousness with bilateral miotic pupils, and the empirical IV administration of 0.4-2.0 mg naloxone (with a maximum dose of 4 mg) is indicated. The "coma kit", including naloxone, atropine, flumazenil and thiamine, is not indicated

without the proper assessment of the patient for clinical signs warranting its use. The electrocardiogram (EKG), performed on arrival, can provide indications about the cause of unconsciousness: electrolytic changes, ischemia, arrhythmias, and structural heart diseases can be diagnosed at this first ECG. At the neurological examination, asymmetry findings strongly suggest focal lesions, while symmetry suggests lesions due to metabolic causes. The neurological evaluation of the patient in coma should follow four steps: (1) level of consciousness (Glasgow coma scale and FOUR scale); (2) brainstem reflexes (oculocephalic and oculovertibular maneuvers, cranial pairs test with pupil evaluation); (3) motor assessment (spontaneous, reflexive, or induced by painful stimuli); (4) evaluation of the respiratory pattern, which is important to determine the topography of the lesion (a Cheyne-Stokes pattern suggests supratentorial lesions; neurogenic hyperventilation suggests mesencephalic lesions; apneustic pattern suggests pons lesions; ataxic breathing suggests medulla oblongata lesions).²⁷

A brief clinical history may be obtained from family members, from bystanders, or from the prehospital care team. Some history features are strongly suggestive of the coma etiology: sudden onset (suggesting a vascular etiology, seizure, or drug overdose); tumor history (suggesting metastasis); hemorrhagic disorders (suggesting ICH, subdural hematoma, SAH); hypercoagulability states (suggesting dural sinus thrombosis);

assisted seizures and gradual worsening to coma (suggesting tumoral or inflammatory diseases).²⁷

At that time, neuroimaging is a fundamental part of the assessment: structural lesions are potentially treated with an early neurosurgical approach and should be diagnosed as soon as possible. A computed tomography (CT) scan of the skull without contrast medium is the test of choice due to of its great availability, low cost, and fast execution; however, it requires hemodynamic stability. Focal hypodensities suggestive of stroke, ICH, SAH, brain edemas, herniations, and acute hydrocephalus are readily diagnosed. In the infectious hypotheses, CT scans with and without contrast medium can be useful in the exclusion of cerebral abscess, of extra-axial collections, of hemorrhagic transformations, and of hydrocephalus, even before lumbar puncture. Comas due to non-structural lesions include hypoxicischemic encephalopathy, sepsis, epilepsies, metabolic alterations, endocrinopathies, toxins, and drugs. More specific lesions – including white matter involvement, neoplasms, posterior fossa and brainstem lesions – are better investigated by more accurate methods, such as magnetic resonance imaging (MRI) of the brain, magnetic resonance angiography, and digital angiography. In the hyperacute phases of the ischemic stroke, a

brain MRI with diffusion will be diagnostic, since the skull CT will not show lesions.^{1,2}

In undetermined cases, a lumbar puncture may aid the diagnosis. Infections, inflammation, neoplasms, demyelinations, and autoimmune diseases can be diagnosed by a cerebrospinal fluid (CSF) analysis. If a status epilepticus is suspected, an EEG should be requested² (– Fig. 4).

Some neuroprotective therapies are advocated in cases of lowered level of consciousness. With the current knowledge about neuroanatomic structures corresponding to the level and content of consciousness, the patient in coma, in vegetative state, and in minimally conscious state may benefit from some clinical measures. Therapeutic hypothermia has been used in the last 10 years in patients who have undergone cardiopulmonary arrest and, to date, is the only truly effective neuroprotective measure. Hypothermia is known to reduce the inflammatory process, decreasing the production of reactive oxygen species, excitotoxicity, apoptosis, and neuronal death. Amantadine inhibits N-methyl-D-aspartate (NMDA) channels, preventing calcium influx. In addition, amantadine is a dopaminergic agonist in the cortical regions related to attention and arousal, showing benefits in the recovery of patients who evolved to a permanent vegetative or minimally

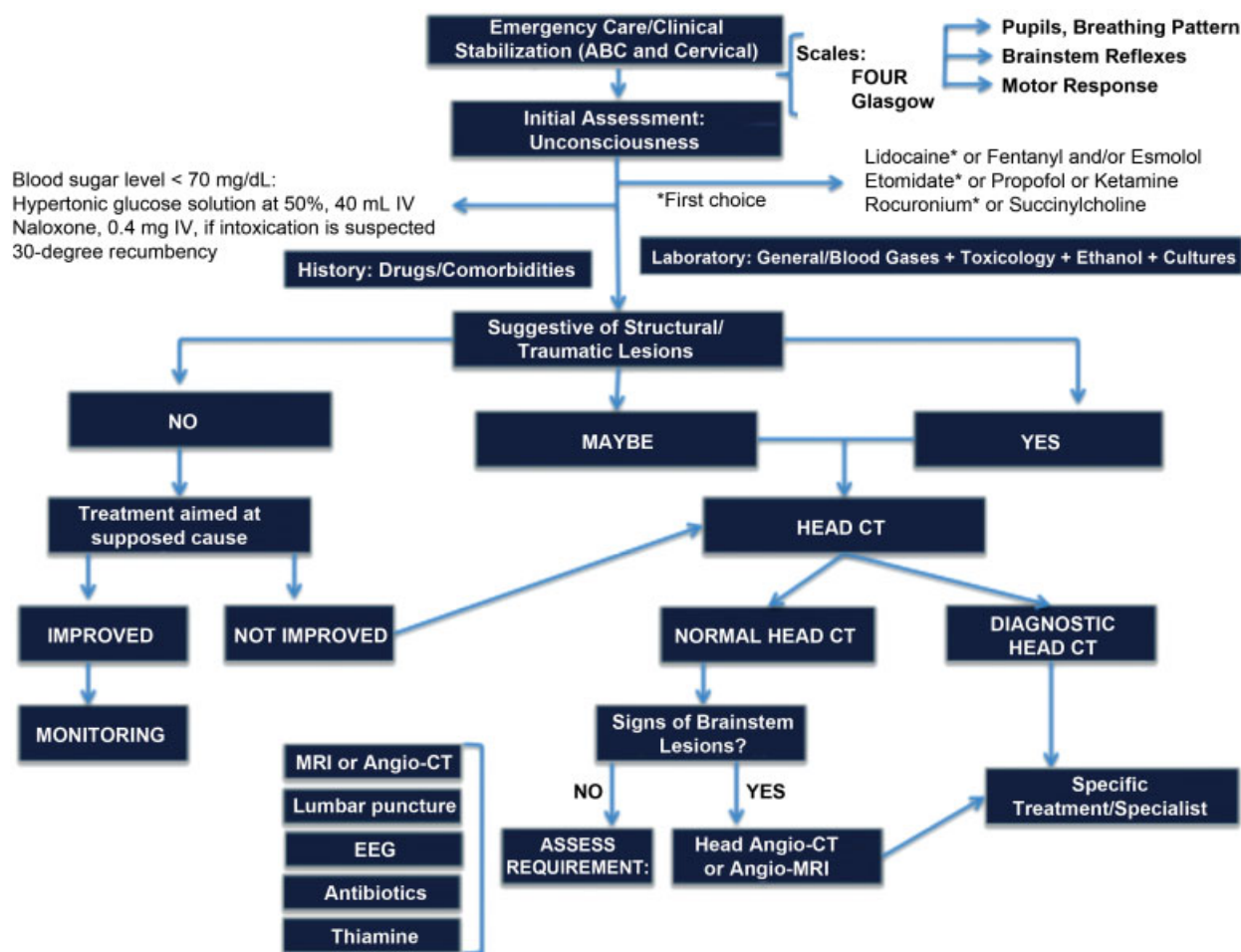


Fig. 4 Algorithm recommended for the initial care of the unconscious patient. Abbreviations: Angio-CT, angiography by computed tomography; EEG, electroencephalogram; MRI, magnetic resonance imaging. Source: adapted from Edlow et al and from Huff et al.^{1,2} Source: Adapted from Han et al.²⁷

conscious state. Methylphenidate, an amphetamine, is a noradrenergic and dopaminergic stimulant, acting on the prefrontal cortex. Some studies show that the administration of methylphenidate to patients with severe TBI reduces the length of stay in the intensive care unit (ICU) and the hospitalization period. Modafinil (an orexin agonist), zolpidem (a GABAergic agonist) and baclofen (a GABAergic agonist) resulted in improvement of some persistent vegetative states; however, no randomized, multicenter, prospective, double-blind study has been conducted to date, and only empirical measurements based on the individual observation of some centers are available.^{4,28}

Conclusions

Lowering of the level of consciousness (coma status and its variants) is one of the main causes of emergency room admission. Its diverse etiological possibilities associated to the absence of clinical history, very common in this scenario, are a challenge to the emergency physician. However, initial measures should be promptly instituted according to an established protocol, based on ATLS and ACLS. Some steps recommended by the ENLS, in order to not aggravate a potentially reversible lesion, may increase the time for an investigative work on a clearer etiological definition.

Conflicts of Interests

The author has no conflicts of interests to declare.

References

- Edlow JA, Rabinstein A, Traub SJ, Wijdicks EFM. Diagnosis of reversible causes of coma. *Lancet* 2014;384(9959):2064–2076
- Huff JS, Stevens RD, Weingart SD, Smith WS. Emergency neurological life support: approach to the patient with coma. *Neurocrit Care* 2012;17(Suppl 1):S54–S59
- Plum F, Posner JB. Brain death. In: Plum F, Posner JB. *Diagnosis of stupor and coma*. 3rd ed. Philadelphia: Davis; 1984:313–328
- McClenathan BM, Thakor NV, Hoesch RE. Pathophysiology of acute coma and disorders of consciousness: considerations for diagnosis and management. *Semin Neurol* 2013;33(02):91–109
- Monti MM, Laureys S, Owen AM. The vegetative state. *BMJ* 2010;341:c3765
- Laureys S, Celesia GG, Cohadon F, et al; European Task Force on Disorders of Consciousness. Unresponsive wakefulness syndrome: a new name for the vegetative state or apallic syndrome. *BMC Med* 2010;8:68
- Laureys S, Owen AM, Schiff ND. Brain function in coma, vegetative state, and related disorders. *Lancet Neurol* 2004;3(09):537–546
- Dauvilliers Y, Buguet A. Hypersomnia. *Dialogues Clin Neurosci* 2005;7(04):347–356
- Stevens RD, Bhardwaj A. Approach to the comatose patient. *Crit Care Med* 2006;34(01):31–41
- Moruzzi G, Magoun HW. Brain stem reticular formation and activation of the EEG. *Electroencephalogr Clin Neurophysiol* 1949;1(04):455–473
- Lin JS, Anaclet C, Sergeeva OA, Haas HL. The waking brain: an update. *Cell Mol Life Sci* 2011;68(15):2499–2512
- Yeo SS, Chang PH, Jang SH. The ascending reticular activating system from pontine reticular formation to the thalamus in the human brain. *Front Hum Neurosci* 2013;7(07):416
- Kukkonen JP, Holmqvist T, Ammoun S, Akerman KEO. Functions of the orexinergic/hypocretinergic system. *Am J Physiol Cell Physiol* 2002;283(06):C1567–C1591
- Sakurai T. The neural circuit of orexin (hypocretin): maintaining sleep and wakefulness. *Nat Rev Neurosci* 2007;8(03):171–181
- Parvizi J, Damasio AR. Neuroanatomical correlates of brainstem coma. *Brain* 2003;126(Pt 7):1524–1536
- Fuller PM, Sherman D, Pedersen NP, Saper CB, Lu J. Reassessment of the structural basis of the ascending arousal system. *J Comp Neurol* 2011;519(05):933–956
- Smith WS, Weingart S. Emergency Neurological Life Support (ENLS): what to do in the first hour of a neurological emergency. *Neurocrit Care* 2012;17(Suppl 1):S1–S3
- Teasdale G, Jennett B. Assessment of coma and impaired consciousness. A practical scale. *Lancet* 1974;2(7872):81–84
- Wijdicks EFM, Bamlet WR, Maramattom BV, Manno EM, McClelland RL. Validation of a new coma scale: The FOUR score. *Ann Neurol* 2005;58(04):585–593
- Davis DP, Idris AH, Sise MJ, et al. Early ventilation and outcome in patients with moderate to severe traumatic brain injury. *Crit Care Med* 2006;34(04):1202–1208
- Reynolds SF, Heffner J. Airway management of the critically ill patient: rapid-sequence intubation. *Chest* 2005;127(04):1397–1412
- Seder DB, Riker RR, Jagoda A, Smith WS, Weingart SD. Emergency neurological life support: airway, ventilation, and sedation. *Neurocrit Care* 2012;17(Suppl 1):S4–S20
- Dumont TM, Visionsi AJ, Rughani AI, Tranmer BI, Crookes B. Inappropriate prehospital ventilation in severe traumatic brain injury increases in-hospital mortality. *J Neurotrauma* 2010;27(07):1233–1241
- Davis DP, Stern J, Sise MJ, Hoyt DB. A follow-up analysis of factors associated with head-injury mortality after paramedic rapid sequence intubation. *J Trauma* 2005;59(02):486–490
- Walsh BK, Crotwell DN, Restrepo RD. Capnography/Capnometry during mechanical ventilation: 2011. *Respir Care* 2011;56(04):503–509
- Bergen JM, Smith DC. A review of etomidate for rapid sequence intubation in the emergency department. *J Emerg Med* 1997;15(02):221–230
- Han JH, Wilber ST. Altered mental status in older patients in the emergency department. *Clin Geriatr Med* 2013;29(01):101–136
- Han HS, Park J, Kim JH, Suk K. Molecular and cellular pathways as a target of therapeutic hypothermia: pharmacological aspect. *Curr Neuropharmacol* 2012;10(01):80–87