

# “Baker’s Cyst”–Induced Above-Knee Amputation

Michael Christian Liebensteiner, MD<sup>1</sup> Thomas Auckenthaler, MD<sup>1</sup> Andreas Frech, MD<sup>2</sup>  
Lydia Posch, MD<sup>2</sup> Gustav Fraedrich, MD<sup>2</sup> Peter Wilhelm Ferlic, MD<sup>1</sup>

<sup>1</sup>Department of Orthopedic Surgery, Innsbruck Medical of University, Innsbruck, Austria

<sup>2</sup>Department of Vascular Surgery, Innsbruck Medical of University, Innsbruck, Austria

Address for correspondence Peter Wilhelm Ferlic, MD, Department of Orthopedic Surgery, Innsbruck Medical of University, Anichstrasse 35, A-6020 Innsbruck, Austria (e-mail: peter.ferlic@gmail.com).

J Knee Surg Rep 2016;2:e4–e7.

## Abstract

We report a 65-year-old man who presented with a necrotic fifth toe, incipient phlegmon and hypesthesia of the right foot, a swollen lower leg, and a palpable popliteal mass. An occlusion of the popliteal artery secondary to a Baker’s cyst was found to have caused protracted ischemia and the abovementioned symptoms. Despite several endovascular and open-surgery procedures to restore perfusion of the limb, the patient eventually had to undergo above-knee amputation.

It might be speculated whether earlier surgery would have preserved the patient’s limb. Whereas the traditional procedure of open resection of the Baker’s cyst has been associated with high recurrence rates, the condition can be treated effectively and safely today by means of arthroscopic surgery. We believe that arthroscopic interventions should at least be performed in the following instances: (1) in patients with recurrent symptoms of a Baker’s cyst after previous treatment of the intra-articular pathology and previous aspiration of the cyst and (2) in patients with incipient sequelae that indicate relevant compression of neurovascular structures of the popliteal fossa (pseudothrombophlebitis, intermittent claudication, neuropathy).

## Keywords

- ▶ Baker’s cyst
- ▶ popliteal cyst
- ▶ popliteal artery compression
- ▶ knee arthroscopy
- ▶ above-knee amputation

A Baker’s cyst is a commonly observed condition.<sup>1</sup> As it is always secondary to an intra-articular knee pathology (except in children) and the symptoms arising from the cyst are usually minor compared with the symptoms of the intra-articular pathology, the cyst itself is excised in just a small number of cases.<sup>2</sup> However, in some patients, a Baker’s cyst may cause major symptoms and even complications such as pseudothrombophlebitis, phlebothrombosis, cyst leakage, hemorrhage in the calf, or posterior tibial neuropathy.<sup>3,4</sup> Complications arising from compression of the popliteal artery are rare; these include intermittent claudication<sup>5</sup> or more rarely popliteal artery occlusion with limb ischemia. We are aware of three published cases

of ischemia induced by a Baker’s cyst.<sup>6–8</sup> The three patients, in contrast to our case, recovered from the condition.

## Case Report

A 65-year-old man presented with a necrotic fifth toe, incipient phlegmon (see ▶ **Fig. 1**) and hypesthesia of the right foot, a swollen lower leg, and a palpable popliteal mass. No popliteal artery flow was identified below the knee, as verified by clinical examination. A CT scan revealed occlusion of the popliteal artery below the knee joint line, secondary to a Baker’s cyst in a degenerative knee joint (see ▶ **Fig. 2**). A subsequent angiography revealed that it would be

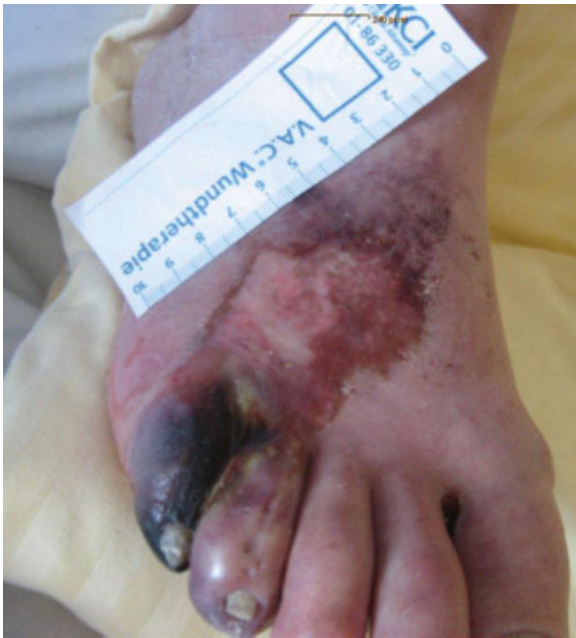received  
February 17, 2016  
accepted after revision  
September 5, 2016  
published online  
January 31, 2017

DOI <http://dx.doi.org/10.1055/s-0036-1597139>.  
ISSN 2326-2729.

Copyright © 2016 by Thieme Medical Publishers, Inc., 333 Seventh Avenue, New York, NY 10001, USA.  
Tel: +1(212) 584-4662.

License terms





**Fig. 1** The right foot at the patient's initial presentation.

appropriate to perform an endovascular procedure on the occlusion. For this reason, and because the inflammation in the lower leg rendered an open intervention unsuitable, a percutaneous transluminal angioplasty (PTA) was performed and the artery was opened by 3 mm (see ►Fig. 3). ►Fig. 4 illustrates the intervals from initial presentation to all treatments performed (see ►Fig. 4). Prolonged ischemia caused a reactive hyperperfusion syndrome which then culminated in a compartment syndrome. We performed an open procedure with cyst resection, drainage of synovial fluid from obviously ruptured portions, and a medial fasciotomy. Two days later the necrotic portion of the forefoot that had demarcated earlier had to be amputated. The local situation worsened over the

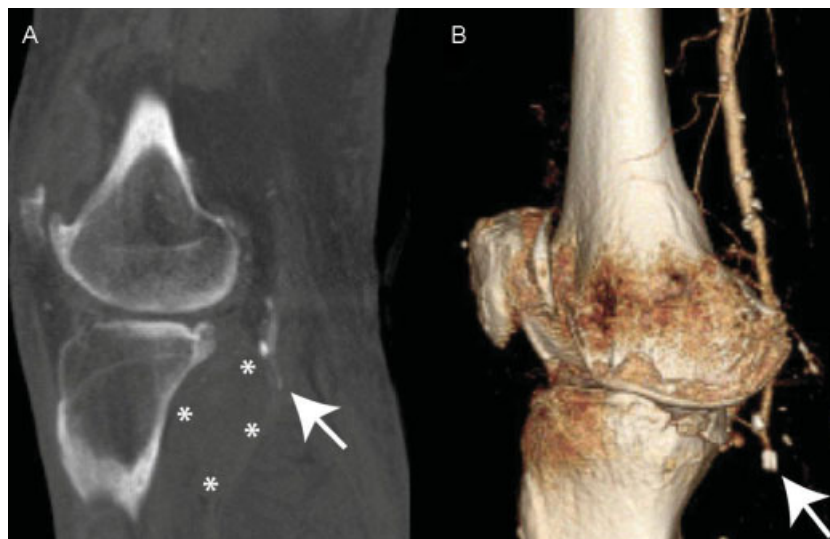
following 3 days. A further angiography revealed three relative stenosis (two in the superficial femoral artery and one in the anterior tibial artery), which were also treated with PTA. Although oscillometric measurements confirmed satisfactory perfusion of the limb, a midfoot amputation had to be performed 10 days later because of gangrene in the right foot. The patient was discharged 2 weeks later. Healing of the fasciotomy wound was associated with complications. Despite wound debridement and treatment with alginate for several weeks, the patient's condition deteriorated (see ►Fig. 5). Due to advanced degeneration of the knee joint, the patient was offered two options: (1) below-knee amputation with contemporary total knee arthroplasty, or (2) above-knee amputation. The patient was informed about the pros and cons of the options. He eventually consented to above-knee amputation. Following amputation, the wounds healed uneventfully. The patient is currently undergoing rehabilitation.

## Discussion

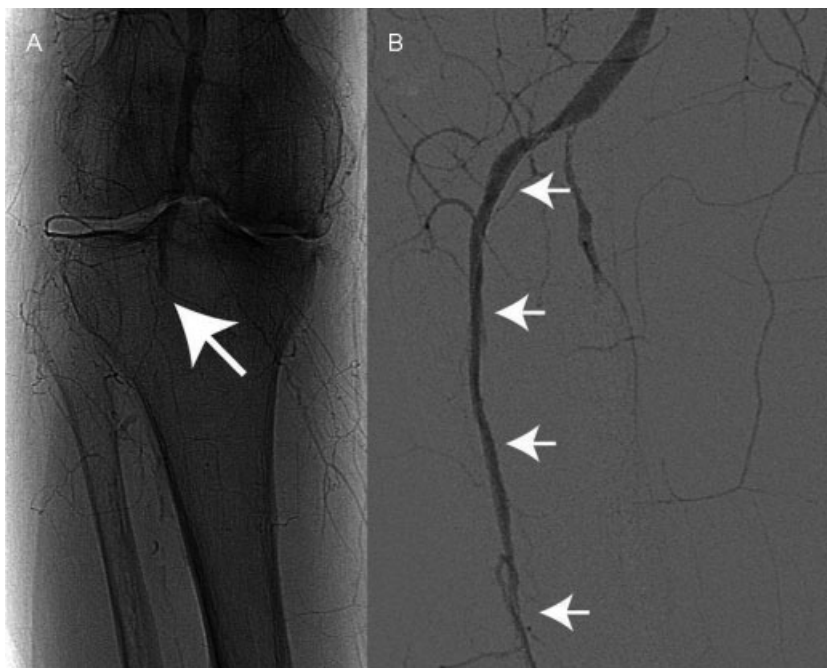
We are aware of three published cases of popliteal artery occlusion induced by a Baker's cyst.<sup>6–8</sup> Krag and Stansel<sup>7</sup> reported resection of the cyst without direct arterial intervention. Clarke et al<sup>6</sup> and Robb<sup>8</sup> performed excision of the cyst and concomitant excision of the thrombosed portion of the artery, which was replaced by a vein graft. The limbs of all of the abovementioned patients recovered fully from ischemia.

Our patient had to undergo above-knee amputation. As the patient presented with protracted ischemia, we presume that the treatment had been appropriate eventually.

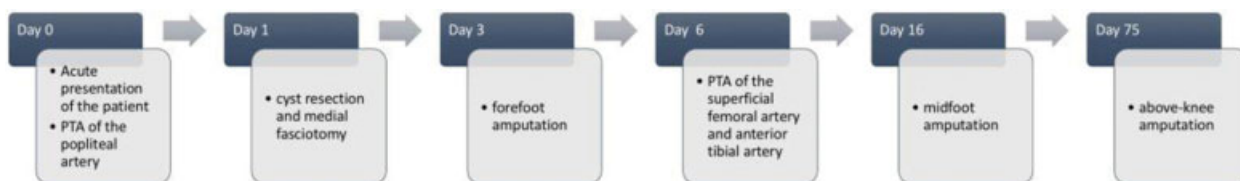
At the time of the patient's acute presentation to our hospital, the angiography revealed an occlusion of the popliteal artery. The aim of the initial treatment with PTA was to restore the blood supply to save the limb. Endovascular treatment has been described as a safe, feasible, and effective method for patients with critical limb ischemia<sup>9,10</sup>. Despite,



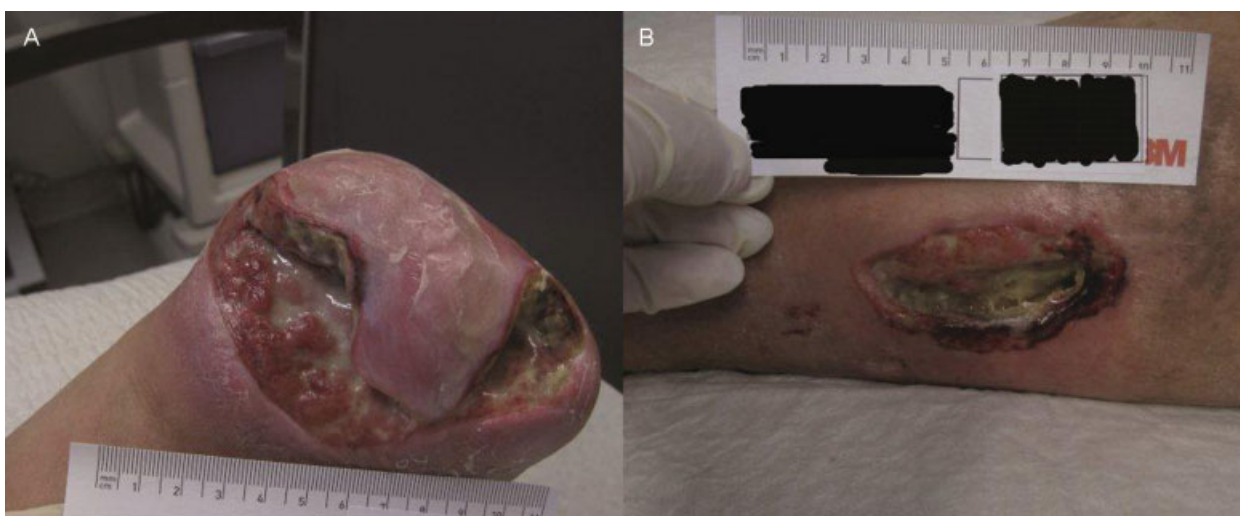
**Fig. 2** CT scan of the right limb at initial presentation. (a) Sagittal slice showing the Baker's cyst (asterisks) with the occlusion of the popliteal artery (arrow). (b) Three-dimensional reconstruction showing advanced arthritis of the knee and occlusion of the popliteal artery (arrow).



**Fig. 3** (a) Occlusion (arrow) of the popliteal artery determined by catheter angiography. (b) Refilling (arrows) of the popliteal artery after successful balloon dilatation (lateral view).



**Fig. 4** Time line illustrating the intervals from initial presentation to all treatments performed.



**Fig. 5** Ulcers in the patient's foot (a) and shank (b) 1 week before above-knee amputation.

balloon dilatation being successful at first, further surgical treatment with amputation had to be performed because of the preexisting necrotic portion of the forefoot and wound healing disturbance. Although major amputations limit func-

tional independence, these can be the only remaining treatment option in some cases.<sup>11</sup>

However, we subsequently recalled that the patient had complained of intermittent claudication, gait difficulties, and balance disorders on several occasions during the years

before the acute event. Oscillometric measurements performed at the time had been normal; the vascular surgeon had been able to palpate all pulses. The patient was also seen by a neurologist, who suspected peripheral neuropathy and advised the intake of vitamins. The patient visited an orthopedic surgeon who diagnosed osteoarthritis with a Baker's cyst and administered steroids by the intra-articular route. It may well be argued that the Baker's cyst was not treated as thoroughly as it could have been.

In this regard, a survey among orthopedic surgeons revealed that one-third of them use the “masterly neglect” approach when confronted with a Baker's cyst. According to the same survey, 80% of the surgeons had not altered their treatment regimen for Baker's cyst in the past 10 years.<sup>2</sup> Given the neglect of many orthopedic surgeons on the one hand and the potential limb-threatening complications of a Baker's cyst on the other, it would be appropriate to draw attention to recent advances in the surgical treatment of this condition. Whereas the traditional procedure of open resection of the Baker's cyst has been associated with high recurrence rates,<sup>12</sup> the condition can be treated effectively and safely today by means of arthroscopic surgery.<sup>13</sup>

We advocate to perform MRI scans in all patients with Baker's cysts and believe that arthroscopic therapy of the cyst should at least be performed in the following instances: (1) in patients with recurrent symptoms of a Baker's cyst after previous treatment of the intra-articular pathology and previous aspiration of the cyst, and (2) in patients with incipient sequelae that indicate relevant compression of the neurovascular structures of the popliteal fossa (pseudothrombophlebitis, intermittent claudication, neuropathy). With regard to our patient, one may well speculate whether early surgery would have preserved the patient's limb.

## Conclusion

A Baker's cyst, secondary to intra-articular knee pathology, is a common condition and in most cases causes only minor

symptoms. However, due to its anatomic location, it can potentially cause severe complications due to compression of neurovascular structures. To prevent these, all patients with a Baker's cyst should undergo a thorough clinical examination and the MRI scans are advocated. We suggest early arthroscopic therapy of the cyst in selected cases.

## References

- 1 Johnson LL, van Dyk GE, Johnson CA, Bays BM, Gully SM. The popliteal bursa (Baker's cyst): an arthroscopic perspective and the epidemiology. *Arthroscopy* 1997;13(1):66–72
- 2 Fritschy D, Fasel J, Imbert J-C, Bianchi S, Verdonk R, Wirth CJ. The popliteal cyst. *Knee Surg Sports Traumatol Arthrosc* 2006;14(7):623–628
- 3 Drescher MJ, Smally AJ. Thrombophlebitis and pseudothrombophlebitis in the ED. *Am J Emerg Med* 1997;15(7):683–685
- 4 Kashani SR, Moon AH, Gaunt WD. Tibial nerve entrapment by a Baker cyst: case report. *Arch Phys Med Rehabil* 1985;66(1):49–51
- 5 Zhang WW, Lukan JK, Dryjski ML. Nonoperative management of lower extremity claudication caused by a Baker's cyst: case report and review of the literature. *Vascular* 2005;13(4):244–247
- 6 Clarke JM, McCann BG, Colin JF. Popliteal artery occlusion by a popliteal (Baker's) cyst. *Eur J Vasc Surg* 1988;2(1):61–63
- 7 Krag DN, Stansel HC Jr. Popliteal cyst producing complete arterial occlusion. A case report. *J Bone Joint Surg Am* 1982;64(9):1369–1370
- 8 Robb D. Obstruction of popliteal artery by synovial cyst. Report of a case. *Br J Surg* 1960;48:221–222
- 9 Gulati A, Botnaru I, Garcia LA. Critical limb ischemia and its treatments: a review. *J Cardiovasc Surg (Torino)* 2015;56(5):775–785
- 10 Mousa A, Rhee JY, Trocciola SM, et al. Percutaneous endovascular treatment for chronic limb ischemia. *Ann Vasc Surg* 2005;19(2):186–191
- 11 Kinlay S. Management of critical limb ischemia. *Circ Cardiovasc Interv* 2016;9(2):e001946
- 12 Rauschnig W, Lindgren PG. Popliteal cysts (Baker's cysts) in adults. I. Clinical and roentgenological results of operative excision. *Acta Orthop Scand* 1979;50(5):583–591
- 13 Ahn JH, Lee SH, Yoo JC, Chang MJ, Park YS. Arthroscopic treatment of popliteal cysts: clinical and magnetic resonance imaging results. *Arthroscopy* 2010;26(10):1340–1347