Vertex Extradural Hematoma due to Traumatic Coronal Suture Diastasis: Review of Three Cases

Tarun Varshney[1] Somnath Sharma[1] Sanjeev Chopra[1] Devendra Purohit[1]

[1] Department of Neurosurgery, SMS Medical College and Hospitals, Jaipur, Rajasthan, India

Address for correspondence Tarun Varshney, MS, Department of Neurosurgery, SMS Medical College and Hospitals, Jaipur, Rajasthan 302004, India (e-mail: tarunvarshney1984@gmail.com).

Indian J Neurotrauma 2016;13:157–160.

Abstract

Vertex extradural hematomas (VEHs) are rare and account for only 1.3 to 8.2% of all traumatic hematomas. The clinical picture of VEH is variable. Three cases of traumatic VEH with coronal suture diastasis following head injury on neuroimaging presented in emergency. All underwent emergency surgery and had excellent outcome.

Keywords
- vertex
- extradural hematoma
- coronal suture
- diastasis

Introduction

Vertex extradural hematomas (VEHs) account for only 1.3 to 8.2% of all traumatic intracranial hematomas with a reported mortality of 18 to 50% in the pre–magnetic resonance imaging (pre-MRI) era.[1] The source of bleeding is believed to be veins, the fracture itself, and diffuse dural bleeding caused by dural stripping.[1,2] We present three cases of VEH with coronal suture diastasis. Superior sagittal sinus (SSS) was found to be intact in all cases.

Case Report

The clinical details of patients are mentioned ►**Table 1**. All cases were taken up for an emergency operation. The plan was to evacuate the hematoma without disturbing the SSS. An S-shaped skin incision was placed over the vertex, and bilateral frontoparietal craniotomy was performed in two cases and unilateral frontoparietal craniotomy using inverted frontoparietal U-shaped flap in one case, leaving a strip of bone over the SSS. There was no injury noted to the SSS, which was stripped away from the inner table. The hematoma was completely evacuated and dural hitch stitches were applied all around the lateral edges of the craniotomies. Postoperative neurologic recovery was good.

Discussion

VEHs are a rare subset with unique radiologic and clinical presentation, frequently causing a diagnostic dilemma. The majority of the reported cases have an associated vertex fracture with fracture line usually crossing the sagittal suture or there is diastasis of the sagittal suture.[1] In our series all cases had coronal suture diastasis (►**Figs. 1–3**). VEH usually presents with headache and elevated intracranial pressure because of obstruction of cerebral venous drainage by the expanding vertex extradural mass or it may present with paraplegia, motor weakness, and quadriplegia.[1,3–5] In our series of patients, no arterial bleeding source was identified. The source of bleeding is believed to be veins, the fracture itself, and diffuse dural bleeding caused by dural stripping.[1,2] The sagittal sinus was intact in our cases. In cases in which SSS is lacerated, the course is much more acute with high mortality.[1] Smaller VEHs may be missed on axial computed tomographic (CT) images but are evident on coronal sequence. Magnetic resonance imaging (MRI) or thin-section CT should be performed to exclude the diagnosis in patients with trauma to the skull vertex.[6,7] In the pre-CT scan era, separation of the sagittal sinus from the inner table was a characteristic angiographic finding. Retarded venous flow to the sinus has been frequently noted on arteriogram.[1] Surgery in any extradural hematoma depends on the volume of

received
October 21, 2016
accepted
November 26, 2016
published online
December 30, 2016

© 2016 Neurotrauma Society of India

DOI http://dx.doi.org/10.1055/s-0036-1597666.
ISSN 0973-0508.

Table 1 Clinical details of cases

Case	Age/sex	GCS	Neurologic finding	CT finding	GOS
1	35/Male	E3V4M6	No weakness	Bifrontal extradural hematoma with coronal suture diastasis	5
2	60/Male	E1V1M5	No weakness	Bifrontal extradural hematoma with coronal suture diastasis	5
3	40/Male	E2V4M5	No weakness	Bifrontal extradural hematoma with coronal suture diastasis	5

Abbreviations: CT, computed tomography; GCS, Glasgow coma scale; GOS, GCS, Glasgow outcome scale.

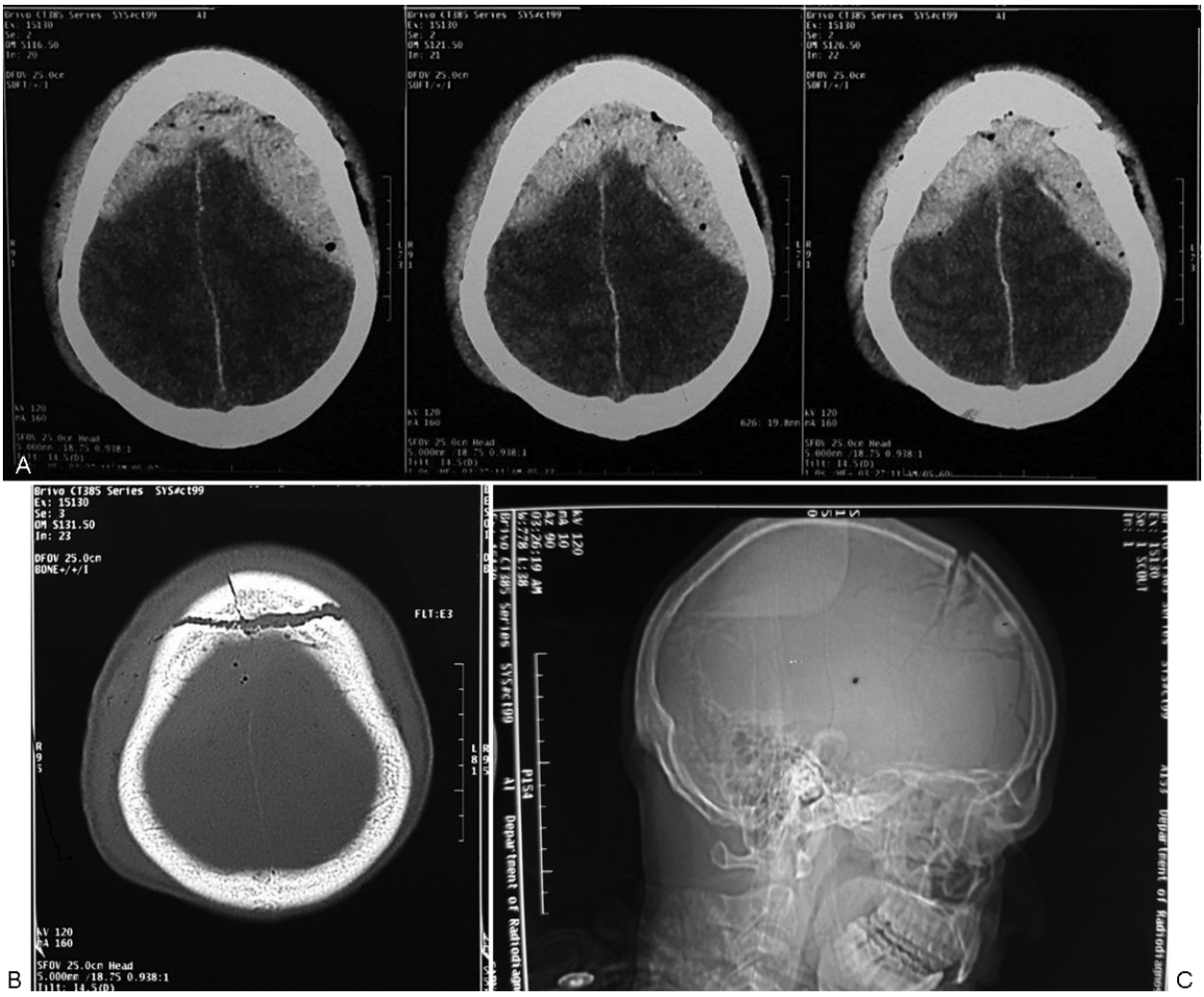

Fig. 1 CT brain axial sections **(A)** showing a large vertex extradural hematoma extending bilaterally. The axial **(B)** and sagittal **(C)** bony cuts clearly show coronal suture diastasis (case 1).

hematoma, presenting neurologic deficits, and clinical course.[6] The majority of the reported cases have been managed conservatively with recovery. Our cases are unique in the clinical presentation, acute course without SSS tear, the radiologic findings, coronal suture diastasis with large hematoma, and the surgical strategy chosen as in the first two cases. We have taken bicoronal flap with bilateral frontoparietal craniotomy and in the third case we opted for unilateral frontoparietal inverted U-shaped flap and right frontoparietal craniotomy (►**Figs. 4**, **5**). Jones et al have described a similar strategy with a bicoronal skin incision and this strategy provided a wide exposure bilaterally and opportunity to complete evacuation without disturbing the SSS. Tears in SSS may significantly complicate the surgery and result in increased morbidity and mortality. Leaving a strip of the bone over the SSS may considerably reduce these risks. Tears, if noted, can be sutured, and the use of multiple hitch stitches all around the craniotomy site, including along the SSS, would control bleeding effectively.[8]

Conclusion

VEHs are unique extradural hematoma with specific features in clinical presentation, diagnosis, and management. The

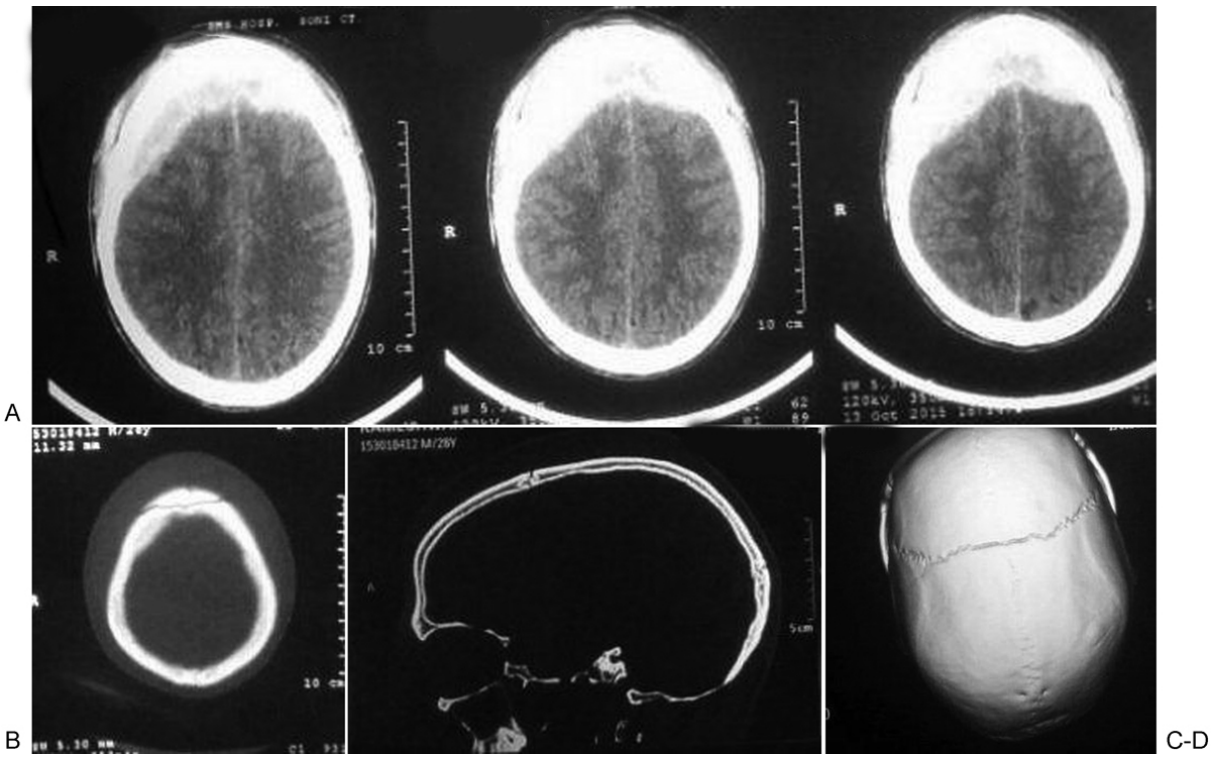

Fig. 2 CT brain axial sections **(A)** showing a large vertex hematoma extending bilaterally. The axial **(B)**, sagittal **(C)**, and 3D reconstruction **(D)** bony cuts clearly show coronal suture diastasis (case 2).

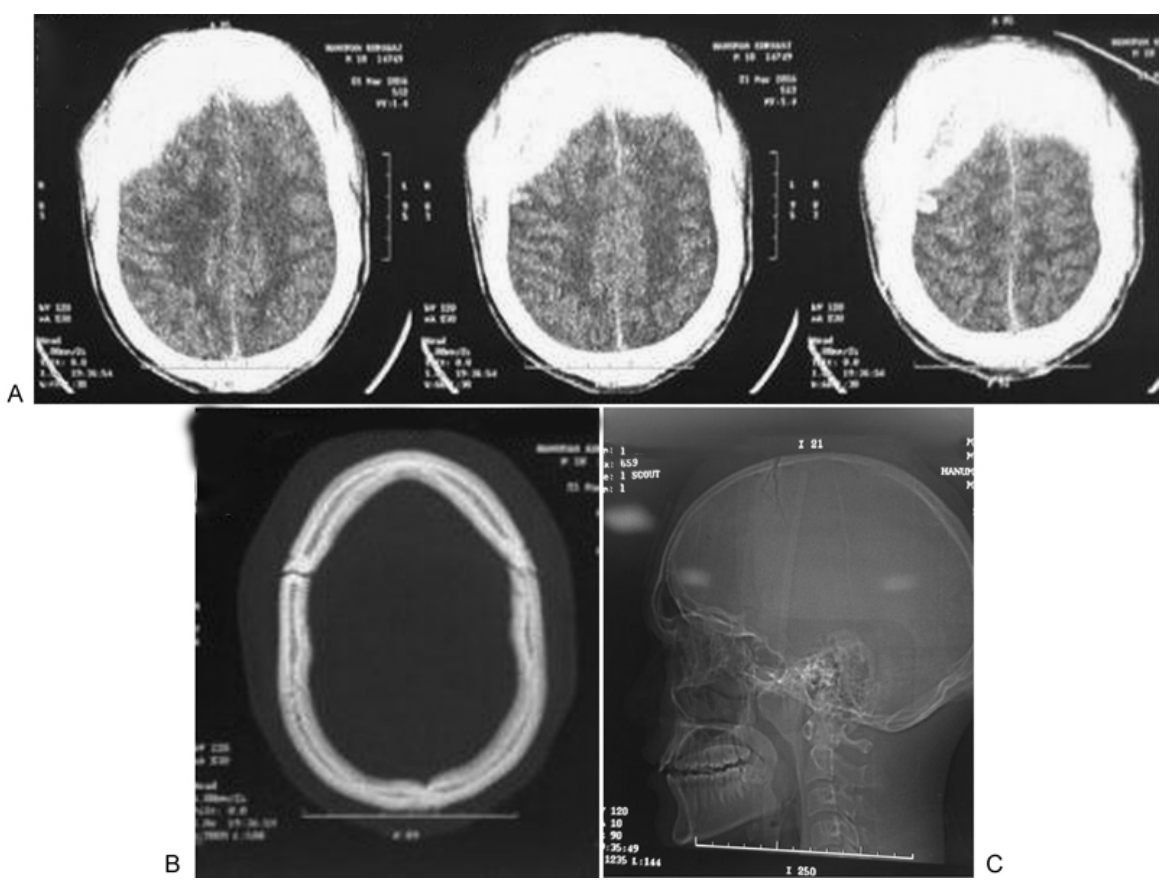

Fig. 3 CT brain axial sections **(A)** showing a large vertex hematoma extending bilaterally. The axial **(B)** and sagittal **(C)** bony cuts clearly show coronal suture diastasis (case 3).

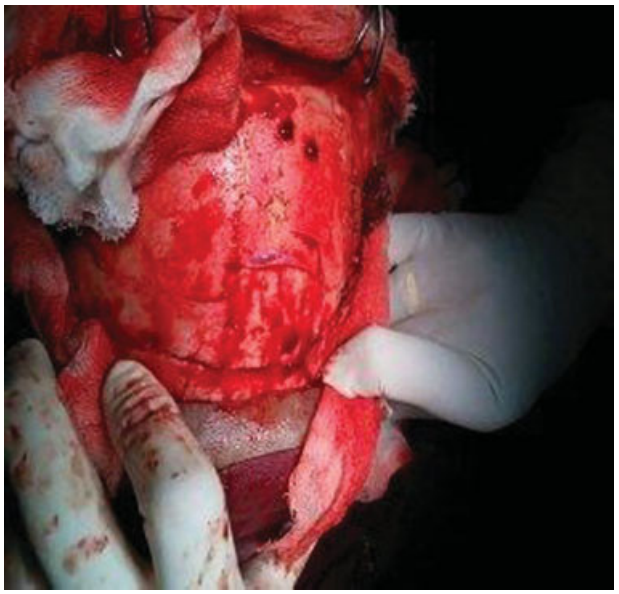

Fig. 4 Coronal suture diastasis (operative photograph of case 2).

other significant lesson learnt from this case series is that regardless of poor Glasgow coma scale (GCS), early decompression of extradural hematomas may result in excellent recovery without significant morbidity.

Fig. 5 Coronal suture diastasis (operative photograph of case 3).

References

1 Wylen EL, Nanda A. Vertex epidural hematoma with coronal suture diastasis presenting with paraplegia. J Trauma 1998; 45(2):413–415

2 Datta SGS. Bilateral vertex extradural hematomas: a case report Indian. J Neurotrauma 2008;5(2):109–111

3 Liliang PC, Liang CL, Chen HJ, Cheng CH. Vertex epidural haematoma presented with paraplegia. Injury 2001;32(3):252–253

4 Miller DJ, Steinmetz M, McCutcheon IE. Vertex epidural hematoma: surgical versus conservative management: two case reports and review of the literature. Neurosurgery 1999;45(3): 621–624, discussion 624–625

5 Somnath S, Krishan OB, Anil C, Kumar SS, Chhhitij S. Vertex epidural hematoma: a rare cause of quadriparesis. Indian Journal of Neurotrauma 2015;12(1):75–79

6 Harbury OL, Provenzale JM, Barboriak DP. Vertex epidural hematomas: imaging findings and diagnostic pitfalls. Eur J Radiol 2000;36(3):150–157

7 Server A, Tollesson G, Solgaard T, Haakonsen M, Johnsen UL. Vertex epidural hematoma—neuroradiological findings and management. Acta Radiol 2002;43(5):483–485

8 Jones TL, Crocker M, Martin AJ. A surgical strategy for vertex epidural haematoma. Acta Neurochir (Wien) 2011;153(9): 1819–1820