

# Bilateral Temporal Bone Fractures with Bilateral Facial Nerve Palsy

Kanjully Sabarigirish<sup>1</sup> Lohith B.R.<sup>1</sup> Sanjeev Saxena<sup>1</sup> Himanshu Swami<sup>1</sup> Angshuman Dutta<sup>1</sup>

<sup>1</sup>Department of Otorhinolaryngology, Command Hospital Air Force Bangalore, Rajiv Gandhi University of Health Sciences, Bangalore, Karnataka, India

Address for correspondence Lohith B.R., MS (ENT), Department of Otorhinolaryngology, Command Hospital Air Force Bangalore, Rajiv Gandhi University of Health Sciences, Bangalore, Karnataka 560007, India (e-mail: lohithbr@gmail.com).

Indian J Neurotrauma 2016;13:168–170.

## Abstract

Bilateral fracture of the temporal bone is a rare cause of bilateral symmetrical simultaneous facial nerve palsy. Early clinical diagnosis of bilateral facial palsy is often delayed due to poor neurologic status of the patient and the absence of asymmetry of the face. Lack of comparison with an unaffected side further compounds assessment of severity with electroneuronography. We report a case of a 27-year-old with bilateral facial nerve palsy following a traumatic head injury causing symmetrical longitudinal fractures of both petrous temporal bones. Follow-up 6 months after facial nerve grafting on the right side and decompression on the left side showed early recovery on both sides.

## Keywords

- bilateral facial palsy
- fracture
- temporal bone

## Introduction

The temporal bone is a complex bone encapsulating many vital structures. Fracture of the temporal bone, especially when it violates the otic capsule, tend to injure facial nerve more than the fractures that spare the otic capsule. Most fractures of the temporal bone are unilateral and otic capsule sparing. Bilateral temporal bone fracture with facial nerve injury is a rarity. Involvement of both facial nerves augments the diagnostic and therapeutic challenges involved.

## Case Report

A 27-year-old man was referred with the inability to close both the eyes completely from the neurosurgical department. It followed a road traffic accident 10 days prior, resulting in closed head injury and intracranial bleeding, which was managed with appropriate neurosurgical intervention. Physical examination revealed an expressionless countenance and complete immobility of all facial muscles with House–Brackmann grading of 6/6. On closure of the eyes, Bell's phenomenon was observed on both sides (►Fig. 1). Otoscopy revealed bilateral hemotympanum, but showed no evidence of injury of external auditory canal or cerebrospinal fluidotorrhea.

Audiological evaluation confirmed bilateral conductive hearing loss and bilateral flat type B curve in tympanometry. Electroneuronography (ENoG) showed reduction in amplitude of the waveform on both sides on maximal stimulation. High-resolution computed tomography scan of the temporal bone revealed symmetrical longitudinal fractures coursing through the petrous part, sparing the otic capsules but extending cranially to the squamous part. On the both sides, the fracture line crossed the region of the geniculate ganglia of the seventh cranial nerve (►Fig. 2). Additionally, hemorrhagic contusions were observed on both temporal and parietal lobes, with focal subarachnoid hemorrhage over the right temporal lobe.

The patient underwent surgical intervention of both sides on the 12th day after onset. On the right side, facial nerve transection was observed on the proximal part of the horizontal segment adjoining the geniculate ganglion. A short segment of greater auricular nerve was used for neural grafting. Limited access to the proximal end of the transection prevented the graft from being secured with sutures to the nerve. The grafted segment was therefore wrapped around in temporalis fascia and stabilized with fibrin glue. On the left side, there was no discontinuity of the nerve, but nerve sheath was edematous in the horizontal segment, which was duly decompressed. Follow-up 6 months after surgery revealed

received

September 20, 2016

accepted

December 2, 2016

published online

December 30, 2016

© 2016 Neurotrauma Society of India

DOI <http://dx.doi.org/10.1055/s-0036-1597749>.  
ISSN 0973-0508.



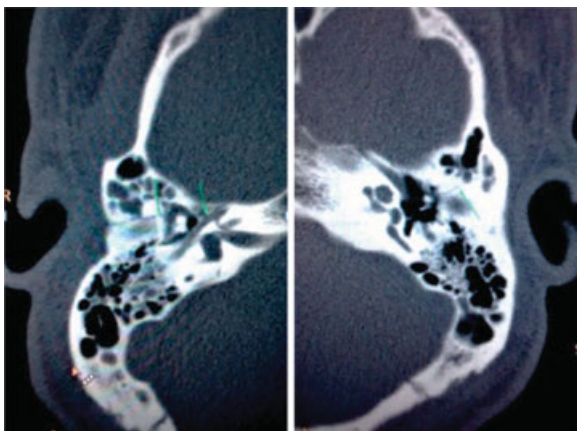
**Fig. 1** Bell's phenomenon and masklike expression in bilateral facial nerve palsy.

House–Brackmann grading of 5/6 on the left side and 3/6 on the right side.

## Discussion

Bilateral facial nerve palsy, defined as involvement of both hemifacies within 4 weeks of onset, is a rare condition occurring in 0.4% of all cases of facial nerve palsy.<sup>1</sup> The commonest cause, Bell's palsy, is a diagnosis arrived by exclusion of traumatic, metabolic, immunological, infective, and vascular causes.<sup>2</sup> Fractures of skull base occur in 4 to 30% of closed head injuries due to falls, assault, or traffic accidents, with temporal bones involved in 22%.<sup>3</sup> These fractures are mostly unilateral, with bilateral fractures reported in less than 20%. Of these, bilateral facial nerve palsy is limited to a mere 3%.<sup>4</sup>

Conventionally temporal bone fractures are described as longitudinal or transverse based on its alignment to the axes of the temporal bone. However, descriptors such as oblique fractures have been added to describe a fracture plane that crosses the petrotympanic fissure.<sup>5</sup> Longitudinal fractures are most likely to involve the fallopian canal in the region of the geniculum, whereas labyrinthine segment is the usual site of injury in transverse fractures. Transection of the nerve is more common in transverse fractures.<sup>6</sup> These morphological



**Fig. 2** Symmetrical bilateral temporal bone fractures involving the geniculate ganglion.

descriptions of the fractures do not accurately correlate with the clinical sequelae. Involvement of the otic capsule is a more accurate predictor of the outcome. Facial nerve injury is twice as common when the otic capsule is violated.<sup>7</sup> High-resolution imaging of the temporal bone plays a crucial role in accurately identifying the site of injury. However, assessing the severity of damage with certainty, especially when a transection of the nerve is suspected, is often difficult radiologically.

Electrophysiological tests such as ENoG have the potential to assess the severity of neuronal damage and degeneration with precision. When done serially in the window period between 3 and 21 days after onset, it determines the threshold for surgical intervention when 90% or more of neuronal degeneration is recorded. However, use of ENoG is compromised in bilateral facial nerve palsy as ENoG can only determine the degree of neuronal degeneration when the evoked amplitude of the traumatized side is compared with that of the unaffected side in unilateral facial nerve palsy.

Therefore, in posttraumatic bilateral facial nerve paralysis, decision on the necessity of surgical intervention and its timing is primarily based on the immediacy of onset and completeness of palsy. Immediate complete palsy indicates loss of neural discontinuity, whereas delayed onset or partial palsy suggests an intact nerve compromised by neural edema and/or hematoma in the fallopian canal compressing the nerve. Often, an early diagnosis of bilateral facial nerve palsy secondary to head injury is delayed as the nerve function cannot be checked in an unresponsive comatose patient. A masklike facial expression with lack of asymmetry of the face on volitional movement adds to the diagnostic dilemma.<sup>8</sup> Surgical intervention also tend to get delayed due to unfavorable posttraumatic neurologic status. However, inappropriate delay should not be the aver surgical intervention as studies suggest reasonable recovery even in surgical intervention performed as late as 160 days.<sup>9,10</sup>

## Conclusion

Bilateral temporal bone fracture with bilateral facial nerve palsy is a rare entity. Clinical diagnosis of this condition is often delayed in a neurologically compromised patient. High-resolution imaging accurately identifies the site of facial nerve injury but not the severity of the injury. ENoG, a useful tool for assessing neuronal degeneration in unilateral facial nerve palsy, is not feasible in bilateral involvement of facial nerve. Immediate surgical intervention is warranted when there is immediate, complete posttraumatic facial nerve palsy.

## References

- Kim YH, Choi IJ, Kim HM, Ban JH, Cho CH, Ahn JH. Bilateral simultaneous facial nerve palsy: clinical analysis in seven cases. *Otol Neurotol* 2008;29(3):397–400
- Ghiasi S, Banaei M. Bilateral facial paralysis caused by temporal bone fracture: a case report. *Arch Trauma Res* 2016;5(2):e26892
- Li J, Goldberg G, Munin MC, Wagner A, Zafonte R. Post-traumatic bilateral facial palsy: a case report and literature review. *Brain Inj* 2004;18(3):315–320

- 4 Cannon CR, Jahrsdoerfer RA. Temporal bone fractures. Review of 90 cases. *Arch Otolaryngol* 1983;109(5):285–288
- 5 Ghorayeb BY, Yeakley JW. Temporal bone fractures: longitudinal or oblique? The case for oblique temporal bone fractures. *Laryngoscope* 1992;102(2):129–134
- 6 Wysocki J. Cadaveric dissections based on observations of injuries to the temporal bone structures following head trauma. *Skull Base* 2005;15(2):99–106, discussion 106–107
- 7 Dahiya R, Keller JD, Litofsky NS, Bankey PE, Bonassar LJ, Megerian CA. Temporal bone fractures: otic capsule sparing versus otic capsule violating clinical and radiographic considerations. *J Trauma* 1999;47(6):1079–1083
- 8 Kumar R, Mittal RS. Post traumatic delayed bilateral facial nerve palsy (FNP): diagnostic dilemma of expressionless face. *J Clin Diagn Res* 2015;9(4):PD15–PD16
- 9 Sanuş GZ, Tanrıöver N, Tanrıverdi T, Uzan M, Akar Z. Late decompression in patients with acute facial nerve paralysis after temporal bone fracture. *Türk Neurosurg* 2007;17(1):7–12
- 10 Quaranta A, Campobasso G, Piazza F, Quaranta N, Salonna I. Facial nerve paralysis in temporal bone fractures: outcomes after late decompression surgery. *Acta Otolaryngol* 2001;121(5):652–655