

# Frontal Bone Fracture Extending into the Roof and Medial Wall of Orbital Fracture Causing Diplopia

Amit Agrawal<sup>1</sup> Umamaheswara Reddy V<sup>2</sup> Yashawanth Sandeep<sup>1</sup> Ninad Nareshchandra Shrikhande<sup>1</sup>

<sup>1</sup>Department of Neurosurgery, Narayana Medical College Hospital, Chinthareddypalem, Nellore, Andhra Pradesh, India

<sup>2</sup>Department of Radiology, Narayana Medical College Hospital, Chinthareddypalem, Nellore, Andhra Pradesh, India

Address for correspondence Amit Agrawal, MCh, Department of Neurosurgery, Narayana Medical College Hospital, Chinthareddypalem, Nellore, Andhra Pradesh 524003, India (e-mail: dramitagrawal@gmail.com).

Indian J Neurotrauma 2016;13:165–167.

## Abstract

### Keywords

- orbital wall fractures
- diplopia
- medial orbital wall
- extraocular muscle entrapment
- skull fracture

Fractures of the anterior cranial fossa can extend into the orbit and, if not detected early, can lead to either acute (e.g., diplopia, retrobulbar hematoma, and enophthalmos) or chronic complications (e.g., diplopia, restricted extraocular movement, ectropion, and enophthalmos). We report a case of a 15-year-old male child who sustained frontal bone fracture extending into the orbit. He had swelling of the right eye, and once the swelling subsided, he complained of diplopia. Computed tomography scan of the brain showed comminuted depressed frontal bone fracture extending more on the right side—the fracture was extending into the right orbital roof and associated fracture of the right medial orbital wall. The child underwent elevation of depressed bone fragments including decompression of the medial rectus muscle. Frontal bone fragments was replaced and secured with miniplates and screws. His diplopia completely recovered and he is doing well at follow-up.

## Introduction

Fractures involving the medial wall of the orbit can be asymptomatic in acute phase or can be overshadowed by other associated injuries (i.e., traumatic brain injury).<sup>1,2</sup> If not detected early, these can lead to either acute (e.g., diplopia, retrobulbar hematoma, and enophthalmos) or chronic complications (e.g., diplopia, restricted extraocular movement, ectropion, and enophthalmos).<sup>3–5</sup> We report a case of cranial base fracture extending into the orbit and discuss its management.

## Case Report

A 15-year-old male child presented with a history of fall from a motorcycle. He presented to the emergency room 6 hours after the incident. The patient was in altered sensorium since the time

of injury and had multiple episodes of vomiting and nasal bleed. There was no history of seizures. Glasgow Coma Scale (GCS) was E1, V2, and M5. In view of altered sensorium and low GCS, the child was intubated and electively ventilated. His general examination was normal. His systemic examination was normal, except swelling of the left thigh. He was sedated and paralyzed; hence, detail neurologic examination was not possible. Pupils were bilateral 3 mm and briskly reacting to light. Local examination revealed laceration over the forehead, depression over the right frontal region, and crepitus over the right zygomatic arch. Computed tomography (CT) scan of the brain showed comminuted depressed frontal bone fracture extending more on the right side—the fracture was extending into the right orbital roof and associated fracture of the right medial orbital wall (►Fig. 1A–D). There were associated small patchy bifrontal contusions with mild cerebral edema. In view of

received

September 9, 2016

accepted

December 2, 2016

published online

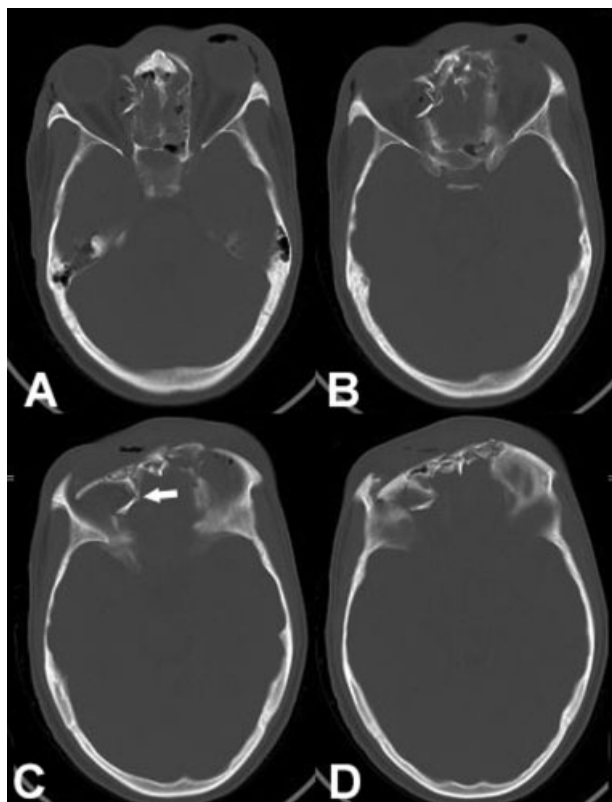
December 28, 2016

© 2016 Neurotrauma Society of India

DOI <http://dx.doi.org/>

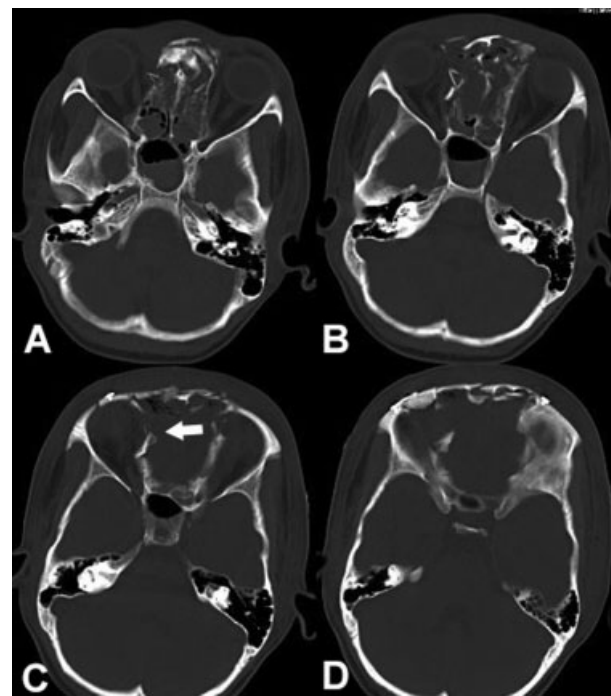
10.1055/s-0036-1597751.

ISSN 0973-0508.



**Fig. 1** (A–D) Computed tomography scan of the brain with orbital sections showing comminuted depressed frontal bone fracture extending more on right side—the fracture was extending into the right orbital roof and associated fracture of the right medial orbital wall (C; white arrow).

poor neurologic status, the patient was planned for initial elective management (antibiotics, antiepileptics, and antiedema measures) followed by elective elevation of the depressed fracture fragments. The patient responded well to conservative management and regained consciousness on day 2 postinjury. At the same time, there was resolution of right periorbital edema. After this the child started complaining of double vision. The CT was reviewed and it was decided that this diplopia might be due to compression of medial rectus by fractured fragments. His vision in both the eyes was normal. The patient was planned for bifrontal craniotomy and elevation of depressed bone fragments including decompression of the medial rectus muscle. A bicoronal scalp flap was raised, fractured frontal bone fragments were exposed, and a bifrontal craniotomy was performed (flush to the orbital roof). Loose bone fragments from orbital roof were removed, lateral part of the cribriform plate was visualized, and loose fractured fragments from medial orbital wall were carefully removed. Pericranial fascial graft was placed to separate the dura from the anterior cranial fossa base (and to avoid cerebrospinal fluid leak). Frontal bone fragments were replaced and secured with miniplates and screws. The incision was closed in layers. The patient recovered well after surgery and there was complete resolution of diplopia. Follow-up CT scan showed adequate repositioning of the medial wall (→ Fig. 2A–D). The patient further underwent internal fixation of left femur fracture. He is doing well at follow-up.



**Fig. 2** (A–D) Follow-up computed tomography scan of the brain bone showing elevation of the depressed fragments and repositioning of medial orbital wall (C; white arrow).

## Discussion

Fractures of the anterior cranial fossa can extend into the orbit and can lead to diplopia and ocular motility disorders due to the restricted movements of the entrapped ocular muscles in acute stage<sup>6</sup> or due to ischemia, subsequent fibrosis, and delayed dysfunction of the entrapped rectus muscles.<sup>7,8</sup> In early postinjury period, clinically orbital fractures can be masked by the presence of periorbital edema, ecchymosis, and subcutaneous emphysema, thus requiring a detail and careful evaluation along with radiological investigations.<sup>7,9</sup> CT scan, axial and coronal sections with bone window, can provide the details of fractured fragments (including degree of displacement), muscle entrapment, and any intraorbital collections, and additionally it will help to know the presence of any intracranial injuries and need for surgical intervention.<sup>7,10–13</sup>

In the absence of orbital dysfunctions, orbital and displaced fractures do not require surgical intervention.<sup>7</sup> However, the presence of diplopia and significant enophthalmos are the major indication for early surgical intervention.<sup>8,14,15</sup> Early surgical intervention helps to restore the normal alignment of the bony orbit and facilitates decompression of the orbital contents, repositioning of extraocular muscles, and removal of loose fragments and other orbital soft tissue contents.<sup>8,16–18</sup> The reported duration for intervention ranges from 3 days (in children) to 7 days (in adults who present with diplopia),<sup>14</sup> to 2 weeks in another study where the extraocular muscle entrapment was present.<sup>16,19,20</sup> The surgical approach depends on the location and extent of fractures (orbit-only involvement or extension to the cranial base, as in the present case), the

amount of compression on orbital contents and clinical manifestations (diplopia and enophthalmos), and the expertise available to manage these injuries.<sup>21–23</sup> If the fracture involve only medial orbital wall, then the available options are lid fornix incision,<sup>22,23</sup> transcaruncular incision, medial canthus Lynch incision, transconjunctival incision, or medial upper lid crease incision.<sup>7,24–26</sup> If there is involvement of the cranial base, a bicoronal incision<sup>22,23,27</sup> can provide wider exposure to handle both cranial and orbital pathologies (as in the present case).

## Conclusion

Skull fractures that extend and involve orbit need careful evaluation for the function of the orbital structures. Early surgical intervention to manage diplopia in patients with orbital wall fractures results in good functional recovery. This requires involvement of the neurosurgeon, ophthalmologist, otolaryngologist, and craniofacial surgeon, as well as complete neurologic and ophthalmic evaluation with appropriate radiological investigations and early but planned surgical intervention to gain the best functional outcome and to reduce delayed complications.

## References

- Burm JS, Chung CH, Oh SJ. Pure orbital blowout fracture: new concepts and importance of medial orbital blowout fracture. *Plast Reconstr Surg* 1999;103(7):1839–1849
- Pearl RM. Treatment of enophthalmos. *Clin Plast Surg* 1992;19(1):99–111
- Park MS, Kim YJ, Kim H, Nam SH, Choi YW. Prevalence of diplopia and extraocular movement limitation according to the location of isolated pure blowout fractures. *Arch Plast Surg* 2012;39(3):204–208
- Gassner R, Tuli T, Hächl O, Rudisch A, Ulmer H. Cranio-maxillofacial trauma: a 10. year review of 9,543 cases with 21,067 injuries. *J Craniomaxillofac Surg* 2003;31(1):51–61
- Lieger O, Zix J, Kruse A, Goldblum D, Iizuka T. Bone and cartilage wedge technique in posttraumatic enophthalmos treatment. *Arch Facial Plast Surg* 2010;12(5):305–310
- Kushner BJ. Paresis and restriction of the inferior rectus muscle after orbital floor fracture. *Am J Ophthalmol* 1982;94(1):81–86
- Thiagarajah C, Kersten RC. Medial wall fracture: an update. *Craniomaxillofac Trauma Reconstr* 2009;2(3):135–139
- Brannan PA, Kersten RC, Kulwin DR. Isolated medial orbital wall fractures with medial rectus muscle incarceration. *Ophthal Plast Reconstr Surg* 2006;22(3):178–183
- Nolasco FP, Mathog RH. Medial orbital wall fractures: classification and clinical profile. *Otolaryngol Head Neck Surg* 1995;112(4):549–556
- Hopper RA, Salemy S, Sze RW. Diagnosis of midface fractures with CT: what the surgeon needs to know. *Radiographics* 2006;26(3):783–793
- Schuknecht B, Graetz K. Radiologic assessment of maxillofacial, mandibular, and skull base trauma. *Eur Radiol* 2005;15(3):560–568
- Kahana A, Lucarelli MJ, Burkat CN, Dortzbach RK. Orbital fractures. In: *Surgical Atlas of Orbital Disease* New York, NY: McGraw Hill; 2009:220–243
- Gilbard SM, Mafee MF, Lagouros PA, Langer BG. Orbital blowout fractures. The prognostic significance of computed tomography. *Ophthalmology* 1985;92(11):1523–1528
- Matteini C, Renzi G, Becelli R, Belli E, Iannetti G. Surgical timing in orbital fracture treatment: experience with 108 consecutive cases. *J Craniofac Surg* 2004;15(1):145–150
- Burnstine MA. Clinical recommendations for repair of orbital facial fractures. *Curr Opin Ophthalmol* 2003;14(5):236–240
- Bansagi ZC, Meyer DR. Internal orbital fractures in the pediatric age group: characterization and management. *Ophthalmology* 2000;107(5):829–836
- Jordan DR, Allen LH, White J, Harvey J, Pashby R, Esmaeli B. Intervention within days for some orbital floor fractures: the white-eyed blowout. *Ophthal Plast Reconstr Surg* 1998;14(6):379–390
- Hoşal BM, Beatty RL. Diplopia and enophthalmos after surgical repair of blowout fracture. *Orbit* 2002;21(1):27–33
- Burnstine MA. Clinical recommendations for repair of isolated orbital floor fractures: an evidence-based analysis. *Ophthalmology* 2002;109(7):1207–1210, discussion 1210–1211, quiz 1212–1213
- Egbert JE, May K, Kersten RC, Kulwin DR. Pediatric orbital floor fracture: direct extraocular muscle involvement. *Ophthalmology* 2000;107(10):1875–1879
- Ploder O, Oeckher M, Klug C, et al. Follow-up study of treatment of orbital floor fractures: relation of clinical data and software-based CT-analysis. *Int J Oral Maxillofac Surg* 2003;32(3):257–262
- Kim KS, Kim ES, Hwang JH. Combined transcutaneous transthemoidal/transorbital approach for the treatment of medial orbital blowout fractures. *Plast Reconstr Surg* 2006;117(6):1947–1955
- Su GW, Harris GJ. Combined inferior and medial surgical approaches and overlapping thin implants for orbital floor and medial wall fractures. *Ophthal Plast Reconstr Surg* 2006;22(6):420–423
- Garcia GH, Goldberg RA, Shorr N. The transcaruncular approach in repair of orbital fractures: a retrospective study. *J Craniomaxillofac Trauma* 1998;4(1):7–12
- Kim S, Helen Lew M, Chung S-H, Kook K, Juan Y, Lee S. Repair of medial orbital wall fracture: transcaruncular approach. *Orbit* 2005;24(1):1–9
- Shorr N, Baylis HI, Goldberg RA, Perry JD. Transcaruncular approach to the medial orbit and orbital apex. *Ophthalmology* 2000;107(8):1459–1463
- de Visscher JG, van der Wal KG. Medial orbital wall fracture with enophthalmos. *J Craniomaxillofac Surg* 1988;16(2):55–59