

Elastographic Evaluation of Indeterminate Breast Masses on Ultrasound

Avaliação pela elastografia dos nódulos mamários indeterminados na ultrassonografia

Luciana Graziano¹ Almir Galvão Vieira Bitencourt¹ Marcela Pecora Cohen¹ Camila Souza Guatelli¹
Miriam Rosalina Brites Poli¹ Juliana Alves Souza¹ Elvira Ferreira Marques¹

¹Department of Imaging, AC Camargo Cancer Center, São Paulo, Brazil

Address for correspondence Luciana Graziano, MD, Department of Imaging, AC Camargo Cancer Center, Rua Prof. Antônio Prudente, 211, São Paulo/SP, Brazil 01509-010 (e-mail: lugraziano79@gmail.com).

Rev Bras Ginecol Obstet 2017;39:72–79.

Abstract

Objective To evaluate the diagnostic accuracy of elastography for breast cancer identification in patients with indeterminate lesions on ultrasound.

Methods This prospective, descriptive study included patients with indeterminate breast lesions in the ultrasound and with indication for percutaneous or surgical biopsy. The elastography was evaluated by qualitative analysis and by two methods for the semi quantitative analysis.

Results We evaluated 125 female patients with 159 lesions, with a mean age of 47 years, and a range of 20–85 years. Ultrasound has shown to be a method with good sensitivity (98.1%), but with a lower specificity (40.6%). On the elastography qualitative analysis, the specificity and accuracy were of 80.2% and 81.8% respectively. The mean size of the lesions showed no difference in classification by elastography. For the semiquantitative elastography, the mean values of the malignant lesions were statistically higher when compared with the subcutaneous tissue or the adjacent fibroglandular tissue. The analysis of the receiver operating characteristic (ROC) curves for these two semiquantitative methods showed that both are considered satisfactory, with an area under the curve above 0.75 and statistical significance ($p < 0.0001$). The best results were obtained when using the findings of combined conventional ultrasound and qualitative elastography, with 100% sensitivity and 63.2% specificity.

Conclusions Elastography can be a useful complementary method, increasing the specificity and diagnostic accuracy of conventional ultrasound for the diagnosis of breast cancer in patients with indeterminate breast lesions.

Keywords

- ▶ breast neoplasms
- ▶ mammary ultrasonography
- ▶ elastography
- ▶ lesions

Resumo

Objetivo Avaliar a acurácia diagnóstica da elastografia para identificação do câncer de mama em pacientes com lesões indeterminadas por ultrassom.

Métodos Estudo prospectivo, descritivo, com pacientes com lesões mamárias indeterminadas no ultrassom e indicação de biópsia percutânea ou cirúrgica. A elastografia foi avaliada por análise qualitativa e dois métodos de análise semiquantitativa.

received
May 8, 2016
accepted
November 8, 2016
published online
December 27, 2016

DOI <http://dx.doi.org/10.1055/s-0036-1597753>.
ISSN 0100-7203.

Copyright © 2017 by Thieme-Revinter Publicações Ltda, Rio de Janeiro, Brazil

License terms



Palavras-chave

- ▶ neoplasias da mama
- ▶ ultrassonografia mamária
- ▶ elastografia
- ▶ lesões

Resultados Avaliamos 125 pacientes do sexo feminino com 159 lesões, com média de idade de 47 anos, variando de 20 a 85 anos. O ultrassom mostrou ser um método com boa sensibilidade (98,1%), mas com menor especificidade (40,6%). Na elastografia da análise qualitativa, a especificidade e acurácia foram de 80,2% e 81,8%, respectivamente. A dimensão média das lesões não mostrou diferença na classificação por elastografia. Para a elastografia semiquantitativa, os valores médios das lesões malignas foram estatisticamente maiores quando comparados ao tecido subcutâneo ou fibroglandular adjacente. A análise das curvas ROC para estes dois métodos semiquantitativos mostrou que ambos são considerados satisfatórios, com área abaixo da curva acima de 0,75 e significância estatística ($p < 0,0001$). Os melhores resultados foram obtidos com os achados de ultrassonografia combinada convencional e elastografia qualitativa, com sensibilidade de 100% e especificidade de 63,2%.

Conclusões A elastografia pode ser um método complementar útil, aumentando a especificidade e a precisão diagnósticas do ultrassom convencional para o diagnóstico de câncer de mama em pacientes com lesões mamárias indeterminadas.

Introduction

Imaging methods have a fundamental role in the management of patients with breast cancer, especially in the early diagnosis of non-palpable breast lesions. The conventional image methods (that is, mammography and ultrasound [US]) already present high sensitivity; however, there is still a large number of false positive results.¹ The biopsy rate with positive cancer is only 10–30%, and this means that most breast biopsies performed result on benign findings, causing unnecessary discomfort and anxiety to the patient, and increasing the costs for health care systems.²

Ultrasonography is often used to complement mammography, especially in young patients or those with dense breasts. However, conventional US is known to have a high rate of false positive results, and its specificity varies from 24 to 98.8%.³ Elastography is a new tool available in some US devices that measures the degree of elasticity or deformation of a tissue. Combined with the morphological criteria evaluated during the examination of the US, it can aid in the differential diagnosis between benign and malignant lesions.^{4–7} This technique relies on the fact that the tissue of malignant lesions is more resistant to compression than the surrounding normal parenchyma and benign lesions.⁸ There are two different techniques available for clinical use, compression or “strain” elastography, and “shear-wave” elastography, and both have a good diagnostic performance in the evaluation of breast lesions.⁹

Although this technology is already being studied for the evaluation of breast lesions, it only recently became available for use in the clinical practice, and there are few studies on its performance and real benefit in the evaluation of patients with breast lesions. The objective of this study was to evaluate the diagnostic accuracy of elastography for breast cancer identification in patients with indeterminate lesions on conventional US.

Methods

This prospective, descriptive study included 125 patients with 159 indeterminate breast lesions in ultrasonography, and with an indication for percutaneous or surgical biopsy, in the Imaging Department of a cancer center, from June 2013 to May 2015. The study was approved by the institution's Ethics Review Board, and all patients signed a written informed consent before enrollment. A standardized data sheet was completed for all patients, with clinical information, ultrasound findings and histological analysis. The imaging findings of other methods, such as mammography and magnetic resonance imaging, were not analyzed, as they were not available for most patients, and to avoid influence on lesion characterization by US.

The Breast Imaging Reporting and Data System (BI-RADS) lexicon (5th edition) was used to describe the lesions' characteristics, including shape, margins, orientation, echo pattern and posterior features. Lesions classified in BI-RADS categories 3, 4a, 4b, 4c and 5 were considered indeterminate and included in the study. Category 3 lesions included hypoechoic, isoechoic or heterogeneous echo pattern, oval shape, circumscribed margins and parallel orientation masses, or isolated grouped micro cysts. Category 4a lesions included round masses with circumscribed masses and any posterior features. Category 4b included non-mass lesions with architectural distortion, oval or rounded masses with indistinct margins, intraductal masses and complex cystic and solid masses. Category 4c included non-mass lesions with architectural distortion and micro calcifications, and round or irregular hypoechoic masses with angular or micro lobulated margins. Category 5 included irregular hypoechoic mass with spiculated margins and posterior shadowing.

Patients were submitted to an ultrasonographic examination with elastography before the percutaneous procedure (needle biopsy or preoperative localization). Ultrasounds were performed in a specific device (Aplio 500; Toshiba America Medical Systems, Minato-ku, Tokyo 105–8001,

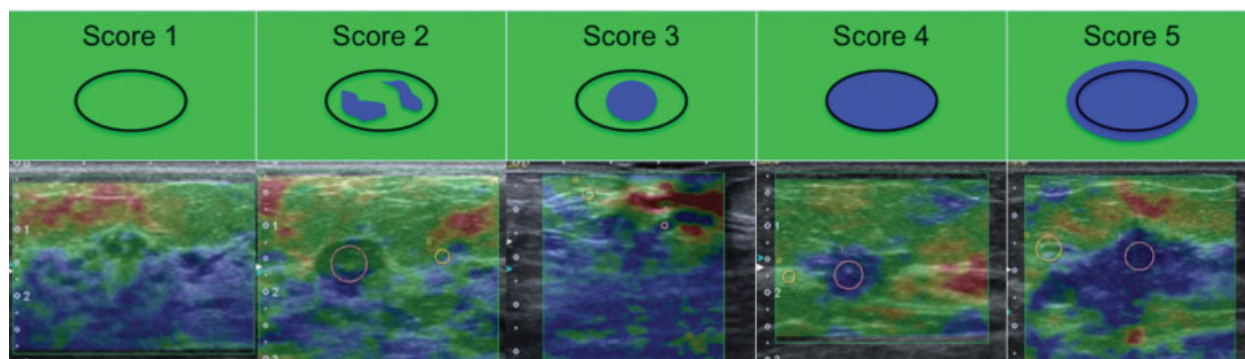


Fig. 1 Examples of lesions classified in each compressibility score for the qualitative elastography, according to the criteria proposed by Itoh et al.

Japan), using the “strain” elastography technique, performed by a single radiologist with expertise in breast US. The exam was performed in real time, with the probe positioned perpendicular to the skin over the region of interest (ROI), with normal respiratory movements of the patient, and associated with repetitive movements of slight pressure. The ROI area for the elastography evaluation was selected including subcutaneous fat and the pectoralis muscle, and more than 5 mm from the side edges. The elastography findings were evaluated for the qualitative and semi quantitative analyses.

For the qualitative analysis of the elastography, a color scale was used, in which tissues with lower compressibility appeared as blue, more compressible tissues as red, and tissues with intermediate compressibility as green/yellow. According to the criteria proposed by Itoh et al,¹⁰ the lesions were classified in 5 different scores, and considered as probably benign (scores 1, 2 and 3) or suggesting malignancy (scores 4 and 5)^{10,11} (► **Fig. 1**):

- Score 1 - Uniformly compressible lesion, suggesting benignity.
- Score 2 - Highly compressible lesion with some areas of lesser compressibility, also suggesting benignity.
- Score 3 - Lesion with greater compressibility in the periphery, indicating the probability of a benign lesion.
- Score 4 - Absence of compressibility all over the lesion; suspicion of malignancy.
- Score 5 - Absence of compressibility all over the lesion and also in the surrounding tissues, suggesting malignancy.

For the semi quantitative analysis, we used a ratio that compares the “strain” tension rate between two ROI areas selected manually. The compressibility within the lesion was compared with the compressibility in the subcutaneous tissue (lesion/subcutaneous tissue ratio), and also with the adjacent normal fibroglandular breast tissue (lesion/adjacent fibroglandular tissue ratio) (► **Fig. 2**). This “strain” rate reflects the relative

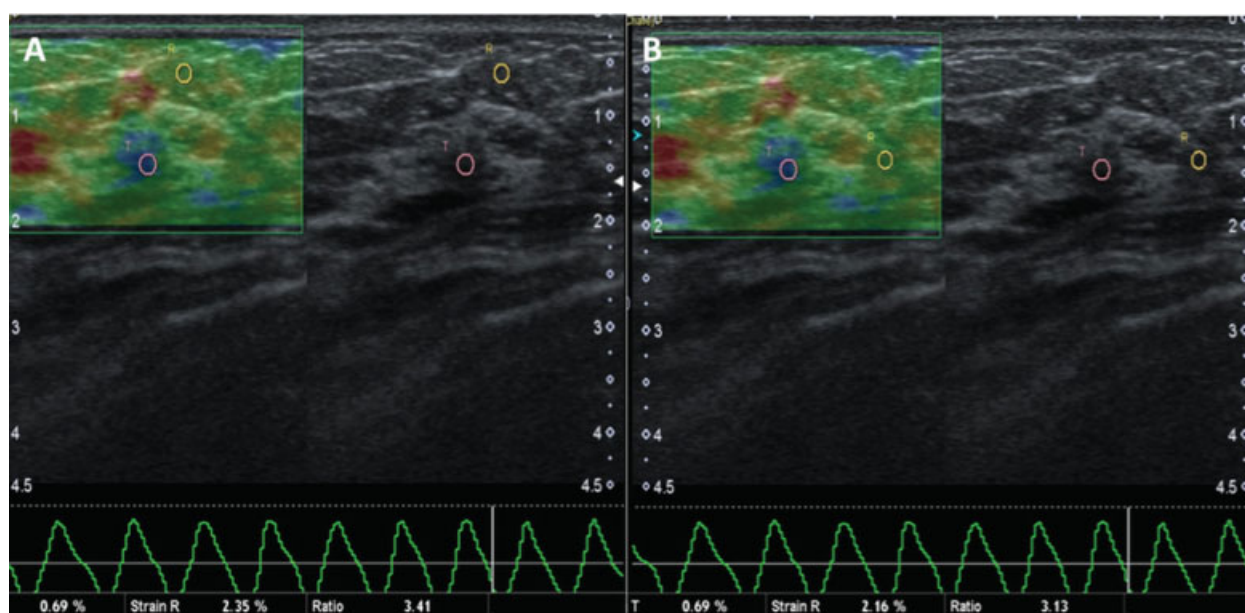


Fig. 2 Example of elastography analysis, showing a conventional ultrasound image on the right and an elastography image on the left, used for the qualitative analysis. For the semi quantitative analysis, regions of interest (ROI) are positioned on the lesion and on subcutaneous tissue (A) or adjacent fibroglandular tissue (B).

lesion stiffness, which is directly proportional to the probability of malignancy.¹²⁻¹⁴

The Statistical analysis was performed using softwares STATA 11 SE (StataCorp LP, College Station, TX, USA), SPSS 16.0 (IBM, Armonk City, NY, USA) and MedCalc 15.6.1 (MedCalc Software bvba, Ostend, Belgium). In order to evaluate the diagnostic accuracy of the elastography, the histological result was considered as the gold standard. The Receiver Operating Characteristic (ROC) curve was used to determine the cut-off points on the semi quantitative analysis of the elastography, including the evaluation of the area under the curve (AUC), the standard error (SE), the 95% confidence interval (CI) and the *p* value. The normality of the variables was tested by the Shapiro-Wilk test, and the associations were tested by chi-square test or Fisher's exact test when necessary. Continuous variables were evaluated using the unpaired T-Student, ANOVA and non-parametric Mann-Whitney and Kruskal-Wallis tests, with a 5% significance level. Therefore, the results were considered statistically significant when the value of *p* < 0.05.

Results

Sample Description

The mean age of the 125 included patients was 47 years (standard deviation: 11 years), ranging from 20 to 85 years. Most of the patients were aged less than 40 years (70.4%). Twenty-three patients (18.4%) had breast cancer family history, and 10 (8.0%) had a previous history of breast cancer. Six patients (4.8%) had breast implants. Ninety-seven patients (77.6%) had a single lesion, and 28 (22.4%) had more than one lesion in the breast.

We evaluated 159 indeterminate breast lesions at US: 46 (28.9%) were palpable, and 113 (71.1%) were non-palpable. The mean major size of the lesions was 15.6 mm (standard deviation: 11 mm), ranging between 3 mm and 68 mm. The morphological characteristics and BI-RADS category of the lesions are described in ►Table 1. ►Table 2 describes all histological biopsies results, used as reference.

►Table 3 shows the relationship of the BI-RADS categories with the histopathologic results. Of the 106 benign lesions at histology, 43 (40.6%) were classified as probably benign (BI-RADS 3), and 63 (59.4%) were classified as suspect (BI-RADS 4 or 5) on US. Of the 53 malignant lesions at histology, 52 lesions (98.0%) were classified as suspect (BI-RADS 4 or 5) and 1 lesion was classified as probably benign (BI-RADS 3) on US. Thus, using the BI-RADS classification, US showed a sensitivity of 98.1%, a specificity of 40.6%, a positive predictive value of 45.2%, a negative predictive value of 97.0%, and a diagnostic accuracy of 59.7%.

Elastography

The qualitative classification of the elastography based on the criteria of Itoh et al¹⁰ is described in ►Table 4. It was observed that 91.4% of patients classified as probably benign confirmed this diagnosis, while 68.2% of patients classified as suspicious for malignancy had their results confirmed (*p* < 0.01).

Table 1 Characteristics of the lesions on conventional ultrasonography, according to the BI-RADS lexicon (5th edition)

Characteristic	Frequency (n)	%
Lesion		
Mass	132	83.0
Others	27	17.0
Echo pattern		
Hypoechoic	125	78.6
Isoechoic	20	12.6
Hiperechoic	1	18.2
Heterogeneous	13	0.6
Shape		
Oval	85	53.5
Round	30	18.9
Irregular	44	27.7
Margin		
Circumscribed	64	40.2
Indistinct	43	27.0
Angular	11	6.9
Microlobulated	10	6.2
Spiculated	31	19.4
Orientation*		
Parallel	93	86.1
Not parallel	15	13.9
Posterior features		
None	120	75.5
Enhancement	31	19.5
Shadowing	8	5.0
BI-RADS		
3	44	27.7
4 a	32	20.1
4 b	36	22.6
4 c	13	8.2
5	34	21.4
Total	159	100

Abbreviation: BI-RADS, Breast Imaging Reporting and Data System.

Note: * Missing data for 51 patients.

In the semi quantitative analysis, malignant lesions had a mean compression ratio higher than the benign lesions, when compared with the subcutaneous tissue and when compared with the adjacent fibroglandular tissue (►Table 5). The ROC curve analysis (►Fig. 3) showed no significant difference on sensitivity and specificity for the diagnosis of malignant lesions (*p* = 0.77) between these ratios: lesion/subcutaneous tissue (AUC: 0.788; SE: 0.393; *p* < 0.0001; 95% CI: 0.715 to 0.849); and lesion/adjacent fibroglandular tissue (AUC: 0.799; SE: 0.375; *p* < 0.0001; 95% CI: 0.727 to 0.858).

Table 2 Histological diagnosis of benign and malignant breast lesions

Histological diagnosis	Frequency (n)	%
Benign lesions	106	66.7
Fibroadenoma	44	41.5
Stromal fibrosis	16	15.1
Papilloma	8	7.5
Fibrocystic changes	7	6.6
Malignant lesions	59	33.3
Invasive Carcinoma NST*	35	66
Ductal carcinoma in situ	8	15.1
Invasive lobular carcinoma	7	13.2
Papillary Carcinoma	1	1.9
Tubular Carcinoma	2	3.7

Note: * NST: no special type (ancient invasive ductal carcinoma).

Table 3 Correlation of histological results and BI-RADS classification on conventional ultrasonography

BI-RADS	Histological results	
	Benign (n)	Malignant (n)
3	43 (97.7%)	1 (2.3%)
4a	32 (100%)	0 (0%)
4b	27 (75%)	9 (25.0%)
4c	3 (23.1%)	10 (76.9%)
5	1 (2.9%)	33 (97.1%)
Total	106 (66.7%)	53 (33.3%)

Abbreviation: BI-RADS, Breast Imaging Reporting and Data System.

Table 4 Correlation of histological results and qualitative elastography analysis, according to Itoh et al criteria

Score	Histological results	Total	n (%)
	Benign n (%)	Malignant n (%)	
1	21 (100%)	0 (0%)	21 (13.2%)
2	55 (88.7%)	9 (11.3%)	62 (39.0%)
3	9 (90%)	1 (10%)	10 (6.3%)
4	21 (46.7%)	24 (53.3%)	45 (28.3%)
5	0 (0%)	21 (100%)	21 (13.2%)
Probably benign (1, 2 or 3)	85 (91.4%)	8 (8.6%)	93 (58.5%)
Suspicion of malignancy (4 or 5)	21 (31.8%)	45 (68.2%)	66 (41.5%)

Table 5 Correlation of histological results and semi quantitative elastography ratios

Ratios	Histological results		p
	Benign Mean (SD)	Malignant Mean (SD)	
Lesion/Adipose tissue*	3.69 (4.4)	8.28 (7.5)	< 0,001
Lesion/Adjacent fibroglandular tissue	2.15 (1.7)	7.18 (8.1)	< 0,001

Abbreviation: SD, standard deviation.

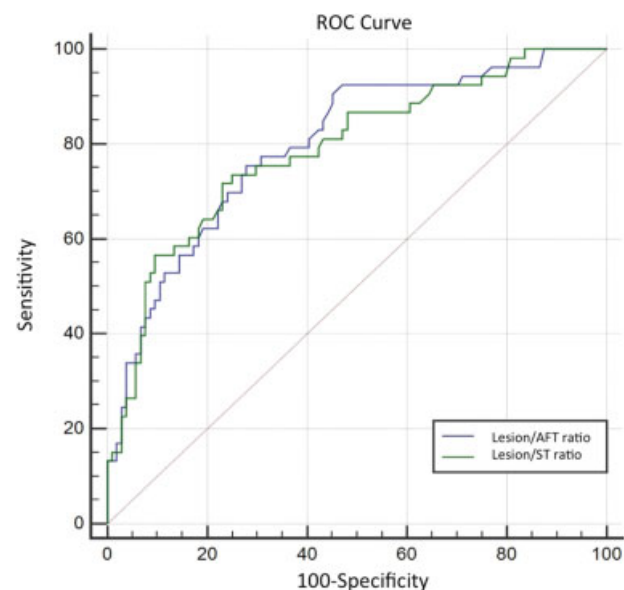
Note: * Data unknown for 2 patients (superficial lesions).

Using the data obtained by the ROC curve, the best cut-off points were 3.00 for the lesion/subcutaneous tissue ratio (sensitivity: 71.7%; specificity: 75.0%; accuracy: 73.9%) and 2.15 for the lesion/adjacent fibroglandular tissue ratio (sensitivity: 83.0%; specificity: 70.8%; accuracy: 72.3%).

Combination of Conventional Ultrasound and Elastography

For the combination of the findings of the elastography and the conventional US, the following criteria were considered:

- Probably benign US (BI-RADS 3) and probably benign elastography: probably benign combination;
- Probably benign US (BI-RADS 3) and suspicious elastography: suspicious for malignancy combination;
- Low-suspicion US (BI-RADS 4a) and probably benign elastography: probably benign combination (► Fig. 4);
- Low-suspicion US (BI-RADS 4a) and elastography suspicion: suspicious for malignancy combination;

**Fig. 3** Receiver Operating Characteristic (ROC) curve representing the diagnostic accuracy of the semi quantitative elastography analysis for the diagnosis of malignant breast lesions, using both the lesion/subcutaneous tissue (ST) ratio and the lesion/adjacent fibroglandular tissue (AFT) ratio.

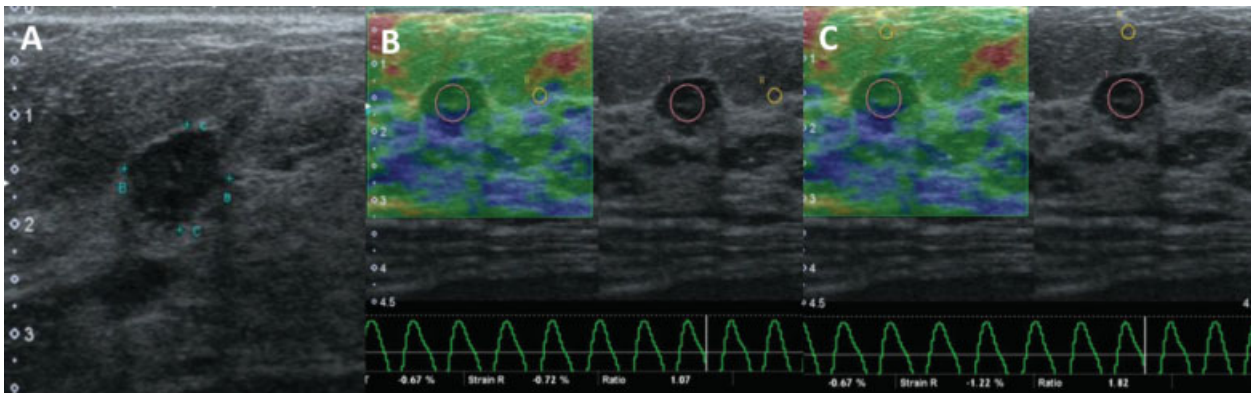


Fig. 4 Example of a suspicious finding at conventional ultrasound with probably benign findings in both qualitative and semi quantitative elastographies. Conventional ultrasonography showed a hypoechoic round mass, considered suspicious for malignancy (A). The qualitative elastography showed a score 2 based on the criteria of Itoh et al, and the semi quantitative analysis showed a lesion/subcutaneous tissue ratio of 1.82 (B) and a lesion/adjacent fibroglandular tissue ratio of 1.07 (C), suggesting a probably benign lesion. The histological results were compatible with fibroadenoma.

- Intermediate or high-suspicion US (BI-RADS 4b, 4c and 5), regardless of the elastography: suspicious for malignancy combination;

–**Table 6** describes the sensitivity, specificity, positive predictive value (PPV), negative predictive value (NPV) and accuracy for the conventional ultrasound, the qualitative and semi quantitative elastography analyses, and for their combination. Thus, we observed that the best results were obtained when using the findings of the combined conventional US and the qualitative elastography, with 100% sensitivity and 63.2% specificity (versus 40.6% on the conventional US).

Discussion

In the literature, the sensitivity and specificity of the elastography ranged from 72 to 83.3%, and from 86.7 to 98.5% respectively.^{10,11,13,15–18} In our study, the sensitivity (84.9%) was similar to the one found in the literature; however, the specificity (80.2%) was found to be slightly lower. Still, the

association of the US with the elastography showed an increase in specificity and diagnostic accuracy when compared with the isolated conventional US assessment. Similar findings observed in the literature showed that combined conventional US and elastography present a sensitivity of 89.1 to 96.9%, and a specificity of 50.5 to 95.7%.³

Studies that assessed semi quantitative elastography had different approaches, using subcutaneous adipose tissue and/or adjacent fibroglandular tissue to assess the lesion compressibility ratio. The subcutaneous fat was considered the most suitable for the calculation of the deformity, because it is not influenced by other factors such as breast density, hormonal status, lactation and cycle phase.^{3,14,19–21} In a study published by Zhou et al,²² the lesion/adipose tissue ratio (with a cut-off point of 2.78) showed 82.9% sensitivity and 75.6% specificity, while the lesion/glandular tissue ratio (with a cut-off point of 1.54) showed a sensitivity of 77.1% and a specificity of 65.9%.²² Similarly, in the present study, the lesion/subcutaneous tissue ratio showed slightly superior results than the lesion/adjacent fibroglandular tissue ratio; however, this difference was not statistically significant.

Table 6 Sensitivity, specificity, positive predictive value (PPV), negative predictive value (NPV) and accuracy of conventional ultrasound, qualitative and semi quantitative elastography analysis, and combination of these methods

Method	Sensibility	Specificity	PPV	NPV	Accuracy
Conventional ultrasound	98.1%	40.6%	45.2%	97.7%	69.7%
Qualitative elastography	84.9%	80.2%	68.2%	91.4%	81.8%
Lesion/subcutaneous tissue ratio	71.7%	75.0%	59.4%	83.9%	73.9%
Lesion/adjacent fibroglandular tissue ratio	83.0%	70.8%	56.3%	85.2%	72.3%
Combined conventional ultrasound and qualitative elastography	100%	63.2%	57.6%	100%	75.5%
Combined conventional ultrasound and lesion/subcutaneous tissue ratio	98.1%	53.8%	51.5%	98.3%	68.6%
Combined conventional ultrasound and lesion/adjacent fibroglandular tissue ratio	100%	55.6%	53.0%	100%	70,4%

Abbreviations: NPV, negative predictive value; PPV, positive predictive value.

Our results showed that the qualitative analysis of the elastography showed better results than the semi quantitative assessment, regardless of the approach used. These data are consistent with the findings published by Stachs et al.²³

It is worth mentioning that elastography can also have false-negative and false-positive results. Not all cancers are more rigid than the healthy tissue, and the stiffness is different depending on the type of histological and clinical presentations, such as the association with necrosis, which can make them softer.²⁴ Furthermore, elastography has some limitations, such as the size of the lesion: the higher the lesion, the less accurate is the elastography, with a higher performance on lesions smaller than 1 cm.²⁵

Due to the high percentage of malignancy in lesions in categories 4b, 4c and 5 BI-RADS, biopsy should always be performed, regardless of the finding of the elastography. However, in lesions with low suspicion for malignancy (BI-RADS 3 and 4a), elastography can help define the best management, reducing the number of false-negative and false-positive results.

In our study, only one probably benign (BI-RADS 3) lesion on conventional US was diagnosed as malignant on biopsy. However, this lesion showed suspicious findings in the elastography, and that could be used to reclassify it as BI-RADS 4a, which would avoid a delay in diagnosis. Moreover, in our sample, ~ 84% of lesions classified as BI-RADS 4a on conventional US had probably benign findings in the elastography, and could be reclassified as BI-RADS 3, reducing the number of unnecessary biopsies in this group. For Raza et al,²⁶ all BI-RADS 4a lesions classified as probably benign in the elastography have benign histological diagnoses.

This study has some limitations. Because we used only one observer, it was not possible to evaluate the variability of the interpretation of the elastography, which may be a challenge in the clinical practice, where there are sonographers with varying levels of experience. Moreover, we did not assess the influence of breast size, lesion depth or proximity to the papilla in the elastography results.

It is important to emphasize that elastography is a complementary tool for US examination, and should not be used as a single method; the final diagnosis should always be done in combination with the morphological characteristics. In addition, in patients with lesions of intermediate suspicion in the conventional US, with a benign histological result after the percutaneous biopsy, the elastography findings could help in the radio-pathological correlation. Therefore, we believe that this method has the potential to effectively improve the management of breast lesions.

In conclusion, elastography can be a useful complementary method, increasing the level of confidence in the final evaluation of breast lesions at US. The results presented in this study showed that elastography may increase the specificity and diagnostic accuracy of conventional US for the diagnosis of breast cancer in patients with indeterminate breast lesions. The combination of conventional US and qualitative elastography showed higher specificity and accuracy values, without reducing the sensitivity in our sample, and it could be used to decrease unnecessary biopsy rates.

References

- 1 Wojcinski S, Boehme E, Farrokh A, Soergel P, Degenhardt F, Hillmann P. Ultrasound real-time elastography can predict malignancy in BI-RADS®-US 3 lesions. *BMC Cancer* 2013;13(1):159
- 2 Zhi H, Xiao XY, Ou B, et al. Could ultrasonic elastography help the diagnosis of small (≤ 2 cm) breast cancer with the usage of sonographic BI-RADS classification? *Eur J Radiol* 2012;81(11):3216–3221
- 3 Lee JH, Kim SH, Kang BJ, et al. Role and clinical usefulness of elastography in small breast masses. *Acad Radiol* 2011;18(1):74–80
- 4 Balleyguier C, Ciolovan L, Ammari S, et al. Breast elastography: the technical process and its applications. *Diagn Interv Imaging* 2013;94(5):503–513
- 5 Barr RG. Sonographic breast elastography: a primer. *J Ultrasound Med* 2012;31(5):773–783
- 6 Ricci P, Maggini E, Mancuso E, Lodise P, Cantisani V, Catalano C. Clinical application of breast elastography: state of the art. *Eur J Radiol* 2014;83(3):429–437
- 7 Yerli H, Yılmaz T, Ural B, Gülay H. The diagnostic importance of evaluation of solid breast masses by sonoelastography. *Ulus Cerrahi Derg* 2013;29(2):67–71
- 8 Yoon JH, Kim MH, Kim EK, Moon HJ, Kwak JY, Kim MJ. Interobserver variability of ultrasound elastography: how it affects the diagnosis of breast lesions. *AJR Am J Roentgenol* 2011;196(3):730–736
- 9 Chang JM, Won JK, Lee KB, Park IA, Yi A, Moon WK. Comparison of shear-wave and strain ultrasound elastography in the differentiation of benign and malignant breast lesions. *AJR Am J Roentgenol* 2013;201(2):W347–56
- 10 Itoh A, Ueno E, Tohno E, et al. Breast disease: clinical application of US elastography for diagnosis. *Radiology* 2006;239(2):341–350
- 11 Kumm TR, Szabunio MM. Elastography for the characterization of breast lesions: initial clinical experience. *Cancer Contr* 2010;17(3):156–161
- 12 Goddi A, Bonardi M, Alessi S. Breast elastography: A literature review. *J Ultrasound* 2012;15(3):192–198
- 13 Carlsen JF, Ewertsen C, Lönn L, Nielsen MB. Strain elastography ultrasound: an overview with emphasis on breast cancer diagnosis. *Diagnostics (Basel)* 2013;3(1):117–125
- 14 Thomas A, Degenhardt F, Farrokh A, Wojcinski S, Slowinski T, Fischer T. Significant differentiation of focal breast lesions: calculation of strain ratio in breast sonoelastography. *Acad Radiol* 2010;17(5):558–563
- 15 Schaefer FKW, Heer I, Schaefer PJ, et al. Breast ultrasound elastography—results of 193 breast lesions in a prospective study with histopathologic correlation. *Eur J Radiol* 2011;77(3):450–456
- 16 Tan SM, Teh HS, Mancor JFK, Poh WT. Improving B mode ultrasound evaluation of breast lesions with real-time ultrasound elastography—a clinical approach. *Breast* 2008;17(3):252–257
- 17 Tardivon A, El Khoury C, Thibault F, Wyler A, Barreau B, Neuenschwander S. [Elastography of the breast: a prospective study of 122 lesions]. *J Radiol* 2007;88(5 Pt 1):657–662
- 18 Thomas A, Fischer T, Frey H, et al. Real-time elastography—an advanced method of ultrasound: First results in 108 patients with breast lesions. *Ultrasound Obstet Gynecol* 2006;28(3):335–340
- 19 Cho N, Moon WK, Park JS, Cha JH, Jang M, Seong MH. Nonpalpable breast masses: evaluation by US elastography. *Korean J Radiol* 2008;9(2):111–118
- 20 Barr RG, Nakashima K, Amy D, et al. WFUMB guidelines and recommendations for clinical use of ultrasound elastography: Part 2: breast. *Ultrasound Med Biol* 2015;41(5):1148–1160
- 21 Farrokh A, Wojcinski S, Degenhardt F. [Diagnostic value of strain ratio measurement in the differentiation of malignant and benign breast lesions]. *Ultraschall Med* 2011;32(4):400–405
- 22 Zhou J, Zhou C, Zhan W, Jia X, Dong Y, Yang Z. Elastography ultrasound for breast lesions: fat-to-lesion strain ratio vs gland-to-lesion strain ratio. *Eur Radiol* 2014;24(12):3171–3177

- 23 Stachs A, Hartmann S, Stubert J, et al. Differentiating between malignant and benign breast masses: factors limiting sonoelastographic strain ratio. *Ultraschall Med* 2013;34(2):131–136
- 24 Fleury EdeF, Assunção-Queiros MdoC, Roveda D Jr. Breast carcinomas: variations in sonoelastographic appearance. *Breast Cancer (Dove Med Press)* 2014;6:135–143
- 25 Chang JM, Moon WK, Cho N, Kim SJ. Breast mass evaluation: factors influencing the quality of US elastography. *Radiology* 2011;259(1):59–64
- 26 Raza S, Odulate A, Ong EMW, Chikarmane S, Harston CW. Using real-time tissue elastography for breast lesion evaluation: our initial experience. *J Ultrasound Med* 2010;29(4):551–563