

Safety and Effectiveness of Transarterial Embolization for Blunt Abdominal Injuries: A Multicenter Study with Review of Literature

Mathew Cherian¹ Tejas Kalyanpur¹ Krishna Swami Murali² Ashwin Garg³ Yadav Munde⁴
Ajit Yadav⁵ Arun Gupta⁵ Sibasankar Dalai⁶ Paresh Desai⁷ Prithviraj Jadhav⁸

¹ Department of Radiology, Kovai Medical Center and Hospital, Coimbatore, India

² Department of Interventional Radiology, Vijaya Health Center, Chennai, India

³ Maharaja Agrasen Hospital, New Delhi, India

⁴ Department of Interventional Radiology, Ruby Hall Clinic, Pune, India

⁵ Department of Interventional Radiology, Sir Ganga Ram Hospital, Delhi, India

⁶ Department of Interventional Radiology, Seven Hills Hospital, Visakhapatnam, India

⁷ Department of Diagnostic and Interventional Radiology, Apollo Victor Hospital, Goa, India

⁸ Department of Interventional Radiology, Aster Aadhaar Hospital, Kolhapur, India

Address for correspondence Mathew Cherian, MD, Department of Radiology, Kovai Medical Center and Hospital, P.B. No. 3209, Avanashi Road, Coimbatore 641014, India
(e-mail: dr.mathewcherian@gmail.com).

J Clin Interv Radiol ISVIR 2017;1:13–19.

Abstract

Aims To evaluate the safety and effectiveness of transarterial embolization for blunt abdominal trauma in patients without the imaging signs of peritonitis or bowel injury.

Materials and Methods A total of 45 patients (41 males and 4 females; mean age: 32.15) were studied, of which 48% were hemodynamically unstable. All patients underwent multidetector computed tomography prior to selective angiography and embolization. Outcomes were considered as favorable if embolization was successful in achieving hemostasis. The frequency of complications, mortality rates, and duration of hospital stay were calculated.

Results Embolization was successful in achieving hemostasis in all patients. None of the patients required surgery to achieve hemostasis after embolization. The overall mortality rate was 13.3% and none related to persistent bleeding. The mean intensive care unit stay was 5.6 days and the median was 3.5 days. Only one patient required continued blood transfusion of more than 10 units after embolization. No major complications were encountered except for one patient who required hemodialysis for acute renal injury related to embolization procedure.

Conclusion Transarterial embolization is very effective in treating bleeding related to blunt abdominal trauma even in hemodynamically unstable patients and is associated with minimal complications. Embolization should be considered as an integral part of resuscitative measures for bleeding related to trauma.

Keywords

- ▶ embolization
- ▶ trauma
- ▶ abdomen

Introduction

Trauma is one of the leading causes of death with abdominal organ injuries implicated in 20 to 30%.¹ Massive uncontrolled

blood loss is one of the commonest cause of death in poly-trauma.² If ongoing hemorrhage can be controlled, we can not only save lives but also reduce morbidity associated with emergency unplanned surgeries. Arterial embolization (AE)



has the potential of achieving hemostasis even at multiple bleeding sites from a single access point while maintaining the natural tamponade effect of closed space bleeding that is often lost during open surgery. Paralleling the refinements in concepts of AE, newer concepts such as damage control surgery have emerged for hemodynamically unstable patients. However, surgery may be a difficult proposition in patients with severe coagulopathy, which is frequently associated with massive hemorrhage. In addition, a recent meta-analysis concluded no definitive advantage of damage control surgery with respect to traditional laparotomy in patients with major abdominal trauma.³ Endovascular embolization is fast and associated with less morbidity,⁴ and even if it fails, the procedure can be repeated or emergency surgery can be postponed to an elective surgery. Endovascular management of blunt trauma to the abdominal solid organs is the standard of care for hemodynamically stable patients without signs of peritonitis.⁵⁻⁷ However, surgery is still considered the gold standard in treatment of hemodynamically unstable patients.⁸ Early imaging in trauma is as vital as the resuscitation itself. Meta-analysis of reported data suggests that the application of early whole-body computed tomography (CT) significantly reduces the mortality rate in major trauma as compared with conventional Advanced Trauma Life Support protocols.⁹ Whole-body multidetector CT (MDCT) not only accurately depicts the exact site of bleeding but also provides an angiographic road map that obviates the needs for exploratory angiography.

In this multicenter study, we evaluated the safety and effectiveness of transarterial embolization for bleeding secondary to blunt abdominal trauma in both hemodynamically stable and hemodynamically unstable patients.

Materials and Methods

This multicenter retrospective study included all patients who presented to the emergency room at eight major centers over a 4-year period. All patients had blunt abdominal trauma and were referred for endovascular embolization. Demographic data including age and gender, and data related to mechanism of injury were collected. All patients underwent MDCT examination with calculation of the Injury Severity Score (ISS). The time delay from the time of injury to the presentation at the hospital and blood pressure (BP) at presentation were recorded. All patients underwent selective angiography and superselective embolization by interventional radiologists with more than a decade of experience. The injured organ, exact site of bleeding, effect of embolization procedure and the BP after the embolization procedure, and change in inotropic supports were recorded. The patients were followed until discharge from the hospital for recurrent bleeding and any surgical interventions to arrest bleeding. The safety of embolization procedure was assessed by calculating the frequency of intraprocedure and postprocedure complications related to the embolization procedure, included bleeding, vessel injury, nontarget embolization, organ dysfunction, and infection or abscess formation. The effectiveness of embolization was assessed by calculating the duration of in-hospital stay following embolization procedure, recurrent bleeding, overall mortality, and bleeding-related mortality.

Results

Forty-five patients (41 men) were included in this study. Of them, 2 patients were in the age group of <10 years, 9 (17.7%) in the age group of 11 to 20 years, 14 (35%) were in the age group of 21 to 30 years, 8 (17.7%) in the age group of 31 to 40 years, 6 in the age group of 41 to 60 years, and 6 were more than 60 years. Forty-three (95.7%) patients were victims of road traffic accidents. The mean time lapse in transportation of patients from the site of trauma to the hospital was 4 hours.

Hemodynamic Status at the Time of Presentation and after Embolization

Twenty-two (48%) patients presented to the emergency room with a systolic BP of less than 90 mm Hg. Four (8.88%) patients had no recordable diastolic BP. Nineteen patients (42%) had a systolic BP of more than 100 mm Hg. Twenty-six patients were on inotropic support at the time of embolization.

Postembolization, there was significant improvement in systolic BP to more than 100 mm Hg in 90% of patients (23 of the 26 patients who were on inotropes).

Organ Injuries

Liver was the most commonly injured organ, with a maximum of 19 hepatic arteries embolized (► Fig. 1), followed by the internal iliac arteries ($n = 9$), splenic ($n = 4$) and mesenteric arteries ($n = 4$) (► Fig. 2), and a muscular branch of the lateral circumflex iliac ($n = 1$). Of the 45 patients, 30 had active extravasation of contrast material during CT angiography and 15 had pseudoaneurysms. None of the patients had arteriovenous fistulas. Four patients had multivessel embolization and the vessels embolized were hepatic, splenic, and mesenteric arteries. One of the patients had additional involvement of the circumflex iliac artery. Forty patients had presented with ISS of more than 45, maximum being 67. The embolic materials used were pushable coils, polyvinyl alcohol particles, Gelfoam, and n-butylcyanoacrylate.

Effectiveness of Arterial Embolization

Requirement of surgery to achieve hemostasis was considered an indicator of successful embolization. None of the patients required surgery for target organ after embolization. Two patients had undergone surgery prior to embolization (explorative laparotomy with splenectomy and liver packing in one and liver packing alone in the other) and continued to be hemodynamically unstable. Repeat CT demonstrated active extravasation from the hepatic arteries that were successfully embolized in both the patients.

Blood Transfusions

One (2.2%) patient required a massive transfusion of more than 10 units prior to embolization. Three patients required 10 units prior to embolization. Average units transfused were 3.6 units per patient along with other blood products such as fresh frozen plasma.

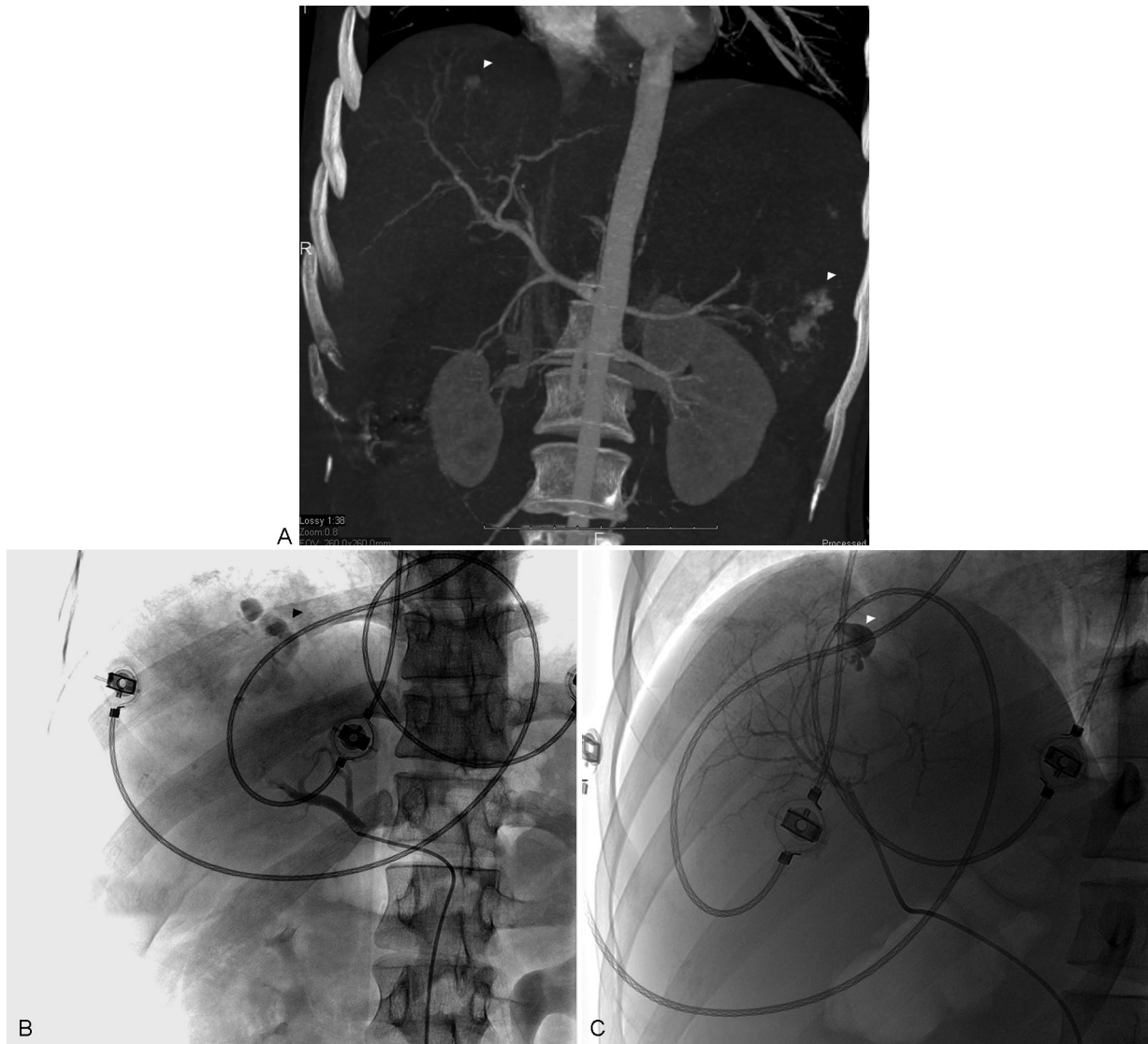


Fig. 1 (A) Computed tomography shows active extravasation from the liver and spleen. (B) Hepatic angiography shows active extravasation of contrast material from segment 8. (C) Postembolization angiography shows no further bleeding.

Hospital Stay

The average intensive care unit (ICU) stay was 5.2 days with a maximum of 28 days. Three patients required a stay of more than 10 days secondary to acute renal failure postembolization. Out of them, two patients had low effective glomerular filtration rate (EGFR) prior to the procedure. Both the patients died due to septic shock and multiorgan failure. One patient had a single functioning kidney with pseudoaneurysm that was superselectively embolized. The patient recovered completely after short-term hemodialysis.

Outcomes

Of the 45 patients, 6 patients died resulting in a mortality rate of 13.3%. Three patients died of septic shock, one died of disseminated intravascular coagulation (DIC), and two died of severe intracranial injuries. Thirty-nine patients (86.7%) survived and were ambulatory at the time of discharge.

Discussion

The last decade has shown an increasing trend toward nonoperative management in trauma. Nonoperative management consists of observation, supportive care, and the use of arteriography and embolization for hemostasis. The goal of present-day treatment approach for any trauma is organ preservation while assuring patient safety. Superselective embolization can be safely used in hemodynamically stable patients in the absence of associated hollow visceral injuries and lack of peritoneal signs on abdominal examination. Several recent reports have shown that hemodynamically unstable patients with abdominal solid organ injuries may be successfully managed using nonoperative methods. As early as 2004, Hagiwara et al showed that transarterial embolization could be performed safely for patients with blunt trauma who were in hemorrhagic hypotension if their hemodynamics could be improved by initial fluid resuscitation.¹⁰

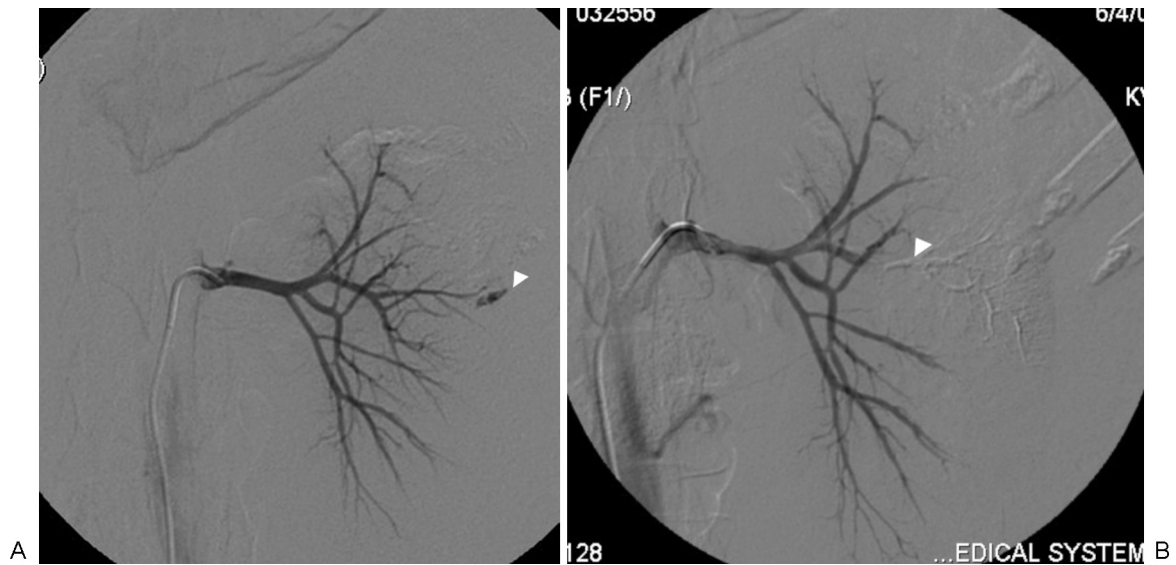


Fig. 2 (A) Selective left renal angiography shows active extravasation of contrast material from left interpolateral renal artery following penetrating trauma. (B) The bleeding artery was embolized with 30% n-butylcyanoacrylate.

Hepatic Injuries

More than 80% of patients with blunt hepatic injury can be treated nonoperatively obviating the need for operative intervention.^{11–13} AE is the procedure of choice in hemodynamically stable patients with active bleeding demonstrable on CT. Although hemodynamic instability has been considered as one of the best predictors of the need for operative management, recent studies have shown that AE can be effectively performed in hemodynamically unstable patients with success rates of 93%¹⁴ (►Fig. 1). van der Wilden et al in their multicenter study showed that AE can be safely performed even in grade IV and grade V blunt liver injuries, with a 91.3% success rate. They attributed the higher successful outcomes of nonoperative management to nearly quarter of patients that underwent immediate embolization.¹⁵

In our study, hepatic injuries constituted 42% of all injuries, and superselective embolization of the hepatic artery was performed in all cases. Technical success was achieved in all, with none of the patients requiring surgery to arrest bleeding. AE may be the last resort for failed surgeries.

Delayed bleeding, biliary injury (bile leak, biloma), infection (hepatic and perihepatic abscesses), cholecystitis, and liver failure are possible complications of embolization. Complication rates in liver trauma patients treated nonoperatively was 27.2% as compared with 50% in patients who underwent surgical hemostasis, with an overall failure rate was 3.7%.¹⁶

Splenic Injuries

Nonoperative management can be considered in all hemodynamically stable patients regardless of the grade of injury. In 2013, participants of the “Evidence Based Telemedicine – Trauma and Acute Care Surgery” (EBTACS) Group conducted a critical review of the literature on the management of high-grade splenic injuries. They concluded that AE should be performed in all patients with contrast blush on initial CT

scan subjected to selective nonoperative management after splenic injury. When AE was not performed, the failure rate of nonoperative management was 71%¹⁷ (►Fig. 3).

All four patients in our study who underwent splenic artery embolization had other injuries that were also embolized in the same sitting. Although surgery continues to remain the standard of care in hemodynamically unstable patients, studies with small sample size have shown that AE can be used in hemodynamically unstable patients. Hagiwara et al showed that AE could be effective in treating unstable patients who were transient responders to fluid resuscitation.¹⁸

Lin et al in their series of 13 patients showed that splenic AE is safe and effective even in hemodynamically unstable patients.¹⁹ Proximal AE can also be performed in patients with a high risk for secondary rupture of the spleen to reduce the pressure in the splenic parenchyma, which can help in healing of the laceration. Wahl et al in their series compared embolization to surgery and demonstrated a significantly lower number of complications in the embolization group (13%) than the operative group (29%).²⁰ The failure rates vary in literature with a recent study showing only 3% in the entire group, although it was 6% in patients with grade IV and grade V spleen injuries.²¹ However, the opinions are divided regarding complication rates between proximal and distal splenic embolization and there has been no consensus as to which reduces the complications while ensuring hemostasis.²² Major complications can occur in up to 14% of patients and include splenic abscesses, infarction, cysts, and contrast-induced renal insufficiency.²³ No major complications were seen in our series.

Renal Injuries

AE is increasingly accepted for treating ongoing bleeding without surgical exploration with surgical intervention

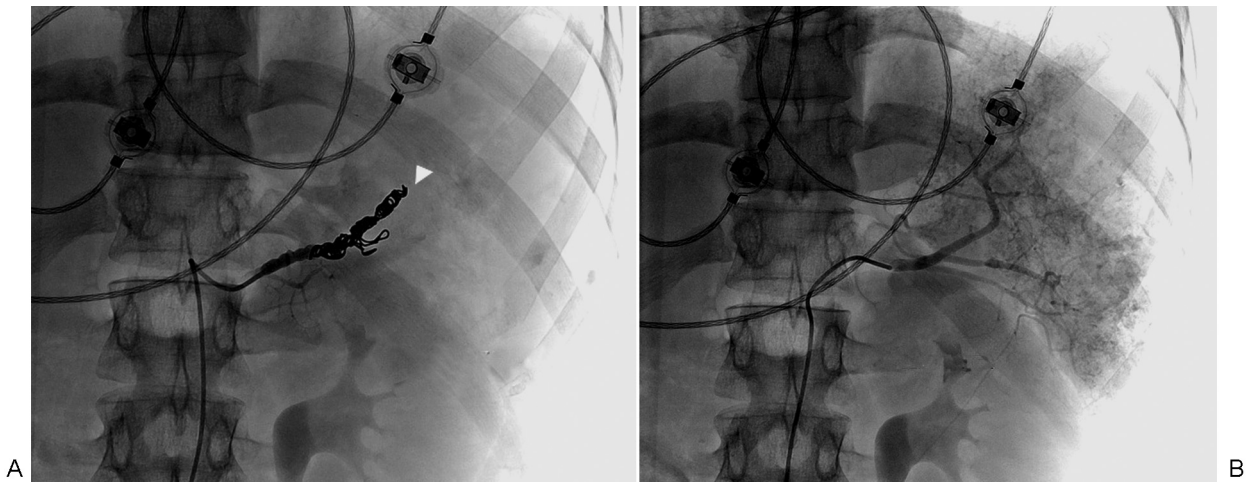


Fig. 3 (A) Angiography shows no extravasation. (B) Preemptive embolization of the main splenic artery was performed based on the computed tomography findings.

being essential in only 5 to 10%. Nephrectomy may be an inevitable outcome when hemodynamically unstable patients undergo surgical exploration.^{24,25} Hemodynamically unstable patient with active extravasation of intravenous contrast material demands immediate intervention; however, the guidelines again are indecisive about the choice of procedure, whether surgical exploration or angioembolization. Shoobridge et al reported that these injuries could now be managed with embolization.²⁶ The absolute indications for renal exploration are persistent, life-threatening hemorrhage from renal injury, renal pedicle avulsion (Grade V injury), and expanding, pulsatile, or uncontained retroperitoneal hematoma.

Success rates reported are high in patients undergoing angiography and embolization as primary management.²⁷ Frequently, an additional procedure may be required in 88.3% of cases to avoid nephrectomy especially in penetrating trauma²⁸ (→ Fig. 2). In a series of hemodynamically unstable patients with grade V injuries, one study reported 100% technical and clinical success with none of the patients requiring further intervention.²⁹

Saour M et al studied the effects of embolization on renal function and concluded that renal AE did not seem to significantly affect the occurrence and course of acute kidney injury or renal recovery.³⁰

Three patients in our series had acute renal failure postembolization. Two patients had low EGFR prior to embolization and both died due to septic shock and multiorgan failure. One patient had a single functioning kidney with pseudoaneurysm that was superselectively embolized and the patient required temporary hemodialysis postprocedure.

Pelvic Injuries with Internal Iliac Artery Bleeding

The mortality rates of hemodynamically unstable patients with pelvic fractures are high. In case of life-threatening hemodynamic instability and failure to find an arterial

lesion, temporary nonselective embolization of both internal iliac arteries may be performed. Success rates for AE for pelvic fractures are 80 to 100%.³¹ Level I recommendation exists for pelvic angiography and embolization when arterial contrast extravasation occurs regardless of hemodynamic status. There is a level II recommendation for repeat pelvic angiography and embolization if the first procedure has failed in achieving hemostasis.³¹ Pelvic fractures were common in our series, with internal iliac artery being the second most common artery embolized. All patients responded to embolization with none requiring second procedure.

Mesenteric Artery Injuries

Mesenteric artery injury is not uncommon in trauma,³² although we had only one patient with injury to the mesenteric vessel along the ileocolic arcade. The patient had associated injury to the spleen and liver. Embolization of these vessels requires careful angiographic evaluation of the both proximal and distal segments to ensure that bleeding does not recur from either end (→ Fig. 4).

Eventual Outcomes

In our study, nearly 50% of the patients were hemodynamically unstable at the time of presentation, and embolization was 100% successful with no patient requiring surgery to achieve hemostasis. The overall mortality rate was 13.3%, none of which was due to persistent or recurrent bleeding. Of the patients who died, three deaths were due to of septic shock, one due to DIC, and two due to severe intracranial injuries. The remaining 86.7% survived and were ambulatory at the time of discharge. The average ICU stay was 5.2 days, with only one patient requiring transfusion of more than 10 units. These findings suggest that angioembolization can be successfully employed for blunt traumatic injuries of the abdomen both in hemodynamically stable and hemodynamically unstable patients.

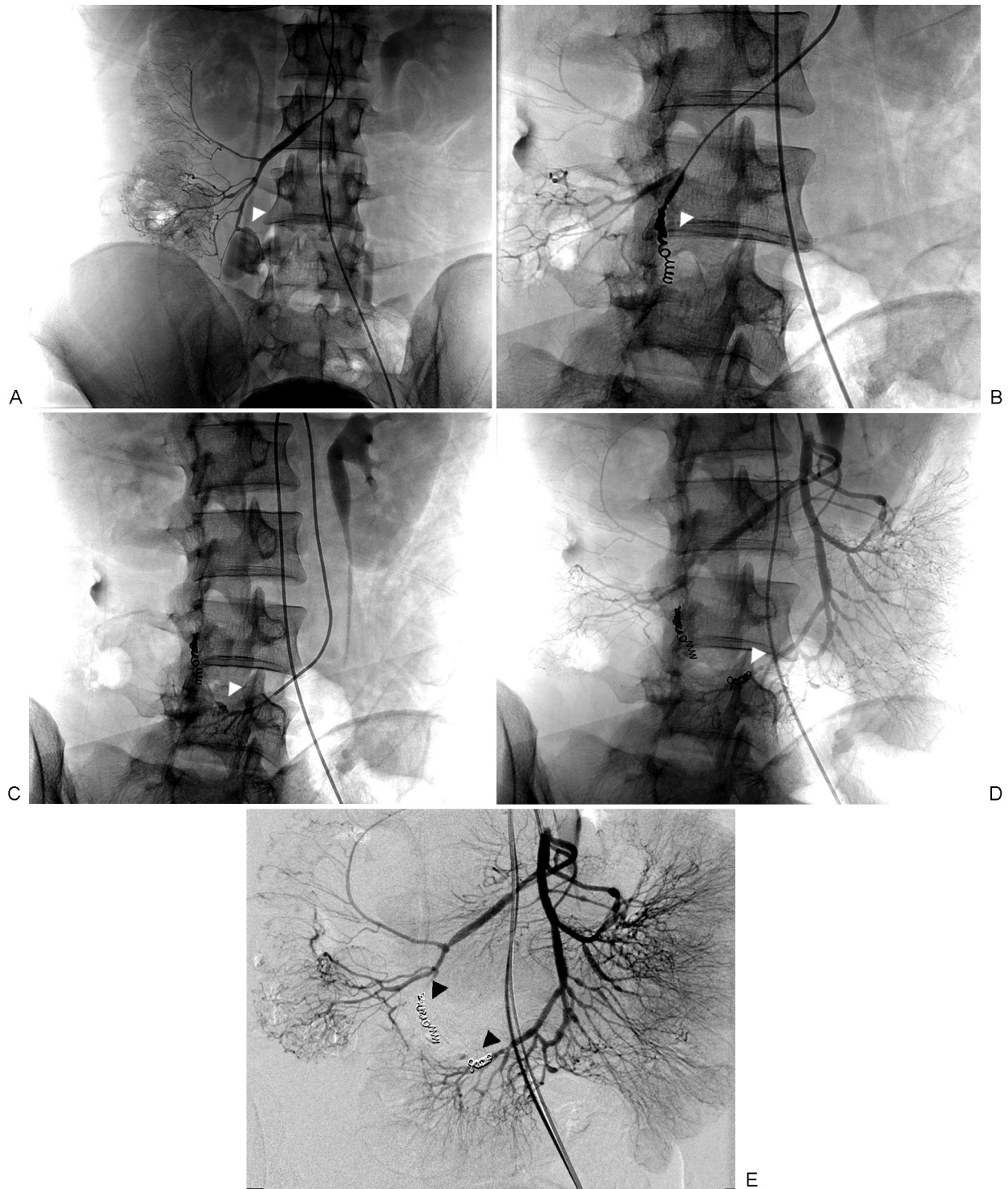


Fig. 4 (A) Selective ileocolic angiography shows active extravasation from a disrupted ileocolic arcade. (B) The artery was embolized with 0.018" coils. (C) Additional injection in the last ileal branch shows disruption with active extravasation of contrast material. (D) The artery was also embolized to ensure complete hemostasis. (E) Proximal superior mesenteric artery angiography shows the final result of embolization.

Limitations and Conclusions

Although the study by itself cannot make recommendations and draw definitive conclusions largely due to its small sample size, it surely questions the guidelines on the management of trauma purely based on hemodynamic status of

patients. With increasing availability of interventional radiology resources and better planning of location of interventional radiology suites closer to the emergency rooms and CT suites, AE should be considered as an integral part of resuscitative measures and should be considered as the first-line management for hemostasis even in unstable patients.

References

- 1 Centers for Disease Control and Prevention. "Leading Causes of Death." Available at https://www.cdc.gov/nchs/data/nvsr/nvsr65/nvsr65_05.pdf. October 22, 2014
- 2 Lopera JE. Embolization in trauma: principles and techniques. *Semin Intervent Radiol* 2010;27(1):14–28
- 3 Cirocchi R, Abraha I, Montedori A, et al. Damage control surgery for abdominal trauma. *Cochrane Database Syst Rev* 2013;1:CD007438
- 4 Sartorelli KH, Frumiento C, Rogers FB, Osler TM. Nonoperative management of hepatic, splenic, and renal injuries in adults with multiple injuries. *J Trauma* 2000;49(1):56–61, discussion 61–62
- 5 Stassen NA, Bhullar I, Cheng JD, et al; Eastern Association for the Surgery of Trauma. Selective nonoperative management of blunt splenic injury: an Eastern Association for the Surgery of Trauma practice management guideline. *J Trauma Acute Care Surg* 2012;73(5, Suppl 4):S294–S300
- 6 Stassen NA, Bhullar I, Cheng JD, et al; Eastern Association for the Surgery of Trauma. Nonoperative management of blunt hepatic injury: an Eastern Association for the Surgery of Trauma practice management guideline. *J Trauma Acute Care Surg* 2012;73(5, Suppl 4):S288–S293
- 7 Morey AF, Brandes S, Dugi DD III, et al; American Urological Association. Urotrauma: AUA guideline. *J Urol* 2014;192(2):327–335
- 8 Wallis A, Kelly MD, Jones L. Angiography and embolisation for solid abdominal organ injury in adults - a current perspective. *World J Emerg Surg* 2010;5:18
- 9 Caputo ND, Stahmer C, Lim G, Shah K. Whole-body computed tomographic scanning leads to better survival as opposed to selective scanning in trauma patients: a systematic review and meta-analysis. *J Trauma Acute Care Surg* 2014;77(4):534–539
- 10 Hagiwara A, Murata A, Matsuda T, Matsuda H, Shimazaki S. The usefulness of transcatheter arterial embolization for patients with blunt polytrauma showing transient response to fluid resuscitation. *J Trauma* 2004;57(2):271–276, discussion 276–277
- 11 Petrowsky H, Raeder S, Zuercher L, et al. A quarter century experience in liver trauma: a plea for early computed tomography and conservative management for all hemodynamically stable patients. *World J Surg* 2012;36(2):247–254
- 12 Leppäniemi AK, Mentula PJ, Streng MH, Koivikko MP, Handolin LE. Severe hepatic trauma: nonoperative management, definitive repair, or damage control surgery? *World J Surg* 2011;35(12):2643–2649
- 13 Kozar RA, McNutt MK. Management of adult blunt hepatic trauma. *Curr Opin Crit Care* 2010;16(6):596–601
- 14 Monnin V, Sengel C, Thony F, et al. Place of arterial embolization in severe blunt hepatic trauma: a multidisciplinary approach. *Cardiovasc Intervent Radiol* 2008;31(5):875–882
- 15 van der Wilden GM, Velmahos GC, Emhoff T, et al. Successful nonoperative management of the most severe blunt liver injuries: a multicenter study of the research consortium of new England centers for trauma. *Arch Surg* 2012;147(5):423–428
- 16 Bala M, Gazalla SA, Faroja M, et al. Complications of high grade liver injuries: management and outcome with focus on bile leaks. *Scand J Trauma Resusc Emerg Med* 2012;20:20
- 17 Branco BC, Tang AL, Rhee P, et al. Selective nonoperative management of high grade splenic trauma. *Rev Col Bras Cir* 2013;40(3):246–250
- 18 Hagiwara A, Fukushima H, Murata A, Matsuda H, Shimazaki S. Blunt splenic injury: usefulness of transcatheter arterial embolization in patients with a transient response to fluid resuscitation. *Radiology* 2005;235(1):57–64
- 19 Lin WC, Chen YF, Lin CH, et al. Emergent transcatheter arterial embolization in hemodynamically unstable patients with blunt splenic injury. *Acad Radiol* 2008;15(2):201–208
- 20 Wahl WL, Ahrns KS, Chen S, Hemmila MR, Rowe SA, Arbabi S. Blunt splenic injury: operation versus angiographic embolization. *Surgery* 2004;136(4):891–899
- 21 Bhullar IS, Frykberg ER, Tepas JJ III, Siragusa D, Loper T, Kerwin AJ. At first blush: absence of computed tomography contrast extravasation in grade IV or V adult blunt splenic trauma should not preclude angioembolization. *J Trauma Acute Care Surg* 2013;74(1):105–111, discussion 111–112
- 22 Sosada K, Wiewióra M, Piecuch J. Literature review of non-operative management of patients with blunt splenic injury: impact of splenic artery embolization. *Wideochir Inne Tech Malo Inwazyjne* 2014;9(3):309–314
- 23 Ekeh AP, Khalaf S, Ilyas S, Kauffman S, Walusimbi M, McCarthy MC. Complications arising from splenic artery embolization: a review of an 11-year experience. *Am J Surg* 2013;205(3):250–254, discussion 254
- 24 McGuire J, Bultitude MF, Davis P, Koukounaras J, Royce PL, Corcoran NM. Predictors of outcome for blunt high grade renal injury treated with conservative intent. *J Urol* 2011;185(1):187–191
- 25 Bjurlin MA, Jeng EI, Goble SM, Doherty JC, Merlotti GJ. Comparison of nonoperative management with renorrhaphy and nephrectomy in penetrating renal injuries. *J Trauma* 2011;71(3):554–558
- 26 Shoobridge JJ, Corcoran NM, Martin KA, Koukounaras J, Royce PL, Bultitude MF. Contemporary management of renal trauma. *Rev Urol* 2011;13(2):65–72
- 27 Chow SJ, Thompson KJ, Hartman JF, Wright ML. A 10-year review of blunt renal artery injuries at an urban level I trauma centre. *Injury* 2009;40(8):844–850
- 28 Reis LO, Kim FJ, Moore EE, et al. Update in the classification and treatment of complex renal injuries. *Rev Col Bras Cir* 2013;40(4):347–350
- 29 Brewer ME Jr, Strnad BT, Daley BJ, et al. Percutaneous embolization for the management of grade 5 renal trauma in hemodynamically unstable patients: initial experience. *J Urol* 2009;181(4):1737–1741
- 30 Saour M, Charbit J, Millet I, et al. Effect of renal angioembolization on post-traumatic acute kidney injury after high-grade renal trauma: a comparative study of 52 consecutive cases. *Injury* 2014;45(5):894–901
- 31 Cullinane DC, Schiller HJ, Zielinski MD, et al. Eastern Association for the Surgery of Trauma practice management guidelines for hemorrhage in pelvic fracture—update and systematic review. *J Trauma* 2011;71(6):1850–1868
- 32 Asensio JA, Berne JD, Chahwan S, et al. Traumatic injury to the superior mesenteric artery. *Am J Surg* 1999;178(3):235–239