

# Interlude

Yadav Munde<sup>1</sup>

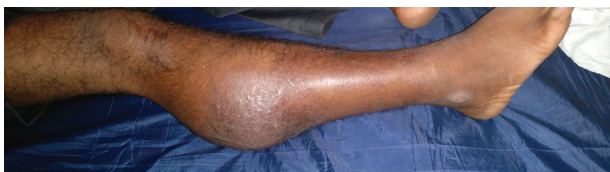<sup>1</sup>Ruby Hall Clinic, Pune

J Clin Interv Radiol ISVIR 2017;1:31.

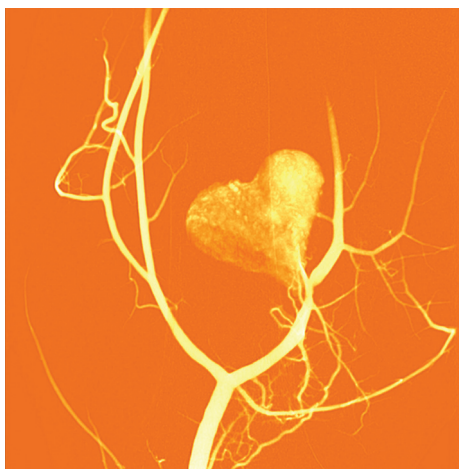
Address for correspondence Yadav Munde, MBBS, DNB, FVIR, Consultant Vascular and Interventional Radiologist, Flat #1003, F2-Building, Ganga Skies, Vallabh Nagar, Pimpri, Pune 411018, Maharashtra, India (e-mail: yadavmunde@gmail.com).

## Image description

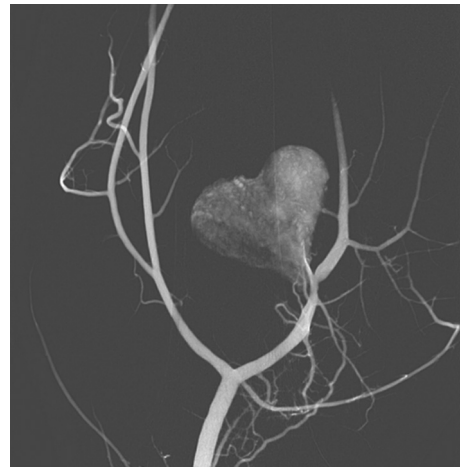
A 39-year-old male patient with a history of road traffic accident presented with swelling (►Fig. 1) in the right calf. The digital subtraction angiography (►Figs. 2, 3) reveals a “heart symbol” shaped pseudoaneurysm arising from the proximal right anterior tibial artery with a wide and short neck. The pseudoaneurysm was treated by placing a stent graft (3.5 × 27 mm; Prograft, Vascular Concepts) (►Fig. 4) across the neck of pseudoaneurysm.



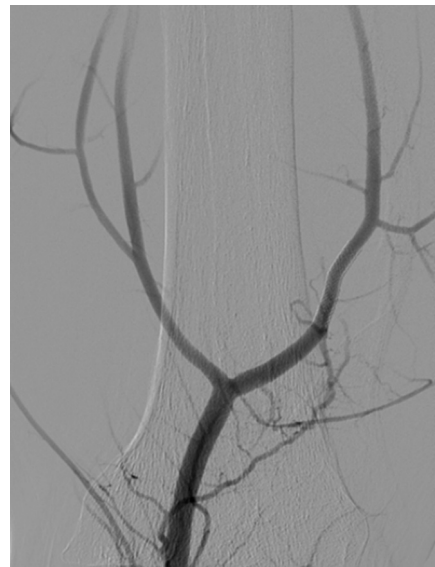
**Fig. 1** Clinical photograph reveals upper right leg swelling.



**Fig. 2** Color image from digital subtraction angiography reveals a heart shaped pseudoaneurysm from right anterior tibial artery.



**Fig. 3** Digital subtraction angiography of right leg demonstrating a heart shaped pseudoaneurysm from right anterior tibial artery.



**Fig. 4** Digital subtraction angiography following the exclusion of the pseudoaneurysm with a stent graft demonstrates patent right anterior tibial artery with no opacification of the pseudoaneurysm.