

Calcified Epidural Hematoma in an Adult Patient: A Case Report

Subramanya G.S. Datta¹ Chandraprakash Sharma²

¹Department of Neurosurgery, INHS Asvini, Mumbai, Maharashtra, India

²Department of Surgery, INHS Asvini, Mumbai, Maharashtra, India

Address for correspondence Subramanya G.S. Datta, MS, MCh, Department of Neurosurgery, INHS Asvini, Next to RC Church, Colaba, Mumbai, Maharashtra, India (e-mail: Sgs1datta@rediffmail.com).

Indian J Neurotrauma 2016;13:171–173.

Abstract

A rare entity encountered in neurosurgery is calcification of epidural hematoma (EDH). The mechanism of calcification of EDH is still unclear. A 31-year-old adult patient sustained blunt trauma to head as a result of assault leading to loss of consciousness of approximately 15 minutes. Initial noncontrast computed tomography (CT) of the head showed left frontal large EDH. Repeat CT after a week showed resolving EDH. One month after trauma, follow-up CT of the head demonstrated increased amount of hypodensity of EDH and thin inner layer calcification toward the dural side. The patient was treated with conservative management, as he showed no neurologic deficits except mild headache.

Keywords

- ▶ epidural
- ▶ hematoma
- ▶ calcification

Introduction

There have been few case reports of calcification or ossification of chronic epidural hematoma (EDH). The presence of calcification can be identified at various intervals after the initial occurrence of EDH. However, the mechanism of the calcification of EDH is still unclear. Treatment of calcified EDH remains controversial, which ranges from conservative nonoperative management to craniotomy and evacuation. We present the case of a 31-year-old adult patient with calcified EDH that was found within a month of head injury. The patient was successfully treated conservatively without operation.

Case Report

A 31-year-old adult male patient was transferred into to our hospital from another hospital. He presented to that center with a history of blunt trauma to the head following an assault nearly 7 days earlier. He had loss of consciousness for approximately 15 minutes followed by good recovery. Presently, he had mild headache and no other neurologic symptoms. Physical examination revealed tenderness over the left forehead. The neurologic examination was

essentially normal. There were no neurologic deficits. Initial brain computed tomography (CT) scanning done at the civil hospital revealed an acute EDH at the left frontal region (▶ Fig. 1). The EDH was of sizable thickness of 18 mm at largest width with mild mass effect on the underlying frontal lobe. On arrival at our hospital, CT scan of the head was immediately repeated and it revealed same size EDH with resolution of mass effect to some extent (▶ Fig. 2).

In view of the young age, delayed presentation, well preserved neurologic status, and nonprogression in the size of the EDH, a decision to continue non operative management was taken. He was closely monitored clinically. A 10-day course of seizure prophylaxis was started.

A repeat CT of the head was done 5 days later in view of the large size of the EDH and persisting headache of the patient. This showed further decreases in size of EDH with reduction in the CT density, suggesting progressive resolution of the hematoma (▶ Fig. 3). Subsequently, he was managed in a subacute ward. He had no further neurologic complaints. He was kept in the hospital for nearly a month.

One month after trauma, a follow-up brain CT of the head was done before a decision to discharge the patient could be taken. This CT head demonstrated a further resolution of the EDH in terms of size and density. However, the deeper dural

received

September 4, 2016

accepted

December 20, 2016

published online

December 28, 2016

© 2016 Neurotrauma Society of India

DOI <http://dx.doi.org/>

10.1055/s-0036-1597942.

ISSN 0973-0508.

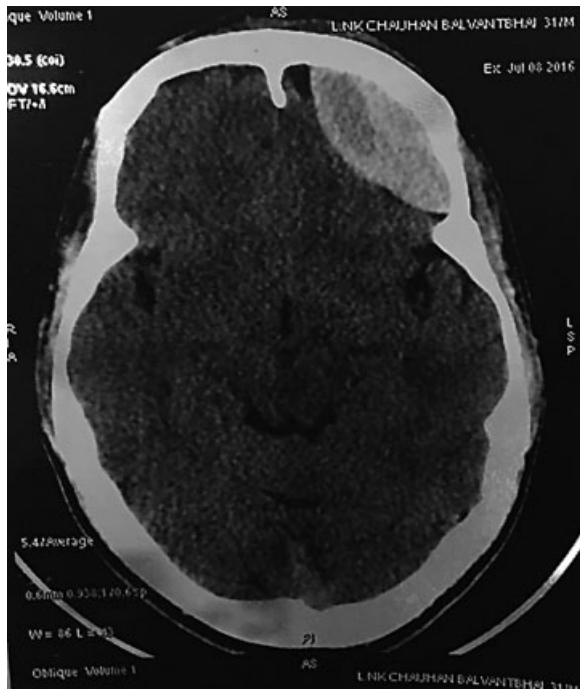

Fig. 1 Computed tomography of the head immediately after injury.

layer of the EDH showed a thin hyperdense layer of calcification (→**Fig. 4**). The patient was counseled. No intervention was offered. He was discharged with advice for early follow-up.

Discussion

Several papers have reported calcification or ossification of EDH. Chang et al¹ reported a 13-year-old female who was found with a calcified EDH 32 days after a mobile accident.

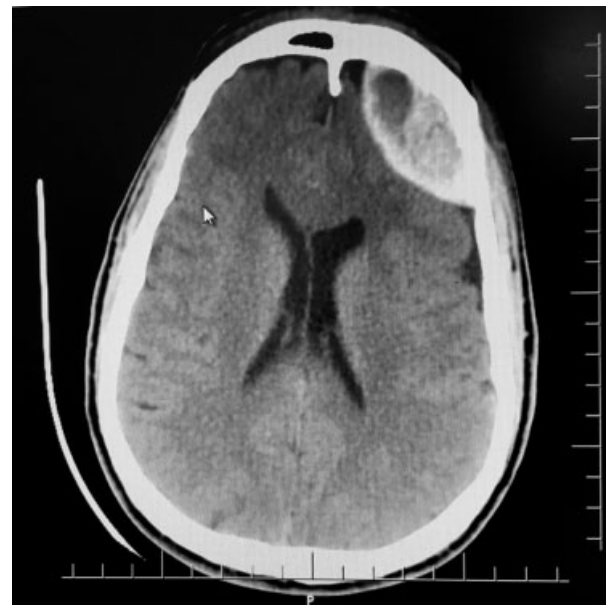


Fig. 3 Computed tomography of the head fourteen days after trauma.

Erdogan et al² reported rapid ossification of an EDH appearing in an 8-year-old boy, which occurred 10 days after a head trauma. De Oliveira et al³ reported a 12-year-old boy who had a large chronic EDH with calcification 1 month after a mild head injury. Yu et al⁴ reported a 26-day-old female infant who had a chronic EDH with a thick layer of calcification. Thus, most papers have been presented in pediatric patients. Seyithanoglu et al⁵ reported that a 17-year-old girl with hydrocephalus was treated with a ventriculoperitoneal shunt and was found to have a bifrontal calcified EDH after 3 years.

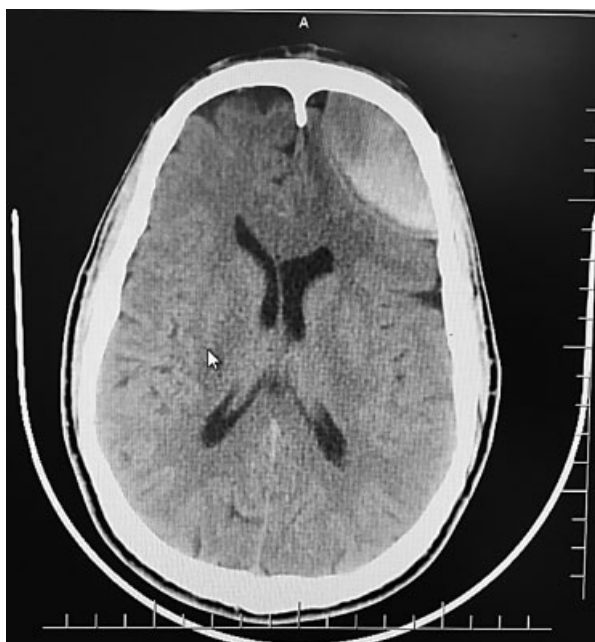

Fig. 2 Computed tomography of the head seven days after trauma.

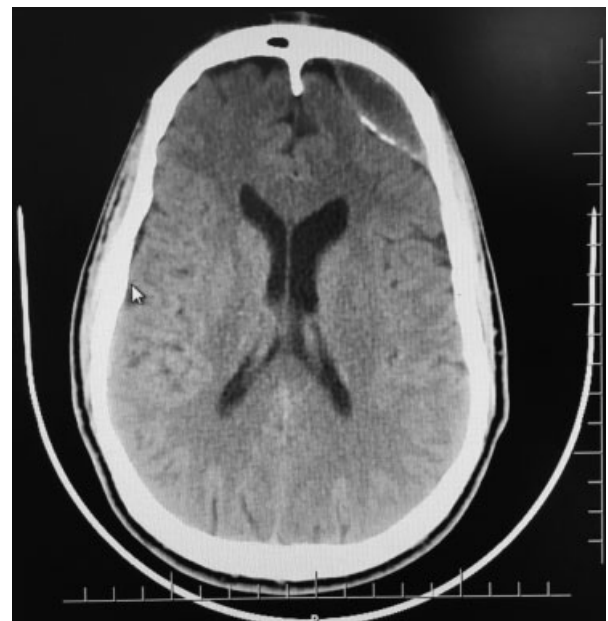

Fig. 4 Computed tomography of the head 1 month after the trauma showed resolving epidural hematoma, with thickened calcified inner layer.

The incidence varies from 2.7 to 4%.^{1,2} The calcification has been noted from as early as 10 days to 4 years.^{1,6} The precise mechanism of calcification or ossification is uncertain. It has been hypothesized that vascularized tissue damage such as bone and dura provokes inflammation and remodeling in tissues.^{2,7} The natural sequence of healing is more rapid in children than adult. Some authors presume that the ossification starts at junction between dura and hematoma capsule.⁸ The calcification of EDH was found on the dural side of the hematoma in all cases including our case. In contrast, in cases of chronic subdural hematomas, calcification is usually found on the outer dural layer.⁶ Nagane et al⁸ suggested that cellular necrosis or hyalinization of the connective tissue continues within the capsule over a lengthy period under conditions of poor circulation or malabsorption of the hematoma content, resulting in calcium deposits. It is unclear if predisposing metabolic, hematologic, and endocrinologic disorders could be a factor for ossification or calcification.

Management is largely conservative and close observation. In a few cases, surgery has been resorted to in order to relieve mass effect from an expanding hematoma.⁹

Conclusion

Majority of cases of EDH calcification occur at the dural side, with young age as predisposing factor. Surgical intervention is not required till the patient tolerates mass effect, but serial CT of the head should be performed to observe the course of calcification and in case of clinical deterioration surgical evacuation of the hematoma may be resorted to.

Conflict of Interest

The authors declare no conflict of interest or financial interests.

References

- 1 Chang JH, Choi JY, Chang JW, Park YG, Kim TS, Chung SS. Chronic epidural hematoma with rapid ossification. *Childs Nerv Syst* 2002;18(12):712–716
- 2 Erdogan B, Sen O, Bal N, Cekinmez M, Altinors N. Rapidly calcifying and ossifying epidural hematoma. *Pediatr Neurosurg* 2003;39(4):208–211
- 3 de Oliveira Sillero R, Zanini MA, Gabarra RC. Large chronic epidural hematoma with calcification: a case report. *J Trauma* 2008;64(6):1619–1621, discussion 1621
- 4 Yu DK, Heo DH, Cho SM, Cho YJ. Rapidly calcified epidural hematoma in a neonate. *J Korean Neurosurg Soc* 2008;44(2):98–100
- 5 Seyithanoglu H, Guzey FK, Emel E, Ozkan N, Aycan A. Chronic ossified epidural hematoma after ventriculoperitoneal shunt insertion: a case report. *Turk Neurosurg* 2010;20(4):519–523
- 6 Kawata Y, Kunimoto M, Sako K, et al. Ossified epidural hematomas: report of two cases [in Japanese]. *No Shinkei Geka* 1994;22(1):51–54
- 7 Buckwalter JA, Cruess RL. Healing of the musculoskeletal tissues. ; In Rockwood CA, Green DP, Bucholz RW, eds. *Fractures in Adults*. 3rd ed. Vol. 1. Philadelphia, PA: Lippincott; 1991:181–222
- 8 Nagane M, Oyama H, Shibui S, Nomura K, Nakanishi Y, Kamiya M. Ossified and calcified epidural hematoma incidentally found 40 years after head injury: case report. *Surg Neurol* 1994;42(1): 65–69
- 9 Sinha S, Borkar S. Chronic calcified extradural hematoma in a child: case report and review of literature. *Indian J Neurotrauma* 2008;5(1):51–52