

A Comparative Study between Universal Eclectic Septoplasty Technique and Cottle

Odim Ferreira do Amaral Neto^{1,*} Flavio Massao Mizoguchi¹ Renato da Silva Freitas²
João Jairney Maniglia^{1,3} Fábio Fabrício Maniglia¹ Ricardo Fabrício Maniglia¹

¹ Hospital Paranaense de Otorrinolaringologia IPO LTDA, Curitiba, Paraná, Brazil

² Plastic Surgery Department, Universidade Federal do Paraná, Curitiba, Paraná, Brazil

³ Universidade Federal do Paraná, Curitiba, Paraná, Brazil

* Master in Sciences thesis, Post Graduate Program (Ringgold Standard), Clinical Surgery Department, Universidade Federal do Paraná, Curitiba, Paraná, Brazil

Address for correspondence Flavio Massao Mizoguchi, PhD, NEP, Hospital Paranaense de Otorrinolaringologia IPO LTDA, Av. República Argentina, 2069 Curitiba, Paraná 80620010, Brazil (e-mail: flaviomizoguchi@gmail.com).

Int Arch Otorhinolaryngol 2017;21:281–285.

Abstract

Introduction Since the last century surgical correction of nasal septum deviation has been improved. The Universal Eclectic Technique was recently reported and there are still few studies dedicated to address this surgical approach.

Objective The objective of this study is to compare the results of septal deviation correction achieved using the Universal Eclectic Technique (UET) with those obtained through Cottle's Technique.

Methods This is a prospective study with two consecutive case series totaling 90 patients (40 women and 50 men), aged between 18 and 55 years. We divided patients into two groups according to the surgical approach. Fifty-three patients underwent septoplasty through Universal Eclectic Technique (UET) and thirty-seven patients were submitted to classical Cottle's septoplasty technique. All patients have answered the Nasal Obstruction Symptom Evaluation Scale (NOSE) questionnaire to assess pre and postoperative nasal obstruction.

Results Statistical analysis showed a significantly shorter operating time for the UET group. Nasal edema assessment performed seven days after the surgery showed a prevalence of mild edema in UET group and moderate edema in Cottle's technique group. In regard to complication rates, UET presented a single case of septal hematoma while in Cottle's technique group we observed: 02 cases of severe edemas, 01 case of incapacitating headache, and 01 complaint of nasal pain.

Conclusion The Universal Eclectic Technique (UET) has proven to be a safe and effective surgical technique with faster symptomatic improvement, low complication rates, and reduced surgical time when compared with classical Cottle's technique.

Keywords

- rhinoplasty
- nasal obstruction
- nasal septum

Introduction

Deviated nasal septum is one of the most common causes of nasal obstruction in adult patients, as well as a frequent complaint in rhinologic practice.¹ Nasal obstruction is the ninetieth most frequent complaint reported at medical ex-

ams in the United States. Nearly 1/3 of the world population presents some type of septum deviation, and 1/4 of those require surgical treatment.^{2,3}

Septoplasty is the definitive treatment for septum deviation, having been performed for several decades with good results. Surgical techniques have evolved and currently there

received
March 22, 2016
accepted after revision
January 13, 2017
published online
March 22, 2017

DOI <https://doi.org/10.1055/s-0037-1599275>.
ISSN 1809-9777.

Copyright © 2017 by Thieme Revinter Publicações Ltda, Rio de Janeiro, Brazil

License terms



are new approaches that must be further studied to understand their advantages and disadvantages.⁴⁻⁶ Such studies would provide important information and guide the surgeon on the choice of a surgical approach.

The Universal Eclectic Technique was described in 2002.⁷ This technique differs from others because it systematizes surgical steps, and is easily learned by residents. Universal Eclectic Technique is a combination of different surgical techniques for the correction of bony and cartilaginous septum deviations.

Despite the importance of this matter, there are still few studies establishing an objective comparison between surgical techniques. Therefore, this study aims at comparing the results obtained through the Universal Eclectic Technique (UET) and those obtained through classic Cottle's Technique.^{8,9} Cottle's Technique is widely accepted and has great results.

For the present study, we performed two series of consecutive septoplasty cases: 53 septoplasty using UET and 37 using Cottle's technique. We assessed and compared some important aspects such as: deviation types, operating surgical time, postoperative edema, postoperative complications, and degree of clinical improvement. Patients who required complementary surgical approaches, such as turbinectomy, were not included in the present study.

We assessed clinical improvement through the Nasal Obstruction Symptom Evaluation Scale (NOSE). We applied a transcultural adaptation and validation of this questionnaire addressing quality of life related to nasal obstruction.¹⁰

Materials and Methods

Study Design

Prospective study of two consecutive case series, based on the analysis of 90 patients submitted to UET and Cottle's septoplasty, using SINPE© as analysis instrument. The research received approval from the Human Research Ethics Committee, number 001/2012 – 01.

The primary objective was to compare the Universal Eclectic Technique with Cottle's Technique. The parameters considered for this comparison were: operating time, complications, and clinical improvement (NOSE).

Sample

Ninety consecutive patients underwent septoplasty through UET or Cottle's Technique between November 2010 and July 2011. Initially, we performed a consecutive series of 53 septoplasties in patients from the UET group. Then, we confirmed a new consecutive series of 37 septoplasties using Cottle's Technique. The same surgeon operated all patients in a single procedure, with a minimum of three-month follow-up.

Inclusion criteria were minimum age of 18 years, with complaint of nasal obstruction and septal deviation. We also excluded patients that presented improvement after clinical treatment; patients who did not authorize the use of their data; that required aesthetic, functional, or restorative surgery; that needed functional sinus surgery; presented nasal

tumor; required intervention in any of the turbinates; tamponade; splint; were submitted to a previous nasal surgery; suffered from allergic rhinitis.

All patients were submitted to flexible nasopharyngoscopy (3.2 mm) to determine location and type of septal deviation. In addition, they answered the NOSE questionnaire.

We evaluated the following variables in both: a) intensity of the symptoms; b) degree of septal deviation; c) operating time; d) postoperative edema; e) septal deviation correction; and f) patient satisfaction.

The author of the present work suggests a classification of the degree of septal deviation based on Maurice Cottle's classification: a) septal deviation degree I: simple deviation, compatible with proper nasal function, however, patient complains of nasal obstruction; b) septal deviation degree II: unilateral deviation consistent with moderate nasal obstruction; c) septal deviation degree III: unilateral or bilateral deviation in contact with the lateral nasal wall, complaint of severe nasal obstruction.

Treatment

The selected patients underwent UET septoplasty or Cottle's septoplasty.

To compare the operating time (surgical times) for both techniques, we timed each surgery from the infiltration on nasal mucosa up to the conclusion of the septal suture. Surgical time classification was divided into: a) 10 to 20 minutes of surgery; b) 20 to 30 minutes of surgery; c) over 30 minutes of surgery

Statistics

We performed proper statistic treatment and used the following nonparametric tests: Wilcoxon for studied groups during pre and postoperative using NOSE; Mann-Whitney between groups on preoperative and postoperative periods also using NOSE; Chi-square between groups to evaluate surgical time and the edema grading. The chosen significance level was $\alpha < 0.05$.

Results

Regarding the comparison between surgical time for UTE group and Cottle group, Chi-square showed $p = 0.00001$.

After surgical procedure, the researcher monitored clinical course, and performed an evaluation of nasal edema seven days after the surgery. Edemas were classified as: a) mild edema: nasal patency between 70 and 100%; b) moderate edema: nasal patency of 30 to 69%; c) severe edema: nasal patency lower than 29%.

We applied the Chi-square test for the comparison between edema grading for both groups and observed significantly better results ($p = 0.000001$) in the UET group.

Thirty days after the surgery an evaluation was performed to assess the presence of residual deviation.

Ninety days after the surgery, we assessed the improvement of nasal obstruction using NOSE. Wilcoxon *t*-test was applied pre-operative and postoperative for period both UET

and Cottle groups, and the results were $p = 0.0000$ for the first group and $p = 0.0000$ for the second one. Therefore, it is possible to state that both techniques have achieved significant clinical improvement.

We applied the Mann-Whitney test to verify whether there was statistically significant difference on pre- and postoperative scores from both groups. We observed no statistical difference ($p = 0.96$).

We performed data collection using SINPE Analisador© for the analysis.

Discussion

The present study has confirmed the hypothesis that UET has some advantages over Cottle's technique, the main advantage being reduced surgical time, with the same rate of clinical improvement. A study published in May/June of 2012 was the first to use the NOSE questionnaire, and has confirmed an improvement in the quality of life of patients submitted to septoplasty three months earlier. However, the present work compared two specific surgical techniques – UET and Cottle's technique – performed by the same surgeon.

It is well known that reduced surgical time also means less exposure of the patient to anesthetics, minimizing costs with medications and optimizing the use of surgical rooms. In the present study, surgical time was statistically lower in the UET group (Chi-square 0.0000) (► **Table 1**).

The first assessment took place seven days after the surgery and we assessed the degree of mucosal edema and the presence of immediate complications (► **Table 2**). The evaluation of mucosal edema is very important due to its relation to nasal congestion complaints. Also, it may compromise patients' performance at work or even delay their return to workplace. It is also important to check possible postoperative complications to perform an early correction. We observed statistically significant difference for degree of edema ($p = 0.000001$) with a prevalence of mild edema in UTE and moderate edema in the Cottle group.

Table 1 Operating time

Operating Time	Cottle	Eclectic Universal Technique
10 to 20 minutes	0%	28%
21 to 30 minutes	16%	64%
Over 30 minutes	84%	8%

Table 2 Edema grading

Edema Grading	Cottle	Eclectic Universal Technique
Mild edema	16%	68%
Moderate edema	60%	21%
Severe edema	24%	11%

Table 3 Early postoperative complications

Early Postoperative Complications	
Crusts	0%
Septal perforation	0%
Nasal Pain	20%
Migraine	20%
Edema	40%
Psychological disturbances	0%
Dehiscence	0%
Others	0%
Necrosis	0%
Hematoma	20%
Infection	0%

In regard to postoperative complications in the UET group there was one case of septal hematoma that was drained in an ambulatory procedure seven days after the surgery. In the Cottle group, 04 patients presented early complications: 01 with nasal pain, 02 with severe edema, and 01 with incapacitating headache (► **Table 3**).

Patients underwent subsequent evaluation 30 days after surgery, when complete regress of the edema is expected, which allows proper examination of the nasal septum to verify if it is centered or if there is residual deviation. We observed no residual deviation in patients from the Cottle group, while two patients from the UET group presented anterior residual deviation. This can be related to the fact that both patients had a severe deviation resulting from nasal trauma.

We performed the final evaluation 90 days after the surgery. We applied NOSE again and compared the scores with those obtained on the pre-operative period. At first, we used the Wilcoxon t -test to compare pre-operative and postoperative in the Cottle group. As expected, there was a significant improvement ($p = 0.0000$). Then, we used the same test for the same comparison in the UET group and observed significant improvement ($p = 0.0000$). Both techniques achieved significant improvement at postoperative; however, which technique achieves better results?

To answer this question, we used a Mann-Whitney test to compare both groups postoperative and the result was $p = 0.96$. Thus, it is possible to state that there was no statistically significant difference between the results of both techniques (► **Table 4**).

When beginning this research, we were not sure of the best way to assess the improvement of patients' clinical conditions. Therefore, we decided to use the NOSE scale in the present study after it had been through transcultural validation. The scale was easily applied and did not compromise the consultation time.

The UET emerges as a more viable option for septoplasty due to the systematization of surgical steps thus reducing

Table 4 Clinical improvement

Clinical Improvement	Cottle	Eclectic Universal Technique
0–30%	0%	0%
31–60%	5%	5%
> 60%	95%	95%

operating time, full access to osteocartilaginous septum, and it being secure and effective.

The safer surgical technique consists of the dissection of the concave side of the perichondrium, preserving its convex side connected to the cartilage (► **Fig. 1**). To correct deviation, strips can be resected in vertical, horizontal, or even oblique direction (► **Figs. 2, 3, and 4**). Scientific basis of this correction is mathematical. A straight line is a circle with an infinite radius (► **Fig. 5**). Rectification of septum deviations is performed through segmentation of large curvatures into one or more fragments that will become parts of the greater radius curve, therefore tending to rectification. After the rectification of the nasal septum, an incision must be made in the convex side of the muco-perichondrium to prevent possible bleeding and the formation of post-operative septal hematoma.

According to our review the pre-maxillary- maxillary access described by Cottle is the most utilized access. Many authors consider Cottle's technique superior due to its preservation of bony and cartilage septum, which can provide stability to nasal pyramid in future trauma and its preservation of quadrangular cartilage, also part of nasal function. It can be performed in children aged over six years with low rates of complications, such as columellar retraction, septal perforation, and atrophic rhinitis. However, this technique has as disadvantages its long operating time and longer learning time, as well as more intense transoperative

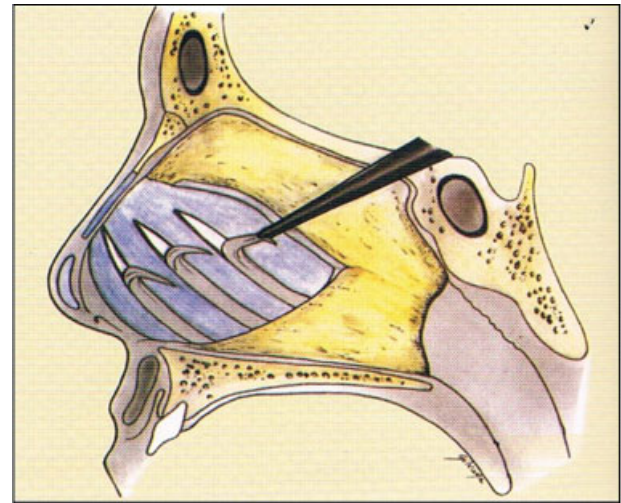


Fig. 2 Opening the compartments in the quadrangular cartilage. Removing small sections of septal cartilage (Goldman's technique).

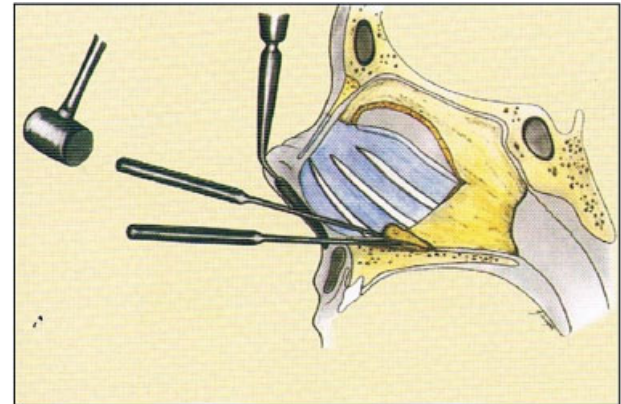


Fig. 3 Removing the bone spur.

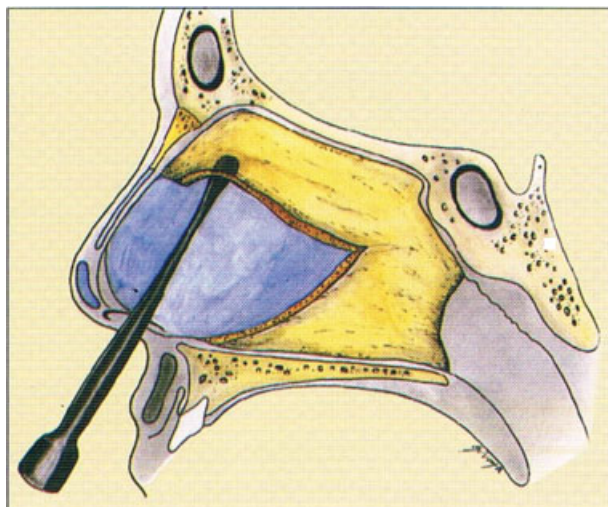


Fig. 1 Goldman Septoplasty Technique: anterior and posterior cartilage incision.

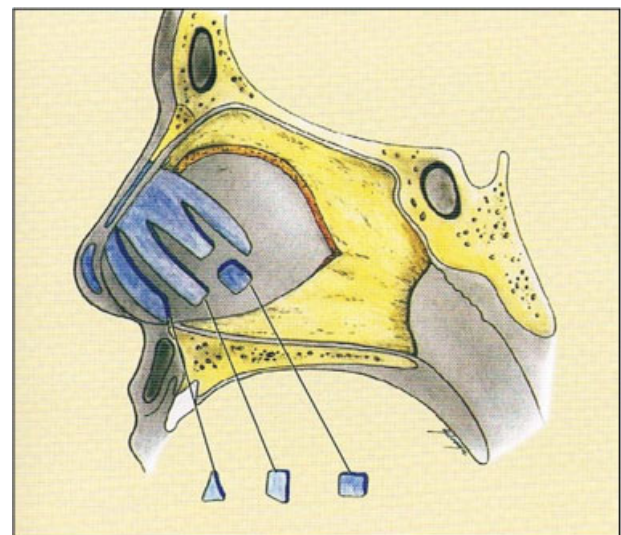


Fig. 4 Removing fragments of septal deformities from compartments.

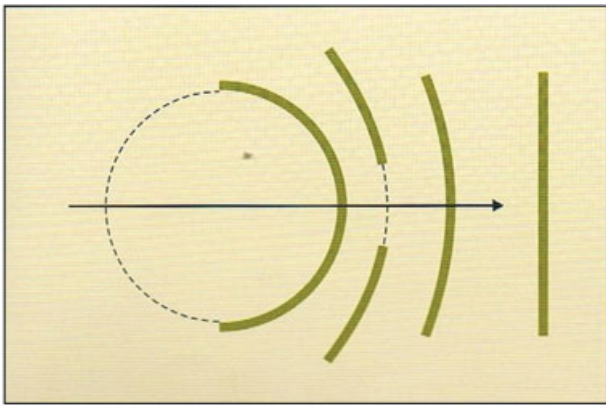


Fig. 5 Mathematical correction of the curvature scheme.

and postoperative bleeding, and more pronounced mucosal edema.¹¹

To obtain more reliable results, there was an effort to exclude patients suffering from concurrent nasal and pulmonary diseases, and patients with septal deviation that did not require surgical interventions other than septoplasty. Therefore, it was not possible to compose a larger sample.

On postoperative septum evaluation, there were two cases of residual anterior deviation after surgery using UET. In both cases the initial deviation was severe and trauma related. The residual anterior deviations were located at less than 1cm from the caudal margin of the septum and, even using transfixation incision of the columella (modified Metzemaum), the complete correction was not possible. However, there was an improvement of clinical symptomatology. For both cases the extracorporeal Toriumi technique would be indicated, therefore, these results cannot be considered as a failure of the UET.

A single case of septal hematoma was observed as a complication of the UET (1.88%). Other authors have reported different rates of this complication after Cottle's technique. An index of 1.3% was reported by Low and Willatt and 6.9% by Fjermedal et al.¹² Thus, UET is equivalent to Cottle's technique. Other studies have reported cases of septal perforation, but in the present study, this complication did not occur in any of the studied groups. The study performed by Low and Willatt reported a septal perforation rate of 2.7%, which is considerably lower than those observed in Fjermedal et al (11.6%), Tzadik et al (6.4%) and Haraldsson et al (8%).^{13–15}

The UET has been used at otorhinolaryngology service for ~30 years, which shows that this is a technique of easy execution for residents in apprenticeships related to septoplasty, rhinoplasty, and functional surgeries of facial sinus.

The Universal Eclectic Technique is increasingly replicated in several continuing education programs in the field of otorhinolaryngology and, with the development of electronic databases, allows further multi-focus studies to better assess and propagate its outcomes.

Conclusion

Our study found that both UET and Cottle's surgical techniques present similar long-term (3 months) results; however, UET presented a briefer operating time and early improvement of postoperative edema.

Shorter operating time also means reduced expenses with anesthetics and optimal use of surgical rooms. Thus, UET is a reliable surgical technique with lower costs to the hospital.

References

- 1 Konstantinidis I, Triaridis S, Triaridis A, Karagiannidis K, Kontzoglou G. Long term results following nasal septal surgery. Focus on patients' satisfaction. *Auris Nasus Larynx* 2005;32(04):369–374
- 2 Bateman ND, Woolford TJ. Informed consent for septal surgery: the evidence-base. *J Laryngol Otol* 2003;117(03):186–189
- 3 Bailey BJ. Nasal septal surgery 1896–1899: transition and controversy. *Laryngoscope* 1997;107(01):10–16
- 4 Killian G. The submucous window resection of nasal septum. *Ann Otol Rhinol Laryngol* 1905;••:363–393
- 5 Cottle MH. Concepts of nasal physiology as related to corrective nasal surgery. *Arch Otolaryngol* 1960;72(01):11–20
- 6 Metzemaum M. Replacement of the lower end of the dislocated septal cartilage versus submucous resection of the dislocated end of the septal cartilage. *Arch Otolaryngol* 1929;9(03):282–296
- 7 Maniglia JJ. Indicações e técnicas de septoplastia. In: Maniglia JJ, Maniglia AJ, Maniglia JV. (orgs.). *Rinoplastia Estética-Funcional-Reconstrutora*. Rio de Janeiro: Revinter; 2002:69–85
- 8 Cottle MH, Loring RM. Newer concepts of septum surgery; present status. *Eye Ear Nose Throat Mon* 1948;27(09):403–406
- 9 Blaugrund SM. Nasal obstruction. The nasal septum and concha bullosa. *Otolaryngol Clin North Am* 1989;22(02):291–306
- 10 Bezerra TFP, Stewart MG, Fornazieri MA, et al. Avaliação da qualidade de vida após septoplastia em pacientes com obstrução nasal. *Rev Bras Otorrinolaringol (Engl Ed)* 2012;78(03):57–62
- 11 Fine J. The antero-inferior premaxillary approach to surgery of the nasal septum. *S Afr Med J* 1973;47(02):49–52
- 12 Low WK, Willatt DJ. Submucous resection for deviated nasal septum: a critical appraisal. *Singapore Med J* 1992;33(06):617–619
- 13 Fjermedal O, Saunte C, Pedersen S. Septoplasty and/or submucous resection? 5 years nasal septum operations. *J Laryngol Otol* 1988;102(09):796–798
- 14 Tzadik A, Gilbert SE, Sade J. Complications of submucous resections of the nasal septum. *Arch Otorhinolaryngol* 1988;245(02):74–76
- 15 Haraldsson PO, Nordemar H, Anggård A. Long-term results after septal surgery–submucous resection versus septoplasty. *ORL J Otorhinolaryngol Relat Spec* 1987;49(04):218–222