

Surgical Resection of an Optic Nerve Sheath Meningioma: Relevance of Endoscopic Endonasal Approaches to the Optic Canal

Patrick J. Hunt¹ Franco DeMonte^{1,2} Rosa A. Tang³ Shirley Y. Su² Shaan M. Raza^{1,2}

¹Department of Neurosurgery, The University of Texas M.D. Anderson Cancer Center, Houston, Texas, United States

²Department of Head and Neck Surgery, The University of Texas M.D. Anderson Cancer Center, Houston, Texas, United States

³MS Eye Care, University Eye Institute, UHCO, University of Houston, Houston, Texas, United States

Address for correspondence Shaan M. Raza, MD, Department of Neurosurgery, The University of Texas M.D. Anderson Cancer Center, Houston, TX 77030, United States (e-mail: smraza@mdanderson.org).

J Neurol Surg Rep 2017;78:e81–e85.

Abstract

Optic nerve sheath meningiomas (ONSMs) account for less than 2% of meningiomas and 1.7% of orbital tumors. Although rare, the management of these tumors is important as unilateral blindness often results in untreated cases. Radiotherapy has emerged as the preferred treatment. However, therapies for ONSMs are controversial due to the variable natural history of the disease and limitations of surgical and radiotherapy options. A 60-year-old woman presented with monocular left diminished color perception and blurred vision. Magnetic resonance imaging demonstrated a homogeneously enhancing 5-mm left optic nerve mass with evidence of nerve compression. Conservative management was advised. However, 1 month after diagnosis her visual acuity deteriorated further. Because of the small focal location of the tumor within the optic canal, surgery was considered. Given the tumor's location inferomedial to the optic nerve, an endoscopic endonasal approach to the optic canal was performed. This patient recovered fully with resolution of visual symptoms immediately following surgery. Postoperative imaging 24 hours after surgery demonstrated gross total resection of the tumor; 1 year postoperatively the patient has a normal ophthalmologic examination. This report highlights the value of endoscopic endonasal approaches in the management of select optic canal pathology, otherwise inaccessible via transcranial approaches.

Keywords

- ▶ optic nerve sheath
- ▶ meningioma
- ▶ optic canal
- ▶ skull base
- ▶ endoscopic endonasal
- ▶ minimally invasive

Introduction

Optic nerve sheath meningiomas (ONSMs) are rare tumors, accounting for less than 2% of meningiomas and 1.7% of all orbital tumors.^{1,2} Though these tumors are rare, monocular blindness is a common outcome in unmanaged cases, highlighting the importance of treatment.² Radiation therapy has emerged as the first-line treatment option for patients for whom treatment is indicated.^{3–9} However, treatment op-

tions for ONSMs are controversial due to the variable natural history of this disease and the current limitations of both surgical and radiation therapies.

To date, surgical approaches to treating ONSMs have relied on transcranial techniques. These approaches are typically reserved for cases that involve intracranial extension of the tumor, compromising the optic chiasm and the contralateral optic nerve. Otherwise, the indications for surgery have been extremely limited in this disease process.

received
July 28, 2016
accepted after revision
January 18, 2017

DOI <http://dx.doi.org/10.1055/s-0037-1600897>.
ISSN 2193-6358.

© 2017 Georg Thieme Verlag KG
Stuttgart • New York

License terms



Visual outcomes and tumor control rates are often significantly worse in these patients when compared with patients undergoing radiation therapy, which is due to the difficulty of targeting the tumor while avoiding the blood supply to the optic nerve^{10,11}

Endoscopic endonasal approaches are well accepted as part of the armamentarium in dealing with complex skull base pathology. There is a growing body of literature supporting the use of endoscopic endonasal approach strategies in the management of optic canal and orbital apex pathology.^{12–14} For example, optic canal extension in the management of tuberculum sella meningiomas can effectively be managed along with orbital apex pathology. Here we report the endoscopic endonasal resection of an intracanalicular ONSM with complete resolution of symptoms and gross total resection of the tumor on imaging.

Case Presentation

A 60-year-old woman noted diminished color perception in her left monocular fields after walking out of a building during daylight. Concurrently, she began experiencing blurred vision restricted to her left eye. Because of the new onset of these symptoms and their subsequent progression, the patient presented for a formal neuro-ophthalmological evaluation. Her medical history was otherwise unremarkable.

Visual acuity best corrected was 20/20 right eye, 20/30 left eye. She diminished color perception (7/12 vs. 12/12) in her left eye with a relative afferent pupillary defect. There was subtle optic disc pallor in the left eye; the right fundus was normal. Automated visual field testing of the left eye demonstrated a superior arcuate defect while the right fields were normal (►Fig. 1A). Extraocular movements were full; external and anterior segment examinations were unremarkable.

Magnetic resonance imaging (MRI) of the brain demonstrated a homogeneously enhancing mass, measuring approximately 5 mm in greatest dimension, within the left optic canal with evidence of nerve compression (►Fig. 2A). Initially, the patient was advised to pursue conservative management with imaging surveillance. However, 1 month after her initial diagnosis, the patient experienced further worsening of her visual acuity (20/40 OS) and fields

(►Fig. 1B). Subsequently, the patient was referred to our institution for an evaluation for possible treatment options.

Surgery

Because of the patient's deteriorating visual function and imaging demonstrating a focal lesion within the optic canal, surgical intervention was recommended as the primary treatment intervention. An endoscopic endonasal approach was favored over a transcranial approach given the location of the tumor inferomedial to the optic nerve to minimize manipulation of the nerve while allowing direct visualization of any parasitized vasculature. The initial relevant portions of the procedure included raising a nasal septal flap based on the sphenopalatine artery contralateral to the tumor, a tailored posterior septectomy, and resection of the ipsilateral middle turbinate. This then provided access to the lamina papyracea and sphenoid sinus. At this point, the left optic canal was decompressed 270 degrees for its entire length from the tuberculum sellae to the orbital apex (►Fig. 3A) using a high-speed drill with 4- and 3-mm coarse diamond burrs under constant irrigation. This consisted of performing an ipsilateral middle clinoidectomy, exposing adjacent dura of the tuberculum sella and planum sphenoidale along with exposure of the clinoid carotid artery and superior orbital fissure. Additionally, the posterior lamina was removed to expose the orbital apex. Once an adequate bony decompression was completed, the dura of the optic canal was opened over the length of the intracanalicular portion of the nerve with a retractable blade after using a Doppler to confirm the length of the ophthalmic artery. This incision was created over the superior half of the optic canal and then extended inferiorly anteriorly and posteriorly to reflect the dura inferiorly.

The tumor was immediately identified inferior to the nerve and medial to the ophthalmic artery. Using sharp dissection, the dural attachment of the tumor was circumferentially cut, after which the tumor was then sharply dissected away from the inferior surface of the optic nerve. In this process, several attachments along the tumor-nerve interface were noted and selectively dissected. A gross total resection was performed while preserving the ophthalmic artery and the arterial perforators to the optic nerve (►Fig. 3B–E). A nasoseptal flap was then harvested based on the contralateral sphenopalatine artery, its size, and

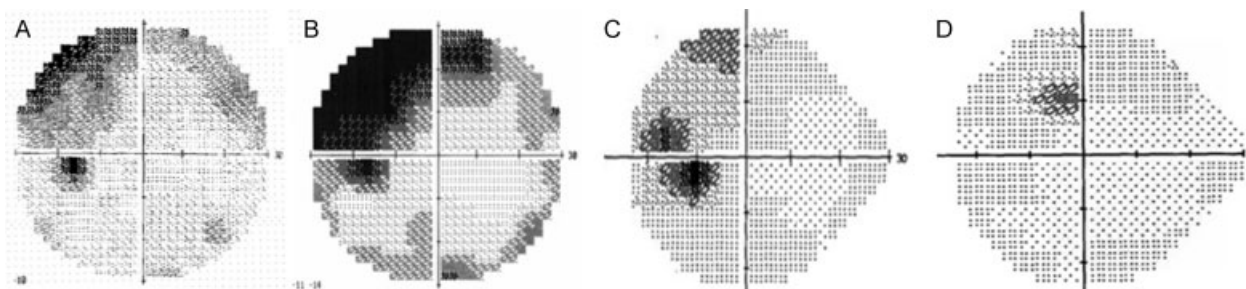


Fig. 1 Automated visual field of the left eye shows a worsening superior arcuate visual field deficit (A) one month preoperatively and (B) two days preoperatively. Postoperative testing demonstrated an improvement in fields. (C) Two weeks postoperatively. (D) Ten months postoperatively.

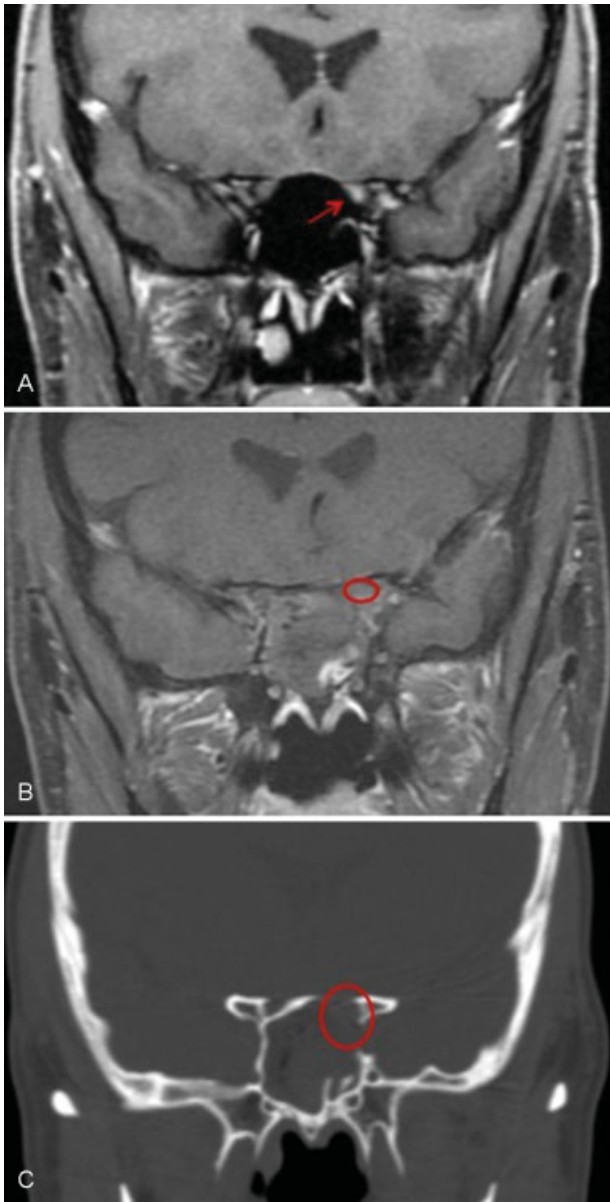


Fig. 2 Pre- and postoperative MRI. (A) Preoperative coronal MRI T1 weighted with contrast demonstrates a small intra canalicular lesion inferomedial to the left optic nerve. (B) Postoperative coronal MRI T1 weighted with contrast demonstrates gross total resection. (C) Postoperative coronal CT demonstrating decompression of the optic canal. Arrow, tumor; circle, optic nerve/canal.

location customized to the dural defect. The optic nerve was initially protected with a small fascia lata graft, which was then covered with the nasal septal flap. The final pathologic diagnosis was a World Health Organization (WHO) grade I meningioma.

Postoperatively, the patient reported an improvement in her color perception and visual acuity immediately after surgery. Postoperative imaging, MRI and computed tomography (CT), obtained 24 hours after surgery, demonstrated a gross total resection with decompression of the optic nerve (► Fig. 2B, C). The patient was discharged home 36 hours postoperatively with continued improvement in her vision. Follow-up neuro-ophthalmological evaluation 2 weeks after

surgery demonstrated improved visual acuity (20/20), with resolution of the color perception in her left eye and improvement of left visual field and left relative afferent pupillary defect.

At 10 months postoperatively, all visual deficits normalized (► Fig. 1D).

Discussion

ONSMs account for less than 2% of all meningiomas and approximately 1.7% of all orbital tumors.^{1,2} Painless visual loss is the most frequent symptom and patients typically complain of decreased color perception and acuity in the affected eye. Although they account for a small percentage of tumors in this region, their management is relevant because of the natural history leading to, at the very least, unilateral blindness if not treated. While the classic radiographic description of ONSMs is the “tram track sign,” this disease entity encompasses several anatomic variants that can perhaps dictate management.¹ While the tumor presented here is of the exophytic variety within the canal with no nerve invasion, ONSMs can be characterized based on the location along the nerve (intraorbital, intracanalicular, intradural) and involvement of the nerve (exophytic, circumferential involvement).

Treatment offered to patients with ONSMs remains controversial due to the variability in the natural history of this disease and the limitations of currently available surgical and radiation therapy options. Observation alone can be useful in patients without visual loss provided a strict follow-up system with imaging and ophthalmologic evaluations. With advancements in planning and targeting, radiation therapy (XRT) has emerged as the preferred treatment for ONSMs. XRT techniques reported in the treatment of ONSMs include intensity-modulated radiotherapy, stereotactic fractionated radiotherapy, and three-dimensional conformal radiation therapy.^{3–9} Typically involving the delivery of 50 to 55 Gy in 1.8 Gy fractions, XRT can result in variable rates of visual stability (8–86%) with complications in up to 33.3% of cases reported in the literature.^{4–9} For smaller, well-circumscribed lesions, single-session stereotactic radiosurgery with a dose of 8 to 10 Gy can be used.¹¹ Overall, potential complications include radiation-induced retinopathy, retinal vascular occlusion, iritis, hypopituitarism, and the development of radiation-induced tumors. However, given the generally poor surgical outcomes that have been previously reported, XRT is the primary intervention for a majority of ONSMs.

Historically, surgery has played a limited role in the management of ONSMs. The indication for transcranial approaches (i.e., orbitocranial, pterional) has been traditionally limited to tumors with significant intracranial extension where the chiasm and contralateral nerve may be at risk. However, such approaches have been limited regarding the treatment of purely intracanalicular or intraorbital pathology due to the intimate association of the lesion with the nerve and/or its vascular supply. Several recent publications have affirmed this affect with worse visual outcomes and

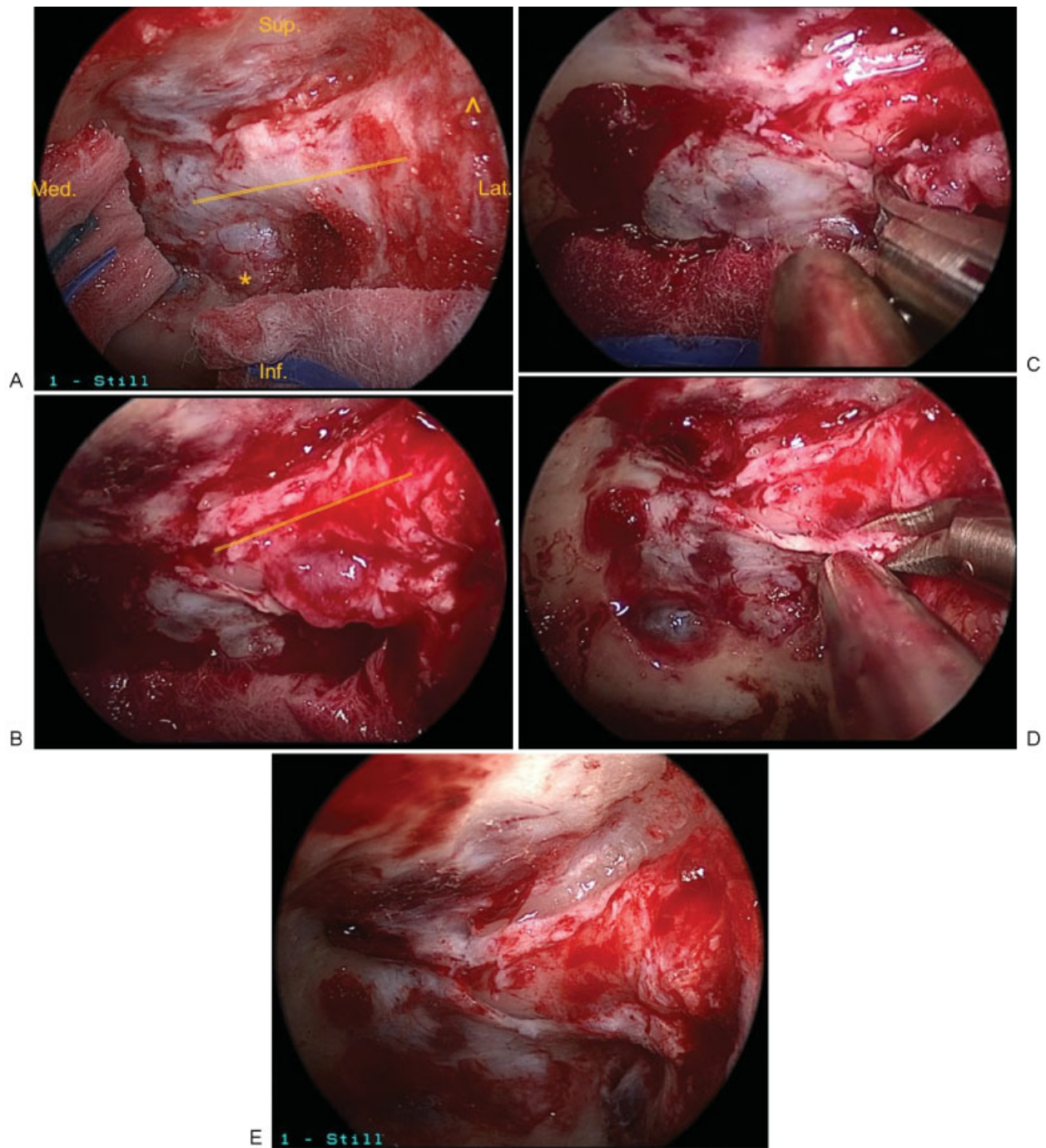


Fig. 3 Intraoperative images during endonasal endoscopic resection. (A) Initial exposure of the entire length of the optic canal prior to sheath opening. (B) Visualization of the tumor along the inferomedial surface of the nerve after sheath incision. (C) Sharp dissection of the tumor away from the optic nerve. (D) Sharp excision of the dural attachment of the tumor. (E) Visualization of the optic nerve at the completion of tumor resection. Sup., superior; Inf., inferior; Med., medial; Lat., lateral; solid line, optic nerve; *, cavernous sinus; ^, orbital apex.

tumor control rates in surgically treated patients—especially with the primary pathology along the intracanalicular or intraorbital segments of the optic nerve.^{10,15}

Initially reported for the resection of pituitary adenomas, the endoscopic endonasal technique is now used for optic canal decompressions and orbital apex pathology. Several publications have documented outcomes from endoscopic endonasal resection of tuberculum sella meningiomas with optic canal invasion,^{13,16} orbital apex pathology,^{17–19} and

decompression for traumatic and nontraumatic optic neuropathy¹⁷; however, endoscopic resection of an intracanalicular ONSM has not yet been reported. In the management of optic nerve-related pathology in general, and within this specific case, there are several key technical considerations. The extent of canal decompression is key to minimizing optic nerve manipulation by opening up the space through which the resection can be performed. The length of the canalicular segment of the optic nerve runs from the annulus of Zinn

proximally to the distal optic canal—whose marker would be the medial OCR (optico-carotid recess) when viewed endonasally. The superior extent is limited by the planum dura, whereas the inferior extent is limited by the clinoid segment of the internal carotid artery (ICA) (distally), the superior orbital fissure (middle segment), and the lamina papyracea (proximally). An important, but perhaps not adequately discussed step in the literature, is performing removal of the bone inferior to the distal optic canal and superior to the clinoid ICA at the level of the distal dural ring. This maneuver facilitates early identification of the ophthalmic artery prior to and during the process of opening the dura over the optic canal. Given the course of the ophthalmic artery inferior to the nerve, the risk of arterial injury is further minimized by opening the optic canal along the superior aspect of the canal and parallel to the nerve. It additionally should be recognized that the ophthalmic artery can have a variable course relative to the nerve and should be studied on preoperative CT angiography. According to a study by Zoli et al, in a majority of cases, the ophthalmic artery arises either inferocentrally or inferolaterally to the optic nerve and remains along the lateral aspect of the canal.²⁰ However, in 13% of the cadaver dissections performed, the artery arose inferomedially, and in half of those cases, the artery remained along the medial aspect of the canal. Beyond early identification of the artery and a judicious dural opening, the use of the Doppler to plot out the course of the intracanalicular course of the ophthalmic artery can reduce the risk of an arterial injury.

Conclusion

Surgical resection of ONSMs is an important treatment option to consider. In this report we discuss an endoscopic endonasal approach that resulted in complete resolution of visual symptoms and gross total resection of the tumor on imaging. In conjunction with existing surgical approaches to the optic nerve, the expansion of endoscopic endonasal approaches to this anatomic region now provides a means by which every segment of the optic nerve can be targeted in a 360-degree fashion by either transcranial, transorbital, or endonasal approaches. Advancements in neuroimaging can now provide a detailed understanding of the relative lesion-nerve anatomy by which the appropriate approach can be selected to provide the best possible visual and oncologic outcome. Given the variability in presentation and anatomy of ONSMs, it is important that the treatment be tailored to the patient and desired outcome. In light of our experience with this patient, endoscopic endonasal approaches can perhaps be considered part of the armamentarium for selected tumors.

Disclosures

The authors declare that there is no conflict of interest regarding the publication of this paper.

References

- Castel A, Boschi A, Renard L, De Potter P. Optic nerve sheath meningiomas: clinical features, functional prognosis and controversial treatment. *Bull Soc Belge Ophtalmol* 2000;275:73–78
- Dutton JJ. Optic nerve sheath meningiomas. *Surv Ophthalmol* 1992;37(03):167–183
- Shapey J, Sabin HI, Danesh-Meyer HV, Kaye AH. Diagnosis and management of optic nerve sheath meningiomas. *J Clin Neurosci* 2013;20(08):1045–1056
- Abouaf L, Girard N, Lefort T, et al. Standard-fractionated radiotherapy for optic nerve sheath meningioma: visual outcome is predicted by mean eye dose. *Int J Radiat Oncol Biol Phys* 2012;82(03):1268–1277
- Becker G, Jeremic B, Pitz S, et al. Stereotactic fractionated radiotherapy in patients with optic nerve sheath meningioma. *Int J Radiat Oncol Biol Phys* 2002;54(05):1422–1429
- Brower JV, Amdur RJ, Kirwan J, Mendenhall WM, Friedman W. Radiation therapy for optic nerve sheath meningioma. *Pract Radiat Oncol* 2013;3(03):223–228
- Lesser RL, Knisely JP, Wang SL, Yu JB, Kupersmith MJ. Long-term response to fractionated radiotherapy of presumed optic nerve sheath meningioma. *Br J Ophthalmol* 2010;94(05):559–563
- Moyer PD, Golnik KC, Breneman J. Treatment of optic nerve sheath meningioma with three-dimensional conformal radiation. *Am J Ophthalmol* 2000;129(05):694–696
- Paulsen F, Doerr S, Wilhelm H, Becker G, Bamberg M, Classen J. Fractionated stereotactic radiotherapy in patients with optic nerve sheath meningioma. *Int J Radiat Oncol Biol Phys* 2012;82(02):773–778
- Schick U, Dott U, Hassler W. Surgical management of meningiomas involving the optic nerve sheath. *J Neurosurg* 2004;101(06):951–959
- Liu D, Xu D, Zhang Z, et al. Long-term results of Gamma knife surgery for optic nerve sheath meningioma. *J Neurosurg* 2010;113(Suppl):28–33
- Ditzel Filho LF, Prevedello DM, Jamshidi AO, et al. Endoscopic endonasal approach for removal of tuberculum sellae meningiomas. *Neurosurg Clin N Am* 2015;26(03):349–361
- Kulwin C, Schwartz TH, Cohen-Gadol AA. Endoscopic extended transsphenoidal resection of tuberculum sellae meningiomas: nuances of neurosurgical technique. *Neurosurg Focus* 2013;35(06):E6
- Turel MK, Tsermoulas G, Reddy D, Andrade-Barazarte H, Zadeh G, Gentili F. Endonasal endoscopic transsphenoidal excision of tuberculum sellae meningiomas: a systematic review. *J Neurosurg Sci* 2016;60(04):463–475
- Roser F, Nakamura M, Martini-Thomas R, Samii M, Tatagiba M. The role of surgery in meningiomas involving the optic nerve sheath. *Clin Neurol Neurosurg* 2006;108(05):470–476
- Fernandez-Miranda JC, Pinheiro-Nieto C, Gardner PA, Snyderman CH. Endoscopic endonasal approach for a tuberculum sellae meningioma. *J Neurosurg* 2012;32(Suppl):E8
- Berhouma M, Jacquesson T, Abouaf L, Vighetto A, Jouanneau E. Endoscopic endonasal optic nerve and orbital apex decompression for nontraumatic optic neuropathy: surgical nuances and review of the literature. *Neurosurg Focus* 2014;37(04):E19
- Lee JY, Ramakrishnan VR, Chiu AG, Palmer J, Gausas RE. Endoscopic endonasal surgical resection of tumors of the medial orbital apex and wall. *Clin Neurol Neurosurg* 2012;114(01):93–98
- Locatelli M, Carrabba G, Guastella C, Gaini SM, Spagnoli D. Endoscopic endonasal removal of a cavernous hemangioma of the orbital apex. *Surg Neurol Int* 2011;2:58
- Zoli M, Manzoli L, Bonfatti R, et al. Endoscopic endonasal anatomy of the ophthalmic artery in the optic canal. *Acta Neurochir (Wien)* 2016;158(07):1343–1350