

Brain Studded with Innumerable Larger Stones: Starry Sky at Night Appearance: Multiple Calcified Giant Tuberculoma with 15 Years of Follow-up

Guru Dutta Satyarthee¹ P. S. Chandra¹ A. K. Mahapatra¹

¹Department of Neurosurgery, Neurosciences Centre, AIIMS, New Delhi, India

Address for correspondence Guru Dutta Satyarthee, MCh, Department of Neurosurgery, Neurosciences Centre, AIIMS, Room no. 714, New Delhi, India (e-mail: duttaguru2002@yahoo.com).

Indian J Neurosurg 2017;6:155–158.

Abstract

Keywords

- ▶ multiple intracranial tuberculoma
- ▶ stones
- ▶ starry night appearances
- ▶ hydrocephalus
- ▶ histopathological diagnosis

Tuberculosis is rapidly reemerging as a major health problem due to rising incidence of HIV cases across the globe. Central nervous system involvement is rare, but rarely multiple intracerebral granulomas can occur or occasional solitary tuberculoma also develops. The authors report a unique case of 24-year-old woman suffering from pulmonary tuberculosis developed headache and vomiting. Cranial CT scan revealed multiple widespread deposit of intracranial granuloma of sizeable lesion mimicking starry sky at night appearance. Excision of one tuberculoma was done for confirmation of definitive diagnosis, and histopathology was suggestive of tuberculoma. The patient also underwent VP shunt surgery. At last follow-up at 15 years following surgery, she was doing well.

Tuberculosis is rapidly reemerging as a major health problem globally due to associated increasing incidence of human immunodeficiency virus (HIV) cases. Central nervous system (CNS) involvement due to tuberculous affection is rare and commonly presents as meningitis, ventriculitis, or, rarely, as intracerebral granulomas, which can occur as multiple smaller lesion or occasional solitary tuberculoma.

A 24-year-old woman presented in our OPD with headache and occasional vomiting for past 8 months, but it increased over past 2 weeks. She was a diagnosed case of pulmonary tuberculosis and kept on antituberculous drugs for past 10 months. On examination, she was consciously alert, her vital was stable, fundi showed bilateral papilledema, and the rest of the neurologic examination was essentially within normal limit. Noncontrast computed tomographic (CT) scan of the head showed larger-sized multiple calcified lesions, scattered throughout the supra- and infratentorial compartment, which were noticed in

each axial section images, with absent perilesional edema in the bilateral cerebral hemispheres, bilateral cerebellar hemisphere, right basal ganglia, and thalamus, as well as in left cerebral peduncle mimicking as brilliantly shining stars in the sky at night appearance (▶Figs. 1, 2). In view to ascertain the definite diagnosis, a plan was made for right frontal craniotomy and excision of tuberculoma. She was taken up for surgery under general anesthesia. Right frontal osteoplastic flap craniotomy was made. After dural opening, a small cortical incision was made, just beneath the corticectomy incision. A well-encapsulated mass was seen and excised, and wound was closed in layers after achieving hemostasis. Ventriculo-peritoneal (VP) shunt was also performed to relieve persistent hydrocephalus.

Histopathologic examination of specimen was suggestive of tuberculous granuloma, and the patient was advised addition antituberculous medication for further 8 months as she had already received 10 months medication. At last follow-up at 15 years following the first craniotomy for

received
September 21, 2016
accepted
January 23, 2017
published online
April 12, 2017

DOI <https://doi.org/10.1055/s-0037-1601365>.
ISSN 2277-954X.

© 2017 Neurological Surgeons' Society of India

License terms



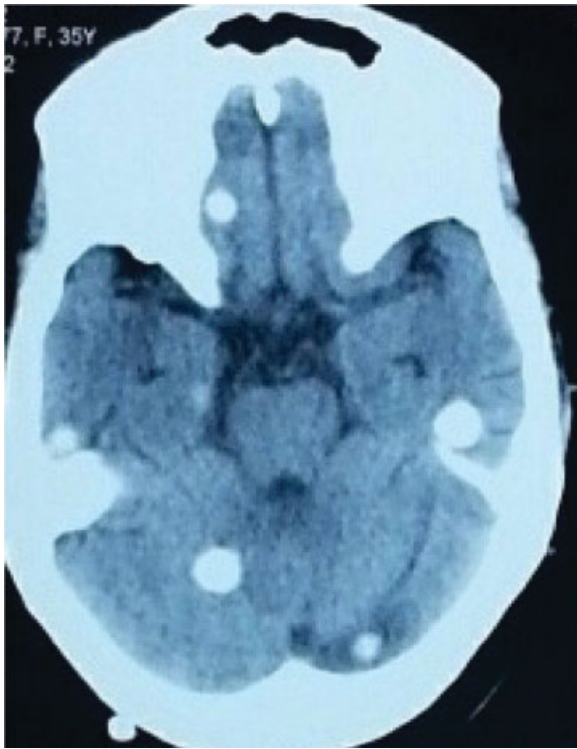


Fig. 1 Noncontrast computed tomography scan of head showing presence of multiple calcified lesions in the bilateral temporal lobes and cerebellar hemisphere, and right basifrontal regions mimicking starry sky at night appearance (preoperative scan).

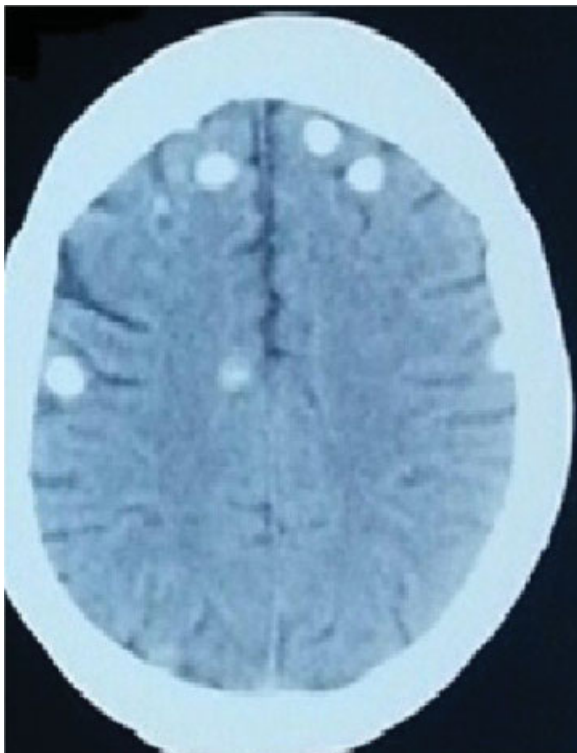

Fig. 2 Cranial computed tomography scan of head showing presence of multiple calcified lesions in the bilateral frontal and parietal region in the supratentorial compartment (preoperative scan).

tuberculoma excision surgery, she had no focal neurologic deficit. The cranial CT scan at the present follow-up revealed presence of multiple intracranial tuberculoma. Although the sizes of the multiple lesions were slightly reduced, still considerable sizes are persisting (–Figs. 3, 4),

Intracranial tuberculoma is not a common entity, and multifocal tuberculosis incidence is increasing due to rise in immunocompromised conditions such as HIV.

CNS involvement in tuberculosis is usually caused by hematogenous spread from either the lungs or gastrointestinal tract, which in the beginning causes formation of small subpial or subependymal infective focus also called *Rich focus* and acts as a reservoir from which intracranial spread can subsequently occur either during the primary infection or later as reactivation causing a postprimary infection.^{1–3} CNS tuberculosis is usually secondary to hematogenous dissemination of bacilli from an infection focus elsewhere in the body. All intracranial compartments can be affected. Intracranial involvement broadly can be divided into intra- and extra-axial affection. Extra-axial involvement includes tuberculous meningitis that is more common comparing to pachymeningitis that is extremely uncommon. Extra-axial tuberculous involvement can manifest as tuberculous granuloma formation also called *tuberculoma*, with others being focal cerebrates, tuberculous abscess, and encephalopathy.

These CNS involvements such as meningitis, solitary tuberculoma, abscess, infarct, or miliary parenchymal lesion

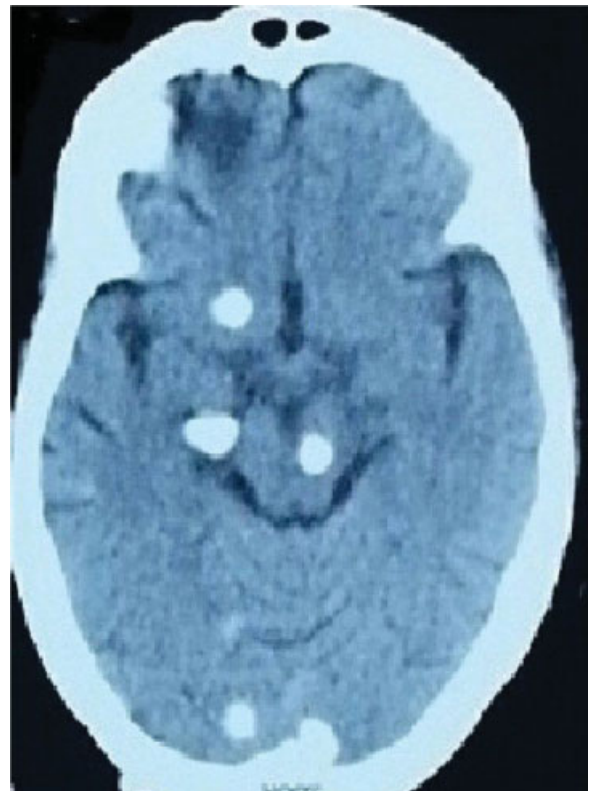

Fig. 3 Postoperative computed tomography scan of head at follow-up period after 15 years following craniotomy and resection of right frontal calcified tuberculoma in brainstem, and supratentorial compartment.

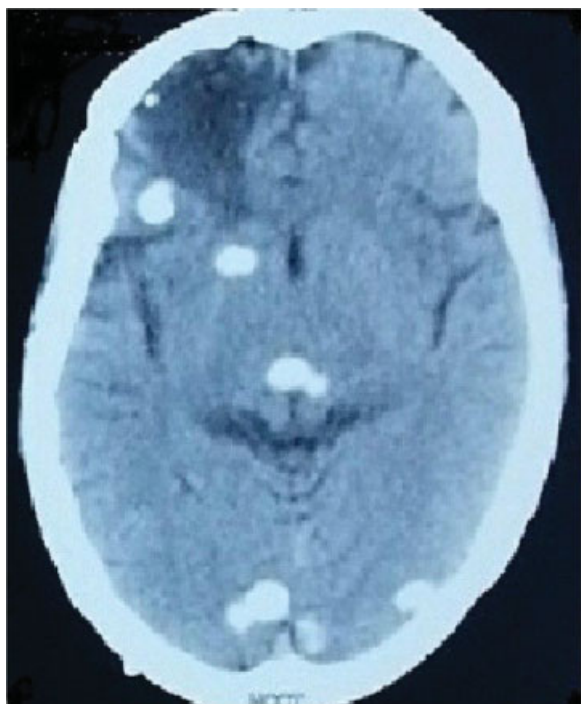

Fig. 4 Postoperative cranial computed tomography scan after excision of right frontal tuberculoma still showing presence of right frontal, thalamic, and occipital lobes.

are seen in approximately 5 to 10% of tuberculosis cases. The intracranial tuberculoma account for 5 to 30% of all intracranial space-occupying lesions in developing countries.¹

The tuberculosis leads to intracranial calcifications in 10 to 20% cases. It is usually located supratentorial in adults and infratentorial in children.² Intracranial tuberculomas are usually seen in the basal section of the brain. Tuberculoma may show a spectrum of clinical manifestations depending on location, size, associated edema, number of tuberculoma, and obstruction to cerebrospinal fluid (CSF) pathway. The most frequent symptoms include headache, epileptic attacks, focal neurologic deficits, and features of raised intracranial pressure.^{3,4}

It is difficult to diagnose when the patient has no history of tuberculosis. Radiologic diagnosis is also difficult due to varied and nonspecific imaging presentation.

Our patient was a known case of pulmonary tuberculosis, who was receiving antituberculous therapy, and she presented with headache. Noncontrast CT of the head showed multiple calcified lesions in the brain with single larger lesion in the right frontal region.

With history of tuberculosis, first differential of tuberculosis was made and further histopathologic confirmation was made after excision of lesion in the right frontal region. In the developing countries, granulomatous infections such as tuberculosis and parasitic infections such as neurocysticercosis and hydatid cyst can also result in the development of characteristic intracranial calcifications. Rising number of HIV cases may lead to increased incidence of tuberculosis, and other associated infections including

toxoplasmosis, rubella, cytomegalovirus, and herpes simplex may promote occurrence of intracranial calcifications.² The other differentials can be multiple calcified meningioma, craniopharyngioma, oligodendroglioma, dystrophic calcification in chronic infarction, chronic vasculitis, and exaggerated physiologic calcifications.

CT can identify and clearly delineate and characterize brain stones defining their locations, size, number, involvement of supra- and infratentorial compartment, extent, associated perilesional edema, and associated hydrocephalus. However, magnetic resonance imaging (MRI) of the brain remains the gold standard imaging modality, and advent of newer sequences such as gradient echo T2-weighted images and susceptibility-weighted image is adjunctive and clearly categorizes the tuberculoma. The calcified tuberculoma can appear as “broken shell” or dense centrally located lobulated calcification.^{5,6}

Neurocysticercosis is a major cause of adult-onset seizures in developing countries; here calcifications represent dead larvae.⁷ The hydatid disease is considered a rare cause of intracranial calcification, and lesion is usually solitary, septated, or multilocular representing the dead parasite.⁸

In countries where suspicion for tuberculoma is high and clinical and imaging findings suggests high probability of tuberculous mass lesion, a trial of anti-tuberculous medication course should be tried. However, the surgical excision or biopsy is usually reserved for the cases, in which the diagnosis of the intracranial calcification or mass lesion is in doubt or lack of appropriate response to empirical medical therapy after receiving for at least 2 months or paradoxical response to antituberculous medications. However, in cases associated with severe obstructive hydrocephalus or raised intracranial pressure, CSF diversion surgery such as VP shunt surgery is required.^{9,10} Our patient was already on ATT for past 10 months, and she developed the lesions so the diagnosis was doubtful. Therefore, to confirm that, single lesion was excised and additionally VP shunt was also placed. Dawar et al observed that the calvarial tuberculosis is rare and can present with a localized focal scalp swelling with overlying skin discoloration and solitary or multiple discharging sinus. They reported a case of calvarial tuberculosis in 17-year-old girl, who had a large painless scalp swelling spreading over both the frontal areas from supraorbital margin to coronal suture without discoloration or sinus formation, and neuroimaging showed absence of extradural granulation tissue deposits with very subtle bony architecture changes of adjacent calvarium. The swelling completely subsided with medical therapy alone.¹¹

To conclude, early diagnosis and appropriate management including medical or surgical intervention should be tailor-made, and should constitute an important step in terms of reducing mortality and morbidity. In our country tuberculosis is an endemic disease and the physician should be aware that size of tuberculoma can be variable and sometimes can be of giant sizes, which may persist up to many years as current case persisted for at least 15 years despite receiving full course of antituberculous therapy.

References

- 1 Alkhani A, Al-Otaibi F, Cupler EJ, Lach B. Miliary tuberculomas of the brain: case report. *Clin Neurol Neurosurg* 2006;108(04):411–414
- 2 Celzo FG, Venstermans C, De Belder F, et al. Brain stones revisited-between a rock and a hard place. *Insights Imaging* 2013;4:625–635
- 3 Aniba K, Ghannane H, Jalal H, et al. [Giant cerebellar tuberculoma mimicking a malignant tumor] [in French]. *Neurochirurgie* 2009;55(03):337–339
- 4 Arseni C. Two hundred and one cases of intracranial tuberculoma treated surgically. *J Neurol Neurosurg Psychiatry* 1958;21(04):308–311
- 5 Watts JM, Singh J, Schoppe CH, Johnson AJ. Calcified intracranial masses: an unexpected diagnosis in western radiology. *Clin Neuroradiol* 2012;22(03):253–256
- 6 Wasay M, Kheleani BA, Moolani MK, et al. Brain CT and MRI findings in 100 consecutive patients with intracranial tuberculoma. *J Neuroimaging* 2003;13(03):240–247
- 7 Velasco TR, Zanello PA, Dalmagro CL, et al. Calcified cysticercotic lesions and intractable epilepsy: a cross sectional study of 512 patients. *J Neurol Neurosurg Psychiatry* 2006;77(04):485–488
- 8 Senturk S, Oguz KK, Soylemezoglu F, Inci S. Cerebral alveolar echinococcosis mimicking primary brain tumor. *AJNR Am J Neuroradiol* 2006;27(02):420–422
- 9 Al-Mefty O. Intracranial tuberculoma. *J Neurosurg* 1986;65(04):572–573
- 10 Awada A, Daif AK, Pirani M, Khan MY, Memish Z, Al Rajeh S. Evolution of brain tuberculomas under standard antituberculous treatment. *J Neurol Sci* 1998;156(01):47–52
- 11 Dawar P, Satyarthee GD, Sharma BS. Total resolution of large scalp swelling due to calvarial tuberculosis with medical management only: case report and review of the literature. *Turk Neurosurg* 2015;25(02):313–316