

# Evaluation of Probably Benign Adnexal Masses in Postmenopausal Women

## *Avaliação de massas anexiais benignas em mulheres pós-menopáusicas*

Burcu Kisa Karakaya<sup>1</sup> Emre Ozgu<sup>1</sup> Hatice Celik Kansu<sup>1</sup> Ozlem Evliyaoglu<sup>1</sup> Esmâ Sarıkaya<sup>1</sup>  
Bugra Coskun<sup>1</sup> Salim Erkaya<sup>1</sup>

<sup>1</sup>Department of Gynaecology, Dr. Zekai Tahir Burak Women's Health Training and Research Hospital, Ankara, Turkey

Address for correspondence Burcu Kisa Karakaya, MD, Zekai Tahir Burak Women's Health Training and Research Hospital, Ankara, Turkey (e-mail: kisaburcu@gmail.com).

Rev Bras Ginecol Obstet 2017;39:229–234.

### Abstract

**Background** Preoperatively identification of malignancy potential of a postmenopausal adnexal masses is important.

**Aim** To evaluate the effectiveness of the Risk of Malignancy Index-2 in presumably benign adnexal masses in postmenopausal women.

**Study Design** Retrospective, observational study.

**Methods** 119 women with postmenopausal adnexal masses with a preliminary diagnosis of benign tumors according to the Risk of Malignancy Index-2 were included. Age, duration of menopause, ultrasonographic findings, and serum CA-125 levels were recorded preoperatively. The definitive diagnosis was based on postoperative histopathological examination.

**Results** Of 119 adnexal mass, 10 were malignant and 109 were benign. There was no statistically significant difference with regard to age and tumor size between the groups. The two significant ultrasonographic parameter between groups were the presence of solid area in the mass and bilaterality. Moreover, if the cut off point for serum CA-125 was adjusted to 14.75 IU/mL according to ROC curve, a sensitivity value of 80% and a specificity value of 72% could be achieved to discriminate benign and malign cysts.

**Conclusion** In the differential diagnosis of benign and malignant adnexal masses in postmenopausal women, the presence of a solid component, bilaterality based on ultrasonography and high CA-125 values may be used as discriminative criteria. There is no direct relation between the size of the adnexal mass and malignancy potential. Therefore, in the malignancy indexes of postmenopausal women, we recommend lower cut-off values of CA-125 to increase the sensitivity of preoperative evaluation tests without having a great impact on negative predictive values.

### Keywords

- ▶ adnexal mass
- ▶ transvaginal ultrasonography
- ▶ CA-125 antigen

received  
October 8, 2016  
accepted after revision  
January 6, 2017  
published online  
March 27, 2017

DOI <https://doi.org/10.1055/s-0037-1601454>.  
ISSN 0100-7203.

Copyright © 2017 by Thieme Revinter Publicações Ltda, Rio de Janeiro, Brazil

License terms



**Resumo**

**Introdução** É fundamental identificar o potencial maligno de massas anexiais pós-menopáusicas no período pré-operatório.

**Objetivo** Avaliar a efetividade do risco de malignidade (*risk of malignancy index-2*, RMI2) em massas anexiais benignas presumíveis em mulheres na pós-menopausa.

**Desenho do Estudo** Estudo observacional retrospectivo.

**Métodos** Este estudo foi conduzido em nossa clínica de cirurgia de endoscopia e endoscopia de nosso hospital entre janeiro de 2013 e setembro de 2015. Um total de 119 mulheres com massas anexiais pós-menopausa com diagnóstico preliminar de tumores benignos de acordo com o RMI-2. A idade, a duração da menopausa, os achados ultrassonográficos e os níveis séricos de CA-125 foram registrados no pré-operatório. O diagnóstico definitivo foi baseado no exame histopatológico pós-operatório.

**Resultados** A média de idade dos pacientes foi de  $55,4 \pm 6,71$  anos. O exame histopatológico revelou que 8,4% das massas anexiais eram tumores malignos ou limítrofes, enquanto 91,6% eram benignos. Não houve diferença estatisticamente significativa quanto ao tamanho do tumor e do tamanho das lesões entre patologias malignas e benignas. Não houve diferença estatisticamente significativa entre pacientes benignos e malignos quanto à idade e tamanho do tumor. Os dois parâmetros ultrassonográficos estatisticamente significativos entre os grupos foram a presença de área sólida na massa e bilateralidade. Além disso, se o ponto de corte para CA-125 sérico fosse ajustado para 14,75 UI/mL de acordo com a curva *receiver operating characteristic* (ROC), um valor de sensibilidade de 80% e um valor de especificidade de 72% poderiam ser conseguidos para discriminar cistos benignos e malignos (área sob a curva [ASC]: 0,89).

**Conclusão** No diagnóstico diferencial de massas anexiais benignas e malignas em mulheres pós-menopáusicas, a presença de um componente sólido, bilaterais com base na ultra-sonografia e valores elevados de CA-125 podem ser utilizados como critério discriminatório. Parece que não há relação direta entre o tamanho da massa anexial eo potencial maligno. Portanto, nos índices de malignidade de mulheres pós-menopáusicas, recomendamos valores de corte mais baixos de CA-125 para aumentar a sensibilidade dos testes de avaliação pré-operatória sem ter grande impacto em valores preditivos negativos.

**Palavras-chave**

- ▶ massa anexial
- ▶ ultrassonografia transvaginal
- ▶ antígeno CA-125

**Introduction**

Adnexal masses, which are lumps located in the tissue of the structures closely related to the uterus, such as the ovaries, the fallopian tubes, or any of the surrounding connective tissues, are pathologies commonly seen in the gynecology practice. The management of adnexal masses depends on their benign or malignant nature. Most of the ovarian cancers are epithelial in origin.<sup>1</sup> Malignant epithelial ovarian tumors often appear after the age of 50 years and increase to peak in the 7th decade of life. The increasing use of radiological tools as an investigation modality increases the number of asymptomatic adnexal masses diagnosed, which may, otherwise, be neglected.<sup>1</sup> Previously, all adnexal masses in postmenopausal women were managed by surgery to rule out malignancy.<sup>2</sup> Later, it became apparent that a vast majority of adnexal masses in postmenopausal women have a benign nature. However, a sharp increase in the incidence of ovarian cancer after the usual age of the onset of menopause is

observed. The survival rate in these later stages is around 23%, compared with 87% in stage 1.<sup>2,3</sup> In patients diagnosed with an advanced stage ovarian cancer, the 5-year survival rate is ~ 30–40%, whereas in those diagnosed at an early stage, the 5-year survival rate is ~ 90%.<sup>4</sup> Therefore, the way in which to best manage adnexal masses in postmenopausal women still remains controversial.

Ovarian cancer has non-specific symptoms and is usually silent in its early stages.<sup>5</sup> The most common symptoms are abdominal pain, and gastrointestinal and urinary symptoms due to the bulky mass, which occurs in the advanced stage of the disease.<sup>5</sup> Granulosa cell tumors and Sertoli-Leyding cell tumors are types of non-epithelial ovarian carcinoma, and can cause postmenopausal bleeding as a presenting symptom. The cotemporary preoperative work-up for an adnexal mass comprises taking the medical history and performing a physical examination, measuring the level of serum cancer antigen 125 (CA-125), and conducting imaging studies, mostly ultrasonography (USG). Currently, pelvic USG

remains the only imaging modality of choice to detect and characterize adnexal masses.<sup>6</sup> About 90% of adnexal masses can be adequately characterized with USG alone. The tumor markers should be combined with age, complexity of the mass, and medical history.<sup>6</sup> The level of serum CA-125 has a high sensitivity and low specificity for the identification of benign and malignant masses.<sup>7</sup> When USG fails to provide a definite diagnosis, other imaging tools such as magnetic resonance imaging (MRI) or novel biomarkers may be helpful, but their use is still largely controversial.<sup>8</sup>

Furthermore, the differential preoperative diagnosis of adnexal masses is complicated. A variety of diagnostic procedures is used, leading to a wide number of variables that may affect negatively the accurate interpretation of the nature of the adnexal masses.

Benign tumors can be managed by non-surgical interventions or minimal invasive surgery performed by a gynecologist. For women with high risk of ovarian cancer, a centralized, specialized, multi-disciplinary treatment provided by an experienced gynecological oncologist is warranted to improve survival.<sup>9-11</sup>

In recent years, novel strategies have been described that reflect the latest improvements in diagnostic tests for the preoperative characterization of ovarian masses and the diagnosis of ovarian cancer. These include the risk of ovarian malignancy algorithm (ROMA), the multivariate index assay known as OVA1, and the risk prediction models (logistic regression model 1 [LR1], logistic regression model 2 [LR2]) and decision rules (Simple Rules) developed by the International Ovarian Tumor Analysis (IOTA) study.<sup>12-14</sup> The risk of malignancy index (RMI) is a formula which was first described by Jacobs et al.<sup>15</sup> in 1990 for discriminating malignant adnexal masses.<sup>15-18</sup> In spite of the recent improvements, for most practitioners, the RMI is the most useful test in the daily practice.

In this study, we aimed to evaluate the effectiveness of the RMI in presumably benign adnexal masses in postmenopausal women.

## Methods

Written informed consent was obtained from each patient. The study protocol was approved by the institutional Ethics Committee. The study was conducted in accordance with the principles of the Declaration of Helsinki.

This retrospective, descriptive study included a total of 119 postmenopausal women who had adnexal masses and were treated in the gynecology and obstetrics clinic of a training and research hospital between January 2013 and September 2015. Data, including age, USG and tumor markers were analyzed, and the records of previously performed surgical interventions were collected from the hospital database. The postmenopausal status of the patients was documented by the presence of amenorrhea for at least 6 months and a follicle-stimulating hormone (FSH) level > 40 IU/mL.

Patients with adnexal masses were scanned by transvaginal USG. For all patients, the USG scan was performed with an endovaginal probe (5–6.5 MHz). The lesions were classi-

fied as unilocular cysts if they contained no septa, solid areas or papillary projections, and as multilocular cysts if they contained a septum or septa without any solid areas or papillary projections. In addition, patients with missing USG findings on their files were excluded.

The RMI can be simply defined as a mathematical calculation made by using the USG features of the mass, the menopausal status and the numeric value of the CA-125 levels. The choice of which USG scores and menopausal status multipliers to use varies among formulas. There are three additional RMI calculations described by other authors in the literature. In our study, the RMI2, which was described by Tingulstad et al<sup>16</sup>, was used to detect possible malignant adnexal lesions. An RMI cut-off value of 200 was considered an indicator of malignancy. Patients with RMI values above 200 were referred to the gynecologic oncology department of our hospital. Patients with RMI values below 200 were recruited and operated in our gynecology clinic by expert gynecologists.

The histopathology reports of the uterus and adnexa of the patients who were included in the study were examined by expert pathologists, and the pathology reports were obtained from the hospital database.

## Statistical Analysis

Statistical analysis was performed using the Statistical Package for the Social Sciences (SPSS, IBM SPSS Inc., Chicago, IL, US) software, version 15.0. Continuous variables were presented by mean  $\pm$  standard deviation (SD) with ranges. Categorical variables were expressed in frequencies and percentages. The chi-square test was used to analyze the statistical significance of the differences in binary data, while the Mann-Whitney U test was used to analyze the statistical significance of the differences in continuous data. The receiver operating characteristic (ROC) curve was used to calculate cut off Ca-125 level for detecting malignant adnexal mass.

## Results

A total of 119 pathological specimens of women with postmenopausal adnexal masses were examined. Of these, 109 were benign, and 10 were malignant ( $n = 6$ ) or borderline ( $n = 4$ ) lesions. The mean age was  $55.4 \pm 6.71$  (range, 40 to 71) years. Only one patient was 40 years old, based on the previous diagnosis of premature ovarian failure.

Total 47 (39.49%) adnexal masses were simple serous cysts, while 62 (52.10%) were non-neoplastic cysts, including dermoid cysts, myomas, endometriomas, mucinous cystadenomas, tubo-ovarian abscesses, hydrosalpinges, serous cysts, and adenofibromas. Ten neoplastic cysts contained four borderline ovarian tumors, three serous adenocarcinomas, one clear-cell carcinoma, one Sertoli-Leydig cell tumor, and one stromal tumor (**► Table 1**). A total of 22 women had bilateral lesions. Ten of them were diagnosed with malignant tumors (**► Table 2**). There were also fifteen multilocular cysts, three of them malignant. Out of 119 patients, 41 had solid areas, and 8 of them were diagnosed as malignant.

**Table 1** Histopathological diagnoses of the patients

Benign disease (n = 109)	n (%)
Dermoid cyst	11 (9.2)
Myoma	21 (17.6)
Endometrioma	3(2.5)
Simple cyst	47 (39.5)
Mucinous cystadenoma	8 (6.7)
Tuba-ovarian abscess	3(2.5)
Hydrosalpinges	13 (10.9)
Serous cyst adenofibroma	3 (2.5)
Malignant disease (n = 10)	n (%)
Borderline ovarian tumor	4 (3.4)
Adenocarcinoma	3 (2.5)
Clear cell carcinoma	1 (0.8)
Sertoli-Leydig cell tumor	1 (0.8)
Stromal tumor	1 (0.8)

There was a statistically significant difference in the percentage of solid areas of benign and malignant tumors compared with a previous examination ( $p = 0.003$ ). In 72 patients, the masses were smaller than 7 cm, and 5 of them were malignant. Total 5 out of 47 cases with an adnexal mass above 7 cm in diameter were malignant (► **Table 3**). Among malignant cases there was one patient and among benign cases there was one patient with more than one USG finding related to RMI. There was no significant difference in the USG scores between benign and malignant lesions. Considering the clinical characteristics of the malignant cases, none had CA-125 levels above 35 IU/mL, which was defined as the cut-off value for CA-125. The mean CA-125 levels of the benign and malignant patients were  $11.87 \pm 8.19$  and  $19.48 \pm 8.17$  respectively ( $p = 0.002$ ).

In our study, we included all postmenopausal women admitted to the gynecology outpatient clinic and diagnosed

with an adnexal mass. We investigated the possible reasons for the failure to diagnose the malignancy. We found that a specificity value of 91.6% was high for a screening test. When we investigated the malignant cases that were presumed as benign based on the RMI scores previously, 40% ( $n = 4$ ) were found to have borderline ovarian tumors. In all malignant cases, CA-125 levels were below the reference upper limit of 35 IU/mL. Moreover, the malignancy risk for postmenopausal women with a complex adnexal mass and with normal CA-125 levels was of 8.6%. The overall risk drops to 5.04% if the borderline tumors are excluded.

The ROC curve for accurate CA-125 levels in postmenopausal women with adnexal masses showed that marking down the cut-off value for CA-125 or increasing the effect of CA-125 in the calculation of the RMI might increase the accuracy of this index. If the cut-off value for CA-125 were adjusted to 14.75, a sensitivity of 80% and a specificity of 72% could be achieved. However, this would lead to a decrease in the negative predictive value, another challenge for practitioners (► **Fig. 1**).

## Discussion

Preoperative identification of the malignant potential is a challenging issue for a gynecologist. Currently, there is no screening test or preoperative diagnostic tool to diagnose ovarian carcinomas. At the postmenopausal age, due to an increased incidence of malignant adnexal masses, accurate preoperative investigation becomes more important. A well-known tumor marker, CA-125 has a low specificity in the early stages of the disease, and may also be elevated in some benign conditions.<sup>19</sup> In this study, we found that the risk of malignancy among postmenopausal women with USG findings of a complex adnexal mass who did not have elevated CA-125 levels or any other evidences of cancer was of 8.6%. When the borderline tumors were excluded, the risk was found to be of 5.04%.

It is not reasonable to consider that every woman with an adnexal mass can be operated in a center. Increasing the

**Table 2** Characteristics of patients with malignant adnexal tumors

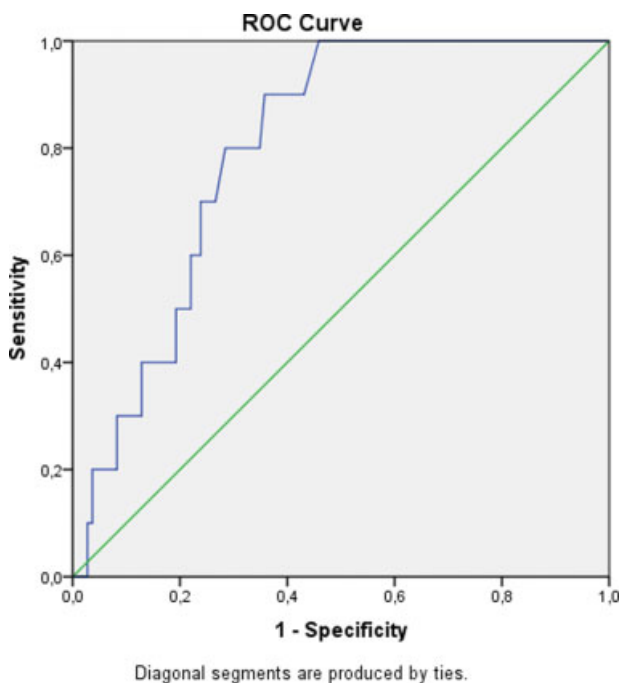
#	Age	Tumor size	CA-125	Surgical pathology	Bilaterality	Solid area
1	56	80	14.8	Borderline ovarian tumor	Yes	No
2	68	65	15.4	Borderline ovarian tumor	Yes	Yes
3	52	42	16.8	Borderline ovarian tumor	No	No
4	52	90	19.3	Borderline ovarian tumor	Yes	Yes
5	52	70	15.9	Adenocarcinoma	Yes	Yes
6	61	79	31.0	Adenocarcinoma	Yes	Yes
7	65	61	34.9	Adenocarcinoma	Yes	Yes
8	57	78	10.0	Clear cell carcinoma	Yes	Yes
9	54	40	24.7	Sertoli-Leydig cell tumor	Yes	Yes
10	56	80	14.8	Stromal tumor	Yes	Yes

Abbreviation: CA-125, cancer antigen 125.

**Table 3** Characteristics of postmenopausal women with adnexal masses

Patients (n = 119)	Benign (n = 109)	Malignant (n = 10)	p
Age			
Mean ± SD	55.4 ± 6.71	57.3 ± 5.63	NS
Range	40–71	52–68	
USG score			
< 1	108 (99.1%)	9 (90.0%)	
> 1	1 (0.9%)	1 (10.0%)	NS
USG features			
Bilaterality	13 (11.9%)	9 (90.0%)	< 0.001
Multilocularity	12 (11.0%)	3 (30.0%)	NS
Solid area	33 (30.3%)	8 (80.0%)	0.003
Ascites	1 (0.9%)	0 (0.0%)	NS
Tumor size			
Mean ± SD	62.6 ± 26.36	66.0 ± 16.66	NS
Range	20–156	40–90	
< 7 cm	67 (61.5%)	5 (50.0%)	
> 7 cm	42 (38.5%)	5 (50.0%)	NS
CA-125			
Mean ± SD	11.87 ± 8.19	19.48 ± 8.17	0.002
Range	2.8–50.0	10.0–34.9	

Abbreviations: CA-125, cancer antigen 125; NS, not significant (> 0.05); SD, standard deviation; USG, ultrasonography.



**Fig. 1** The receiver operating characteristic (ROC) curve of cancer antigen 125 (CA-125) in postmenopausal women with adnexal masses (n = 119). The area under the curve (AUC) was 0.898.

sensitivity of the preoperative assumption for malignancy should be the primary aim in investigations. The malignancy indexes such as the RMI are designed for the overall population. Correction of the RMI by adding the menopausal score increases the sensitivity of the RMI for postmenopausal women up to a certain extent. Several studies were designed to increase the sensitivity of the RMI without any significant decrease in the positive predictive values, increasing the cut-off values to 350 or 400.<sup>20,21</sup> In addition to the RMI index, The American Congress of Obstetricians and Gynecologists (ACOG) has published a guideline for the referral of patients with pelvic masses to a gynecologic oncologist.<sup>22</sup> According to the guideline recommendations, the cut-off value of postmenopausal CA-125 for the referral to a gynecologic oncologist is 35 IU/mL, while it is 200 IU/mL for premenopausal women.<sup>22</sup> In our study, all patients with the diagnosis of ovarian malignancy had CA-125 levels below 35 IU/mL. According to our findings, decreasing the cut-off value of CA-125 to 14.75 yielded a sensitivity of 80% and a specificity of 72%, using CA-125 as a single marker.

In general, for any test to diagnose ovarian malignancy, a high sensitivity, preferably over 90%, is essential, as such tests can correctly identify women with cancer, which is the key to the appropriate triage for specialists in high-volume oncology centers.<sup>23</sup> When using a score of 200 to indicate malignancy, the RMI misses 1 in 3 patients with ovarian cancer. Therefore, we consider that it is not a reasonable cut-off value to triage patients. In addition, as shown in phase 3 of

the IOTA study, a negative test result for the RMI is associated with a disproportionately high-risk of cancer (around 50%).<sup>24</sup>

Furthermore, our study focused on low-risk postmenopausal women, who are known as the weak side of the RMI in the literature. Increasing the importance of having solid components and bilaterality in the USG by increasing the index multipliers, which were the only two significantly different USG findings that were common to both benign and malignant cases, would increase the sensitivity of the preoperative evaluation by the RMI.

In conclusion, our study is the first to investigate postmenopausal women who were diagnosed with benign masses using the RMI 2. We believe that further similar studies will provide more information about the patients who cannot be differentiated by malignancy indexes. The importance of solid components, compared with other USG findings, will give us a clue for improving the sensitivity and positive predictive value of the RMI without adding an additional component, such as human epididymis protein 4 (HE4) or transferrin, which will increase the cost of the preoperative investigation.

## References

- Rufford B. Ovarian cysts in postmenopausal women. London: Royal College of Obstetricians and Gynaecologists; 2012 Green-top Guideline No. 34)
- Dørum A, Blom GP, Ekerhovd E, Granberg S. Prevalence and histologic diagnosis of adnexal cysts in postmenopausal women: an autopsy study. *Am J Obstet Gynecol* 2005;192(01):48–54
- Goldstein SR, Subramanyam B, Snyder JR, Beller U, Raghavendra BN, Beckman EM. The postmenopausal cystic adnexal mass: the potential role of ultrasound in conservative management. *Obstet Gynecol* 1989;73(01):8–10
- Morgan A. Adnexal mass evaluation in the emergency department. *Emerg Med Clin North Am* 2001;19(03):799–816
- Rossing MA, Wicklund KG, Cushing-Haugen KL, Weiss NS. Predictive value of symptoms for early detection of ovarian cancer. *J Natl Cancer Inst* 2010;102(04):222–229
- Brown DL, Dudiak KM, Laing FC. Adnexal masses: US characterization and reporting. *Radiology* 2010;254(02):342–354
- Davies AP, Jacobs I, Woolas R, Fish A, Oram D. The adnexal mass: benign or malignant? Evaluation of a risk of malignancy index. *Br J Obstet Gynaecol* 1993;100(10):927–931
- Biggs WS, Marks ST. Diagnosis and management of adnexal masses. *Am Fam Physician* 2016;93(08):676–681
- Vergote I, De Brabanter J, Fyles A, et al. Prognostic importance of degree of differentiation and cyst rupture in stage I invasive epithelial ovarian carcinoma. *Lancet* 2001;357(9251):176–182
- Carley ME, Klingele CJ, Gebhart JB, Webb MJ, Wilson TO. Laparoscopy versus laparotomy in the management of benign unilateral adnexal masses. *J Am Assoc Gynecol Laparosc* 2002;9(03):321–326
- Woo YL, Kyrgiou M, Bryant A, Everett T, Dickinson HO. Centralisation of services for gynaecological cancers - a Cochrane systematic review. *Gynecol Oncol* 2012;126(02):286–290
- Bast RC Jr, Skates S, Lokshin A, Moore RG. Differential diagnosis of a pelvic mass: improved algorithms and novel biomarkers. *Int J Gynecol Cancer* 2012;22(Suppl 1):S5–S8
- Timmerman D, Testa AC, Bourne T, et al. Simple ultrasound-based rules for the diagnosis of ovarian cancer. *Ultrasound Obstet Gynecol* 2008;31(06):681–690
- Timmerman D, Testa AC, Bourne T, et al; International Ovarian Tumor Analysis Group. Logistic regression model to distinguish between the benign and malignant adnexal mass before surgery: a multicenter study by the International Ovarian Tumor Analysis Group. *J Clin Oncol* 2005;23(34):8794–8801
- Jacobs I, Oram D, Fairbanks J, Turner J, Frost C, Grudzinskas JG. A risk of malignancy index incorporating CA 125, ultrasound and menopausal status for the accurate preoperative diagnosis of ovarian cancer. *Br J Obstet Gynaecol* 1990;97(10):922–929
- Tingulstad S, Hagen B, Skjeldestad FE, et al. Evaluation of a risk of malignancy index based on serum CA125, ultrasound findings and menopausal status in the pre-operative diagnosis of pelvic masses. *Br J Obstet Gynaecol* 1996;103(08):826–831
- Tingulstad S, Hagen B, Skjeldestad FE, Halvorsen T, Nustad K, Onsrud M. The risk-of-malignancy index to evaluate potential ovarian cancers in local hospitals. *Obstet Gynecol* 1999;93(03):448–452
- Yamamoto Y, Yamada R, Oguri H, Maeda N, Fukaya T. Comparison of four malignancy risk indices in the preoperative evaluation of patients with pelvic masses. *Eur J Obstet Gynecol Reprod Biol* 2009;144(02):163–167
- Cure MC, Cure E, Kirbas A, Yazici T, Yuce S. Requests for tumor marker tests in Turkey without indications and frequency of elevation in benign conditions. *Asian Pac J Cancer Prev* 2012;13(12):6485–6489
- Obeidat BR, Amarin ZO, Latimer JA, Crawford RA. Risk of malignancy index in the preoperative evaluation of pelvic masses. *Int J Gynaecol Obstet* 2004;85(03):255–258
- Ashrafgangooei T, Rezaeezadeh M. Risk of malignancy index in preoperative evaluation of pelvic masses. *Asian Pac J Cancer Prev* 2011;12(07):1727–1730
- American College of Obstetricians and Gynecologists Committee on Gynecologic Practice. Committee Opinion No. 477: the role of the obstetrician-gynecologist in the early detection of epithelial ovarian cancer. *Obstet Gynecol* 2011;117(03):742–746
- Kaijser J, Bourne T, Valentin L, et al. Improving strategies for diagnosing ovarian cancer: a summary of the International Ovarian Tumor Analysis (IOTA) studies. *Ultrasound Obstet Gynecol* 2013;41(01):9–20
- Testa A, Kaijser J, Wynants L, et al. Strategies to diagnose ovarian cancer: new evidence from phase 3 of the multicentre international IOTA study. *Br J Cancer* 2014;111(04):680–688