

Joint Space Width and Osteoarthritis in Patients Undergoing Hip Arthroscopy

Tyler S. Pidgeon, MD¹ Jonathan R. Schiller, MD¹ Joseph A. Gil, MD¹ Peter T. Evangelista, MD²
Jason T. Machan, SCM, PhD¹ Ramin R. Tabaddor, MD³

¹Department of Orthopaedic Surgery, Brown University Warren Alpert Medical School, Providence, Rhode Island

²Department of Diagnostic Imaging, Brown University Warren Alpert Medical School, Providence, Rhode Island

³Department of Orthopaedic Surgery, South County Orthopedics and Sports Medicine, East Greenwich, Rhode Island

Address for correspondence Joseph A. Gil, MD, Department of Orthopaedic Surgery, Brown University Warren Alpert Medical School, 593 Eddy St., Providence, RI 02912 (e-mail: joseph_gil@brown.edu).

J Hip Surg 2017;1:99–104.

Abstract

Preoperative hip joint space width (JSW) of ≤ 2 mm on plain radiography has been shown to be predictive of intraoperative findings of osteoarthritis, worse functional outcomes, and failure to total hip arthroplasty following hip arthroscopy. However, there is no evidence to suggest that hip joint space greater than 2 mm can definitively rule out the presence of osteoarthritis. We hypothesize that a preoperative JSW of 2 mm or greater does not reliably rule out the presence of high-grade arthritis on hip arthroscopy. Retrospective review of 50 patients who underwent hip arthroscopy between January 11, 2010, and January 3, 2015, at a single institution was performed. Preoperative, standing anteroposterior hip radiographs were reviewed to determine the minimum hip JSW of each operative hip. Operative notes and images were reviewed to determine the Outerbridge classification of cartilage changes on both the acetabulum and femoral head for each patient. High-grade arthritis was defined as a minimum of grade 3 changes on either the femoral head or the acetabulum, which was required for inclusion in the study. The sensitivity of a JSW of 2 mm or less on preoperative radiographs to diagnose a patient with grade 3, grade 4, and grade 3 or 4 arthritis was calculated. Linear regression was used to test for an association between Outerbridge grading and the radiographic minimum JSW. The mean JSW for all patients was 3.5 ± 1.2 mm (range: 0–5.5 mm). Regression found an inverse relationship between joint space and the arthroscopic grading of the articular surfaces ($p = 0.0031$). However, a preoperative JSW of ≤ 2 mm was only 14.3% sensitive (95% confidence interval [CI] 2.6–51.3%) for predicting Outerbridge grade 3 changes, 7.3% sensitive (95% CI: 2.5–19.4%) for predicting Outerbridge grade 4 changes, and 8.3% sensitive (95% CI: 3.3–20.6%) for predicting Outerbridge grade 3 or 4 changes. The threshold of ≤ 2 mm of hip JSW on plain radiographs has poor sensitivity for predicting the existence of high-grade arthritis.

Keywords

- ▶ hip arthroscopy
- ▶ radiology
- ▶ joint space width
- ▶ osteoarthritis

received
April 13, 2017
accepted
May 30, 2017
published online
June 20, 2017

Copyright © 2017 by Thieme Medical Publishers, Inc., 333 Seventh Avenue, New York, NY 10001, USA.
Tel: +1(212) 584-4662.

DOI <https://doi.org/10.1055/s-0037-1603963>.
ISSN 2472-8446.

The diagnosis of hip osteoarthritis (OA), particularly in its earliest stages, can be challenging. Although advanced imaging techniques are being developed, plain radiographs remain the most common imaging modality used for this diagnosis.¹⁻³ Since cartilage is radiolucent and cannot be directly visualized on plain radiographs, joint space width (JSW) is thought to represent the presence of articular cartilage. Consequently, the loss of JSW is predicted to correspond to degeneration of articular cartilage. Previous studies have demonstrated that the measurement of the smallest JSW, or minimum interbone distance (MID), on plain radiographs is highly reproducible and suitable for monitoring the progression of OA.¹

Philippon et al showed that JSW of 2 mm or less on plain radiographs predicted conversion to total hip arthroplasty (THA) at 3 years following hip arthroscopy and that patients with 2 mm of JSW or less were 12 times more likely to undergo THA.³ Multiple authors have confirmed that joint space narrowing is a risk factor for THA following hip arthroscopy.^{4,5} In a recent systematic review, Domb et al also concluded that patients with a JSW of 2 mm or less are more likely to undergo THA and less likely to benefit from hip arthroscopy.⁶ These findings have suggested that a JSW of 2 mm may be used as a cutoff to separate patients with substantial OA and those with preserved hip joints.

However, JSW on plain radiographs remains an indirect measurement of the presence of articular cartilage with high variability among asymptomatic patients; thus, the reliability of this metric remains unclear.² Chu Miow Lin et al performed a systematic literature review on this subject in 2011 and found only a weak association between JSW and OA symptoms.⁷ In fact, while there is evidence that a preoperative JSW of 2 mm or less is predictive of failure to THA following hip arthroscopy, there is no evidence to suggest that JSW greater than 2 mm on plain hip radiographs can definitively rule out the presence of substantial cartilage wear.

Given the uncertainty of the accuracy of measuring JSW on plain radiographs in the diagnosis of hip OA, the purpose of our study is to determine whether patients with > 2 mm of JSW on preoperative radiographs are protected from high-grade cartilage changes. We hypothesize that a preoperative JSW of > 2 mm does not reliably rule out the presence of high-grade arthritis on hip arthroscopy.

Materials and Methods

After study examination and approval by our institutional review board (#654668-1), patient charts of the senior authors (J.R.S., R.R.T.) of this article were reviewed from January 11, 2010, to January 3, 2015. Inclusion criteria comprised having undergone hip arthroscopy during the above timeframe, being between 16 and 70 years of age at the time of arthroscopy, and having quality, preoperative, standing anteroposterior (AP) radiographs of the operative hip available for review. Exclusion criteria included history of previous hip surgery, history of previous hip trauma (dislocation or fracture), and present or past diagnosis of developmental dysplasia of the hip (DDH), slipped capital femoral epiphysis (SCFE), Legg–Calve–Perthes' disease, avascular necrosis (AVN) of the hip, pigmented villo-

nodular synovitis, synovial chondromatosis, fibrous dysplasia, or hip instability. If a patient had undergone multiple arthroscopies of the same hip, only data from the first performed arthroscopy were included in the study. Out of 163 initially screened patients, 12 were excluded for being outside the study age range, 10 due to lack of quality radiographs, 7 due to history of treatment for DDH, 2 due to history of dislocation, 2 due to previous acetabular fracture, 2 due to history of Legg–Calve–Perthes' disease, 1 due to hip trauma causing arthritis, 1 due previous treatment for SCFE, and 1 due to history of fibrous dysplasia.

Operative notes and/or arthroscopic photographs of the 125 remaining patients were reviewed and converted into OA grades for both the acetabulum and femoral head using the Outerbridge classification (►Fig. 1; ►Table 1).⁸⁻¹⁰ Patients with grade 3 or 4 Outerbridge changes on the femoral and/or acetabular side of the hip were identified and included in the study ($n = 50$). Any patients without at least grade 3 changes on either the femoral head or the acetabulum were excluded from analysis ($n = 75$). Of the 50 study patients, 18 patients were female; the average patient age at the time of surgery was 44 ± 12 (range: 20–70). Of note, two patients did not have sufficient operative note descriptions or arthroscopic photos to make an accurate judgment of femoral head grade, and thus they were not included in any part of data analysis that required grading of the femoral head.

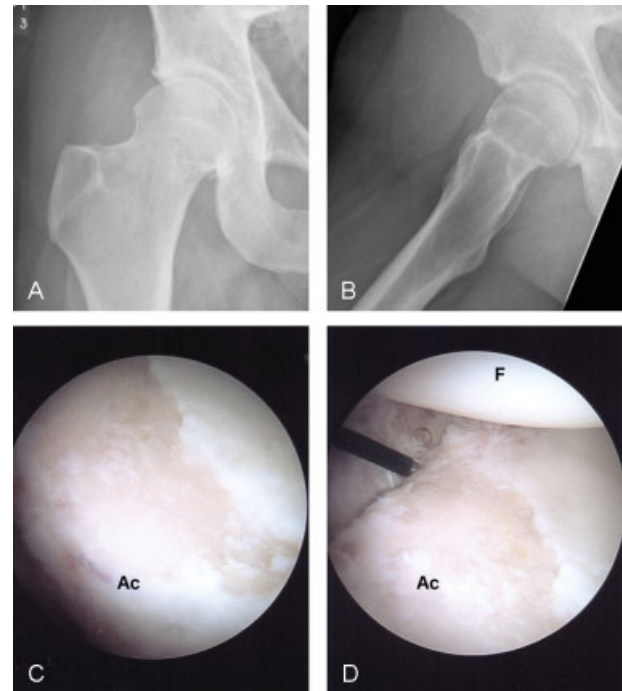

Fig. 1 Hip Arthroscopy demonstrates the preoperative radiographs (A,B) and intraoperative arthroscopy images (C,D) of patient 8. This 26 year-old man underwent right hip arthroscopy, labral and chondral surface debridement, and removal of loose bodies. The joint space width in (A) was measured to be 4.3 mm. However, during arthroscopy, the patient was noted to have grade 4 changes of the acetabular cartilage (C). Notice in (D) that the patient's femoral head cartilage is pristine, which likely accounts for why this patient has ample joint space width on radiographs despite high-grade cartilage changes intraoperatively. Ac, Acetabulum; F, femoral head. (Radiographs and pictures courtesy of Dr. Ramin R. Tabaddor.)

Table 1 Outerbridge classification

Grade 0	Normal cartilage
Grade 1	Softening and swelling of cartilage
Grade 2	Partial-thickness defect; fissures ≤ 1.5 cm that do not reach subchondral bone
Grade 3	Fissures > 1.5 cm that reach subchondral bone
Grade 4	Exposed subchondral bone

High-grade arthritis visualized during arthroscopy was defined for the purposes of this study as grade 3 changes or greater. High-grade arthritis on radiographs was defined as JSW (specifically, the MID) of less than or equal to 2 mm based on findings from previous studies that this cutoff is predictive of conversion to THA.^{3,6} A single musculoskeletal radiologist who was blinded to all arthroscopic findings read each of the radiographs to minimize variability in radiographic interpretation. Joint space was reported as the MID on standing AP radiographs using a digital caliper system. All measurements assume a standard film-screen distance.

During statistical analysis, comparison of mean acetabulum grades to mean femoral head grades across all patients was performed using a two-sample *t*-test assuming equal variance (► **Table 2**). Next, the mean values for minimum JSW between patients with at least grade 4 changes and patients with less than grade 4 changes were also compared using a two-sample *t*-test assuming equal variance (► **Table 3**). Additionally, the sensitivity of a JSW of 2 mm or less on preoperative radiographs as a threshold to diagnose patients with grade 3, grade 4, and grade 3 or 4 arthritis was calculated (► **Table 4**), and Wilson's simple asymptotic method was used to determine 95% confidence intervals (CIs). The specificity of this threshold is not possible to calculate since it was not feasible in our context to estimate

Table 2 Patient summary

<i>N</i> = 50 (18 F)	Mean	<i>p</i> -Value
Joint space width (mm)	3.5 ± 1.2	
Age (y)	44 ± 12	
Acetabular grade	3.7 ± 0.6	
Femoral grade	2.4 ± 1.3	<0.01

Abbreviation: F, female.

Note: Acetabular grade and femoral grade indicate arthroscopic grades based on the Outerbridge classification.

Table 3 Grade 4 versus less than grade 4 arthritis

Group	Average JSW (mm)	<i>p</i> -Value
Grade 4 (<i>N</i> = 41)	3.5 ± 1.1	
Less than grade 4 (<i>N</i> = 7)	3.2 ± 1.7	0.5

Abbreviation: JSW, joint space width.

Table 4 Joint space width as a predictor of hip arthritis

Maximum acetabular/femoral head grade	Grade 3	Grade 4	Grade 3 or 4
All patients			
≤ 2 mm	1	3	4
Total	7	41	48
Sensitivity	14.3%	7.3%	8.3%
95% confidence interval	2.6–51.3%	2.5–19.4%	3.3–20.6%

joint space in all hip arthroscopy patients from the studied time frame. Additionally, an ordinal scale was created from the cartilage gradings of the femoral head and acetabulum by rank ordering based on the minimum grade and then the maximum grade. Because all included patients had at least one grade 3 or 4, eight combinations were observed: [0,4], [1,3], [1,4], [2,3], [2,4], [3,3], [3,4], and [4,4], with only [0,3] not represented. A linear regression was then used to test for an association between the ordinal grade and the radiographic minimum JSW measured between the acetabulum and the femoral head (► **Fig. 2**).

Results

All patients had at least grade 3 changes during arthroscopy on the acetabulum and/or the femoral head. The mean JSW for all patients was 3.5 ± 1.2 mm (range: 0–5.5 mm). The mean acetabular Outerbridge grade was 3.7 ± 0.6 (range: 1–4). The mean femoral head Outerbridge grade was 2.4 ± 1.3 (range: 0–4). There was a statistically significant difference between acetabular and femoral head grades (*p* < 0.01; ► **Table 2**).

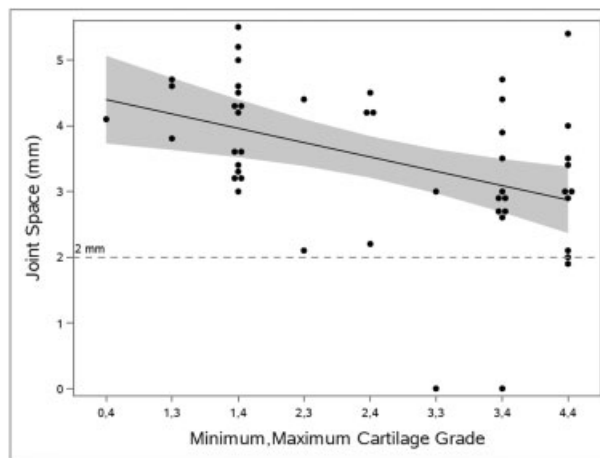


Fig. 2 Regression analysis charts joint space with respect to combined acetabular and femoral Outerbridge grade. There is an inverse relationship between joint space and Outerbridge grading (*p* = 0.0031), and it is clear that most joint space measurements in this population with at least Outerbridge grade 3 changes on arthroscopy fall above the threshold of 2 mm (dashed horizontal line).

This document was downloaded for personal use only. Unauthorized distribution is strictly prohibited.

A preoperative JSW of ≤ 2 mm was 14.3% sensitive (95% CI: 2.6–51.3%) for predicting Outerbridge grade 3 changes, 7.3% sensitive (95% CI: 2.5–19.4%) for predicting Outerbridge grade 4 changes, and 8.3% sensitive (95% CI: 3.3–20.6%) for predicting Outerbridge grade 3 or 4 changes (►Table 4). Notably, in this study population of 48 patients (not including those missing femoral head data) with documented grade 3 or 4 changes, only four patients would have been predicted to have high-grade arthritis based on the preoperative JSW ≤ 2 mm metric.

Linear regression analysis validated the existence of a relationship between joint space and the arthroscopic grading of the articular surfaces of the femoral head and acetabulum ($p = 0.0031$; ►Fig. 2). However, it was also apparent that the vast majority of joint space estimates are above the threshold of 2 mm.

Forty one patients had at least grade 4 changes on either the acetabulum or femoral head with a mean JSW of 3.5 ± 1.1 mm (range: 0–5.5 mm) (►Table 3). Comparatively, seven patients had less than grade 4 changes of both the acetabulum and the femoral head with a mean JSW of 3.2 ± 1.7 mm (range: 0–4.7 mm). The difference between these two groups was not statistically significant ($p = 0.5$).

Discussion

Measuring the smallest JSW (or MID) on plain radiographs is highly reproducible and has been suggested to be a suitable method for monitoring OA progression in patients with hip arthritis.¹ Furthermore, a JSW of less than or equal to 2 mm has been demonstrated to be predictive of a patient's future need for THA.³ However, JSW is merely an indirect measurement of articular cartilage on plain radiographs, and there is no conclusive evidence that a JSW of >2 mm rules out high-grade arthritis.

In 2014, Skendzel et al studied 466 adult patients who had undergone hip arthroscopy for femoroacetabular impingement.¹¹ They found that patients with JSW ≤ 2 mm were 10.8 times (95% CI: 4.6–6.8) ($p = 0.001$) as likely to have Outerbridge grade 3 or 4 defects. They also reported an 86% (54/63) conversion rate to THA among patients with JSW ≤ 2 mm compared with 16% (63/683) among patients with JSW > 2 mm. Notably, at a mean follow-up of 73 months, they found higher hip outcome scores for activities of daily living and sports in patients with JSW > 2 mm.¹¹

In 2009, Byrd and Jones studied 29 patients (31 hips) who underwent hip arthroscopy for acetabular labrum tears and had 10-year follow-up.¹² Using the modified Harris Hip Score preoperatively and postoperatively at 3, 12, 24, 60, and 120 months, the authors demonstrated worse outcomes ($p < 0.001$) in patients with preoperative, clinically diagnosed arthritis. In fact, 88% (7/8) of patients with preoperative hip arthritis converted to THA by final follow-up.¹²

Due to the retrospective nature of our study, it was convenient to select for only patients with known high-grade arthritis (Outerbridge grade 3 or greater) based on the gold standard test of hip arthroscopy. We could then look back at the preoperative radiographs and with the benefit of hind-

sight determine whether or not the 2-mm-JSW threshold would have ruled in severe cartilage damage prior to arthroscopy in these patients.

Fascinatingly, in our cohort of 50 patients with known high-grade hip cartilage changes, the mean preoperative JSW was 3.5 mm, a full standard of deviation (1.2 mm) greater than the 2-mm threshold (►Table 2). Furthermore, only 4 of the 48 patients (8.3%) with known high-grade changes included in statistical analysis met the criteria of JSW ≤ 2 mm on preoperative radiographs, making this threshold poorly sensitive for high-grade cartilage wear (►Table 4). Consequently, a JSW of > 2 mm did not reliably rule out the discovery of high-grade changes during arthroscopy. When combined with Philippon et al's findings that patients with JSW ≤ 2 mm are at increased risk for requiring THA, orthopaedic surgeons may use these data to counsel preoperative hip arthroscopy patients that while a JSW of ≤ 2 mm almost certainly demonstrates advanced degenerative joint disease (high specificity), a JSW of > 2 mm does not necessarily rule out the presence of high-grade arthritis during surgery (poor sensitivity).³ This is an important point since Outerbridge high-grade lesions (grade 3 or 4) independent of JSW have been associated with increased failure of hip arthroscopy to THA at 10 years.¹³

In addition, our study did demonstrate a relationship between joint space and the arthroscopic grading of the hip articular surfaces through linear regression analysis (►Fig. 2). However, most of the joint space estimates were above the threshold of 2 mm. Combined with the sensitivity data, these results suggest that while a narrowed joint space had prognostic value for predicting replacement in other studies, applying this threshold when considering the existence of high-grade arthritis would have extremely low and unacceptable sensitivity, regardless of specificity.

Finally, patients with at least Outerbridge grade 4 changes on either the acetabulum or the femoral head did not differ significantly from patients with less than grade 4 changes with respect to preoperative JSW (►Table 3). This demonstrates that patients with the most severe arthritis on arthroscopy could not be differentiated from those with less severe arthritis based on preoperative radiographs alone.

Our findings may be explained by the nature of plain radiographs as an indirect measure of radiolucent structures such as cartilage. Outerbridge grade 3 or 4 lesions that take up a small proportion of the total size of the acetabulum, while likely symptomatic, may not cause loss of joint space on radiographs especially when the femoral head is minimally involved (►Fig. 3). This was the case in our study where patients were found to have significantly higher-grade acetabulum changes (mean: 3.7) compared with femoral head changes (mean: 2.4). For joint space loss to be evident on plain radiographs, cartilage changes must take up a significant portion of the joint surfaces, be adjacent to each other in space, or both (►Fig. 4). Additionally, it is possible that in patients with an intact labrum, its suction effect helps temporarily maintain JSW despite cartilage loss. For these reasons, plain radiographs do not tell the whole story with respect to the presence of high-grade arthritis found at the time of arthroscopy.

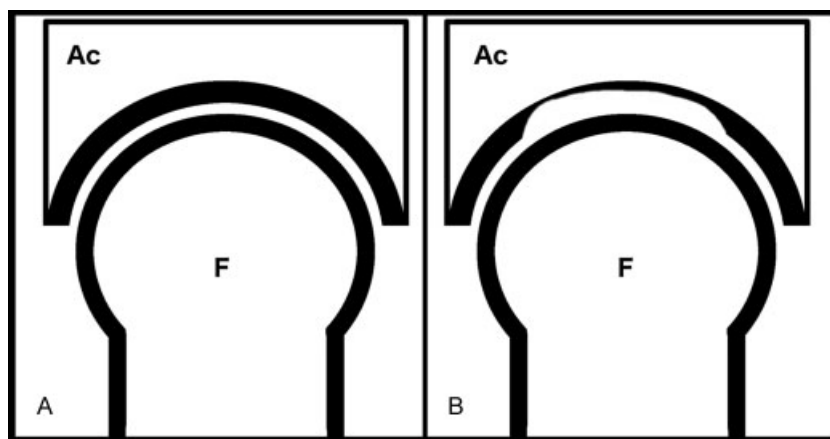


Fig. 3 Hip arthritis without joint space narrowing illustrates how patients may demonstrate advanced Outerbridge cartilage injury grades (3–4) during hip arthroscopy while maintaining a joint space width (JSW) of >2 mm on preoperative radiographs. (A) This represents a hip without arthritis (Outerbridge grade 0) for reference. (B) This represents a hip with Outerbridge grade 3 or 4 findings on the acetabulum without a change in JSW due to the maintained cartilage on the femoral head. Ac, Acetabulum; F, femoral head.

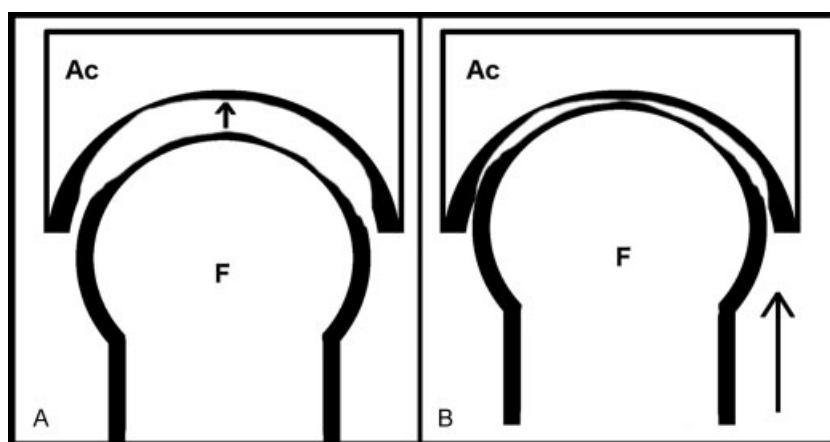


Fig. 4 Hip arthritis with joint space narrowing in contrast to ▶ Fig. 3, this figure demonstrates how patients with large, adjacent cartilage defects (Outerbridge grade 3 or 4) on the femoral head and acetabulum (A) lose joint space width on preoperative radiographs (B). Notice that these large lesions that take up a substantial portion of the cartilage surface also line up in space, leading to decreased distance between the femoral head and acetabulum. Ac, Acetabulum; F, femoral head.

One potential alternative to plain radiography for preoperative evaluation of hip degeneration is delayed gadolinium-enhanced MRI (magnetic resonance imaging) of cartilage (dGEMRIC).¹⁴ Techniques implementing dGEMRIC take advantage of the loss of glycosaminoglycans (GAGs), which are negatively charged, during cartilage degeneration. In dGEMRIC, the negatively charged contrast agent, gadopentetate dimeglumine, enters the cartilage more efficiently as GAGs are lost, improving the ability of MRI to quantify the biochemical degradation of cartilage.¹⁴ As demonstrated by Bulat et al in 2015, Outerbridge grading and the dGEMRIC index correlate moderately to strongly with Beck's intraoperative grade during hip arthroscopy.¹⁴ While promising, it should be noted that dGEMRIC is not readily available to most orthopaedic surgeons.

Our study has numerous limitations. First, our study is limited by the accuracy and reproducibility of the Outerbridge classification, which was not initially designed to classify hip cartilage loss.⁸ Second, with only 50 patients

(two of whom did not have adequate information on the femoral head for complete statistical analysis), it is possible that our study is not completely representative of the population at large. Finally, our study design was preselected for patients with at least grade 3 arthritis on arthroscopy in a retrospective fashion, which makes it more vulnerable to inherent bias than a prospective study.

Conclusion

While a JSW of ≤ 2 mm on radiographs has been shown to be predictive of poor functional outcomes and even conversion to THA in patients undergoing arthroscopy of the hip, a JSW of > 2 mm does not reliably rule out high-grade arthritis. Thus, when counseling patients undergoing hip arthroscopy, orthopaedic surgeons should note that even those patients with preoperative JSW > 2 mm are at risk for demonstrating high-grade arthritic changes during surgery.

References

- 1 Conrozier T, Lequesne M, Favret H, et al. Measurement of the radiological hip joint space width. An evaluation of various methods of measurement. *Osteoarthritis Cartilage* 2001;9(03):281–286
- 2 Nishii T, Shiomi T, Sakai T, Takao M, Yoshikawa H, Sugano N. Computational measurement of joint space width and structural parameters in normal hips. *Arch Orthop Trauma Surg* 2012;132(05):591–598
- 3 Philippon MJ, Briggs KK, Carlisle JC, Patterson DC. Joint space predicts THA after hip arthroscopy in patients 50 years and older. *Clin Orthop Relat Res* 2013;471(08):2492–2496
- 4 Philippon MJ, Briggs KK, Yen YM, Kuppersmith DA. Outcomes following hip arthroscopy for femoroacetabular impingement with associated chondrolabral dysfunction: minimum two-year follow-up. *J Bone Joint Surg Br* 2009;91(01):16–23
- 5 Philippon MJ, Schroder E Souza BG, Briggs KK. Hip arthroscopy for femoroacetabular impingement in patients aged 50 years or older. *Arthroscopy* 2012;28(01):59–65
- 6 Domb BG, Gui C, Lodhia P. How much arthritis is too much for hip arthroscopy: a systematic review. *Arthroscopy* 2015;31(03):520–529
- 7 Chu Miow Lin D, Reichmann WM, Gossec L, Losina E, Conaghan PG, Maillefert JF. Validity and responsiveness of radiographic joint space width metric measurement in hip osteoarthritis: a systematic review. *Osteoarthritis Cartilage* 2011;19(05):543–549
- 8 Cameron ML, Briggs KK, Steadman JR. Reproducibility and reliability of the Outerbridge classification for grading chondral lesions of the knee arthroscopically. *Am J Sports Med* 2003;31(01):83–86
- 9 Outerbridge RE, Dunlop JA. The problem of chondromalacia patellae. *Clin Orthop Relat Res* 1975;(110):177–196
- 10 Outerbridge RE. The etiology of chondromalacia patellae. *J Bone Joint Surg Br* 1961;43-B:752–757
- 11 Skendzel JG, Philippon MJ, Briggs KK, Goljan P. The effect of joint space on midterm outcomes after arthroscopic hip surgery for femoroacetabular impingement. *Am J Sports Med* 2014;42(05):1127–1133
- 12 Byrd JW, Jones KS. Hip arthroscopy for labral pathology: prospective analysis with 10-year follow-up. *Arthroscopy* 2009;25(04):365–368
- 13 McCarthy JC, Jarrett BT, Ojeifo O, Lee JA, Bragdon CR. What factors influence long-term survivorship after hip arthroscopy? *Clin Orthop Relat Res* 2011;469(02):362–371
- 14 Bulat E, Bixby SD, Siversson C, Kalish LA, Warfield SK, Kim Y-J. Planar dGEMRIC Maps May Aid Imaging Assessment of Cartilage Damage in Femoroacetabular Impingement. *Clin Orthop Relat Res* 2016;474(02):467–478