

A Very Unlikely Finding in a Male Child: Urethral Prolapse

Çiğdem Ulukaya Durakbaşı¹ Gonca Gerçel¹ Murat Huseyin Mutus¹ Burhan Aksu¹ Seyma Ozkanlı²

¹Department of Pediatric Surgery, Istanbul Medeniyet University Goztepe Training and Research Hospital, Istanbul, Turkey

²Department of Pathology, Istanbul Medeniyet University Goztepe Training and Research Hospital, Istanbul, Turkey

Address for correspondence Professor Çiğdem Ulukaya Durakbaşı, MD, Department of Pediatric Surgery, Istanbul Medeniyet University Goztepe Training and Research Hospital, Dr. Erkin Caddesi Kadıköy, Istanbul 34722, Turkey (e-mail: cigdemulukaya@yahoo.com).

Eur J Pediatr Surg Rep 2017;5:e36–e38.

Abstract

Urethral prolapse is a disease of prepubertal black girls and postmenopausal women with an unknown cause. It may be congenital in origin or an acquired condition. It has never been reported in males. We report a 10-year-old Caucasian boy who presented because of recurrent right undescended testis. He had been operated on for bilateral undescended testes 7 years ago in another hospital, and circumcision was done during the same operation. The boy complained of a weak urinary stream during voiding. The physical examination was consistent with recurrent right undescended testis. Penile examination showed a circumferential urethral prolapse around the meatus. The urethral meatal appearance was apparent right after the circumcision. An orchiopexy operation as well as circumferential excision of the perimeatal urethral tissue with primary repair was done. The pathological examination of the specimen revealed keratinized stratified squamous epithelium consistent with urethral mucosa. The postoperative course was uneventful, and the patient urinates normally at the 8 postoperative month with a normal uroflowmetry study. This is the first report of urethral prolapse in a male. Because circumcision is a widely employed practice in many cultures, it is unlikely to be a predisposing factor. It is a benign condition that can be cured with simple resection and anastomosis.

Keywords

- ▶ urethral prolapse
- ▶ urethral meatus
- ▶ urethral anomaly
- ▶ male urethra

New Insights and the Importance for the Pediatric Surgeon

This is the first case report of urethral prolapse in a male. Primary resection and anastomosis of the prolapsing mucosa were curative.

Introduction

Most urethral anomalies are rare in children. Among the anomalies, such as lacuna magna, anterior urethral valves, megalourethra, urethral duplication, and urethral polyps, only “urethral prolapse” is considered to be unique to

females.^{1–3} Urethral prolapse is a benign condition in which distal urethra protrudes circumferentially through the external meatus. The etiology is obscure, and it may be congenital or acquired.² As a benign condition, conservative as well as surgical treatment options were described with generally good long-term results.

received
June 9, 2017
accepted
June 18, 2017

DOI <https://doi.org/10.1055/s-0037-1604359>.
ISSN 2194-7619.

© 2017 Georg Thieme Verlag KG
Stuttgart · New York

License terms



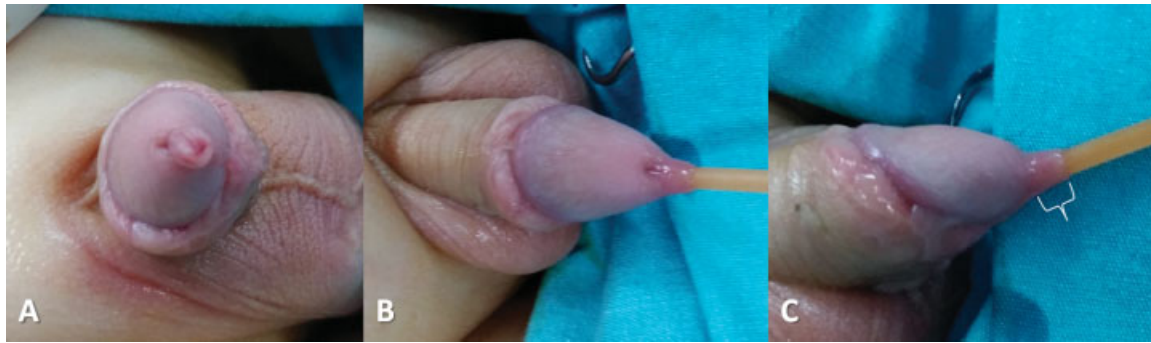


Fig. 1 The preoperative appearance of the urethral meatus is seen in neutral position (A) and with a catheter in (B and C). The prolapsed mucosa was a couple of millimeters long (curved bracelet in C).

This report presents a male child with clinical findings consistent with urethral prolapse and successfully treated surgically.

Case Report

A 10-year-old Caucasian boy presented because of recurrent right undescended testis. He had been operated on for bilateral undescended testes 7 years ago in another center, and circumcision was done during the same operation. The boy complained of a weak urinary stream during voiding. The physical examination was consistent with recurrent right undescended testis with the testis lying in the inguinal canal. Penile examination showed a circumferential urethral prolapse of a couple of millimeters long around the urethral meatus (→**Fig. 1**). Upon questioning, the family stated that the urethral meatal appearance was noticed right after the circumcision. The urethral meatus was getting more prolapsed during voiding and was retracting back as shown in a home video they supplied (→**Video 1**). An ultrasound examination of the upper and lower urinary tracts was normal. An orchiopexy operation as well as circumferential excision of the perimeatal prolapsing tissue with primary repair was done (→**Fig. 2**). The postoperative course was uneventful. The pathological examination of the specimen revealed keratinized stratified squamous epithelium, which is consistent with urethral mucosa (→**Fig. 3**). A uroflow study performed

at the sixth postoperative week was normal with a maximal flow rate of 27 mL/s and an average flow rate of 13 mL/s. He is free of any complaints at the eighth postoperative month.

Video 1

Prolapsing urethral mucosa during voiding partially retracts at the completion of voiding. Online content including video sequences viewable at: www.thieme-connect.com/products/ejournals/html/10.1055/s-0037-1604359.

Discussion

Distal urethral anomalies other than hypospadias are seldom encountered in male children. Urethral prolapse is one of the rare conditions involving distal urethra. However, it is known to exclusively involve “female” urethra.^{3,4} It has never been reported in a male.

Urethral prolapse has a bimodal age distribution and most commonly occurs in prepubertal black females and postmenopausal white women.^{3,5,6} It may either be congenital or acquired.^{2,6} The etiological mechanism has not been clarified yet. It may be caused by disproportional growth in childhood, estrogen deficiency, malnutrition, weak pelvic floor muscles,

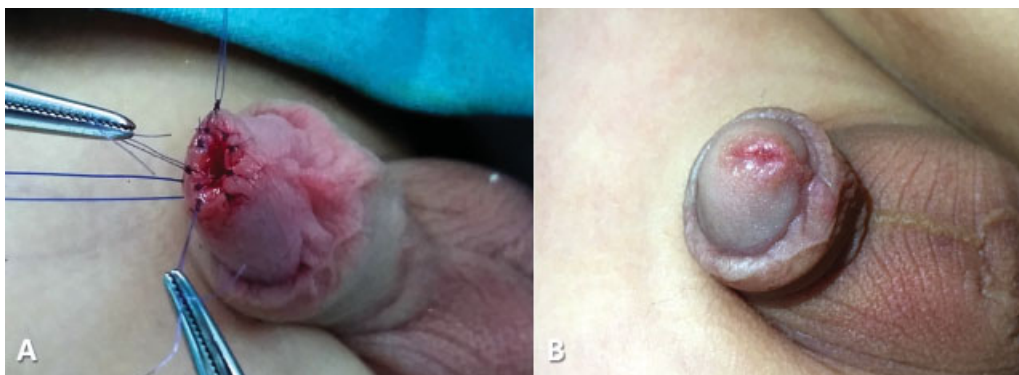

Fig. 2 The prolapsing mucosa was excised circumferentially and a primary repair was done (A). The meatal appearance 6 weeks after the operation (B).

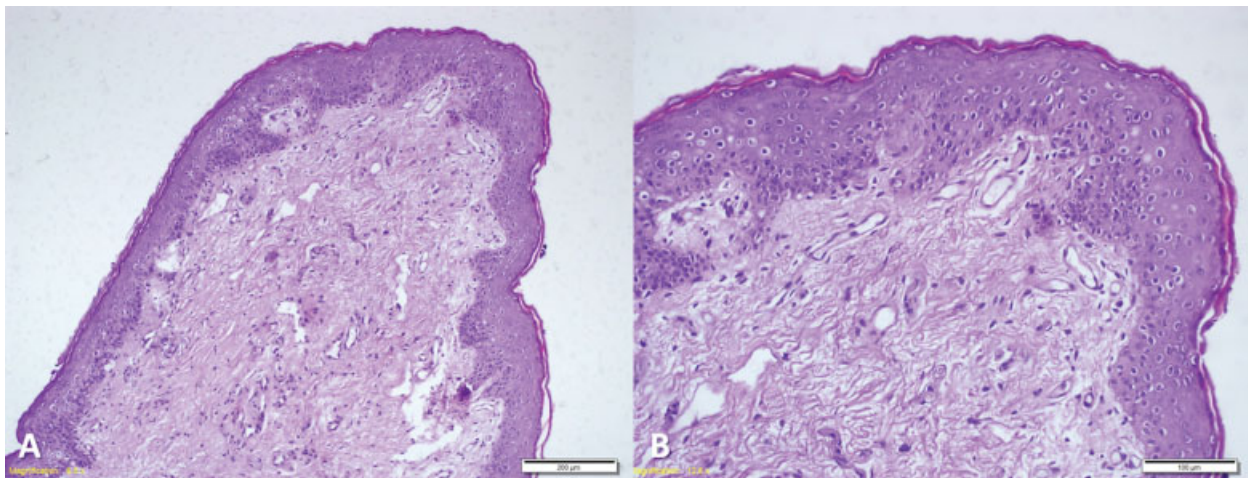


Fig. 3 Histopathologic examination of the specimen revealed (A) polypoid stratified squamous epithelium and edematous stroma (H&Ex10) and (B) stratified squamous epithelium and edematous fibrovascular stroma with dilated veins and a few lymphocytes in higher magnification (H&E x20). H&E, hematoxylin and eosin stain.

congenital adhesion defect between the mucous and submucous membranes, or poor adherence between urethral smooth muscle layers with superimposed elevated intra-abdominal pressure episodes.^{2–6} However, these probable causes should be approached cautiously because they were all proposed to explain the underlying developmental mechanism of urethral prolapse in females. They may not be applicable to the anomaly detected in the presented male patient. Circumcision as a widely employed practice in many cultures is unlikely to be a predisposing factor. Urethral prolapse was most likely to be of congenital in this boy because it was noticed by the family right after the circumcision at the age of 3.

Although diagnosis of urethral prolapse can be straightforward in most cases by simple visual inspection, the rarity of the condition may cause a delay in diagnosis with additional investigations undertaken.^{2,4} A circular protrusion of the distal urethra through the external meatus is the typical finding, and inspection reveals an edematous, “doughnut-shaped” prolapsing tissue completely surrounding the urethral meatus.^{3,5,6} Urethral prolapse may become complicated by infection, ulceration, or necrosis and may cause vaginal bleeding and/or urinary symptoms, such as dysuria.^{2,5} In complicated cases, the protruding mucosa may be bright red or blue-black. In the presented male child, the main complaint was weak urinary stream with an apparently normal looking, but prolapsed mucosa. Unlike girls, in whom the differential diagnosis may involve ectopic ureteroceles, urethral cysts, condyloma acuminatum, periurethral abscesses, or tumors,^{4,6} the physical examination findings in the presented child were very obvious that it was the urethral mucosa itself that was prolapsing.

Because urethral prolapse is a benign condition, a conservative treatment approach with simple observation or topical ointments and hot sitz baths can be tried in uncomplicated cases.^{2,3} Surgical options include primary

excision and suture ligation of the prolapsed tissue.^{4,6} The boy in this report complained of weak urinary stream, and the prolapsing mucosa had an unappealing appearance. Restoration of functional anatomy should be taken into consideration in deciding a treatment modality. Therefore, a surgical treatment was undertaken with a cosmetically and a functionally satisfactory result. The histopathological examination of the excised specimen confirmed the diagnosis.

In conclusion, this is the first case report of a boy with urethral prolapse, which is a rare diagnosis even in girls. Primary resection and anastomosis of the prolapsing mucosa are curative.

Conflict of Interest

None.

References

- 1 Kajibafzadeh A. Congenital urethral anomalies in boys. Part II. *Urol J* 2005;2(03):125–131
- 2 Ninomiya T, Koga H. Clinical characteristics of urethral prolapse in Japanese children. *Pediatr Int* 2017;59(05):578–582
- 3 Rudin JE, Geldt VG, Aleceev EB. Prolapse of urethral mucosa in white female children: experience with 58 cases. *J Pediatr Surg* 1997;32(03):423–425
- 4 Cartwright PC, Masterson TA, Snow BW. Office pediatric urology. In: Docimo SG, Canning DA, Houry AE, eds. *The Kelalis-King-Belman Textbook of Clinical Pediatric Urology*. Oxon: Informa Healthcare UK; 2007:199–214
- 5 Valerie E, Gilchrist BF, Frischer J, Scriven R, Klotz DH, Ramenofsky ML. Diagnosis and treatment of urethral prolapse in children. *Urology* 1999;54(06):1082–1084
- 6 Hillyer S, Mooppan U, Kim H, Gulmi F. Diagnosis and treatment of urethral prolapse in children: experience with 34 cases. *Urology* 2009;73(05):1008–1011