

# Successful Treatment of Osgood–Schlatter Disease with Autologous-Conditioned Plasma in Two Patients

Dirk-Jonas Danneberg<sup>1</sup>

<sup>1</sup>Department of Orthopaedics and Sports Medicine, Darmstadt, Germany

Joints 2017;5:191–194.

Address for correspondence Dirk-Jonas Danneberg, MD, Department of Orthopaedics and Sports Medicine, Nieder Ramstädter Street 160, 64285 Darmstadt, Germany (e-mail: info@orthopaedy.com).

## Abstract

### Keywords

- ▶ Osgood–Schlatter disease
- ▶ autologous-conditioned plasma
- ▶ platelet concentrate
- ▶ patellar ligament
- ▶ apophysitis

Osgood–Schlatter Disease (OSD) is a painful, growth-related overuse condition of the tibial tuberosity, leading to inflammation of the patellar ligament at the tibial tuberosity. It primarily affects young adolescents, athletic population, and usually, resolves with age or skeletal maturity. Therapy is usually conservative, with surgery indicated in a minority of cases. For patients with treatment-resistant or refractory OSD, an alternative is the application of autologous platelet concentrate. Here, we describe two cases in which autologous-conditioned plasma therapy was used to treat OSD, and present the treatment protocol developed in our clinic.

## Introduction

Osgood–Schlatter disease (OSD) is a painful, growth-related overuse condition of the tibial tuberosity in which inflammation of the patellar ligament at the tibial tuberosity occurs.<sup>1,2</sup> OSD, a traction apophysitis of the anterior aspect of the tibial tuberosity (ATT), is caused by quadriceps muscle contractions at the proximal tibial apophysis insertion. This leads to small avulsion fractures,<sup>1,2</sup> including partial traumatic avulsion of the tibial tuberosity at the patellar tendon insertion. Trauma to the ATT can also lead to acute OSD.<sup>3</sup> Treatment with analgesics, physiotherapy, and reduction of physical activity is recommended.<sup>3</sup> However, the duration of symptoms can be lengthy.<sup>4,5</sup> Injections of autologous-conditioned plasma (ACP) are increasingly being used for a variety of musculoskeletal conditions.<sup>6–10</sup> The growth factors contained in ACP are thought to influence mechanisms essential for tissue repair (e.g., modulation of inflammatory processes, chemotaxis, cell proliferation and migration, and matrix synthesis and differentiation).<sup>11–14</sup> Therapeutic application of these treatments is safe and minimally invasive,<sup>15</sup> and the preparation of conditioned plasma from autologous blood is simple. Here, we describe a case of OSD presenting in a young adult male after resolved childhood OSD and a case of treatment-resistant OSD in an adolescent male.

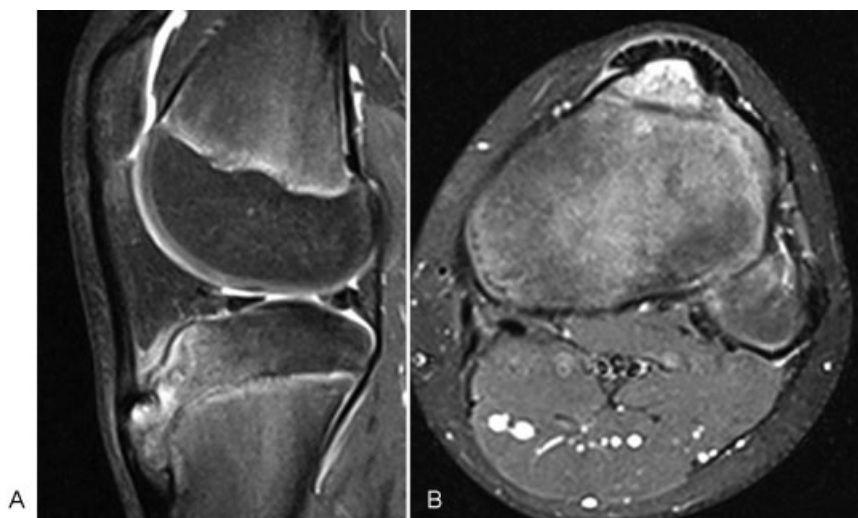
## Methods

### Case 1

A 23-year-old male tennis player with a childhood history of OSD resolving with age presented with right knee pain after a direct frontal impact onto the head of the tibia. On examination, he had tenderness at the tibial tuberosity and a small effusion, but no overlying erythema or limited range of motion. Knee X-rays demonstrated patellar tendon edema, and a sliver-like osseous density anterior to the apophysis of the tibial tuberosity, confirming the diagnosis of OSD. Sonographic imaging revealed a fluid layer or inflammatory fluid collection around the completely healed apophysis. Gait analysis revealed internal rotation of the lower leg.

### Case 2

A 14-year-old male patient presented with reoccurring bilateral knee pain from persisting treatment-resistant OSD. He first presented with knee pain at the age of 12, and played tennis 5 to 6 times/week. Previous repeated therapeutic interventions included extended resting phases, orthopedic insoles, physiotherapy, ultrasound therapy, and pulsed magnetic field therapy. Due to the existing diagnosis of treatment-resistant OSD, only confirmatory sonography and magnetic resonance imaging (MRI) scans were performed (▶ Fig. 1).



**Fig. 1** Magnetic resonance image of the 14-year-old patient (case 2): (A) Sagittal scan; (B) axial scan.

### Treatment

The standard ACP treatment protocol used at our clinic was applied. Patients received once-weekly subcutaneous injections of 1 mL ACP on either side of the palpable Osgood–Schlatter lesion/swelling, for a total of three to five applications.<sup>16</sup> The first patient, was treated in the right knee for 3 weeks, and the second patient in both knees for 4 weeks. The Arthrex ACP Double Syringe (Arthrex GmbH, Munich, Germany) was used, which uses a sterile double syringe system to prepare a leukocyte-poor but platelet-rich ACP. Around 15 mL of blood drawn into the double syringe produced about 5 mL of ACP. Centrifugation at 1,500 rpm for 5 minutes separated erythrocytes from the plasma components. The top portion of the plasma was drawn up into the inner syringe, without disrupting the erythrocyte layer, and used for injection. No activating agent was added. The knee was held in extension during injection to relax the tendon fibers, facilitating ACP diffusion into the injured area. Corticosteroids and local anesthesia were not administered.<sup>17</sup> Cryotherapy was used for pain relief, with an elastic zinc-paste cooling bandage application (Nika Medical Produkte GmbH, Krefeld, Germany) for 24 hours after every injection, and self-administered treatment with an ice popsicle, two to three times daily for 15 minutes. The knee was bandaged twice daily using TRAUMA RÖD 301 Physiko Balsam K (Pharma-Biologica GmbH, Worms, Germany). During the day, patients wore a PUSH Patella Brace (OFA, Bamberg, Germany) to reduce the traction force on the lower leg until 6 months after resolution of pain. At night, kinesiology tape was used to bandage across the tibial head. Ibuprofen, 200 mg daily for 10 days, and Wobenzym Plus (Mucos Pharma GmbH & Co. KG, Berlin, Germany) orally (3–0.3) for 4 weeks were prescribed. The patients underwent physiotherapy and gait optimization to correct foot malposition and received dynamic shoe insoles. Targeted training during the injection therapy was prohibited. The sonographic evaluation was performed before, during, and after the conclusion of the ACP injection therapy.

### Results

There were no postinjection complications. The first patient experienced a subjective pain reduction of approximately 50% after one injection. After 3 weeks, the patient was pain-free and able to return to sport. The second patient was pain-free after 6 weeks and able to return to sports; he has not experienced a relapse in OSD since treatment.

### Discussion

OSD usually resolves with age or conservative therapy (limited physical activity and mild analgesia), though it can be treatment-resistant or reoccurring. Both patients described here were active and intensive tennis players, fitting the typical profile for OSD. For both patients, the novel ACP treatment came after the failure of conventional therapies. Shortly after treatment initiation, both patients had symptom resolution and could return to sport. In addition to the two described patient cases, four more patients were successfully treated with ACP in our clinic at the same time. However, the data collection was incomplete. None of the patients have reported a relapse in OSD, or any adverse events as a result of the ACP injections, and all have returned to sports. We recommend that patients undergo X-ray imaging, MRI, and sonography to confirm the diagnosis of OSD and to exclude additional underlying pathology. All six patients treated with ACP for OSD exhibited internal rotation upon gait analysis, and a tendency to skew or splayfoot. Thus, a digital, dynamic gait analysis should be performed on patients with OSD, and orthopedic insoles fitted when necessary. We have not identified other reported cases of ACP treatment for OSD; however, the Arthrex ACP Double Syringe system has been successfully used to prepare ACP for use in treatment-resistant patellar tendinopathy.<sup>6</sup> In contrast to this study, we did not administer injections under ultrasound guidance. Our patients undertook a comprehensive home-care plan with cryotherapy, patellar braces, bandaging, kinesiology taping, and were allowed to use

analgesics, possibly influencing the positive outcome. The two cases presented herein describe the successful, novel use of ACP therapy for OSD, providing the first insights into an alternative therapy for patients with standard-treatment failure or recurrent OSD. Further studies of ACP therapy for OSD in a larger patient group are indicated to optimize the treatment protocol further.

#### Note

Patient consent has been obtained.

#### Acknowledgments

The authors would like to thank Lyndsey Kostadinov, Dr. Michael Furrer, and Dr. Juan M. Escobar-Restrepo from Medicalwriters.com (Zurich, Switzerland) for medical writing support (funded by Arthrex).

#### References

- Caine D, DiFiori J, Maffulli N. Physeal injuries in children's and youth sports: reasons for concern? *Br J Sports Med* 2006;40(09):749–760
- de Lucena GL, dos Santos Gomes C, Guerra RO. Prevalence and associated factors of Osgood-Schlatter syndrome in a population-based sample of Brazilian adolescents. *Am J Sports Med* 2011;39(02):415–420
- Gholve PA, Scher DM, Khakharia S, Widmann RF, Green DW. Osgood Schlatter syndrome. *Curr Opin Pediatr* 2007;19(01):44–50
- Gerulis V, Kalesinskas R, Pranckevicius S, Birgeris P. Importance of conservative treatment and physical load restriction to the course of Osgood-Schlatter's disease [in Lithuanian]. *Medicina (Kaunas)* 2004;40(04):363–369
- Mital MA, Matza RA, Cohen J. The so-called unresolved Osgood-Schlatter lesion: a concept based on fifteen surgically treated lesions. *J Bone Joint Surg Am* 1980;62(05):732–739
- Charouset C, Zaoui A, Bellaiche L, Bouyer B. Are multiple platelet-rich plasma injections useful for treatment of chronic patellar tendinopathy in athletes? a prospective study. *Am J Sports Med* 2014;42(04):906–911
- Kon E, Filardo G, Delcogliano M, et al. Platelet-rich plasma: new clinical application: a pilot study for treatment of jumper's knee. *Injury* 2009;40(06):598–603
- Zayni R, Thauinat M, Fayard JM, et al. Platelet-rich plasma as a treatment for chronic patellar tendinopathy: comparison of a single versus two consecutive injections. *Muscles Ligaments Tendons J* 2015;5(02):92–98
- Foster TE, Puskas BL, Mandelbaum BR, Gerhardt MB, Rodeo SA. Platelet-rich plasma: from basic science to clinical applications. *Am J Sports Med* 2009;37(11):2259–2272
- Lebiedziński R, Synder M, Buchcic P, Polgaj M, Grzegorzewski A, Sibiński M. A randomized study of autologous conditioned plasma and steroid injections in the treatment of lateral epicondylitis. *Int Orthop* 2015;39(11):2199–2203
- Laudy AB, Bakker EW, Rekers M, Moen MH. Efficacy of platelet-rich plasma injections in osteoarthritis of the knee: a systematic review and meta-analysis. *Br J Sports Med* 2015;49(10):657–672
- Eppley BL, Woodell JE, Higgins J. Platelet quantification and growth factor analysis from platelet-rich plasma: implications for wound healing. *Plast Reconstr Surg* 2004;114(06):1502–1508
- Andia I, Sánchez M, Maffulli N. Molecular and biological aspects of platelet-rich plasma therapies. *Oper Tech Orthop* 2012;22:3–9
- Kon E, Filardo G, Di Martino A, Marcacci M. Platelet-rich plasma (PRP) to treat sports injuries: evidence to support its use. *Knee Surg Sports Traumatol Arthrosc* 2011;19(04):516–527
- Boswell SG, Cole BJ, Sundman EA, Karas V, Fortier LA. Platelet-rich plasma: a milieu of bioactive factors. *Arthroscopy* 2012;28(03):429–439
- Cerza F, Carni S, Carcangiu A, et al. Comparison between hyaluronic acid and platelet-rich plasma, intra-articular infiltration in the treatment of gonarthrosis. *Am J Sports Med* 2012;40(12):2822–2827
- Carofino B, Chowanec DM, McCarthy MB, et al. Corticosteroids and local anesthetics decrease positive effects of platelet-rich plasma: an in vitro study on human tendon cells. *Arthroscopy* 2012;28(05):711–719