

A Novel Use of a Novel Drug: Preoperative Nasal Preparation with Dexmedetomidine for Transnasal Transsphenoidal Neurosurgery Approach in Skull Base Neurosurgery

Ajay Prasad Hrishy¹ Karen Ruby Lionel¹ Prakash Nair²

¹Division of Neuroanesthesia, Department of Anesthesiology, Sree Chitra Tirunal Institute for Medical Sciences and Technology, Trivandrum, Kerala, India

²Department of Neurosurgery, Sree Chitra Tirunal Institute for Medical Sciences and Technology, Trivandrum, Kerala, India

Address for correspondence Dr. Ajay Prasad Hrishy, MD, DM, MNAMS, Division of Neuroanesthesia, Department of Anesthesiology, 4th Floor, C block, Sree Chitra Tirunal Institute for Medical Sciences and Technology, Trivandrum 695011, Kerala, India (e-mail: drajay@sctimst.ac.in).

Indian J Neurosurg 2017;6:170–175.

Abstract

Introduction Transnasal transsphenoidal (TNTS) approach is preferred for surgical excision of the pituitary gland. Despite its numerous merits, the TNTS approach creates wide fluctuations in hemodynamic parameters that are attributed to the routine application of adrenaline-soaked nasal packing and the intense noxious stimulus during the surgery.

Aims To evaluate the effect of dexmedetomidine for preoperative nasal passage preparation on the surgical field visualization and hemodynamic profile of patients during TNTS surgery.

Material and Methods Cotton strips soaked in dexmedetomidine were used for nasal preparation. The primary outcomes studied were the quality of surgical field visualization through the endoscope and the amount of bleeding that occurred while raising the nasal mucosal flap. The secondary outcomes assessed were the intraoperative anesthetic and analgesic requirement and the hemodynamic profile.

Statistical Analysis Data from the study were summarized as mean and SD. Associations were tested using chi-square test for nonparametric data and for continuous variables ANOVA for repeated measures. A *p*-value < 0.05 was considered as statistically significant and < 0.01 as highly significant. SPSS 17.0 was used for analysis.

Results Seventeen (85%) patients had a Formmer's score of 1, which was an excellent surgical field quality. Two (10%) patients had a Formmer's score of 2, and one (5%) had a Formmer's score of 3. There were no statistically significant variations in heart rate and blood pressure with reduced anesthetic requirement.

Conclusion Intranasal dexmedetomidine provides good surgical field conditions with the added advantage of lesser hemodynamic fluctuations.

Keywords

- ▶ intranasal dexmedetomidine
- ▶ transnasal transsphenoidal
- ▶ skull base neurosurgery

received
March 22, 2017
accepted
May 25, 2017
published online
October 13, 2017

DOI <https://doi.org/10.1055/s-0037-1606342>.
ISSN 2277-954X.

© 2017 Neurological Surgeons' Society of India

License terms



Introduction

Transnasal transsphenoidal (TNTS) approach for surgical excision of the pituitary gland is preferred by neurosurgeons worldwide as it offers a rapid midline access to the sella with minimal risk of brain trauma or hemorrhage, excellent exposure of the pituitary with adequate working space, and is associated with less postoperative pain and a shorter hospital stay with a lower incidence of postoperative complications.^{1,2} Despite these numerous merits, the TNTS approach creates wide fluctuations in hemodynamic parameters, particularly, hypertension and tachycardia that is attributed to the routine application of adrenaline-soaked nasal packing and the intense noxious stimulus during nasal speculum insertion, sphenoid, and sellar dissection.³ None of the routinely used anesthetic agents are able to effectively blunt these undesirable hemodynamic responses, thus resulting in a need for increased doses of anesthetic or vasoactive agents.⁴⁻⁶

The main purpose of the nasal mucosa preparation and the intraoperative blood pressure control during endoscopic TNTS surgery is to provide a relatively bloodless and dry surgical field to improve visibility and facilitate the surgical approach. Unfortunately, the conventional practice of packing the nose with 1% lignocaine with adrenaline (1:10,000–1:20,000) and further infiltration of the nasal mucosa with various dilutions of lignocaine with adrenaline (1:50,000–1:200,000) preparations often cause hemodynamic changes that can be catastrophic in patients with secretory pituitary adenomas such as Cushing's disease and acromegaly who have an increased sensitivity to catecholamines.^{3,6,7}

Dexmedetomidine (DEX), a selective α_2 -receptor agonist, is used for its sedative, analgesic, and anxiolytic properties in clinical practice.^{8,9} It has an analgesic-sparing effect, significantly reducing opioid requirements in both intra- and postoperative periods.¹⁰ DEX also has a sympatholytic effect, which can reduce the stress response to surgery and ensure a stable hemodynamic state.¹¹ Intranasal DEX is convenient, effective, noninvasive, and also has useful analgesic and sedative effects in surgical procedures.^{12,13} Cheung's research has shown that intranasal DEX 1 and 1.5 $\mu\text{g}/\text{kg}$ in surgical procedures produced significant sedation and less postoperative pain.^{13,14}

DEX has vasoconstrictive effects on peripheral blood vessels.^{15,16} Locally injected DEX results in peripheral vasoconstriction without a systemic cardiovascular response via the peripheral α_{2A} -adrenoceptor subtype.¹⁷ Further studies have also shown that activation of postsynaptic α_2 -adrenoceptors will cause vasoconstriction (through the activation of α_2 -adrenoceptors on vascular smooth muscle cells).¹⁸

However, the clinical use of intranasal DEX for its local effect of vasoconstriction and hence its effects on the local bleeding during raising of the mucosal flap and on the intraoperative hemodynamics after infiltration of the mucosa with adrenaline in patients undergoing TNTS approach for pituitary adenoma surgery has not been explored. We performed this study to evaluate the feasibility and efficacy

of DEX for preoperative nasal passage preparation on the surgical field visualization and hemodynamic profile of patients during TNTS surgery.

Material and Methods

We conducted a prospective pilot study on patients undergoing TNTS excision of pituitary tumors. Since the nasal mucosal vasoconstrictor effect of DEX in preparation of nasal mucosa in TNTS surgeries has not been evaluated before, a pilot study was warranted to evaluate the vasoconstrictor effects of DEX on the nasal mucosa for preparation for TNTS surgery. The study protocol was approved by the Institutional Ethics Committee and written informed consent was obtained from all the participants. Patients who were pregnant or lactating had decreased levels of consciousness, raised intracranial tension, recurrence of tumor, pituitary apoplexy, cardiac pathology, previous nasal surgery, or history of allergy to any of the study drugs were excluded from the study. The primary outcome parameters studied were the quality of surgical field visualization through the endoscope and the amount of bleeding that occurred while raising the nasal mucosal flap. The secondary outcome parameters assessed were the intraoperative anesthetic requirement and hemodynamic profile.

Preprocedure, no sedative premedication was administered. Standard preinduction monitoring consisted of electrocardiography (ECG), oxygen saturation (SpO_2), and noninvasive blood pressure. Standard anesthetic induction was done with injections (Inj.) fentanyl 1 to 2 $\mu\text{g}/\text{kg}$, propofol 2 mg/kg, and vecuronium 0.1 mg/kg. After intubation, anesthesia was maintained using a combination of oxygen: air (50% FiO_2) and sevoflurane titrated to a bi-spectral index (BIS) of 40 to 60. The radial artery was cannulated for invasive blood pressure monitoring. Analgesia and muscle relaxation was provided with infusions of Inj. fentanyl at 2 $\mu\text{g}/\text{kg}/\text{h}$ and Inj. atracurium at 0.3 to 0.6 mg/kg/h, respectively. The posterior pharynx was packed with moist cotton gauze to prevent the entry of surgical bleed into the esophagus and stomach.

Our surgeries were performed by the same surgical team consisting of one otolaryngologist and one skull base neurosurgeon. Nasal preparation was performed by the surgeon using cotton strips soaked in DEX. Cotton strips were imbibed with the solution; the excess was carefully removed until the cotton strip was saturated but not dripping upon compression.

In a study done by Tang et al to evaluate the effect of intranasally administered DEX in combination with local anesthesia (LA) on the relief of stress and the inflammatory response during functional endoscopic sinus surgery (FESS), the nasal mucosa was prepared with 1.5 $\mu\text{g}/\text{kg}$ of DEX drops.¹⁹ Intranasal DEX 2 $\mu\text{g}/\text{kg}$ is routinely used as a premedication/sedation in the pediatric patient undergoing magnetic resonance imaging (MRI) so we also used the same dose of drug to evaluate the efficacy of the drug as a vasoconstrictor.^{20,21} The entire dose 2 $\mu\text{g}/\text{kg}$ of DEX is diluted in 10 mL of saline that will be adequate to soak the six cotton strips, which is required for the study. Each strip

approximately absorbed approximately 1 to 2 mL. Each nasal cavity was packed with three packs. One placed on the floor of the nasal cavity, the other was placed over it to encroach into the middle meatus and the last one was placed over the second one to anaesthetize the frontal recess area. The nasal packs were left in situ for 10 minutes.

Prior to surgical incision, nasal septal mucosa was infiltrated with 1% lignocaine with adrenaline solution (1:100,000). Hemodynamic parameters that included the heart rate (HR), systolic blood pressure (SBP), diastolic blood pressure (DBP), and mean blood pressure (MAP) were measured at seven time points (T0, baseline; T1, 5 minutes after nasal packing; T2, 15 minutes after nasal packing; T3, after local infiltration; T4, at the beginning of surgery; T5, 30 minutes into surgery; T6, at the end of surgery; T7, on arrival to the surgical intensive care unit [ICU]). Quality of intraoperative surgical field during endoscopic surgery was evaluated by the surgeons using the Formmer's scores for assessing surgical field quality (1, mild bleeding without any surgical nuisance; 2, moderate bleeding, without any interference to surgery; 3, moderate bleeding that moderately compromised surgical field; 4, bleeding, heavy but controllable, that significantly interfered the surgery; 5, massive uncontrollable bleeding).²² The end-tidal sevoflurane and minimum alveolar concentration (MAC) required for sevoflurane to achieve a BIS of 40 to 60 was noted. If the blood pressure and HR remained greater > 20% of the baseline, additional bolus doses of 5 mg of Inj. labetalol were administered until the hemodynamic parameters return to baseline. Total of the additional Inj. labetalol boluses were recorded for each patient. At the end of the procedure, after reversal of neuromuscular blockade, when the patients were able to obey simple commands, they were extubated and shifted to the surgical ICU for postoperative care.

Statistical Analysis

Data from the study were summarized as mean and standard deviation (SD). Associations were tested using chi-square test for nonparametric data and for continuous variables ANOVA (analysis of variance) for repeated measures. A $p < 0.05$ was considered as statistically significant and < 0.01 as highly significant. SPSS 17.0 (SPSS Inc., Chicago, Illinois, United States) was used for analysis.

Results

Twenty patients were enrolled in our study. The mean age of the population was 44.2 ± 9.6 years having an average weight of 65.3 ± 10.2 kg with a male-to-female ratio of 2:3. The mean surgical duration was 245 ± 28.8 minutes. Eight of the patients had a secretory pituitary adenoma of whom four had cortisol-secreting, three had growth hormone-secreting, and one had prolactin-secreting tumors. Three patients were hypertensives under control. Seventeen (85%) patients had grade 1 Formmer's score that was an excellent surgical field quality, characterized by a mild ooze not creating any surgical interference. Two (10%) patients had a Formmer's score of 2, which was characterized by moderate bleeding without surgical interference and one (5%) had a

Table 1 Surgical field quality as graded by the Formmer's score

Surgical field quality by Formmer's score	No. of patients (n = 20)
1	17
2	2
3	1
4	0
5	0

Note: 1, mild bleeding without any surgical nuisance; 2, moderate bleeding, without any interference to surgery; 3, moderate bleeding that moderately compromised surgical field; 4, bleeding, heavy but controllable, that significantly interfered the surgery; 5, massive uncontrollable bleeding.

Formmer's score of 3, where the surgeons encountered moderate bleeding that moderately compromised the surgical field (**►Table 1**).

The hemodynamic changes in our population have been summarized in **►Table 2**. We noted a reduction in HR at 5 minutes postnasal pack from the prepacking basal HR that further continued on a downward trend even after submucosal injection with adrenaline. Moreover, we noted that the HR plateaued through the surgical dissection phase returning back to near baseline values at the time of extubation. The notable fact was that there were minimal fluctuations in the HR following submucosal injections of local anesthetic with adrenaline. A similar pattern was registered in the values of SBP, DBP, and the MAP as well. A decrease in SBP, DBP, and MAP was noted in the first 5 minutes postpacking with a transient minimal increase during the submucosal infiltration followed by a gradual decreasing trend during the dissection phase (**►Fig. 1**). These fluctuations in the measurements were found to be statistically insignificant ($p > 0.05$). None of the patients had cardiac arrhythmias during the procedure. The hemodynamic response did not differ between the patients with secretory and nonsecretory tumors and those who were hypertensives and nonhypertensives.

The end-tidal concentration of the anesthetic agent sevoflurane reduced by 44% after the DEX nasal pack compared with the postinduction baseline, to maintain a BIS of 40 to 60 reaching the lowest requirement during the surgical dissection phase (**►Table 2**). Toward the end of the sellar dissection, there was a gradual increase in the requirement of the anesthetic agent even though it remained significantly below the baseline ($p < 0.05$). This drop was concurrently reflected by a drop in the MAC requirements to maintain a BIS between 40 and 60. The MAC requirements of sevoflurane was reduced by a mean of 30% from the baseline following the nasal packing with DEX with the lowest requirement being during the sinus dissection phase and minimally increasing later on to plateau at 0.6 ± 0.1 MAC to maintain the same BIS. The total fentanyl requirement of the patients was 5.1 ± 0.6 µg/kg. None of the patients required rescue antihypertensive therapy with Inj. labetalol boluses. Two patients (10%) had postoperative nausea and vomiting (PONV).

Table 2 Summary of the hemodynamic changes in our patient population

Stage of surgery	HR (beats/min) (Mean \pm SD)	SBP (mm Hg) (Mean \pm SD)	DBP (mm Hg) (Mean \pm SD)	MAP (mm Hg) (Mean \pm SD)	Et Sevo (%) (Mean \pm SD)	MAC (Mean \pm SD)	BIS (Mean \pm SD)
T0	80.2 \pm 10.1	124 \pm 10.1	72.0 \pm 7.3	89.3 \pm 7.2	1.8 \pm 0.2	0.8 \pm 0.1	49.2 \pm 5.9
T1	72.4 \pm 9.6	115.2 \pm 7.3	69.5 \pm 9.2	84.5 \pm 9.9	1.6 \pm 0.1	0.7 \pm 0.1	43.3 \pm 4.9
T2	71.2 \pm 10.1	111.1 \pm 6.8	65.7 \pm 7.1	80.7 \pm 8.0	1.0 \pm 0.1	0.5 \pm 0.2	40.2 \pm 6.6
T3	68.5 \pm 8.7	114.7 \pm 5.1	73.4 \pm 4.9	86.9 \pm 10.9	1.1 \pm 0.1	0.5 \pm 0.1	41.5 \pm 4.8
T4	66.7 \pm 9.3	111.2 \pm 2.5	64.0 \pm 5.7	79.7 \pm 8.6	1.3 \pm 0.2	0.6 \pm 0.1	41.8 \pm 7.9
T5	69.9 \pm 11.3	111.1 \pm 3.3	62.5 \pm 6.3	78.3 \pm 9.9	1.3 \pm 0.1	0.6 \pm 0.1	47.9 \pm 5.8
T6	77.3 \pm 9.7	115.1 \pm 4.3	69.5 \pm 5.1	84.3 \pm 10.8	0.3 \pm 0.2	0.1 \pm 0.1	94.2 \pm 9.3
T7	74.1 \pm 6.3	112.0 \pm 2.7	69.0 \pm 3.4	83.3 \pm 7.2	NA	NA	NA

Abbreviations: BIS, bi-spectral index; DBP, diastolic blood pressure; Et, end tidal; HR, heart rate; MAC, minimum alveolar concentration; MAP, mean arterial pressure; NA, not available; SBP, systolic blood pressure; SD, standard deviation; Sevo, sevoflurane.

Discussion

The major challenges for endoscopic pituitary surgery are the rich vascularity and complex anatomy of the nose.³ Vasoconstriction of this highly vascular field is achieved conventionally through a combination of 1% lignocaine with adrenaline (1:20,000–1:40,000) as soaked cotton pledgets and injecting the nasal mucosa with various concentrations of lignocaine with adrenaline (1:50,000–1:200,000) during nasal dissections at the anterior aspect of the middle turbinate, sphenopalatine, and greater palatine foramen regions.^{6,7} The tachycardia, hypertension, and arrhythmias secondary to the systemic absorption of adrenaline from the highly vascular nasal mucosa can be catastrophic in patients presenting with Cushing's disease and acromegaly who have an

increased sensitivity to adrenaline as well as associated cardiac abnormalities secondary to the excessive levels of hormones such as cortisol, growth hormone, and insulin-like growth factor.^{3,6,7} Several alternatives such as cocaine and xylometazoline have been previously considered but abandoned due to their ineffectiveness or the incidence of adverse effects.^{1,5} None of the routinely used anesthetic agents, in standard doses, effectively blunt the undesirable hemodynamic responses. Consequently, increased doses of anesthetic agents are required, resulting in the increased occurrence of adverse effects of the anesthetics.^{4,5} Iirola studied the bioavailability of DEX after intranasal administration. Plasma DEX concentrations were measured for 10 hours, and pharmacokinetic variables were calculated with standard noncompartmental methods. HR, blood pressure,

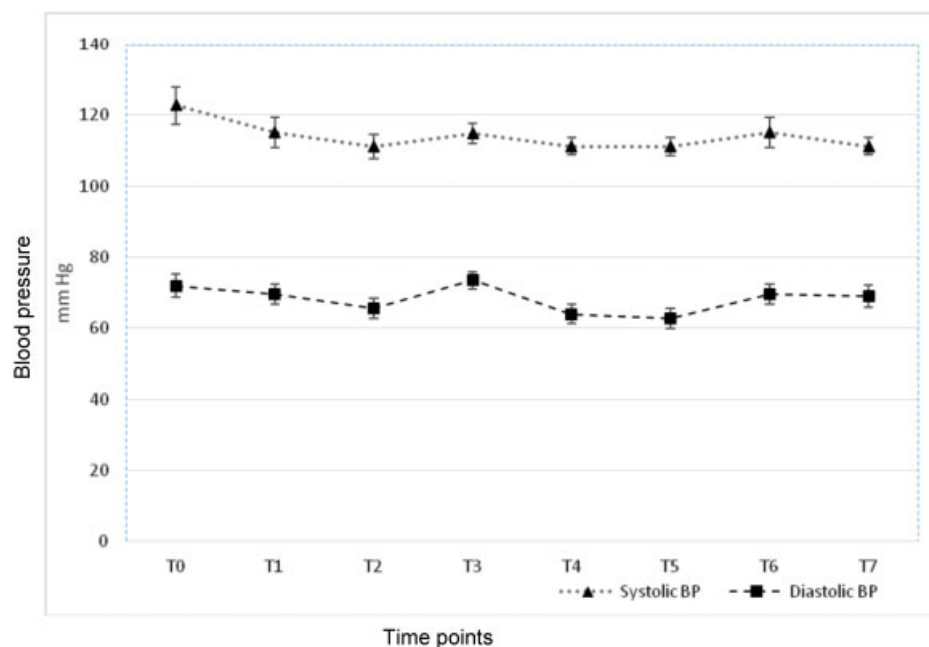


Fig. 1 Trends in BP. T0, baseline; T1, 5 min after nasal packing; T2, 15 minutes after nasal packing; T3, after local infiltration; T4, at the beginning of surgery; T5, 30 minutes into surgery; T6, at the end of surgery; T7, in the surgical ICU (error bars = \pm 1.96 SE). BP, blood pressure; ICU, intensive care unit; SE, standard error.

concentrations of adrenaline and noradrenaline in plasma, and central nervous system drug effects (with the Maddox wing, BIS, and three visual analog scales) were monitored to assess the pharmacologic effects of DEX. Following intranasal administration, peak plasma concentrations of DEX were reached in 38 (15–60) minutes and its absolute bioavailability was 65% (35–93%) (medians and ranges). Pharmacologic effects were similar to those of intravenous administration.²³ Intranasal DEX, with bioavailability and pharmacological effects comparable with intravenous administration, has been demonstrated to be beneficial in providing improved surgical conditions for endoscopic sinus procedures of otolaryngologists.¹⁴

Our findings that 85% of the patients had grade 1 Forrmmer's scale suggests that intranasal DEX provides adequate surgical field conditions. The initial step of the surgery involves nasal mucosal dissection that requires that the nasal mucosa be prepared and bloodless. As our title implies, we only assessed the efficacy of DEX as an agent for nasal passage preparation prior to the surgery and its advantages. The surgical field quality assessed was the state of the nasal mucosa till the point when the surgeon raised the nasal flap for sinus dissection. In conventional practice initial nasal packing is done with adrenaline (1:20,000–1:40,000) soaked strips followed by injection of adrenaline (1:200,000) before raising the mucosal flap. This involves adverse hemodynamic response that is detrimental to the patient's cardiovascular system. In our study we have substituted this step of dual adrenaline insult with DEX nasal packs followed by adrenaline injection, wherein the advantage is that the α -blockade provided by the DEX will negate the adverse effect of the adrenaline injection that results in a better hemodynamic profile. Hypertensive surges caused by the adrenaline injections result in bleeding spurts whereby the blood-less field achieved by the vasoconstrictive effect of adrenaline is eventually lost. The surgical field quality is assessed by the surgeons till the stage of raising the nasal flap that is offered solely by the DEX nasal pack. Since this was a pilot study to evaluate whether mucosal preparation with DEX is a feasible option instead of high doses of adrenalin-soaked cotton strips, we did not include a control group in our study.

Between 50 and 90% of patients undergoing pituitary surgery require either the use of antihypertensive or vasoactive drugs to achieve intraoperative hemodynamic stability. The absence of significant tachycardia and hypertension after infiltrating the nasal submucosa with adrenaline in our study was remarkable. None of the patients had cardiac arrhythmias during the procedure nor did they require rescue antihypertensive therapy suggesting an added benefit of stable intraprocedural hemodynamic profile. Intranasal DEX is known to decrease plasma epinephrine and norepinephrine level perioperatively and attenuates hypertensive responses associated with surgical stimulation.¹⁹

The 44% reduction in end-tidal concentration of sevoflurane from postinduction baseline, despite a gradual increase in the requirement of the anesthetic agent toward the

end of sellar dissection, remained significantly below the baseline ($p < 0.05$). The opioid requirement of 5.1 $\mu\text{g}/\text{kg}$ was low as compared with routine pituitary adenoma surgery of similar duration with requirements in the range of 7.7 $\mu\text{g}/\text{kg}$.²⁴

This decreased anesthetic and analgesic requirement as a consequence of intranasal DEX permits an early and predictable recovery of consciousness which is particularly important in preventing airway obstruction in patients with secretory pituitary tumors such as acromegaly and Cushing's disease that are associated with a high incidence of obstructive sleep apnoea.^{5,6} The use of postoperative nasal packs that makes these patients obligate mouth breathers increases the risk of airway obstruction. Preventing aspiration of hemorrhagic secretions from the nasopharynx requires an awake patient with intact airway reflexes. DEX reduces the intraoperative opioid requirements and modifies the stress and inflammatory response to surgical trauma, thereby attenuating the perioperative pain and improving the postoperative outcome.²⁴ Another advantage of DEX is the absence of the risk of respiratory depression and its associated complications.²⁵ Transnasal pituitary surgeries have an incidence of PONV as high as 50%. In our study DEX appears to be effective in reducing the incidence of PONV (10%), which may be attributed to the reduced requirement of intraoperative opioids.⁶

The limitations of this pilot study is the limited sample size as this was a study to assess the feasibility of DEX as an agent for nasal passage preparation that was never attempted before. The efficacy of DEX in patients with cardiac pathologies and recurrent transnasal pituitary tumor surgeries requires further research.

Conclusion

To conclude, intranasal DEX appears to be a feasible agent for nasal passage preparation in patients undergoing TINTS approach in skull base neurosurgery by providing good endoscopic visualization with minimal nasal mucosal bleeding with a stable hemodynamic profile.

Funding

None.

Conflict of Interest

None.

References

- 1 Jane JA Jr, Thapar K, Kaptain GJ, Maartens N, Laws ER Jr. Pituitary surgery: transsphenoidal approach. *Neurosurgery* 2002;51(02): 435–442, discussion 442–444
- 2 Kuroki A, Kayama T. Endoscopic approach to the pituitary lesions: contemporary method and review of the literature. *Biomed Pharmacother* 2002;56(Suppl 1):158s–164s
- 3 Pasternak JJ, Atkinson JL, Kasperbauer JL, Lanier WL. Hemodynamic responses to epinephrine-containing local anesthetic injection and to emergence from general anesthesia in transsphenoidal hypophysectomy patients. *J Neurosurg Anesthesiol* 2004;16(03): 189–195

- 4 Cafiero T, Cavallo LM, Frangiosa A, et al. Clinical comparison of remifentanyl-sevoflurane vs. remifentanyl-propofol for endoscopic endonasal transphenoidal surgery. *Eur J Anaesthesiol* 2007;24(05):441–446
- 5 Nemergut EC, Dumont AS, Barry UT, Laws ER. Perioperative management of patients undergoing transsphenoidal pituitary surgery. *Anesth Analg* 2005;101(04):1170–1181
- 6 Smith M, Hirsch NP. Pituitary disease and anaesthesia. *Br J Anaesth* 2000;85(01):3–14
- 7 Cohen-Kerem R, Brown S, Villaseñor LV, Witterick I. Epinephrine/Lidocaine injection vs. saline during endoscopic sinus surgery. *Laryngoscope* 2008;118(07):1275–1281
- 8 Hsu YW, Cortinez LI, Robertson KM, et al. Dexmedetomidine pharmacodynamics: part I: crossover comparison of the respiratory effects of dexmedetomidine and remifentanyl in healthy volunteers. *Anesthesiology* 2004;101(05):1066–1076
- 9 Cortinez LI, Hsu YW, Sum-Ping ST, et al. Dexmedetomidine pharmacodynamics: Part II: crossover comparison of the analgesic effect of dexmedetomidine and remifentanyl in healthy volunteers. *Anesthesiology* 2004;101(05):1077–1083
- 10 Ramsay MAE, Luteran DL. Dexmedetomidine as a total intravenous anesthetic agent. *Anesthesiology* 2004;101(03):787–790
- 11 Angst MS, Ramaswamy B, Davies MF, Maze M. Comparative analgesic and mental effects of increasing plasma concentrations of dexmedetomidine and alfentanil in humans. *Anesthesiology* 2004;101(03):744–752
- 12 Cheung CW, Qiu Q, Liu J, Chu KM, Irwin MG. Intranasal dexmedetomidine in combination with patient-controlled sedation during upper gastrointestinal endoscopy: a randomised trial. *Acta Anaesthesiol Scand* 2015;59(02):215–223
- 13 Qiao H, Chen J, Li W, Shen X. Intranasal atomised dexmedetomidine optimises surgical field visualisation with decreased blood loss during endoscopic sinus surgery: a randomized study. *Rhinology* 2016;54(01):38–44
- 14 Cheung CW, Ng KFJ, Liu J, Yuen MY, Ho MHA, Irwin MG. Analgesic and sedative effects of intranasal dexmedetomidine in third molar surgery under local anaesthesia. *Br J Anaesth* 2011;107(03):430–437
- 15 Talke P, Lobo E, Brown R. Systemically administered alpha2-agonist-induced peripheral vasoconstriction in humans. *Anesthesiology* 2003;99(01):65–70
- 16 Talke P, Richardson CA, Scheinin M, Fisher DM. Postoperative pharmacokinetics and sympatholytic effects of dexmedetomidine. *Anesth Analg* 1997;85(05):1136–1142
- 17 Yabuki A, Higuchi H, Yoshitomi T, et al. Locally injected dexmedetomidine induces vasoconstriction via peripheral α -2A adrenoceptor subtype in guinea pigs. *Reg Anesth Pain Med* 2014;39(02):133–136
- 18 Kim HJ, Sohn JT, Jeong YS, et al. Direct effect of dexmedetomidine on rat isolated aorta involves endothelial nitric oxide synthesis and activation of the lipoxygenase pathway. *Clin Exp Pharmacol Physiol* 2009;36(04):406–412
- 19 Tang C, Huang X, Kang F, et al. Intranasal dexmedetomidine on stress hormones, inflammatory markers, and postoperative analgesia after functional endoscopic sinus surgery. *Mediators Inflamm* 2015;2015:939431
- 20 Miller JW, Divanovic AA, Hossain MM, Mahmoud MA, Loepke AW. Dosing and efficacy of intranasal dexmedetomidine sedation for pediatric transthoracic echocardiography: a retrospective study. *Can J Anaesth* 2016;63(07):834–841
- 21 Ambi US, Joshi C, Ganeshnavar A, Adarsh E. Intranasal dexmedetomidine for paediatric sedation for diagnostic magnetic resonance imaging studies. *Indian J Anaesth* 2012;56(06):587–588
- 22 John G, Low JM, Tan PE, van Hasselt CA. Plasma catecholamine levels during functional endoscopic sinus surgery. *Clin Otolaryngol Allied Sci* 1995;20(03):213–215
- 23 Iiro T, Vilo S, Manner T, et al. Bioavailability of dexmedetomidine after intranasal administration. *Eur J Clin Pharmacol* 2011;67(08):825–831
- 24 Gopalakrishna KN, Dash PK, Chatterjee N, Easwer HV, Ganesamoorthi A. Dexmedetomidine as an anesthetic adjuvant in patients undergoing transsphenoidal resection of pituitary tumor. *J Neurosurg Anesthesiol* 2015;27(03):209–215
- 25 Sudheesh K, Harsoor S. Dexmedetomidine in anaesthesia practice: a wonder drug? *Indian J Anaesth* 2011;55(04):323–324