

# Application of Indocyanine Green in Flap Surgery: A Systematic Review

Ke Li, MD<sup>1,\*</sup> Zheng Zhang, MD<sup>1,\*</sup> Fabio Nicoli, MD<sup>1,2,3,4,\*</sup> Christopher D'Ambrosia, BA<sup>4,5,\*</sup>  
Wenjing Xi, MD<sup>1</sup> Davide Lazzeri, MD<sup>3</sup> Shaoqing Feng, MD<sup>1</sup> Weijie Su, MD<sup>1</sup> Hua Li, MD<sup>1</sup>  
Pedro Ciudad, MD, PhD<sup>4</sup> Mathias Tremp, MD<sup>6</sup> Yi Xin Zhang, MD<sup>1</sup>

<sup>1</sup> Department of Plastic and Reconstructive Surgery, Shanghai Ninth People's Hospital, Shanghai Jiao Tong University School of Medicine, Shanghai, China

<sup>2</sup> Department of Plastic and Reconstructive Surgery, University of Rome "Tor Vergata," Rome, Italy

<sup>3</sup> Plastic Reconstructive and Aesthetic Surgery Unit, Villa Salaria Clinic, Rome, Italy

<sup>4</sup> Department of Plastic and Reconstructive Surgery, China Medical University Hospital, Taichung, Taiwan

<sup>5</sup> School of Medicine, Columbia University, New York, New York

<sup>6</sup> Plastic Reconstructive and Aesthetic Surgery, University Hospital of Basel, Basel, Switzerland

Address for correspondence Yi Xin Zhang, MD, Department of Plastic and Reconstructive Surgery, Shanghai Ninth People's Hospital, Shanghai Jiao Tong University School of Medicine, Shanghai, China (e-mail: zhangyixin6688@hotmail.com).

J Reconstr Microsurg 2018;34:77–86.

## Abstract

**Background** The vascularization of the distal portions of transferred tissue represents the most critical factor in the success of reconstructive surgery. In recent years, indocyanine green (ICG) fluorescence imaging techniques have been applied during surgery to evaluate flap perfusion. However, this investigation has found that there is little consensus regarding the standard dose of ICG as well as the pre-operative requirements of ICG allergy testing. The aim of this study is to summarize the applications of ICG to tissue transfers and safe dosing practices and to provide insight to the possible adverse effects of ICG on flap surgery with the goal of helping clinicians apply ICG safely and efficiently to tissue transfer procedures.

**Methods** A literature search was performed using, Wiley InterScience, and Springer with the key words, 'Flap,' 'indocyanine green,' 'surgery,' and related mesh words for all publications between 2005 and 2015. Title and abstract screening was performed using predefined in- and exclusion criteria.

**Results** Seventy-three articles were included. These were classified as "application of ICG in flap surgery" and "the security of applying ICG in flap surgery".

**Conclusions** ICG fluorescence imaging preoperatively facilitates the detection of perforators in tissue flaps with thickness <20 mm, aids in the evaluation of flap microcirculation and perfusion, and allows surgeons to select dominant cutaneous nerves while evaluating the quality of vascular anastomoses and locating thromboses. The literature also concluded that potential allergic reactions to ICG should be taken into consideration.

## Keywords

- ▶ indocyanine green
- ▶ fluorescence imaging
- ▶ flap surgery

\* These authors contributed equally to this work.

received  
December 12, 2016  
accepted after revision  
July 31, 2017  
published online  
October 9, 2017

Copyright © 2018 by Thieme Medical Publishers, Inc., 333 Seventh Avenue, New York, NY 10001, USA.  
Tel: +1(212) 584-4662.

DOI <https://doi.org/10.1055/s-0037-1606536>  
ISSN 0743-684X.

The vascularization of distal portions of transferred tissue represents the most critical factor for the success of reconstructive surgery. The flap selection represents a careful balance between blood supply (random, axial, or perforator based) and geometry of tissue needed.<sup>1</sup> Although practitioners have successfully applied several methods, including ultrasound, magnetic resonance imaging (MRI), and computed tomographic angiography (CTA), to detect perforators and main vessels in transferred tissue, these procedures are unreliable in predicting the degree of flap blood perfusion.<sup>2-4</sup> Currently, the evaluation of flap vascularization, regardless of type, is based on clinical experience and subjective evaluation of tissue color, flap temperature, capillary reperfusion, and assessment of arterial bleeding on flap edges. Objective methods such as oxygen partial pressure, capillaroscopy, laser Doppler flow measurement, thermography, and photoplethysmography have been evaluated clinically,<sup>1</sup> but these techniques have never been applied systematically to the operative process due to high cost, complexity, low sensitivity, and a high rate of false positives and false negatives. Our field is still searching for a protocol that describes an effective, reliable, and stable process to evaluate flap blood perfusion.

In the past few decades, a near-infrared fluorescence imaging device, used in medical diagnostics, has been used by plastic surgeons during procedures. This method uses indocyanine green (ICG) as contrast agent. When protein-bound ICG is exposed to light at wavelengths of 750 to 810 nm, ICG emits fluorescence that peaks at ~840 nm. The light needed for excitation is generated by a near-infrared light source attached directly to a camera equipped with a special filter. A digital video camera allows the absorption of the ICG fluorescence to be recorded in real time, allowing perfusion to be assessed and documented. ICG is used as a marker to assess the perfusion of tissues and organs, including retinal blood vessels, liver and lung tumors, and lymphedema.<sup>5,6</sup> ICG fluorescence imaging has also been proven to significantly improve the accuracy of flap blood perfusion evaluation.<sup>7</sup> It has been reported to be useful in identifying the best perforator during operations and in reducing the incidence of postoperative complications, such as flap necrosis and congestion.<sup>8,9</sup>

However, a standardized protocol for the use of ICG in tissue transfers remains elusive. There is no consensus about the routine dose of ICG and the requirement for preoperative allergy testing. Clinical institutions apply ICG differently from procedure to procedure. ICG may be used to design the flap, to assess flap perfusion, to evaluate the patency of microvascular anastomoses, to monitor the flap postoperatively, and to check lymphatic system function.<sup>1,10-12</sup> The aim of this study is to summarize the utility of ICG in tissue transfer surgery and to evaluate the maximum safe dose, routine dose, pre-operative allergy testing protocols, relevant contraindications, and the potential adverse effects in flap surgery; all of which will assist clinicians in applying ICG safely and efficiently.

## Methods

### Data Source and Search Strategy

A literature search was performed using, Wiley InterScience, and SPRINGER. Searches were based on the follow-

ing key words: “Flap,” “Indocyanine green,” “Surgery, and the related mesh words. Due to the large increase in publications in the previous 10 years, the search focused on studies published during the period June 1, 2005 to June 30, 2015. Title and abstract screening was performed using predefined inclusion and exclusion criteria. Publications identified by the prior criteria were screened individually on a full-text basis. The selection process of the articles is shown in ►Fig. 1.

### Inclusion and Exclusion Criteria

A total of 881 articles were obtained by the search query. All articles were screened manually for relevance by the authors following the inclusion and exclusion criteria. The inclusion criteria covered the articles related to the key words, “Flap,” “Surgery,” and “Indocyanine green.” The exclusion criteria included duplicates, animal experiments, and non-English articles.

## Results

### Application of ICG in Flap Surgery

#### Pre-Operative Application of ICG

##### *Pre-Operative Identification of Perforators*

The location of perforators is important for preoperative flap design as the preoperative identification of perforators can significantly shorten operation times and improve surgical outcomes.<sup>13,14</sup> The most common methods to locate perforators include CTA and Doppler ultrasound.<sup>15</sup> Onoda et al<sup>16</sup> combined multidetector-row computed tomography (MDCT), Doppler flowmetry, and ICG fluorescent angiography to preoperatively identify perforator vessels of flaps for reconstruction in 50 patients. Then, they dissected and verified the test results during procedures. They found that MDCT had a 100% (35/35) positive predictive value and a 70% (35/50) sensitivity in detecting perforators. Doppler flowmetry had an 80% (40/50) positive predictive value and a 100% (50/50) sensitivity in detecting perforators. ICG fluorescent angiography had an 84% (42/50) positive predictive value and a 76% (38/50) sensitivity in detecting perforators. In consideration of the low positive predictive value and insensitivity, this evidence suggests that using ICG dye alone to mark a perforator is not an optimal approach. ICG fluorescent angiography seems better utilized when limited to a final confirmation of the perioperative position of the perforator after identification by MDCT or Doppler ultrasound and when restricted to evaluating the dominant perforating branch of a previously identified vessel. Onoda et al also suggest that ICG fluorescent angiography should be used to confirm the detection of perforators when tissue thickness is <20 mm. Pestana and Zenn<sup>17</sup> did not consider ICG fluorescent angiography suitable for preoperative location of perforators, but found the method useful for intraoperative evaluation of blood perfusion, particularly when comparing the efficacy of ICG fluorescent angiography with CTA.

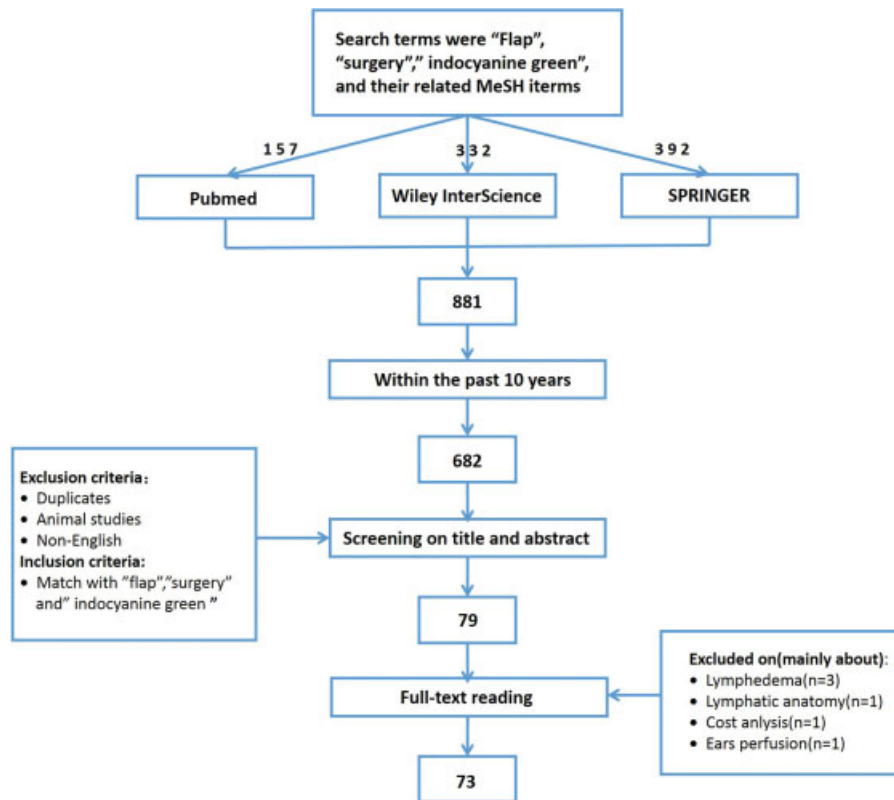


Fig. 1 Flowchart.

### Prediction of Optimal Timing for Second-Stage Operations in Vascular Delay Procedures

When a large flap is harvested to cover an outsized defect, the remaining vascular network in that flap must be able to support the entire flap. To assess the vascular supply of an outsized flap, most surgeons prefer to use the vascular delay method, which contains at least two procedural stages. After the first stage operation, ischemia stimulates the dilation of constricted vessels and angiogenesis.<sup>18</sup> Christensen et al.<sup>19</sup> and Lee et al.<sup>20</sup> used laser-assisted ICG imaging to assess perfusion in free flaps and to inform when and how to divide the target tissue. They concluded that 3 weeks following a first-stage operation was the best time for a second-stage operation. In their experience, ICG fluorescent angiography was useful in decreasing the probability of flap necrosis.

### Intraoperative Application of ICG

#### Intraoperative Evaluation of Microcirculation Perfusion in Flaps

Adequate perfusion of flaps is essential for the postoperative survival. Compromised arterial supply and venous drainage cause postoperative complications, such as flap necrosis.<sup>21,22</sup> Murono et al.<sup>21</sup> found that the intrinsic transit time of the flap, which was defined as the period from when the dye appeared at the arterial anastomosis until it reached the suture line of the venous anastomosis, was ~10 seconds in six free jejunum flaps. Holzbach et al.<sup>23</sup> discovered that the mean transit time between arterial inflow and venous outflow was 32.8 seconds

in eleven free flap cases. The intrinsic transit time of a muscle flap was 27.7 seconds as compared with 47.5 seconds in fasciocutaneous and perforator flaps. Holm et al.<sup>22</sup> evaluated the use of ICG fluorescent angiography in 100 free-flap cases and classified intrinsic transit flow time of >90.0 seconds as venous delay. This delay suggested that microthrombi, existing in the microcirculation of flaps, might elevate the risk of postoperative flap necrosis and congestion. Though no consensus seems to exist for quantifying clinical venous congestion, 90.0 seconds is a suggested threshold for identifying venous delay and pre-emptively assisting venous drainage via supercharging. Nasser et al.<sup>24</sup> found that ICG reliably detects venous congestion in animal models at occlusion rates  $\geq 85\%$ , enabling surgeons to intervene immediately.

While the above-mentioned studies focused largely on the evaluation of perfusion related to one perforator in transferred tissue, when multiple perforators are present in a single flap, surgeons must be able to select and keep the one that will ensure the highest probability of success. Douglas et al.<sup>25</sup> dissected and applied ICG fluorescent angiography to perforators found on either the left or right side of 25 deep inferior epigastric perforator flap (DIEP) flaps. There was no significant difference between the quality of medial and lateral perforators in perfusing zone IV of DIEP flaps. Statistical analysis also confirmed that the perfusion of zone IV fat and skin was significantly higher ( $p < 0.0001$ ) when a single perforator was used to supply the flap than that when two perforators were used. The study concluded that DIEP flaps have poor venous return, and the use of two perforators was

likely to increase the load of venous reflux, thereby leading to postoperative venous congestion. Single superior perforators provided significantly ( $p < 0.0001$ ) better perfusion than that provided by single inferior perforators.

Following the application of ICG fluorescent angiography, SPY-Q quantitative software (Novadaq SPY Elite) is often applied to the analysis of fluorescent intensity in different segments of flaps to assist in the evaluation of the microcirculation perfusion in each zone.<sup>26,27</sup> While there are many ICG fluorescent angiography devices available, including handheld devices (Hamamatsu PDE) and integrated microscope systems (Mitaka, Zeiss), SPY-Q software from SPY Elite is the analytical tool of choice for measuring fluorescence intensity. Munabi et al<sup>28</sup> reported that absolute values (SPY-Q numbers) below 6.0 to 7.0 should be considered areas of critically low vascular perfusion and should be appropriately managed based on collective clinical experience. Moyer et al<sup>29</sup> demonstrated that the threshold of SPY-Q numbers for flap necrosis and stable survival were 6.30 and 12.3, respectively, through 118 cases.

It was also reported that hypertension reduces the probability of flap necrosis, and smoking reduces the probability of flap survival. In another study, Duggal et al<sup>30</sup> found that the 184 patients who underwent post mastectomy breast

reconstruction using ICG angiography imaging had a lower incidence of mastectomy skin necrosis and unexpected reoperations for perfusion-related complications as compared with 184 patients without ICG angiography. This research suggested that the use of ICG angiography during post mastectomy breast reconstruction for evaluating the perfusion of flaps was beneficial and cost effective. Lohman et al<sup>31</sup> made a systematic analysis of 11 articles (198 cases) discussing intraoperative ICG fluorescent angiography for evaluating the perfusion of flaps. They concluded that the sensitivity of intraoperative ICG fluorescent angiography was 90.9%, and the accuracy was 98.6%. ICG has been increasingly applied to evaluate the perfusion of a variety of different types of flaps (► **Table 1**) and has made significant contributions to operative success.

#### *Intraoperative Evaluation of Microcirculation Perfusion in Wound Closure*

Assessing the intraoperative perfusion of the border area of transferred tissue has long been possible using traditional methods, such as capillary reperfusion. Deficiencies in capillary perfusion are understood to lead to an increased probability of postoperative flap necrosis. This phenomenon is related to tension in wound closure. High tension not only

**Table 1** Application of ICG in different types of flaps

Types of flaps	Number of literatures	Subjects	Study
Latissimus dorsi musculocutaneous flap	2	12	Okazaki et al <sup>80</sup> ; Kuriyama et al <sup>63</sup>
DIEP/TRAM	16	652	Casey et al <sup>65</sup> ; Munabi et al <sup>28</sup> ; Duggal et al <sup>30</sup> ; Douglas et al <sup>25</sup> ; Sood et al <sup>52</sup> ; Moyer et al <sup>29</sup> ; Losken et al <sup>48</sup> ; Newman et al <sup>81</sup> ; Quilichini et al <sup>82</sup> ; Newman et al <sup>87</sup> ; Mohebbali et al <sup>83</sup> ; Lee et al <sup>49,84</sup> ; Komorowska <sup>85</sup> ; Yamaguchi <sup>91</sup> ; Holm et al <sup>89,92</sup>
ALT	3	30	Sacks et al <sup>54</sup> ; Nagata et al <sup>50</sup> ; Buehrer et al <sup>10</sup>
Random pattern skin flaps	1	7	Wyles et al <sup>33</sup>
Osteocutaneous flap <sup>a</sup>	3	23	Valerio et al <sup>27</sup> ; Taylor et al <sup>60</sup> ; Nagata et al <sup>50</sup>
Adipofascial cutaneous flap	1	15	Kijima et al <sup>68</sup>
Venous flaps	1	3	Giesen et al <sup>72</sup>
Jejunum flaps	1	6	Murono et al <sup>21</sup>
Intercostal muscle flap	1	27	Piwkowski et al <sup>47</sup>
Pericranial Flaps	1	22	Yano et al <sup>59</sup>
Superficial circumflex iliac artery perforator flap	1	12	Iida et al <sup>71</sup>
RF	3	22	Hayashi et al <sup>64</sup> ; Taylor and Jorgensen <sup>60</sup> ; Nagata et al <sup>50</sup>
Delayed flaps	1	2	Lee et al <sup>49,84</sup>
Forehead flaps	3	17	Surowitz et al <sup>61</sup> ; Shah et al <sup>76</sup> ; Woodard et al <sup>26</sup>
Sural flaps	1	1	Suzuki et al <sup>88</sup>

Abbreviations: ALT, anterolateral thigh flap; DIEP, deep inferior epigastric perforator flap; ICG, indocyanine green; RF, radial forearm flap; TRAM, transverse rectus abdominus myocutaneous.

<sup>a</sup>It is a flap combining bone and skin.

induces scar hyperplasia but also reduces perfusion in the wound.<sup>32,33</sup> Wyles et al<sup>32</sup> applied intraoperative ICG fluorescent angiography to seven cases of wound closure. Wound closures, which showed evidence of ischemia caused by undue tension, were relieved by modification of suture placement. Results showed that this intervention prevented necrosis. Furukawa et al<sup>33</sup> divided 17 patients into two groups. In the first group, where the microcirculation perfusion of wound closure was not evaluated with ICG fluorescent angiography, results showed 89% patients with postoperative wound dehiscence. In the second group, when ICG fluorescent angiography was applied and few suture modifications were performed, only 13% of patients had postoperative wound dehiscence ( $p = 0.003$ ). This research suggests that intraoperative application of ICG fluorescence angiography is effective in preventing postoperative wound dehiscence.

#### *Intraoperative Evaluation of Microcirculation Perfusion in Nerves*

Reconstructive surgery utilizes flaps including cutaneous nerves to restore the sensation of human body. However, few researches have demonstrated the survival and vitality of the nerves in the transferred tissue.<sup>34</sup> Tanaka et al<sup>35</sup> applied ICG fluorescence angiography to eight patients who underwent reconstructive surgery with nerve defects using free anterolateral thigh flaps. This study associated the perfusion of cutaneous nerves with the intensity of fluorescence in those nerves. Tanaka et al also showed that intraoperative ICG fluorescence angiography is a reliable and objective method for selected donor nerves.

#### *Intraoperative Evaluation of Vascular Anastomosis*

Vascular anastomosis is a critical stage during free flap transplantation surgeries.<sup>36</sup> Not efficient anastomosis frequently leads to flap necrosis, arteriovenous crisis, and other complications. On-time detection during surgery of poor anastomosis and immediate repairing by surgeons can increase tissue survival rates. However, the traditional methods to assess vascular anastomoses not ensure an accurate blood flow detection at the anastomotic site. Holm et al<sup>22</sup> applied ICG fluorescence angiography for vascular anastomosis evaluation during 50 free flaps and compared the postoperative changes. They reported that, in comparison with traditional methods, ICG fluorescence angiography resulted in higher sensitivity, and negative ICG fluorescence angiography outcomes were strongly associated with postoperative complications, such as venous congestion.

#### *Microthrombus Detection during Free Flap Re-exploration*

Pedicle tortuosity, hematoma, vasospasm, dressing compression, and thrombosis may lead to postoperative vascular complications or sudden decreases in blood supply to free flaps. According to Chen et al,<sup>37,38</sup> in a retrospective analysis of 1000 free flap cases, over half of the postoperative re-explorations were due to microthrombus formation. Holm et al<sup>39</sup> used ICG fluorescence angiography in 20 postoperative re-exploration surgeries for thrombus detection with a

sensitivity of 100% and specificity of 86%. This seems to indicate that ICG fluorescence angiography is a microthrombus detection method with high accuracy.

### **Postoperative Application of ICG**

#### *Postoperative Detection for Arteriovenous Abnormality*

Local flap necrosis is often due to abnormal arterial supply or venous reflux resulting from postoperative flap hematoma, exudation, and over-pressure.<sup>40</sup> The areas with abnormal blood supply or venous reflux are sometimes larger than the visible necrotic areas. Hagopian et al<sup>12</sup> noted that in one case of postoperative flap necrosis, ICG fluorescence angiography identified a non-fluorescent dark area larger than the visible necrotic area, and after a few days, the necrotic area was expanding to non-fluorescent dark region. His findings indicated that postoperative ICG fluorescence angiography could predict the area of arteriovenous abnormality and provide a useful information when abnormal areas have to be reconstructed. Krishnan et al<sup>41</sup> found two cases of venous congestion in eight tissue transfers following postoperative ICG fluorescence angiography. However, every case in this series later demonstrated adequate perfusion recovery. Though ICG fluorescence angiography is an effective method to detect arteriovenous abnormality, due to its "oversensitivity," clinical presentation should always be taken into consideration when ICG is used to evaluate flap prognosis.

#### *Postoperative Examination of Lymphatic Recovery of Flaps and the Recipient Areas*

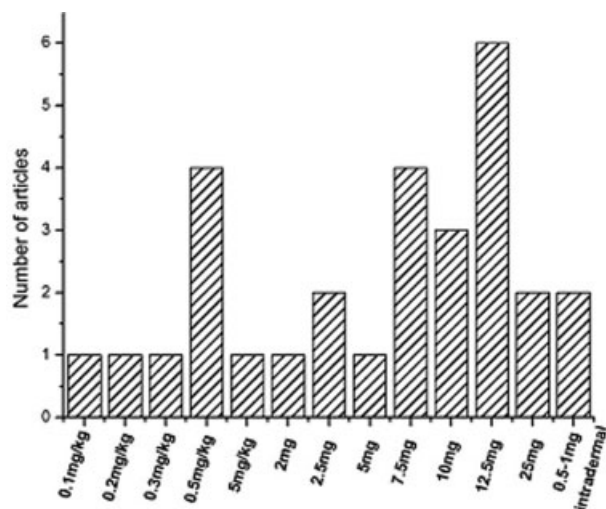
Lymphatic circulation is often damaged in free tissue transfers. Through ICG fluorescence imaging in a patient who had received a free flap transplantation 4.5 years prior, Mihara et al<sup>42</sup> found that lymphatic reconnections had formed between the recipient area and the flap and that ICG injected into the proximal site of the recipient area had drained out of the flap. This showed that ICG can also be used to monitor the lymphatic tissue flap transferred. Akita et al<sup>43</sup> performed ICG fluorescence imaging in 13 cases of lower limb lymphedema patients who received vascularized-free lymph nodes transfers and found that lymphedema improved, and lymph flow was enhanced. This suggests that ICG fluorescence imaging can be used to evaluate the lymphatic drainage of free tissue transfer recipient areas and lymphedematous limbs.

### **The Security of Applying ICG in Flap Surgery**

#### **The Conventional Dose and Maximum Safe Dose of ICG in Plastic Surgery**

ICG fluorescence imaging has been applied for the assessment of a variety of flap types (→ **Table 1**). However, there is no consensus about the optimal intravenous dose. Measurements of free ICG are confounded by in vivo fluorescence quenching, which makes it difficult to predict the precise working dose of ICG needed in the flap. Additionally, all patients have unique circulating plasma volumes and cardiac outputs, which complicate the achievement of consistent in vivo ICG concentration targets. Different medical institutions





**Fig. 2** Frequencies of different doses of indocyanine green reported in flap surgery. The last one is intradermal local dosage for detecting the lymphatic circulation in skin. Others are dosages of intravenous injection. mg/kg: weight of indocyanine green/weight of patients.

and different medical groups use their own experiences to determine the dosage. There is no evidence showing that diverse intravenous dosages will affect the result or the quality of ICG fluorescence imaging. We found 29 articles introducing a potential dosing protocol for ICG (►Fig. 2),<sup>1,11,16,21,22,26–29,31–33,35,39,44–56</sup> and a total dose of 12.5 mg was the most frequently used intravenous dose. The second and third most frequently used intravenous doses were 7.5 mg total and 0.5 mg/kg<sub>(weight)</sub>, respectively. When evaluating local lymphatic function, the doses used at each injection site were 0.5 to 1 mg total. Because ICG is hepatically metabolized and excreted through the kidney with a short half-life of 150 to 180s, it can be repeatedly applied in the same operation. Lee et al<sup>20</sup> suggested that the maximum dose of ICG should be less than 1 mg/kg<sub>(weight)</sub>, while in the literature we have examined that the maximum dose by weight was up to 3 mg/kg<sub>(weight)</sub>.<sup>57</sup> In our clinical cases, we used a total dosage of 10 mg as the conventional dose of ICG for fluorescence angiography. According to our experience, 10 mg total ICG is adequate for assessing the supporting scope of microcirculation in diverse flaps. In the future, ICG dosing should be standardized through large series and clinical trials.

### Adverse Reactions, Preoperative Allergy Testing and Contraindications of ICG

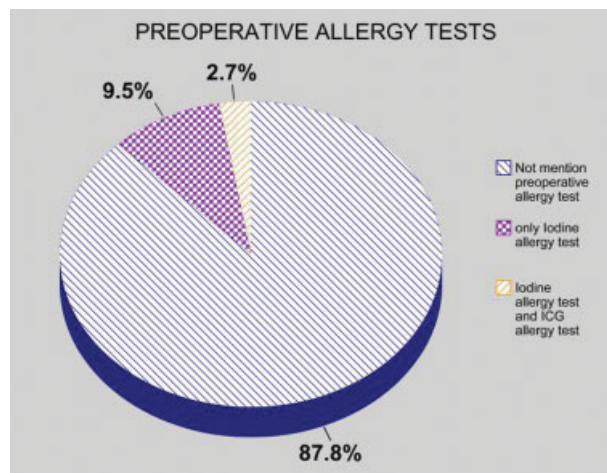
Adverse reactions to ICG were categorized into three levels: mild, moderate, and severe, depending on the duration of the reaction, the need of medical intervention, and the final outcomes. A mild reaction was defined as a transient effect that did not require any treatment with complete and rapid resolution. Nausea, vomiting, extravasation, sneezing, and pruritus were classified as mild reactions. A moderate adverse reaction was defined as a transient effect where medical treatment may have been required. Urticaria, syncope, other skin eruptions, pyrexia, local tissue necrosis, and nerve palsy were categorized

as moderate adverse reactions. A severe adverse reaction was defined as one exhibiting prolonged effects that required intense treatment. A severe adverse reaction involved cardiac, respiratory, and neurologic systems.<sup>5,58</sup>

We have found 74 articles referring to the application of ICG fluorescence imaging in flap surgery of which, 87.8% (65 cases) did not mention preoperative allergy testing<sup>8,10,12,16,17,19–26,29,30,32,33,35,39,42,44,45,47–52,54–56,59–93</sup>; 9.5% (7 cases) only reported preoperative iodine allergy test<sup>26,28,46,53,94–96</sup>; and 2.7% (2 cases) conducted both an iodine allergy test and ICG allergy test<sup>5,57</sup> (►Fig. 3). The lack of reported preoperative ICG allergy tests may be due to the acceptance that ICG is a non-toxic contrast agent with a low rate of allergy (1:42,000–1:60,000) and does not damage blood composition and coagulation systems.<sup>22,39,53</sup> However, in the past 34 years, there had been reported two cases of fatal ICG anaphylaxis.<sup>53</sup> Though no deaths followed preoperative iodine allergy tests, 0 to 4.5% of patients reported experiencing different degrees of allergic reactions.<sup>5,46,58</sup> Therefore, preoperative allergy test seems warranted for ICG procedures. Because iodine allergies are the most probable source of an adverse allergic reaction in ICG procedures,<sup>96</sup> we consider preoperative iodine allergy test a necessary precaution. In addition to hypersensitivity to iodine, contraindications for applying ICG include closed-angle glaucoma, allergic asthma, severe hypertension, hepatic and renal function failure, and pregnancy.<sup>5,96</sup>

### Drawbacks and Prospect of ICG Application in Flap Surgery

Despite the high sensitivity (90.9%) and accuracy (98.6%) of ICG fluorescence imaging<sup>31</sup> in predicting tissue transfer survival, its limited detecting depth (<1 cm) makes the technique insufficient, when used as a standalone method, to evaluate flap microcirculation.<sup>55</sup> However, ICG imaging is



**Fig. 3** Applying preoperative allergy tests before ICG fluorescence imaging. Seventy-four articles were found referring to applying ICG fluorescence imaging in flap surgery, of which, 87.8% (65 cases) did not mention preoperative allergy test; 9.5% (7 cases) only mentioned preoperative iodine allergy test; and 2.7% (2 cases) conducted both an iodine allergy test and an ICG allergy test. ICG, indocyanine green.

an important adjunctive approach when combined with clinical condition as well as the operator's subjective clinical experience.<sup>97</sup>

Proulx et al<sup>98</sup> recently developed a new formulation of ICG that is enveloped with liposomes, and animal experiments have demonstrated increased stabilization, fluorescence intensity, specific absorbance through lymphatic vessels, and ability to create deep lymphatic tissue imaging. This formulation has enhanced the potency of ICG with better imaging depth and has broadened the prospective applications of ICG imaging. In the future, more emphasis on improving the sensitivity and accuracy of ICG to reduce postoperative complications is warranted.

## Conclusions

ICG fluorescence imaging may facilitate the preoperative detection of flap perforators in tissue transfer with thickness <20 mm and may also assist in determining the optimal timing for the second-stage surgeries of delayed flaps. Intraoperatively, ICG may help in evaluating the perfusion of flap microcirculation, assessing microcirculation in wound closures after suturing, selecting dominant cutaneous nerves, evaluating the quality of vascular anastomoses, and locating thromboses. ICG can also be used postoperatively to examine vascular abnormality and lymphatic system recovery. While there is no consensus regarding the recommended ICG dosage, the maximum dose appears to be <3 mg/kg<sub>(weight)</sub>, and the total applied dosages range from 7.5 mg to 12.5 mg. Our experience suggests that 10 mg of total dose is appropriate. The prevalence of allergic reaction to ICG administration has been reported to be 1:42,000–1:60,000, and only two fatalities due to allergy to ICG have been reported. Contraindications and iodine allergies should be assessed before potential use of ICG imaging. ICG remains a low-risk contrast agent, but possible adverse reactions to the agent should be cautiously assessed and be given immediate treatment once they present.

### Conflict of Interest

None of the authors has financial conflicts or interests to report in association with the contents of this paper.

### Acknowledgment

This research was supported by a center of clinical medicine in Shanghai (health education in Shanghai (2012) 052).

## References

- Liu DZ, Mathes DW, Zenn MR, Neligan PC. The application of indocyanine green fluorescence angiography in plastic surgery. *J Reconstr Microsurg* 2011;27(06):355–364
- Dorfman D, Pu LL. The value of color duplex imaging for planning and performing a free anterolateral thigh perforator flap. *Ann Plast Surg* 2014;72(Suppl 1):S6–S8
- Mast BA. Comparison of magnetic resonance angiography and digital subtraction angiography for visualization of lower extremity arteries. *Ann Plast Surg* 2001;46(03):261–264
- Suffee T, Pigneur F, Rahmouni A, Bosc R. Best choice of perforator vessel in autologous breast reconstruction: virtual reality navigation vs radiologist analysis. A prospective study. *J Plast Surg Hand Surg* 2015;49(06):333–338
- Su Z, Ye P, Teng Y, Zhang L, Shu X. Adverse reaction in patients with drug allergy history after simultaneous intravenous fundus fluorescein angiography and indocyanine green angiography. *J Ocul Pharmacol Ther* 2012;28(04):410–413
- Yamamichi T, Oue T, Yonekura T, et al. Clinical application of indocyanine green (ICG) fluorescent imaging of hepatoblastoma. *J Pediatr Surg* 2015;50(05):833–836
- Mothes H, Dönicke T, Friedel R, Simon M, Markgraf E, Bach O. Indocyanine-green fluorescence video angiography used clinically to evaluate tissue perfusion in microsurgery. *J Trauma* 2004;57(05):1018–1024
- Azuma R, Morimoto Y, Masumoto K, et al. Detection of skin perforators by indocyanine green fluorescence nearly infrared angiography. *Plast Reconstr Surg* 2008;122(04):1062–1067
- Matsui A, Lee BT, Winer JH, Laurence RG, Frangioni JV. Quantitative assessment of perfusion and vascular compromise in perforator flaps using a near-infrared fluorescence-guided imaging system. *Plast Reconstr Surg* 2009;124(02):451–460
- Buehrer G, Taeger CD, Ludolph I, Horch RE, Beier JP. Intraoperative flap design using ICG monitoring of a conjoined fabricated anterolateral thigh/tensor fasciae latae perforator flap in a case of extensive soft tissue reconstruction at the lower extremity. *Microsurgery* 2016;36(08):684–688
- Pallotta OJ, van Zanten M, McEwen M, Burrow L, Beesley J, Piller N. Development and validation of a custom made indocyanine green fluorescence lymphatic vessel imager. *J Biomed Opt* 2015;20(06):066003
- Hagopian TM, Ghareeb PA, Arslanian BH, Moosavi BL, Carlson GW. Breast necrosis secondary to vasopressor extravasation: management using indocyanine green angiography and omental flap closure. *Breast J* 2015;21(02):185–188
- Ayhan S, Oktar SO, Tuncer S, Yucel C, Kandal S, Demirtas Y. Correlation between vessel diameters of superficial and deep inferior epigastric systems: Doppler ultrasound assessment. *J Plast Reconstr Aesthet Surg* 2009;62(09):1140–1147
- Imai R, Matsumura H, Tanaka K, Uchida R, Watanabe K. Comparison of Doppler sonography and multidetector-row computed tomography in the imaging findings of the deep inferior epigastric perforator artery. *Ann Plast Surg* 2008;61(01):94–98
- Klasson S, Svensson H, Malm K, Wassélius J, Velerander P. Preoperative CT angiography versus Doppler ultrasound mapping of abdominal perforator in DIEP breast reconstructions: a randomized prospective study. *J Plast Reconstr Aesthet Surg* 2015;68(06):782–786
- Onoda S, Azumi S, Hasegawa K, Kimata Y. Preoperative identification of perforator vessels by combining MDCT, Doppler flowmetry, and ICG fluorescent angiography. *Microsurgery* 2013;33(04):265–269
- Pestana IA, Zenn MR. Correlation between abdominal perforator vessels identified with preoperative CT angiography and intraoperative fluorescent angiography in the microsurgical breast reconstruction patient. *Ann Plast Surg* 2014;72(06):S144–S149
- Ghali S, Butler PE, Tepper OM, Gurtner GC. Vascular delay revisited. *Plast Reconstr Surg* 2007;119(06):1735–1744
- Christensen JM, Baumann DP, Myers JN, Burette K, Sacks JM. Indocyanine green near-infrared laser angiography predicts timing for the division of a forehead flap. *Eplasty* 2012;12:e41
- Lee LN, Smith DF, Boahene KD, Byrne PJ. Intraoperative laser-assisted indocyanine green imaging for objective measurement of the vascular delay technique in locoregional head and neck flaps. *JAMA Facial Plast Surg* 2014;16(05):343–347
- Murono S, Ishikawa N, Ohtake H, et al. Intraoperative free jejunum flap monitoring with indocyanine green near-infrared angiography. *Eur Arch Otorhinolaryngol* 2014;271(05):1335–1338
- Holm C, Mayr M, Höfter E, Dornseifer U, Ninkovic M. Assessment of the patency of microvascular anastomoses using

- microscope-integrated near-infrared angiography: a preliminary study. *Microsurgery* 2009;29(07):509–514
- 23 Holzbach T, Artunian N, Spanholtz TA, Volkmer E, Engelhardt TO, Giunta RE. [Microscope-integrated intraoperative indocyanine green angiography in plastic surgery]. *Handchir Mikrochir Plast Chir* 2012;44(02):84–88
  - 24 Nasser A, Fourman MS, Gersch RP, et al. Utilizing indocyanine green dye angiography to detect simulated flap venous congestion in a novel experimental rat model. *J Reconstr Microsurg* 2015;31(08):590–596
  - 25 Douglas HE, Wilkinson MJ, Mackay IR. Effects of perforator number and location on the total pedicle flow and perfusion of zone IV skin and fat of DIEP flaps. *J Plast Reconstr Aesthet Surg* 2014;67(02):212–218
  - 26 Woodard CR, Most SP. Intraoperative angiography using laser-assisted indocyanine green imaging to map perfusion of forehead flaps. *Arch Facial Plast Surg* 2012;14(04):263–269
  - 27 Valerio I, Green JM III, Sacks JM, Thomas S, Sabino J, Acarturk TO. Vascularized osseous flaps and assessing their bipartate perfusion pattern via intraoperative fluorescence angiography. *J Reconstr Microsurg* 2015;31(01):45–53
  - 28 Munabi NC, Olorunnipa OB, Goltsman D, Rohde CH, Ascherman JA. The ability of intra-operative perfusion mapping with laser-assisted indocyanine green angiography to predict mastectomy flap necrosis in breast reconstruction: a prospective trial. *J Plast Reconstr Aesthet Surg* 2014;67(04):449–455
  - 29 Moyer HR, Losken A. Predicting mastectomy skin flap necrosis with indocyanine green angiography: the gray area defined. *Plast Reconstr Surg* 2012;129(05):1043–1048
  - 30 Duggal CS, Madni T, Losken A. An outcome analysis of intraoperative angiography for postmastectomy breast reconstruction. *Aesthet Surg J* 2014;34(01):61–65
  - 31 Lohman RF, Ozturk CN, Ozturk C, Jayaprakash V, Djohan R. An analysis of current techniques used for intraoperative flap evaluation. *Ann Plast Surg* 2015;75(06):679–685
  - 32 Wyles CC, Taunton MJ, Jacobson SR, Tran NV, Sierra RJ, Trousdale RT. Intraoperative angiography provides objective assessment of skin perfusion in complex knee reconstruction. *Clin Orthop Relat Res* 2015;473(01):82–89
  - 33 Furukawa H, Hayashi T, Oyama A, et al. Effectiveness of intraoperative indocyanine-green fluorescence angiography during inguinal lymph node dissection for skin cancer to prevent postoperative wound dehiscence. *Surg Today* 2015;45(08):973–978
  - 34 Koshima I, Moriguchi T, Soeda S. Reinnervation of denervated Pacinian corpuscles: ultrastructural observations in rats following free nerve grafts. *Plast Reconstr Surg* 1993;92(04):728–735
  - 35 Tanaka K, Okazaki M, Yano T, Miyashita H, Homma T, Tomita M. Quantitative evaluation of blood perfusion to nerves included in the anterolateral thigh flap using indocyanine green fluorescence angiography: a different contrast pattern between the vastus lateralis motor nerve and femoral cutaneous nerve. *J Reconstr Microsurg* 2015;31(03):163–170
  - 36 Khouri RK, Cooley BC, Kunselman AR, et al. A prospective study of microvascular free-flap surgery and outcome. *Plast Reconstr Surg* 1998;102(03):711–721
  - 37 Bui DT, Cordeiro PG, Hu QY, Disa JJ, Pusic A, Mehrara BJ. Free flap reexploration: indications, treatment, and outcomes in 1193 free flaps. *Plast Reconstr Surg* 2007;119(07):2092–2100
  - 38 Chen KT, Mardini S, Chuang DC, et al. Timing of presentation of the first signs of vascular compromise dictates the salvage outcome of free flap transfers. *Plast Reconstr Surg* 2007;120(01):187–195
  - 39 Holm C, Dornseifer U, Sturtz G, Ninkovic M. Sensitivity and specificity of ICG angiography in free flap reexploration. *J Reconstr Microsurg* 2010;26(05):311–316
  - 40 Buchanan IB, Campbell BT, Peck MD, Cairns BA. Chest wall necrosis and death secondary to hydrochloric acid infusion for metabolic alkalosis. *South Med J* 2005;98(08):822–824
  - 41 Krishnan KG, Schackert G, Steinmeier R. Near-infrared angiography and prediction of postoperative complications in various types of integumentary flaps. *Plast Reconstr Surg* 2004;114(05):1361–1362
  - 42 Mihara M, Hara H, Araki J, Narushima M, Iida T, Koshima I. Treatment of hand lymphedema with free flap transfer and lymphangiogenesis analysis after hand replantation using indocyanine green (ICG) lymphography and histological analysis. *J Plast Reconstr Aesthet Surg* 2013;66(11):e338–e340
  - 43 Akita S, Mitsukawa N, Kuriyama M, et al. Comparison of vascularized supraclavicular lymph node transfer and lymphaticovenular anastomosis for advanced stage lower extremity lymphedema. *Ann Plast Surg* 2015;74(05):573–579
  - 44 Green JM III, Thomas S, Sabino J, et al. Use of intraoperative fluorescent angiography to assess and optimize free tissue transfer in head and neck reconstruction. *J Oral Maxillofac Surg* 2013;71(08):1439–1449
  - 45 Mešić H, Kirkeboen KA, Bains R. The importance of a skin bridge in peripheral tissue perfusion in perforator flaps. *Plast Reconstr Surg* 2012;129(03):428e–434e
  - 46 Betz CS, Zhorzel S, Schachenmayr H, et al. Endoscopic assessment of free flap perfusion in the upper aerodigestive tract using indocyanine green: a pilot study. *J Plast Reconstr Aesthet Surg* 2013;66(05):667–674
  - 47 Piwkowski C, Gabryel P, Gąsiorowska Ł, et al. Indocyanine green fluorescence in the assessment of the quality of the pedicled intercostal muscle flap: a pilot study. *Eur J Cardiothorac Surg* 2013;44(01):e77–e81
  - 48 Losken A, Zenn MR, Hammel JA, Walsh MW, Carlson GW. Assessment of zonal perfusion using intraoperative angiography during abdominal flap breast reconstruction. *Plast Reconstr Surg* 2012;129(04):618e–624e
  - 49 Lee BT, Matsui A, Hutteman M, et al. Intraoperative near-infrared fluorescence imaging in perforator flap reconstruction: current research and early clinical experience. *J Reconstr Microsurg* 2010;26(01):59–65
  - 50 Nagata T, Masumoto K, Uchiyama Y, et al. Improved technique for evaluating oral free flaps by pinprick testing assisted by indocyanine green near-infrared fluorescence angiography. *J Craniomaxillofac Surg* 2014;42(07):1112–1116
  - 51 Holm C, Tegeler J, Mayr M, Becker A, Pfeiffer UJ, Mühlbauer W. Monitoring free flaps using laser-induced fluorescence of indocyanine green: a preliminary experience. *Microsurgery* 2002;22(07):278–287
  - 52 Sood M, Glat P. Potential of the SPY intraoperative perfusion assessment system to reduce ischemic complications in immediate postmastectomy breast reconstruction. *Ann Surg Innov Res* 2013;7(01):9
  - 53 Perry D, Bharara M, Armstrong DG, Mills J. Intraoperative fluorescence vascular angiography: during tibial bypass. *J Diabetes Sci Technol* 2012;6(01):204–208
  - 54 Sacks JM, Nguyen AT, Broyles JM, Yu P, Valerio IL, Baumann DP. Near-infrared laser-assisted indocyanine green imaging for optimizing the design of the anterolateral thigh flap. *Eplasty* 2012;12:e30
  - 55 Wu C, Kim S, Halvorson EG. Laser-assisted indocyanine green angiography: a critical appraisal. *Ann Plast Surg* 2013;70(05):613–619
  - 56 Ayestaray B, Andreoletti JB. Microscope-integrated indocyanine green videoangiography for deep inferior epigastric perforator flap. *J Plast Reconstr Aesthet Surg* 2013;66(04):583–585
  - 57 Misaki N, Chang SS, Igai H, Tarumi S, Gotoh M, Yokomise H. New clinically applicable method for visualizing adjacent lung segments using an infrared thoracoscopy system. *J Thorac Cardiovasc Surg* 2010;140(04):752–756
  - 58 Hope-Ross M, Yannuzzi LA, Gragoudas ES, et al. Adverse reactions due to indocyanine green. *Ophthalmology* 1994;101(03):529–533



- 59 Yano T, Okazaki M, Tanaka K, Tsunoda A, Aoyagi M, Kishimoto S. Use of intraoperative fluorescent indocyanine green angiography for real-time vascular evaluation of pericranial flaps. *Ann Plast Surg* 2016;76(02):198–204
- 60 Taylor SR, Jorgensen JB. Use of fluorescent angiography to assess donor site perfusion prior to free tissue transfer. *Laryngoscope* 2015;125(06):E192–E197
- 61 Surowitz JB, Most SP. Use of laser-assisted indocyanine green angiography for early division of the forehead flap pedicle. *JAMA Facial Plast Surg* 2015;17(03):209–214
- 62 Mihara M, Tange S, Hara H, Han Peng Z, Haragi M, Muarai N. Modified lymph vessel flap transplantation for the treatment of refractory lymphedema: a case report. *Microsurgery* 2016;36(08):695–699
- 63 Kuriyama M, Yano A, Yoshida Y, et al. Reconstruction using a divided latissimus dorsi muscle flap after conventional posterolateral thoracotomy and the effectiveness of indocyanine green-fluorescence angiography to assess intraoperative blood flow. *Surg Today* 2016;46(03):326–334
- 64 Hayashi A, Yoshizawa H, Tanaka R, Natori Y, Arakawa A, Mizuno H. Intraoperative use of indocyanine green fluorescence angiography during distally based radial artery perforator flap for squamous cell carcinoma of the thumb. *Plast Reconstr Surg Glob Open* 2015;3(02):e310
- 65 Casey WJ III, Connolly KA, Nanda A, Rebecca AM, Perdakis G, Smith AA. Indocyanine green laser angiography improves deep inferior epigastric perforator flap outcomes following abdominal suction lipectomy. *Plast Reconstr Surg* 2015;135(03):491e–497e
- 66 Royer E, Rausky J, Binder JP, May P, Virzi D, Revol M. [Intraoperative verification of a perforator flap vascularization by indocyanine green angiography]. *Ann Chir Plast Esthet* 2014;59(01):70–75
- 67 Patel KM, Lin CY, Cheng MH. From theory to evidence: long-term evaluation of the mechanism of action and flap integration of distal vascularized lymph node transfers. *J Reconstr Microsurg* 2015;31(01):26–30
- 68 Kijima Y, Yoshinaka H, Hirata M, et al. Oncoplastic surgery combining partial mastectomy and immediate volume replacement using a thoracodorsal adipofascial cutaneous flap with a crescent-shaped dermis. *Surg Today* 2014;44(11):2098–2105
- 69 Kanuri A, Liu AS, Guo L. Whom should we SPY? A cost analysis of laser-assisted indocyanine green angiography in prevention of mastectomy skin flap necrosis during prosthesis-based breast reconstruction. *Plast Reconstr Surg* 2014;133(04):448e–454e
- 70 Tanaka K, Okazaki M. Visualization of blood supply to the 'vascularized nerve' with anterolateral thigh flap using indocyanine green fluorescence angiography. *J Plast Reconstr Aesthet Surg* 2013;66(01):146–147
- 71 Iida T, Mihara M, Yoshimatsu H, Narushima M, Koshima I. Versatility of the superficial circumflex iliac artery perforator flap in head and neck reconstruction. *Ann Plast Surg* 2014;72(03):332–336
- 72 Giesen T, Forster N, Künzi W, Giovanoli P, Calcagni M. Retrograde arterialized free venous flaps for the reconstruction of the hand: review of 14 cases. *J Hand Surg Am* 2014;39(03):511–523
- 73 Dayan JH, Dayan E, Smith ML. Reverse lymphatic mapping: a new technique for maximizing safety in vascularized lymph node transfer. *Plast Reconstr Surg* 2015;135(01):277–285
- 74 Juszczak J. [Two cases of early allergic reactions following a 1-shot intravenous administration of indocyanine green (ICG) and bromsulphothalein (BSP)]. *Wiad Lek* 1972;25:907–912
- 75 Sinove Y, Kyriopoulos E, Ceulemans P, Houtmeyers P, Hoebeke P, Monstrey S. Preoperative planning of a pedicled anterolateral thigh (ALT) flap for penile reconstruction with the multidetector CT scan. *Handchir Mikrochir Plast Chir* 2013;45(04):217–222
- 76 Shah A, Au A. CASE REPORT laser-assisted indocyanine green evaluation of paramedian forehead flap perfusion prior to pedicle division. *Eplasty* 2013;13:e8
- 77 Fujiwara M, Nagata T, Matsushita Y, Fukamizu H. Free hemiback flap with surgical delay for reconstruction of extensive soft tissue defect: a case report. *Microsurgery* 2013;33(02):152–155
- 78 Cheng MH, Chen SC, Henry SL, Tan BK, Lin MC, Huang JJ. Vascularized groin lymph node flap transfer for postmastectomy upper limb lymphedema: flap anatomy, recipient sites, and outcomes. *Plast Reconstr Surg* 2013;131(06):1286–1298
- 79 Phillips BT, Lanier ST, Conkling N, et al. Intraoperative perfusion techniques can accurately predict mastectomy skin flap necrosis in breast reconstruction: results of a prospective trial. *Plast Reconstr Surg* 2012;129(05):778e–788e
- 80 Okazaki M, Tanaka K, Kodaira S, Homma T, Miyashita H. One-stage transfer of 2 paddles of thoracodorsal artery perforator flap with 1 pair of vascular anastomoses for Barraquer-Simons syndrome. *J Craniofac Surg* 2012;23(03):883–885
- 81 Newman MI, Samson MC, Tamburrino JF, Swartz KA, Brunworth L. An investigation of the application of laser-assisted indocyanine green fluorescent dye angiography in pedicle transverse rectus abdominus myocutaneous breast reconstruction. *Can J Plast Surg* 2011;19(01):e1–e5
- 82 Quilichini J, Le Masurier P, Guihard T. [Increasing the reliability of SIEA flap using peroperative fluorescent angiography with indocyanine green in breast reconstruction]. *Ann Chir Plast Esthet* 2010;55(06):531–538
- 83 Mohebbi J, Gottlieb LJ, Agarwal JP. Further validation for use of the retrograde limb of the internal mammary vein in deep inferior epigastric perforator flap breast reconstruction using laser-assisted indocyanine green angiography. *J Reconstr Microsurg* 2010;26(02):131–135
- 84 Lee BT, Hutteman M, Gioux S, et al. The FLARE intraoperative near-infrared fluorescence imaging system: a first-in-human clinical trial in perforator flap breast reconstruction. *Plast Reconstr Surg* 2010;126(05):1472–1481
- 85 Komorowska-Timek E, Gurtner GC. Intraoperative perfusion mapping with laser-assisted indocyanine green imaging can predict and prevent complications in immediate breast reconstruction. *Plast Reconstr Surg* 2010;125(04):1065–1073
- 86 Pestana IA, Coan B, Erdmann D, Marcus J, Levin LS, Zenn MR. Early experience with fluorescent angiography in free-tissue transfer reconstruction. *Plast Reconstr Surg* 2009;123(04):1239–1244
- 87 Newman MI, Samson MC. The application of laser-assisted indocyanine green fluorescent dye angiography in microsurgical breast reconstruction. *J Reconstr Microsurg* 2009;25(01):21–26
- 88 Suzuki A, Fujiwara M, Mizukami T, Fukamizu H. Delayed distally-based super sural flap: evaluation by indocyanine green fluorescence angiography. *J Plast Reconstr Aesthet Surg* 2008;61(04):467–469
- 89 Holm C, Mayr M, Höfner E, Raab N, Ninkovic M. Interindividual variability of the SIEA Angiosome: effects on operative strategies in breast reconstruction. *Plast Reconstr Surg* 2008;122(06):1612–1620
- 90 Frenzel H, Wollenberg B, Steffen A, Nitsch SM. In vivo perfusion analysis of normal and dysplastic ears and its implication on total auricular reconstruction. *J Plast Reconstr Aesthet Surg* 2008;61(Suppl 1):S21–S28
- 91 Yamaguchi S, De Lorenzi F, Petit JY, Rietjens M, Garusi C, Giraldo A, Rey PC, Urban C, Martella S, Bosco R. The "perfusion map" of the unipedicled TRAM flap to reduce postoperative partial necrosis. *Ann Plast Surg* 2004;53(03):205–209
- 92 Holm C, Mayr M, Höfner E, Ninkovic M. Perfusion zones of the DIEP flap revisited: a clinical study. *Plast Reconstr Surg* 2006;117(01):37–43
- 93 Holzbach T, Taskov C, Henke J, et al. [Evaluation of perfusion in skin flaps by laser-induced indocyanine green fluorescence]. *Handchir Mikrochir Plast Chir* 2005;37(06):396–402
- 94 Miyoshi N, Ohue M, Noura S, et al. Surgical usefulness of indocyanine green as an alternative to India ink for endoscopic marking. *Surg Endosc* 2009;23(02):347–351

- 95 Litvack ZN, Zada G, Laws ER Jr. Indocyanine green fluorescence endoscopy for visual differentiation of pituitary tumor from surrounding structures. *J Neurosurg* 2012;116(05):935–941
- 96 Sarkaria IS, Bains MS, Finley DJ, et al. Intraoperative near-infrared fluorescence imaging as an adjunct to robotic-assisted minimally invasive esophagectomy. *Innovations (Phila)* 2014;9(05):391–393
- 97 Koshimune S, Shinaoka A, Ota T, Onoda S, Kimata Y. Laser-assisted indocyanine green angiography aids in the reconstruction of Gustilo grade IIIB open lower-limb fractures. *J Reconstr Microsurg* 2017;33(02):143–150
- 98 Proulx ST, Luciani P, Derzsi S, et al. Quantitative imaging of lymphatic function with liposomal indocyanine green. *Cancer Res* 2010;70(18):7053–7062