

Skull Base Trauma: Clinical Considerations in Evaluation and Diagnosis and Review of Management Techniques and Surgical Approaches

Jacob S. Feldman, MD Soroush Farnoosh, MD Robert M. Kellman, MD Sherard A. Tatum III, MD

¹ Department of Otolaryngology and Communication Sciences, Upstate Medical University, Campus West Building (CWB), Syracuse, New York

Address for correspondence Jacob S. Feldman, MD, Campus West Building (CWB), Room. 241, 750 East Adams Street, Syracuse, NY 13210 (e-mail: feldmanj@upstate.edu).

Semin Plast Surg 2017;31:177–188.

Abstract

Traumatic injuries to the skull base can involve critical neurovascular structures and present with symptoms and signs that must be recognized by physicians tasked with management of trauma patients. This article provides a review of skull base anatomy and outlines demographic features in skull base trauma. The manifestations of various skull base injuries, including CSF leaks, facial paralysis, anosmia, and cranial nerve injury, are discussed, as are appropriate diagnostic and radiographic testing in patients with such injuries. While conservative management is sometimes appropriate in skull base trauma, surgical access to the skull base for reconstruction of traumatic injuries may be required. A variety of specific surgical approaches to the anterior cranial fossa are discussed, including the classic anterior craniofacial approach as well as less invasive and newer endoscope-assisted approaches to the traumatized skull base.

Keywords

- cranial base
- skull base trauma
- surgical approaches
- anterior cranial fossa

The head, deservedly, has been coined the central hub of individuality and communication with the outside world. By virtue of the critical structures encompassed by the craniofacial skeleton, head trauma can have devastating and debilitating consequences. With advancement of our understanding of brain trauma, technology, and medicine, more victims survive to face the sequelae of what were once terminal injuries. There are 30 million trauma-related hospital visits annually, and approximately 16% are associated with traumatic brain injuries (TBIs). Children, older adolescents, and adults aged 65 years or older are among those most likely to sustain TBIs. The incidence of TBIs is also higher in males. As per the Centers for Disease Control and Prevention (CDC) report, males aged 0 to 4 years have the highest rates of TBI-related emergency department visits. However, the rate of hospitalization and death is higher amongst patients 65 years of age and older. Mechanism of injury leading to TBI varies among the demographic parameters. For example, assault and motorized vehicle crashes are major causes of TBI-related deaths up to the third decade of life, whereas falls are implicated in most of the TBI-related deaths

in individuals 65 years of age and older population. In 2010, \$76.5 billion was the estimated economic burden of TBI.¹ In light of the societal and financial burdens involved in cranial trauma and as a result of critical anatomic relationships between important neurologic structures, such as the brain and skull, skull base injuries are an important part of the head trauma mélange. Skull base fractures have been reported in 12% of all head injuries and 20% of all skull fractures.² With the skull base being located at the anatomic gateway of neurovascular connections of the brain with the periphery, timely diagnosis and management of skull base fractures and their complications are of paramount importance. This work aims to briefly review demographics, diagnosis, complications, and surgical management of skull base injuries.

Mechanism of Injury

Motorized vehicle collisions (MVCs) and blunt head trauma have been identified as the leading causes of skull base fractures. A model analysis of MVC collisions revealed that

Issue Theme Skull Base Reconstruction;
Guest Editor: Yadranko Ducic, MD

Copyright © 2017 by Thieme Medical Publishers, Inc., 333 Seventh Avenue, New York, NY 10001, USA.
Tel: +1(212) 584-4662.

DOI <https://doi.org/10.1055/s-0037-1607275>.
ISSN 1535-2188.

82% of the injuries resulted from impacts with hard objects in the vehicles, and higher velocity vector changes were associated with worse injuries.³ Other than local force loading (direct impact), remote loading mechanisms (force exerted distant from the site of fracture), compression mechanisms, and tensile mechanisms have also been implicated in skull base fractures. For instance, mandibular impacts have been associated with transition of the force to the base of skull, causing fractures. Tensile strength of the atlantooccipital ligament has also been hypothesized to avulse bony skull base fragments in high-velocity traumas.⁴ Given the rather high energy impact required for skull base fractures, these are usually associated with TBI and specific craniofacial fracture patterns. Orbital rim and wall fractures, for example, are associated with skull base fractures, but there is no apparent association between skull base fractures and orbital floor, mandible, nasal bone, or zygomaticomaxillary fractures. Skull base fracture is, however, directly associated with an increase in the absolute number of facial fractures.⁵

Anatomy

The human skull is comprised of three embryological components: membranous neurocranium, cartilaginous neurocranium, and viscerocranium. These give rise to the flat skull bones, most of the skull base, and the facial bones, respectively. Classically, the skull base has been divided into three fossae: anterior, middle, and posterior. The frontal bone, lesser wing of the sphenoid, and cribriform plate of the ethmoid bone form the floor of the anterior fossa. The middle fossa is mostly formed by the greater wing of the sphenoid bone and the temporal bone, while the occipital bone is the major component of the posterior cranial fossa. Despite the many anatomic structures comprising the skull base, certain structures bear the brunt of injury. In a retrospective study, temporal bone fractures were the most common skull base fractures (40%), followed by orbital roof (24%), sphenoid (23%), occipital (15.4%), and ethmoid (10.8%). Fractures of the clivus (formed from components of the sphenoid and the occipital bones) were rare (1.03%).²

Historically, classification of fractures into meaningful groups to assist with devising treatment plans and prognostic measures has been studied. In one such study, anterior fossa fractures were stratified into the following four major types: I, cribriform; II, frontoethmoidal; III, lateral frontal; and IV, complex. This study concluded that the farther the fracture was from the midline, the lower was the rate of infection, and that skull base fractures with defects of more than 1 cm were associated with more infections.⁶ Types II and III, however, were associated with more forceful trauma and had higher rates of midface fractures, intracranial injuries, and cerebrospinal fluid leaks.⁷

Multiple parameters have also been proposed for classification of middle cranial fossa and temporal bone fractures, including the axis of the fractures (longitudinal vs. transverse), involvement of otic capsule, involvement of the petrous portion of the temporal bone, and involvement of subsegments of the temporal bone (e.g., tympanic, squamous, mastoid). Trans-

verse fractures (those fractures running perpendicular to the long axis of the temporal bone pyramid) were correlated with sensorineural hearing loss (SNHL), and petrous bone fractures had higher incidence rates of SNHL, vertigo, and eardrum perforation. Interestingly, and perhaps contrary to expectation, in one study assessing the risk of facial palsy in temporal bone fractures, the axis of fracture and subsegments of the temporal bone involved by the fracture were not significantly associated with facial paresis. Only when classifying temporal bone fractures as petrous and nonpetrous, was an association with facial paresis seen in the petrous fracture group.⁸ The reason for this is unclear. The same study of clinical relevance of various temporal bone fracture classification schemes found that involvement of the otic capsule was significantly associated with both incidence and severity of SNHL. Comparing these classifications, the authors concluded that petrous fractures had the highest correlation with vestibulocochlear complaints and facial paralysis.⁸

Posterior cranial fossa fractures present with high mortality and morbidity, but fortunately, their incidence is rather low (0.39–1.2%). Clival fractures are posterior fossa fractures that can be classified as longitudinal, oblique, and transverse and have high mortality rates (40–70%). Cranial neuropathy is an expected consequence of these fractures, as these have an incidence of cranial neuropathy of approximately 100%.^{9,10} High mortality and morbidity of clival fractures can be attributed to higher incidence of brainstem insults associated with these types of fractures, and this is not unexpected given that the clivus rests immediately anterior to the pons.

While there are other possible posterior cranial fossa fracture patterns, including occipital condyle fractures that involve the craniocervical junction, these are beyond the scope of this article.

Evaluation

Like all other cases of trauma, the systematic assessment of the patient with primary and secondary surveys should be undertaken without delay. After completion of the primary survey and when the patient is stabilized, complete physical and neurological examination should be performed as parts of the secondary survey. Quick visual observation of the face and skull as well as palpation of the calvarium and bony landmarks can provide the examiner with important information regarding the extent of possible injuries. Classically, Battle's sign (ecchymosis over the mastoid process) and periorbital ecchymosis have been associated with skull base fractures. Battle's sign and unilateral blepharohematoma have positive predictive values (PPVs) for skull base fractures of 100 and 90%, respectively. Also, bilateral blepharohematoma (raccoon eyes) and bloody otorrhea were associated with skull base fractures but had a lower PPV of 70%. Importantly, these signs, which can be identified easily on visual inspection alone, are predictive of intracranial injuries even if the patient has a Glasgow Coma Scale (GCS) of 13 to 15.¹¹ Another important clue to skull base fractures is traumatic cerebrospinal fluid (CSF) leak, a condition presenting with otorrhea and/or rhinorrhea. CSF leak usually presents acutely near the time of injury but may

present in a delayed manner months or even years after trauma as suggested by cases of occult CSF leak presenting with meningitis remote from the time of injury.¹² While clinical exam findings or subjective patient complaints raise the suspicion of CSF leaks, their diagnosis may be made in several ways. An unsophisticated method of testing suspicious fluid for CSF takes advantage of the differential capillary action of heavier or charged molecules during diffusion through a medium. The halo sign, a ringed pattern formed on gauze when impregnated with CSF, indicates the separation of CSF from heavier blood products and is a nonspecific but confirmatory test for CSF leak. Unfortunately, this classic test for CSF is not specific to CSF, and false positives can be observed with saliva, tears, or nasal secretions. More specific tests have been developed to more accurately diagnose CSF leaks. Meurman et al were the first to note that the beta-2-transferrin protein is exclusive to CSF.¹³ Since then, this test has been useful in confirming the abnormal presence of CSF in other body fluids.¹⁴ Beta-trace protein has also been studied, but its lower specificity in patients with renal insufficiency or bacterial meningitis has made its use limited.¹⁵

While some injuries associated with skull base trauma may be obvious on initial or secondary trauma surveys, there are certainly more occult and subtle injuries that result from craniofacial injury that will be recognized later (after life-threatening or more serious injuries are managed or when the patient is able to cooperate with physical exam maneuvers). Deficits in olfaction resulting from skull base trauma fall into this category. Olfactory neurons distal to the olfactory bulb are themselves the receptor cells of the olfactory system, and their fibers traverse the skull base through a multitude of fenestrations in the cribriform plate. Relatively small shear trauma is required to disrupt this anatomy, making anosmia one of the common complications of the anterior fossa trauma. Once lost, olfaction has a poor prognosis for return varying in the literature from 10 to 30%. Some have studied the use of corticosteroids in traumatic anosmia, showing variable benefits, but the regenerative property of olfactory neurons and resolution of microhematomas and edema over time undermine the validity of assumptions that steroids positively affect return of olfaction in the setting of skull base trauma.^{16,17}

Nonolfactory paresthesias and sensory deficits may be more commonly recognized in the acute phase after traumatic injury because their signs are readily apparent on standard physical exam maneuvers. Middle cranial fossa (or central skull base) fractures that involve the superior orbital fissure, supraorbital foramen, sella, or clivus can present with ophthalmological findings on examination, hypesthesia in the trigeminal sensory distribution (V1 and V2), cranial nerve paresthesias, or Horner's syndrome, and these would be expected to be identified in the more acute phase of trauma evaluation.^{18,19} Middle and posterior cranial fossae injuries are highly associated with cranial neuropathies. Both transverse and longitudinal fractures of the temporal bone have been associated with facial nerve injury at the internal auditory canal or labyrinthine segments and geniculate ganglion, respectively. Glossopharyngeal, vagal, spinal accessory, and hypoglossal nerve injuries

are also likely with fractures that traverse the jugular or hypoglossal foramina.^{19,20}

In summary, a range of injuries can be associated with skull base trauma. A systematic approach such as the well-established primary and secondary trauma survey will benefit the maxillofacial trauma surgeon in the identification of paresthesias, CSF fistula, vestibulocochlear complications, or ocular complications that might exist in a particular patient with skull base injury. Depending on the location of the injury and the subtlety of associated physical exam findings, the signs and symptoms reflecting complications from skull base trauma may be discovered quickly or in a delayed fashion after the inciting injury.

Radiographic Evaluation of Skull Base Fractures

Accessibility of computed tomography (CT) scans in emergency departments and fears of litigation, if low-probability diagnoses are missed, have led to overutilization of advanced imaging tests in the emergency setting.²¹ Guidelines, such as the Canadian CT Head Rule (CCHR) and the New Orleans Criteria (NOC), have been established to try to limit CT scans to patients meeting certain criteria. The decision to acquire a CT head under the NOC for a patient with no loss of consciousness, GCS of 15, and a normal neurological exam comes only with headache, vomiting, age > 60 years, intoxication, seizure, amnesia, or physical evidence of any external injury above the clavicles.²² The CCHR, in contrast, recommends a CT in patients not only with no loss of consciousness or amnesia but also with one or more of the following signs or symptoms: focal neurological deficit, emesis, headaches, age > 65 years, signs of skull base fractures, GCS < 15, coagulopathy, or high-risk mechanism of injury. A comparison study of both systems with respect to their ability to detect skull base trauma revealed that for patients who suffered minor injuries with GCS score of 13 to 15, the CCHR had lower sensitivity to detect all injuries but successfully detected all injuries that eventually benefitted from surgical intervention. The NOC was more sensitive than CCHR for detecting neurocranial trauma. The CCHR, however, was nearly 10 times more specific than the NOC for these outcome measures.²³ Another study comparing the selective CT imaging algorithms, including 1,822 patients with minor head injury and GCS of 15, revealed that both the NOC and the CCHR had 100% sensitivity for predicting the need for neurosurgical intervention, but CCHR was nearly six times more specific. For clinically important brain injury (requiring admission or neurosurgical follow-up), the CCHR and the NOC had similarly high sensitivities, but the CCHR was approximately four times more specific.²⁴ Both studies revealed that CCHR was better at decreasing the number of CT head scans ordered in patients with minor head injuries.^{23,24} Overall, it is unclear which algorithm is superior. Both have rather high sensitivities and are able to capture the majority of significant injuries. Institution- and physician-specific decisions should be made regarding adaption of an algorithm depending on prevalence of head trauma in the specific patient population.

Imaging Modalities Used in Assessment of Skull Base Trauma

In general, thin slice, high-resolution CT scan is the gold standard for evaluation of skull base fractures and also facilitates evaluation of intracranial injuries. CT is particularly effective for assessment of the patency of the neurovascular foramina. It is also the imaging modality of choice for evaluating the integrity of the anterior skull base after suspected injury to the ethmoid fovea and for evaluating likely sources of CSF rhinorrhea after skull base injury. If suspicion for cranial nerve injuries is raised, magnetic resonance imaging (MRI) can play a role in evaluation of cranial nerve integrity. Larger cranial nerves can be easily traced on T2-weighted MRI sequences. Steady-state free precession (SSFP) sequences, in particular, are MRI sequences capable of capturing high-contrast and high-resolution images and delineating CSF and soft tissues. This allows better visualization of cranial nerves that traverse CSF cisterns before entering their skull base foramina, making them invaluable for evaluation of the cerebellopontine angles and inner ear, in addition to providing a window for examination of endolymph and perilymph within the inner ear.²⁵ Other imaging techniques, such as CT or MR angiography, are noninvasive techniques for evaluation of the circulatory system and in some cases, are alternatives to conventional angiography. Powerful imaging tools are at our disposal in the assessment of skull base trauma, and selecting the correct type of imaging study should rely not only on communication with the radiologist with respect to the suspected injuries, but also be based on knowledge about the intrinsic limitations or strengths of a particular imaging study in highlighting different aspects of the neurocranium.

Evaluation and Management of CSF Leak

Trauma is the most common cause of CSF leak, comprising approximately 80% of the cases. As previously mentioned, males are more likely to suffer head trauma, hence traumatic CSF leaks are more common in young males. It is also reported that CSF leak occurs in as many as one-third of patients with basilar skull fractures and in 2% of all head traumas.²⁶ Retrograde transmission of pathogens and development of meningitis is the most feared complication of CSF leak, requiring close clinical observation, a low threshold for diagnostic measures, such as lumbar puncture and initiation of antibiotics, if signs and symptoms of meningeal infection develop. CSF leaks are more common with anterior fossa fractures due to tight attachment of the dura. It has been shown that more medial fractures and defects of greater than 1 cm in length have higher risk of infection compared with more lateral and smaller anterior fossa fractures. Also, leaks not spontaneously resolving within a week were shown to have an infection rate as high as 100%.⁶ Fractures of the temporal bone also can present with CSF otorrhea, if the tympanic membrane is violated, or can present as rhinorrhea via drainage through the Eustachian tube, if the tympanic membrane is intact. Patients may describe salty/sweet rhinorrhea in this case. We discussed the evaluation and diagnosis of CSF leak previously. Localization of

the leak, however, can be challenging even to the most experienced clinicians, especially in the case of intermittent leaks. The first imaging modality for localization of a CSF leak should be a high-resolution CT scan that can easily distinguish skull base bony defects.²⁷ Combination of CT and MRI can significantly increase the sensitivity and specificity of detection and localization of the CSF leak but may not be required when CT scan identifies a definite defect. MR cisternography is a noninvasive technique that utilizes fat-suppressed T2-weighted images to highlight CSF pooling in the extracranial spaces, such as paranasal sinuses. It is generally used only when the previous modalities fail to isolate the source of the leak. In a small study with 15 subjects, this test was able to detect CSF leaks not detected through nasal endoscopy with up to 90% sensitivity and 100% specificity.²⁸ When noninvasive measures fail to identify or localize a CSF leak, more invasive techniques may be used. Intrathecal injections of various agents have been used for evaluation of localization of CSF leaks. These include visible agents, such as fluorescein, radiopaque dyes, such as metrizamide, or radioactive dyes, such as Iodine-131-labeled albumin, which have been used with variable sensitivities and specificities.^{27,29} Once the site of the leak has been identified, management is the next step. Fortunately, conservative management, such as elevation of the head of the bed, and supportive measures, such as laxatives, antiemetics, and anti-tussive medications, as needed, have been shown to allow for spontaneous resolution of CSF leaks up to 85% in the first week.³⁰ A study looking at temporal bone fractures reports near 78% spontaneous resolution of the CSF fistulas.³¹ If conservative measures fail, diversion of CSF (lumbar drain) is the next step to decrease the CSF pressure and allow for spontaneous repair of the leak. CSF diversion can also be used to decrease stress and pressure on a newly repaired defect. Finally, surgical management of the CSF leak, either endoscopic or open, should be considered in cases with brain herniation and in cases that are refractory to conservative management or are too large to spontaneously heal.³² Controversy exists regarding prophylactic use of antibiotics in patients with CSF leaks. Analysis of 5 randomized clinical trials and 17 nonrandomized trials revealed no significant differences between untreated and antibiotic-treated patients with traumatic CSF leak in terms of reduction of the frequency of meningitis, all-cause mortality, meningitis-related mortality, and need for surgical correction.³³ Despite this, individualization of care depending on the duration of leak, severity, and medical comorbidities should be considered.

CSF leaks complicate approximately 2 to 4% of blunt head trauma presentations and most manifest clinically within 48 hours of the injury. In order of decreasing frequency, the ethmoid fovea, cribriform plate, posterior table of the frontal sinus, orbital roof, and sphenoid may be involved in traumatic CSF leaks.³⁴ While 60 to 70% of these leaks resolve with conservative measures (described previously in the text), some require surgical repair. Extracranial approaches with craniotomy were first used in the management of CSF leaks, but the past several decades have seen some shift to transnasal endoscopic approaches for repair of skull base and dura defects.^{34–36}

Endoscopic approaches are used for ethmoidal, sphenoid, sellar, and cribriform defects. Increasingly, these are used in frontal sinus CSF leaks (an anatomic location traditionally approached with craniotomy rather than endoscopy).^{35,37}

A range of options for CSF leak repair is available to the endoscopic surgeon depending on the size of skull base defect, volume of leak, and location. There is some general consensus in the literature that high-flow leaks are best repaired with inclusion of a vascularized mucosal layer as part of the reconstruction.^{38,39} Nonetheless, more simply harvested free mucosal grafts (often from the turbinates) have been used for small cribriform defects, where thin bone prevents multilayered reconstruction, and have even been used with success in selected sellar reconstructions after transnasal pituitary surgery.^{34,40} Tensor fascia lata, free fat grafts, and temporalis fascia grafts are also options for free autografts in skull base reconstruction but require separate incisions for harvest. Composite grafts from the turbinates and pedicled flaps from the inferior or middle turbinate have also been reported and do not require a separate surgical field for harvest. The posteriorly pedicled nasal septal flap, based on the posterior septal artery branch of the sphenopalatine artery, is the workhorse of vascularized intranasal grafts and can cover 50% of the anterior skull base.^{39,41}

Most published data with regard to endoscopic techniques involve small groups of patients undergoing the same technique. This makes comparison between techniques difficult, but a recent comprehensive literature review did offer some conclusions about which techniques to employ in various clinical settings.³⁸ Another publication offers some general guidelines regarding the limitations and utility of different endoscopic reconstructive options.³⁹

When extracranial, nonendoscopic techniques to the skull base are employed, regional flaps, such as the pericranial (galeal) flap, temporalis muscle flap, temporoparietal fascia flap, or even microvascular free tissue grafts, are options.^{42,43}

Xenografts (e.g., bovine pericardium and bovine collagen) and allograft materials, such as cadaveric dermis (alloDerm), also have a role in multilayered CSF leak repair.⁴⁴

Complications of Temporal Bone Fractures

Fractures of the middle cranial fossa can compromise the function of cranial nerves VII and VIII, as these course through temporal bone. Conductive, sensorineural, and mixed hearing losses can be seen with temporal bone fractures. SNHL is most common with transverse fractures and generally has a poor prognosis for recovery. Fractures causing conductive hearing loss might indicate tympanic membrane perforation, hemotympanum, or ossicular chain discontinuity, and these either resolve spontaneously or can be treated electively at a later time.⁴⁵ In severe cases of trauma to the temporal bone that results in severe hearing loss and causes comminuted fractures involving the external ear canal and the middle ear structures, removal of mucosal lining, mastoidectomy, closure of external auditory canal, and obliteration of middle ear may be indicated to prevent cholesteatomas or meningitis.⁴⁶ In patients with bilateral temporal bone trauma leading to bilateral hearing

loss or in patients with contralateral preexisting hearing loss, cochlear implants could be considered to restore hearing.⁴⁷

Facial nerve injury is another complication of temporal bone fractures. Immediate facial nerve paralysis seems to be the driving factor for intervention, as patients with delayed paralysis seem to have a better prognosis with up to 94% with complete recovery. Electroneurography (ENOG) gives objective data comparing the amplitude of motor response on the injured and noninjured sides but must be obtained within a 3 to 14-day window after injury to be reliable. It can be used for detection and surveillance of facial nerve injuries and is often used in conjunction with electromyography (EMG) when making a decision to surgically decompress the facial nerve.⁴⁵ Surgery is usually recommended if no regeneration potentials are noted with EMG, poor prognosis is noted on ENOG (90% reduction in amplitude of motor response on the injured as compared with the noninjured side), or when high-resolution CT reveals severe discontinuity of facial nerve canal in the setting of facial paralysis. Fibrosis, impingement by bone spicules, and laceration were some of the surgical findings in a case series of patients who ultimately underwent facial nerve decompression. Removal of intruding fracture fragments, decompression of the perineural sheath (if the nerve is largely intact and neuronal edema is part of the pathologic process), or suture repair of a partially transected nerve can be performed during the surgical management of facial nerve injury. Nerve grafting is generally reserved for neural discontinuity and inability to perform primary anastomosis.^{45,48} In cases where primary repair or grafting is impossible or unfruitful, hypoglossal-facial nerve anastomosis or regional management, such as upper eyelid gold-weight placement or Botox injection can improve cosmesis and quality of life.^{49,50} The full range of surgical therapies for facial nerve paralysis not amenable to primary repair or immediate grafting takes into account the chronicity of the injury, vitality of the motor units, presence of motor unit atrophy, and presence of concomitant cranial nerve injuries. However, full discussion of management of facial nerve paralysis is beyond the scope of this article.

Specific Surgical Approaches

To provide surgical management options for extirpation of tumors involving the middle and anterior skull base, so called craniofacial disassembly techniques were developed. These generally involve intracranial access through the use of a frontal craniotomy with extracranial access via the use of transfacial incisions and reduction in the amount of brain retraction required for exposure. These approaches are useful for trauma as well.

Refinement of endoscopic techniques has partially supplanted the need for open resection techniques for certain skull base tumors;⁵¹ however, in the management of facial trauma or reconstructive craniofacial surgery, open nonendoscopic, anterior skull base approaches retain importance in the reconstruction and repair of the craniofacial skeleton, as these allow reconstruction of traumatic bony injuries, with an ability to stabilize the facial and cranial skeleton and

contemporaneously allow management of associated injuries such as those described above.

Transfrontal Approach (Anterior Craniofacial Resection Technique)

The classic anterior approach to the skull base is that modeled after the anterior craniofacial resection technique. When used for tumor extirpation, this open approach is ideal for tumors involving the ethmoid sinuses and anterior skull base. It begins with bicoronal incision, development of a bicoronal flap, and frontal craniotomy. Modifications of the approach allow access to the skeleton in case of trauma.

During this approach, a coronal incision is performed in the usual manner with elevation of the flap in a subgaleal or subperiosteal plane depending on the need for a separate vascularized pericranial flap. If required for reconstruction, a separately elevated pericranial flap is raised, and both flaps are then extended to the orbital rims. Frontal craniotomy is then performed, and the central segment of the frontal bones is removed. This allows intracranial exposure of the anterior cranial fossa after sacrifice of the olfactory nerves and subsequent frontal lobe retraction. Loss of olfaction is a consequence, and complications from frontal lobe retraction are possible. Meanwhile, transfacial incisions, including Weber Ferguson, facial degloving, and Lynch incisions, are combined to allow exposure at the level of the midface for osteotomies (for resection) or to allow exposure of the skeleton (for reconstruction).

Modifications of this classic technique, with respect to the supraorbital bar, glabella, and nasal bones, lead to the additional anterior skull base approaches described in the literature, and these modifications of the classic approach to the anterior cranial base are briefly discussed below.

Basal Subfrontal (Basal Approach)

Combining the coronal flap and frontal craniotomy, described above, with additional osteotomies that allow en bloc removal of parts of the anterior cranial floor and supraorbital bar,

defines the basal subfrontal approach. As compared with the transfrontal (anterior craniofacial) approach, more posterior aspects of the anterior cranial base, such as the sphenoid body and upper clivus, can be approached with these modifications.⁵¹ The basal subfrontal approach has been used to access skull base meningiomas, chondromas, chondrosarcomas, and fibrous dysplasia as well as trauma.⁵² Removal of the supraorbital bar and orbital roofs required in this technique relies on dissection of the periorbital from the orbital roof (after coronal exposure and downfracture of the supraorbital foramina) and osteotomies superior to the level of the ethmoidal artery foramina (►Fig. 1). The amount of frontal lobe retraction required in this technique is reduced dramatically secondary to additional removal of the supraorbital bar⁵³ (►Fig. 2).

Subcranial/Transglabellar Approach

The subcranial/transglabellar approach was first described in a group of 395 patients suffering from midface traumatic injuries.⁵⁴ It was later used in extirpative surgery of benign and malignant skull base tumors.^{55,56} The subcranial/transglabellar approach differs from the classic anterior craniofacial approach, as it does not require transfacial incisions, and a different combination of osteotomies (if required) allows removal of the frontal bone and supraorbital bar in continuity. In this approach, coronal incision, in combination with downfracture of the inferior aspect of the supraorbital foramina, provides the facial skeleton exposure, including the frontal bones, glabella, and nasion (►Fig. 3). Frontoethmoidal, orbital, frontal and lateral nasal, and dorsal septal osteotomies are combined to allow removal of the frontal bone, supraorbital bar, and nasion in continuity (►Figs. 4 and 5). When used for exposure of the anterior cranial fossa, removal of the supraorbital bar and nasal bones in this approach allows improved anterior exposure that reduces the need for frontal lobe retraction and avoids sacrifice of the olfactory nerves (as compared with the anterior craniofacial approach and basal subfrontal approach). In addition, there are cosmetic advantages of avoiding the transfacial incisions. Access, as far

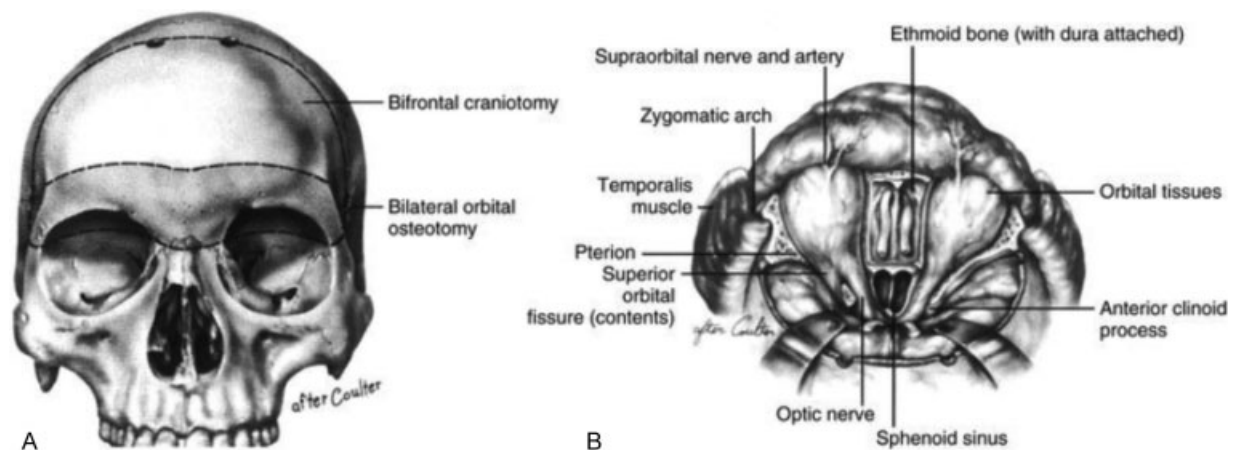


Fig. 1 Bifrontal craniotomy and orbital osteotomy are denoted by the dashed lines in the left pane (A). This combination of osteotomies, employed in the basal subfrontal approach to the skull base, allows for the intracranial exposure shown in the second pane (B). (Adapted from Flint PW, et al. Cummings Otolaryngology Head and Neck Surgery, 6th ed. Surgery of the Anterior Skull Base, Figure 174–16 and reproduced with permission from Elsevier).

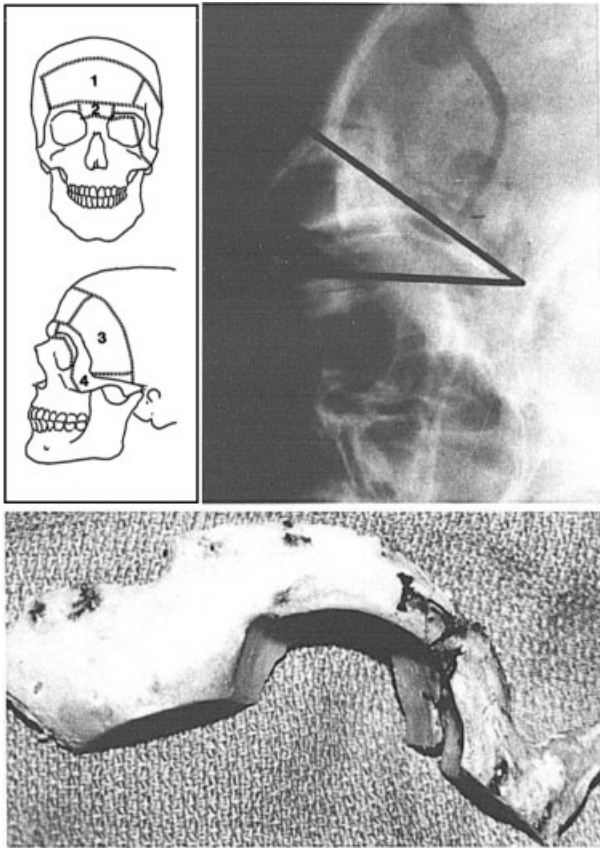


Fig. 2 Extended supraorbital rim osteotomy performed after frontal osteotomy in the basal subfrontal approach allows reduced angles of frontal lobe retraction as illustrated in this figure (Adapted from Snyderman et al⁵⁴ and reproduced with permission from Wiley and Sons).

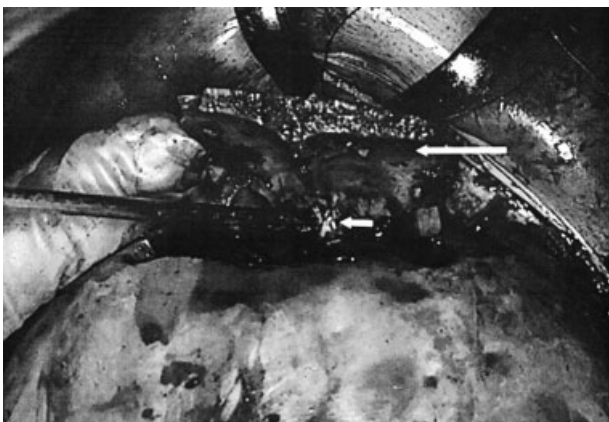


Fig. 3 In the transglabellar subcranial approach, coronal incision and downfracture of the supraorbital foramina followed by en bloc removal of portions of the frontal bone, glabella, and nasion, give access to the central skull base while minimizing manipulation of the brain from above. Large arrow represents bone flap liberated by osteotomies in the subcranial/transglabellar approach. Small arrow represents a nasal dermoid tumor exposed using this technique. (Adapted from Kellman et al⁵⁸ and reproduced with permission from Wiley and Sons.)

posteriorly as the sella, orbital apices, and the upper clivus, is possible with the subcranial/transglabellar approach.⁵¹

This approach has been used in the management of pediatric dermoid tumors, esthesioneuroblastoma, and orbital meningiomas as well as facial trauma.^{54,55,57}

Pterional Approach

Pterional craniotomy, also known as a frontotemporal craniotomy, offers access to a wide variety of intracranial pathologies, including aneurysms of the anterior or posterior intracranial circulation; access to hyperfunctioning areas of the mesial temporal lobe in seizure disorders; and also surgical access to the cavernous sinus and superior orbital fissure.^{58–60} Although not the only method of reaching the parasellar or sellar skull base, it does provide access to this location.⁶¹ The procedure begins with a skin incision approximately 1 cm anterior to the tragus at the zygomatic root. Alternatively, the incision can extend postauricularly rather than preauricularly. The curvilinear incision extends superiorly before curving anteriorly and inferiorly (roughly paralleling the temporal line) to terminate behind the hairline at the midline. The superficial temporal artery is preserved in the skin flap, and subsequently, reflection and focal incision of the temporalis muscle followed by subperiosteal dissection allow bone exposure for frontotemporal osteotomy and subsequent access to the intracranial space.⁶² Dissecting along the Sylvian fissure along with brain retraction then allows access to the midline structures, mesial temporal lobe, superior orbital fissure, or anterior cranial fossa. Several modifications to the soft tissue dissection and the extent of the craniotomy have since been developed to avoid known complications, such as temporalis wasting and facial nerve injury. The minipterional craniotomy and interfascial temporalis fat pad dissection prior to temporalis reflection are two such modifications that have been developed to minimize extensive craniotomy and avoid injury to the frontal branch or temporalis wasting.^{58,63,64} Other modifications are well described in a recent publication by Altay and Couldwell.⁶¹

Transorbital Approach

Combinations of frontal, temporal, and orbital craniotomy give rise to various extraorbital approaches to neoplasms of the orbit or traumatic bony orbital defects. Included among these approaches are frontoorbital craniotomy approaches and frontotemporal orbital craniotomy approaches. Generally, these rely on the classic coronal incision and reflection of parts of the temporalis muscle to allow craniotomy and then involving en bloc or segmental removal of bone for access to the orbit or other pathologies, such as parasellar meningiomas, craniopharyngiomas, olfactory groove meningiomas, and orbital tumors as well as anterior communicating artery (ACA) aneurysms.^{65,66}

A supraorbital keyhole craniotomy avoids the bicoronal incision and decreases the size of the craniotomy by using a transbrow incision with endoscopic guidance and a smaller craniotomy for selected supraorbital lesions and parasellar areas but is still considered an extraorbital approach.⁶⁷

Approaching orbital pathology more directly is sometimes preferred for selected pathology of the orbit. Various transorbital approaches rely on incisions other than the

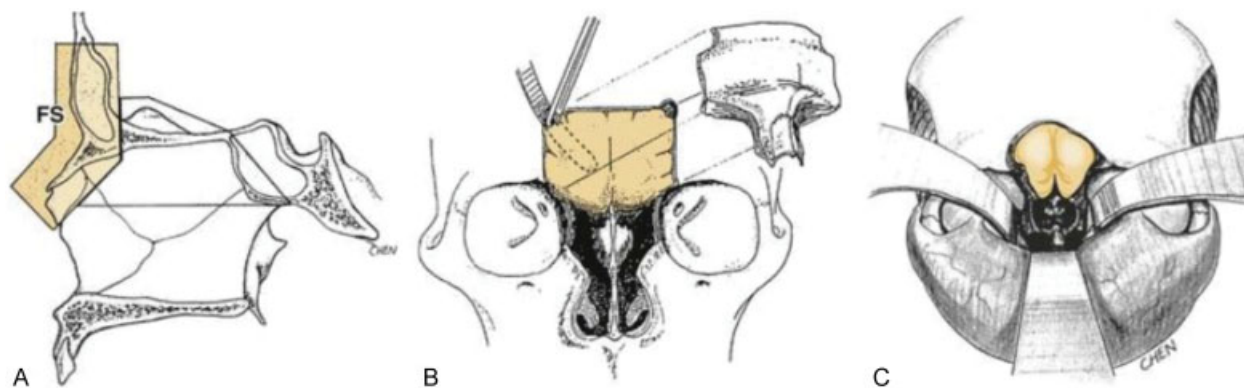


Fig. 4 Sagittal (A) and coronal (B) views of the osteotomies performed in the transglabellar/subcranial approach to the skull base. "FS" indicates the planned frontonasal osteotomy block. After bone plate removal, the area of surgical exposure is conceptualized in (C) with the orbital apex sphenoid and sella visualized deep into the field of exposure beneath the frontal lobes (Adapted from Flint PW, et al. Cummings Otolaryngology Head and Neck Surgery, 6th ed., Surgery of the Anterior Skull Base, Figure 174–17 and reproduced with permission from Elsevier).

bicoronal or modified frontotemporal craniotomy incisions used in the extraorbital approaches described above.

These incisions are familiar to ophthalmologic, plastic, and otorhinolaryngologic surgeons and include eyelid crease (→Fig. 6), lateral lid, subciliary, lower lid, brow, Lynch, Kronlein, or transconjunctival incisions with or without canthotomy and cantholysis, to name a few. The incisions allow manipulation of the orbital skeleton for tumor resection, management of traumatic injuries, and orbital decompression. These also serve as

the first step in traditional transorbital approaches to the posterior orbit, such as lateral orbitotomy, posterolateral orbitotomy, and medial orbitotomy. These approaches often require disruption and then reconstruction of various orbital structures, such as the canthal ligaments and medial rectus insertions.

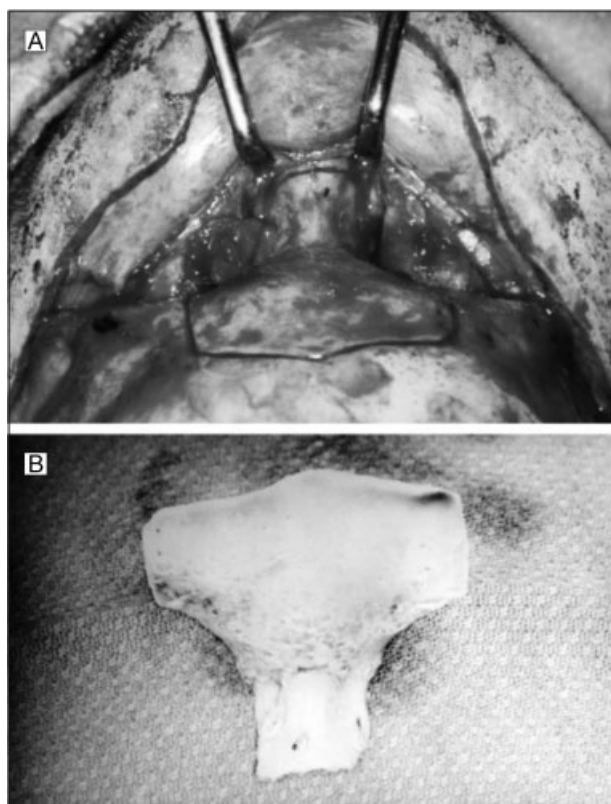


Fig. 5 Transglabellar/subcranial approach. Retraction on skull base may be minimized. Here, the frontonasal bone flap is shown in anatomic position (A) and also after explant (B). Frontal, ethmoidal, orbital, dorsal septal, and lateral nasal osteotomies are required for excision of the bone flap (Photos from Kellman et al⁵⁷ and reproduced with permission from JAMA).

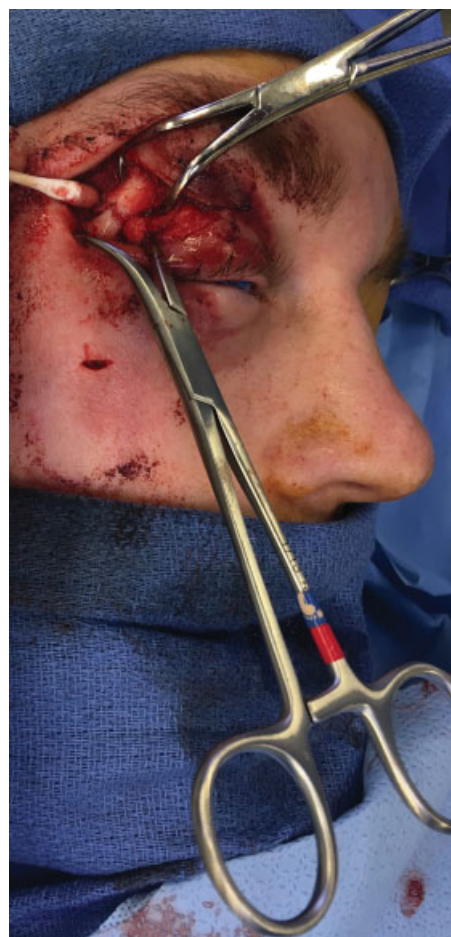

Fig. 6 Transorbital access to the facial skeleton (in this case to the lateral orbital wall) is accomplished through an eyelid crease incision for reduction and fixation of a displaced zygomaticofrontal suture.

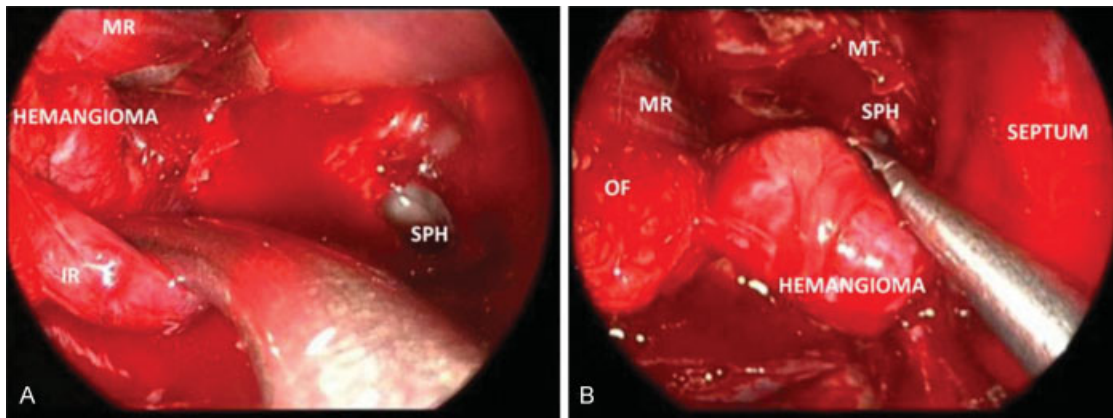


Fig. 7 In these photos, successful access to intraorbital pathology (in this case, a hemangioma) using a purely endonasal, endoscopic approach is demonstrated. In image (A), a curved probe inserted intranasally is used to dissect an intraconal hemangioma between IR and MR. In image (B), hemangioma is pulled away from the orbital structure and into the nasal airway. IR, inferior rectus; MR, medial rectus; MT, middle turbinate; OF, orbital fat; SPH, sphenoid sinus. (Adapted from Chhabra et al⁷² and reproduced with permission from Wiley and Sons.)

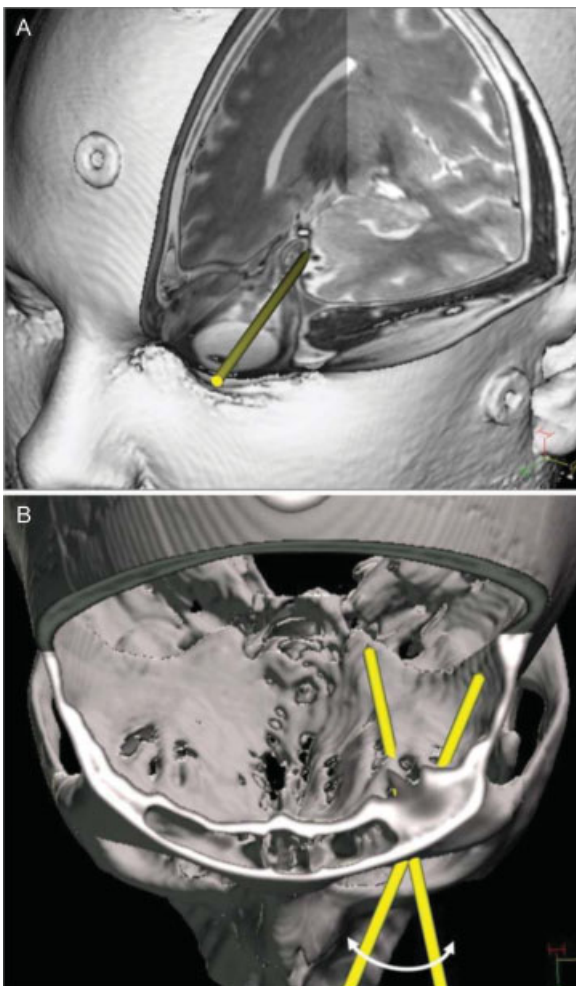


Fig. 8 The lid crease incision is one of many small periorbital incisions used in a transorbital neuroendoscopic surgery (TONES) and it may be combined with other periorbital incisions to facilitate better exposure. Pane (A) is a MRI/CT fusion image used in preoperative planning. The wand represents a 4 mm endoscope drawn to scale and inserted through a lid crease incision. In pane (B), also an MRI/CT fusion image, the area bound between the two wands approximates the ipsilateral skull base accessible through a superior lid crease incision. (Adapted from Moe et al⁷⁶ and reproduced with permission from Wiley and Sons.)

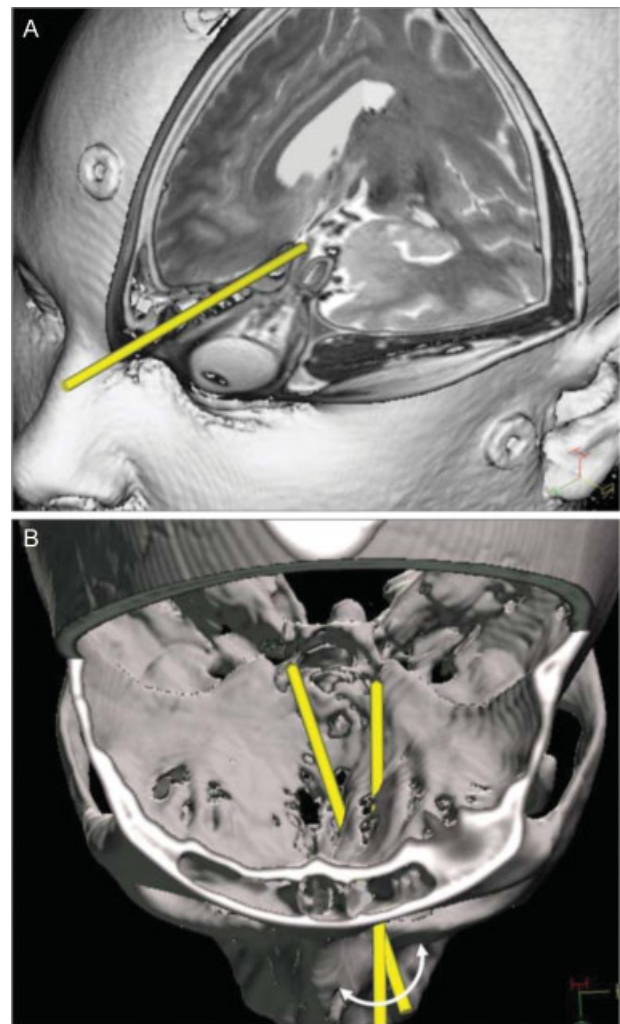


Fig. 9 TONES surgery may also involve a precanthal incision which is suited to access the central (interorbital) skull base. A scaled representation of a 4 mm endoscope inserted through a precanthal incision is shown on a MRI/CT fusion in pane (A). The central skull base accessible through the precanthal incision is the area bound between the wands in pane (B). Adapted from Moe et al⁷⁶ and reproduced with permission from Wiley and Sons.)

Occasionally and especially in the case of the orbital floor, orbital pathology is addressed without facial incisions. Transantral endoscopic approaches have been described in the setting of orbital floor fractures and also for posterior/inferior orbital pathology.⁶⁸ The transantral approach using gingivoalveolar incisions is familiar to otolaryngologists, as it forms the basis of the Caldwell–Luc procedure.

Yet another variation on approaching orbital pathology is the combination of facial incisions with an endonasal endoscopic approach to the orbit, and this has been used to facilitate access to difficult to reach orbital structures and even to access intracranial structures, such as the medial temporal lobe.⁶⁹

Purely endonasal endoscopic strategies without facial incisions have also been described as an alternative to more traditional medial orbitotomy approaches to the orbital apex, as an approach to traumatic optic nerve injuries, and for decompression of the optic nerve, and as the preferred method, in the opinion of many surgeons, for orbital decompression in thyroid-mediated orbitopathy.^{70,71} Orbital, visual, and endonasal complications are possible with these approaches but are likely to occur infrequently.^{72,73}

The purely endoscopic endonasal approaches to the orbit rely on wide maxillary antrostomy, sphenoidotomy, complete ethmoidectomy, and partial middle turbinate resection (→Fig. 7), but access to the more paramedian and lateral anterior skull base is limited.

Seeking to build on advances in endoscopic surgery, expand access to the paramedian and lateral anterior cranial skull base, as well as avoid some ergonomic and angular limitations from the strictly endonasal endoscopic approach, Moe and colleagues developed what they deemed transorbital neuroendoscopic surgery or “TONES.”⁷⁴ In addition, they advocated for modified transorbital approaches, including the precaruncular incision, lateral retrocanthal incision, and conjunctival incision to preserve the eyelid support (canthal) systems. In their approach, the number of transcutaneous incisions was kept to a minimum with only the eyelid crease incision traversing the skin. The incisions described created four ports for the introduction of endoscopic equipment, and the technique has been used to address the optic nerve, anterior skull base defects, CSF leaks, and periorbital tumors.^{74–76} Of note, TONES approaches with excellent CSF fistula repair rates were first characterized in a patient cohort where many patients had failed other techniques at closure (revision cases). This suggests TONES as a reasonable alternative to traditional open (extracranial) and purely endonasal strategies for CSF leak repair.

More recently, TONES was suggested as an approach to the lateral cavernous sinus orbital apex, Meckel’s cave, and the middle fossa floor using the lateral retrocanthal incision.⁷⁷ The wide access to the anterior skull base via small orbital incisions in TONES was demonstrated in a recent publication (→Figs. 8 and 9).

In summary, a variety of different techniques are available for approach to the orbit, with endonasal, endoscopic, and TONES reflecting relatively recent developments in the armamentarium that augment more invasive and traditional extracranial approaches.

Conclusion

Skull base injuries, an important component of the head trauma mélange, are significant in that these are coincident with TBI and are also associated with a range of neurologic, sensory, and possible infectious complications. Plastic surgeons and a range of other surgical and nonsurgical specialists are called on to evaluate persons with such injuries. Important to any consultant is a sound evaluation strategy, heightened suspicion for the range of possible complications, associated injuries in cranial trauma, and a basic understanding of the evolving surgical management for complications of head trauma.

References

- 1 CDC. Traumatic brain injury& Concussion. 2017; Available at: <http://www.cdc.gov/traumaticbraininjury/>. Accessed March 28, 2017
- 2 Michael L, Mandana B. Retrospective study of skull base fracture: a study of incidents, complications, management, and outcome overview from trauma-one-level institute over 5 years. *J Neurol Surg B Skull Base* 2013;74(01):239
- 3 Grant JR, Rhee JS, Pinter FA, Yoganandan N. Modeling mechanisms of skull base injury for drivers in motor vehicle collisions. *Otolaryngol Head Neck Surg* 2007;137(02):195–200
- 4 McElhaney JH, Hopper RH Jr, Nightingale RW, Myers BS. Mechanisms of basilar skull fracture. *J Neurotrauma* 1995;12(04):669–678
- 5 Slupchynskij OS, Berkower AS, Byrne DW, Cayten CG. Association of skull base and facial fractures. *Laryngoscope* 1992;102(11):1247–1250
- 6 Sakas DEB, Beale DJ, Ameen AA, et al. Compound anterior cranial base fractures: classification using computerized tomography scanning as a basis for selection of patients for dural repair. *J Neurosurg* 1998;88(03):471–477
- 7 Madhusudan G, Sharma RK, Khandelwal N, Tewari MK. Nomenclature of frontobasal trauma: a new clinico-radiographic classification. *Plast Reconstr Surg* 2006;117(07):2382–2388
- 8 Kang HM, Kim MG, Boo SH, et al. Comparison of the clinical relevance of traditional and new classification systems of temporal bone fractures. *Eur Arch Otorhinolaryngol* 2012;269(08):1893–1899
- 9 Winkler-Schwartz A, Correa JA, Marcoux J. Clival fractures in a level I trauma center. *J Neurosurg* 2015;122(01):227–235
- 10 Menkü A, Koç RK, Tücer B, Durak AC, Akdemir H. Clivus fractures: clinical presentations and courses. *Neurosurg Rev* 2004;27(03):194–198
- 11 Pretto Flores L, De Almeida CS, Casulari LA. Positive predictive values of selected clinical signs associated with skull base fractures. *J Neurosurg Sci* 2000;44(02):77–82; discussion 82–83
- 12 Guyer RA, Turner JH. Delayed presentation of traumatic cerebrospinal fluid rhinorrhea: case report and literature review. *Allergy Rhinol (Providence)* 2015;6(03):188–190
- 13 Meurman OH, Irjala K, Suonpää J, Laurent B. A new method for the identification of cerebrospinal fluid leakage. *Acta Otolaryngol* 1979;87(3–4):366–369
- 14 Oberascher G, Arrer E. Efficiency of various methods of identifying cerebrospinal fluid in oto- and rhinorrhea. *ORL J Otorhinolaryngol Relat Spec* 1986;48(06):320–325
- 15 Meco C, Oberascher G, Arrer E, Moser G, Albegger K. Beta-trace protein test: new guidelines for the reliable diagnosis of cerebrospinal fluid fistula. *Otolaryngol Head Neck Surg* 2003;129(05):508–517
- 16 West OC, Mirvis SE, Shanmuganathan K. Transsphenoid basilar skull fracture: CT patterns. *Radiology* 1993;188(02):329–338
- 17 Proskynitopoulos PJ, Stippler M, Kasper EM. Post-traumatic anosmia in patients with mild traumatic brain injury (mTBI): a

- systematic and illustrated review. *Surg Neurol Int* 2016;7 (Suppl 10):S263–S275
- 18 Worthington JP, Snape L. Horner's syndrome secondary to a basilar skull fracture after maxillofacial trauma. *J Oral Maxillofac Surg* 1998;56(08):996–1000
 - 19 Katzen JT, Jarrahy R, Eby JB, Mathiasen RA, Margulies DR, Shahinian HK. Craniofacial and skull base trauma. *J Trauma* 2003;54 (05):1026–1034
 - 20 Lehn AC, Lettieri J, Grimley R. A case of bilateral lower cranial nerve palsies after base of skull trauma with complex management issues: case report and review of the literature. *Neurologist* 2012;18(03):152–154
 - 21 Kanzaria HK, Hoffman JR, Probst MA, Caloyer JP, Berry SH, Brook RH. Emergency physician perceptions of medically unnecessary advanced diagnostic imaging. *Acad Emerg Med* 2015;22(04):390–398
 - 22 Haydel MJ, Preston CA, Mills TJ, Luber S, Blaudeau E, DeBlieux PM. Indications for computed tomography in patients with minor head injury. *N Engl J Med* 2000;343(02):100–105
 - 23 Smits M, Dippel DW, de Haan GG, et al. External validation of the Canadian CT Head Rule and the New Orleans Criteria for CT scanning in patients with minor head injury. *JAMA* 2005;294 (12):1519–1525
 - 24 Stiell IG, Clement CM, Rowe BH, et al. Comparison of the Canadian CT Head Rule and the New Orleans Criteria in patients with minor head injury. *JAMA* 2005;294(12):1511–1518
 - 25 Sheth S, Branstetter BF IV, Escott EJ. Appearance of normal cranial nerves on steady-state free precession MR images. *Radiographics* 2009;29(04):1045–1055
 - 26 Friedman JA, Ebersold MJ, Quast LM. Post-traumatic cerebrospinal fluid leakage. *World J Surg* 2001;25(08):1062–1066
 - 27 Stone JA, Castillo M, Neelon B, Mukherji SK. Evaluation of CSF leaks: high-resolution CT compared with contrast-enhanced CT and radionuclide cisternography. *AJNR Am J Neuroradiol* 1999;20 (04):706–712
 - 28 Sillers MJ, Morgan CE, el Gammal T. Magnetic resonance cisternography and thin coronal computerized tomography in the evaluation of cerebrospinal fluid rhinorrhea. *Am J Rhinol* 1997; 11(05):387–392
 - 29 Keerl R, Weber RK, Draf W, Wienke A, Schaefer SD. Use of sodium fluorescein solution for detection of cerebrospinal fluid fistulas: an analysis of 420 administrations and reported complications in Europe and the United States. *Laryngoscope* 2004;114(02):266–272
 - 30 Bell RB, Dierks EJ, Homer L, Potter BE. Management of cerebrospinal fluid leak associated with craniomaxillofacial trauma. *J Oral Maxillofac Surg* 2004;62(06):676–684
 - 31 Brodie HA, Thompson TC. Management of complications from 820 temporal bone fractures. *Am J Otol* 1997;18(02):188–197
 - 32 Prosser JD, Vender JR, Solares CA. Traumatic cerebrospinal fluid leaks. *Otolaryngol Clin North Am* 2011;44(04):857–873, vii
 - 33 Ratilal BO, Costa J, Sampaio C, Pappamikail L. Antibiotic prophylaxis for preventing meningitis in patients with basilar skull fractures. *Cochrane Database Syst Rev* 2011;(08):CD004884
 - 34 Batra PS. Endoscopic evaluation and treatment of CSF leaks. *Bailey's Head and Neck Surgery–Otolaryngology*. Wolters Kluwer Health/Lippincott Williams & Wilkins; 2014 (p. 1 online resource, 2 volumes)
 - 35 Citardi M, Fakhri S. Cerebrospinal fluid rhinorrhea. *Cummings Otolaryngology: Head and Neck Surgery*. Philadelphia, PA: Elsevier Health Sciences; 2015 (p. 1 online resource)
 - 36 Reyes C, Mason E, Solares CA. Panorama of reconstruction of skull base defects: from traditional open to endonasal endoscopic approaches, from free grafts to microvascular flaps. *Int Arch Otorhinolaryngol* 2014;18(Suppl 2):S179–S186
 - 37 Jones V, Virgin F, Riley K, Woodworth BA. Changing paradigms in frontal sinus cerebrospinal fluid leak repair. *Int Forum Allergy Rhinol* 2012;2(03):227–232
 - 38 Soudry E, Turner JH, Nayak JV, Hwang PH. Endoscopic reconstruction of surgically created skull base defects: a systematic review. *Otolaryngol Head Neck Surg* 2014;150(05):730–738
 - 39 Zuniga MG, Turner JH, Chandra RK. Updates in anterior skull base reconstruction. *Curr Opin Otolaryngol Head Neck Surg* 2016;24 (01):75–82
 - 40 Fishpool SJ, Amato-Watkins A, Hayhurst C. Free middle turbinate mucosal graft reconstruction after primary endoscopic endonasal pituitary surgery. *Eur Arch Otorhinolaryngol* 2017;274(02):837–844
 - 41 Hadad G, Bassagasteguy L, Carrau RL, et al. A novel reconstructive technique after endoscopic expanded endonasal approaches: vascular pedicle nasoseptal flap. *Laryngoscope* 2006;116(10):1882–1886
 - 42 Hoffmann TK, El Hindy N, Müller OM, et al. Vascularised local and free flaps in anterior skull base reconstruction. *Eur Arch Otorhinolaryngol* 2013;270(03):899–907
 - 43 Eldaly A, Magdy EA, Nour YA, Gaafar AH. Temporalis myofascial flap for primary cranial base reconstruction after tumor resection. *Skull Base* 2008;18(04):253–263
 - 44 McCall TD, Fufts DW, Schmidt RH. Use of resorbable collagen dural substitutes in the presence of cranial and spinal infections—report of 3 cases. *Surg Neurol* 2008;70(01):92–96; discussion 96–97
 - 45 Patel A, Groppo E. Management of temporal bone trauma. *Cranio-maxillofac Trauma Reconstr* 2010;3(02):105–113
 - 46 Kveton JF. Obliteration of mastoid and middle ear for severe trauma to the temporal bone. *Laryngoscope* 1987;97(12):1385–1387
 - 47 Mack KF, Kempf HG, Lenarz T. Patients with trauma-induced deafness—rehabilitation using a cochlear implant [Article in German]. *Wien Med Wochenschr* 1997;147(10):249–251
 - 48 Ulug T, Arif Ulubil S. Management of facial paralysis in temporal bone fractures: a prospective study analyzing 11 operated fractures. *Am J Otolaryngol* 2005;26(04):230–238
 - 49 do Nascimento Remigio AF, Salles AG, de Faria JC, Ferreira MC. Comparison of the efficacy of onabotulinumtoxinA and abobotulinumtoxinA at the 1: 3 conversion ratio for the treatment of asymmetry after long-term facial paralysis. *Plast Reconstr Surg* 2015;135(01):239–249
 - 50 May M. Facial reanimation after skull base trauma. *Am J Otol* 1985 (Suppl):62–67
 - 51 Flint PW, et al. *Cummings Otolaryngology: Head and Neck Surgery*. London: Elsevier Health Sciences; 2015 (p. 1 online resource)
 - 52 Sekhar LN, Schramm VL. *Tumors of the Cranial base: Diagnosis and Treatment*. Mount Kisco, New York, NY: Futura Publishers; 1987
 - 53 Snyderman CH, Janecka IP, Sekhar LN, Sen CN, Eibling DE. Anterior cranial base reconstruction: role of galeal and pericranial flaps. *Laryngoscope* 1990;100(06):607–614
 - 54 Raveh J, Vuillemin T, Sutter F. Subcranial management of 395 combined frontobasal-midface fractures. *Arch Otolaryngol Head Neck Surg* 1988;114(10):1114–1122
 - 55 Raveh J, Laedrach K, Speiser M, et al. The subcranial approach for fronto-orbital and anteroposterior skull-base tumors. *Arch Otolaryngol Head Neck Surg* 1993;119(04):385–393
 - 56 Kellman RM, Marentette L. The transglabellar/subcranial approach to the anterior skull base: a review of 72 cases. *Arch Otolaryngol Head Neck Surg* 2001;127(06):687–690
 - 57 Kellman RM, Goyal P, Rodziewicz GS. The transglabellar subcranial approach for nasal dermoids with intracranial extension. *Laryngoscope* 2004;114(08):1368–1372
 - 58 Figueiredo EG, Deshmukh P, Nakaji P, et al. The minipterional craniotomy: technical description and anatomic assessment. *Neurosurgery* 2007;61(05, Suppl 2):256–264; discussion 264–265
 - 59 Yaşargil MG, Teddy PJ, Roth P. Selective amygdalo-hippocampectomy. Operative anatomy and surgical technique. *Adv Tech Stand Neurosurg* 1985;12:93–123

- 60 Yaşargil MG, Krayenbühl N, Roth P, Hsu SP, Yaşargil DC. The selective amygdalohippocampectomy for intractable temporal limbic seizures. *J Neurosurg* 2010;112(01):168–185
- 61 Altay T, Couldwell WT. The frontotemporal (pterional) approach: an historical perspective. *Neurosurgery* 2012;71(02):481–491; discussion 491–492
- 62 Winn HR, Youmans JR. *Youmans Neurological Surgery*. London: Elsevier Health Sciences; 2011 (p. 1 online resource)
- 63 Yaşargil MG, Reichman MV, Kubik S. Preservation of the fronto-temporal branch of the facial nerve using the interfascial temporalis flap for pterional craniotomy. Technical article. *J Neurosurg* 1987;67(03):463–466
- 64 Figueiredo EG, Teixeira MJ, Spetzler RF, Preul MC. Clinical and surgical experience with the minipterional craniotomy. *Neurosurgery* 2014;75(03):E324–E325
- 65 Jane JA, Park TS, Pobereskin LH, Winn HR, Butler AB. The supraorbital approach: technical note. *Neurosurgery* 1982;11(04):537–542
- 66 Haines SJ, Marentette LJ, Wirtschafter JD. Extended fronto-orbital approaches to the anterior cranial base: variations on a theme. *Skull Base Surg* 1992;2(03):134–141
- 67 Kabil MS, Shahinian HK. Application of the supraorbital endoscopic approach to tumors of the anterior cranial base. *J Craniofac Surg* 2005;16(06):1070–1074; discussion 1075
- 68 Cheong EC, Chen CT, Chen YR. Endoscopic management of orbital floor fractures. *Facial Plast Surg* 2009;25(01):8–16
- 69 Chen HI, Bohman LE, Emery L, et al. Lateral transorbital endoscopic access to the hippocampus, amygdala, and entorhinal cortex: initial clinical experience. *ORL J Otorhinolaryngol Relat Spec* 2015;77(06):321–332
- 70 Abuzayed B, Tanriover N, Gazioglu N, Eraslan BS, Akar Z. Endoscopic endonasal approach to the orbital apex and medial orbital wall: anatomic study and clinical applications. *J Craniofac Surg* 2009;20(05):1594–1600
- 71 Chhabra N, Wu AW, Fay A, Metson R. Endoscopic resection of orbital hemangiomas. *Int Forum Allergy Rhinol* 2014;4(03):251–255
- 72 Stokken J, Gumber D, Antisdel J, Sindwani R. Endoscopic surgery of the orbital apex: Outcomes and emerging techniques. *Laryngoscope* 2016;126(01):20–24
- 73 Antisdel JL, Gumber D, Holmes J, Sindwani R. Management of sinonasal complications after endoscopic orbital decompression for Graves' orbitopathy. *Laryngoscope* 2013;123(09):2094–2098
- 74 Moe KS, Bergeron CM, Ellenbogen RG. Transorbital neuroendoscopic surgery. *Neurosurgery* 2010;67(3, Suppl Operative):ons16–ons28
- 75 Moe KS, Kim LJ, Bergeron CM. Transorbital endoscopic repair of cerebrospinal fluid leaks. *Laryngoscope* 2011;121(01):13–30
- 76 Ciporen JN, Moe KS, Ramanathan D, et al. Multiportal endoscopic approaches to the central skull base: a cadaveric study. *World Neurosurg* 2010;73(06):705–712
- 77 Bly RA, Ramakrishna R, Ferreira M, Moe KS. Lateral transorbital neuroendoscopic approach to the lateral cavernous sinus. *J Neurol Surg B Skull Base* 2014;75(01):11–17