Intracerebral Hematoma Following Evacuation of Chronic Subdural Hematoma: A Case Report and Review of Literature

Sumit Bansal[1] Ashok K. Mahapatra[1]

[1]Department of Neurosurgery, All India Institute of Medical Sciences, Bhubaneswar, Orissa, India

Address for correspondence Dr. Sumit Bansal, MCh Room No. 419, Department of Neurosurgery, All India Institute of Medical Sciences, Bhubaneswar, Orissa 751019, India (e-mail: drsumitbansal@gmail.com).

Indian J Neurotrauma 2017;14:88–90

Abstract

Intracerebral hematoma is an unusual complication following surgical evacuation of chronic subdural hematoma. We report a case of 61-year-old patient operated at our department for a right-sided chronic subdural hematoma (CSDH), who presented with mild headache and left hemiparesis (4/5, Medical Research Council [MRC] grade). Postoperatively, the patient developed a small hematoma in ipsilateral frontal lobe. Serial computed tomography (CT) of the head showed progressive increase in size of hematoma with development of motor dysphasia. Frontal hematoma was evacuated by craniotomy and the patient improved in motor dysphasia. We emphasize the rarity of this complication and discuss the pathogenesis as well as management of this condition.

Keywords
- chronic subdural hematoma
- intracerebral hematoma
- surgery
- good outcome

Introduction

The evacuation of chronic subdural hematoma (CSDH) is known to have a good prognosis with a relatively simple surgical intervention.[1] Spontaneous intracerebral hematoma (SICH) following the evacuation of CSDH is an uncommon but potentially lethal complication occurring with a reported incidence of 0.5 to 4%.[2,3] Herein, we report a case of SICH complicating the evacuation of CSDH.

Case Report

A 61-year-old right-handed man, known hypertensive (poorly controlled on medications), presented to us with history a road traffic accident. Initial computed tomography (CT) of the head showed inter-hemispheric acute subdural hematoma without any other intracranial hematoma or hydrocephalus (►**Fig. 1A**). He was managed conservatively. During follow-up in outpatient department, he complained of mild headache and left-sided weakness. Repeat CT of the head showed right-sided chronic subdural hematoma with significant midline shift (►**Fig. 1B**). He was conscious, oriented (Glasgow coma scale [GCS] = 15/15) with left hemiparesis (4/5, Medical Research Council [MRC] grade) with left-hand grip weakness (~60% of normal). His blood pressure (BP) was 140/90 mm Hg on admission. Coagulation profile was normal.

Burr hole evacuation of chronic subdural hematoma under local anesthesia was undertaken. Altered blood came under pressure, and irrigation of subdural space was done with saline till effluent was clear. Intraoperatively, the patient was stable except once when he moved his head because of cough causing sudden rise in BP up to 180/120 mm Hg. There was oozing from frontal burr hole site, which was controlled by saline irrigation. Brain came to surface after evacuation of chronic subdural hematoma. CT of the head after 4 hours showed good evacuation of chronic SDH (►**Fig. 2A**) but simultaneous appearance of a small intracerebral hematoma (3 cm in maximum diameter) in ipsilateral frontal lobe away from frontal burr hole site (►**Fig. 2B**). Patient was neurologically stable so he was clinically followed and kept in the intensive care unit (ICU). Repeat CT of the head after 24 hours showed increase in hematoma size (up to 4 cm in maximum diameter) but patient was clinically unchanged (►**Fig. 2C**). After 36 hours, patient developed motor dysphasia without any other new deficit. Repeat CT of the head showed significant increase in hematoma size (up to 5 cm in maximum

received
June 29, 2015
accepted
October 14, 2015

Copyright ©2017 Neurotrauma Society of India

DOI https://doi.org/10.1055/s-0037-1608690.
ISSN 0973-0508.

This document was downloaded for personal use only. Unauthorized distribution is strictly prohibited.

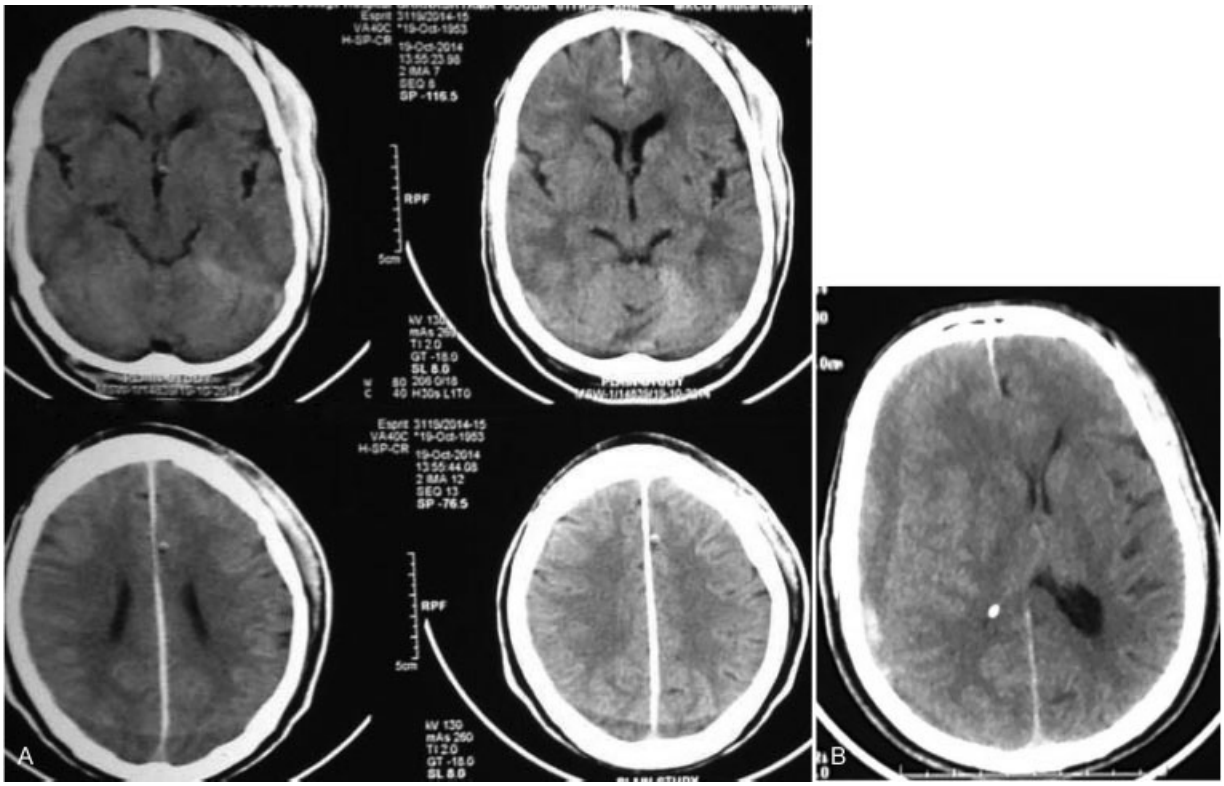

Fig. 1 (**A**) Initial CT of the head showing inter-hemispheric hematoma. (**B**) Follow-up CT of the head showing development of right chronic subdural hematoma with significant midline shift. CT, computed tomography.

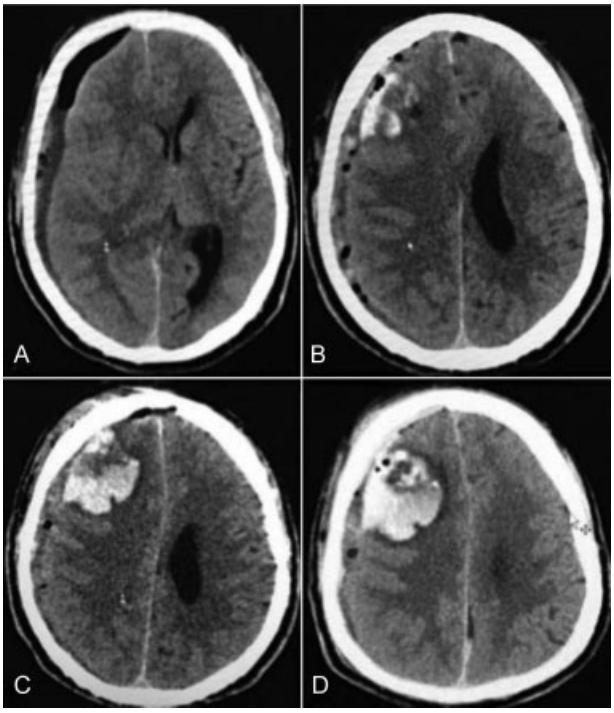

Fig. 2 (**A**) CT of the head done after 4 hours of burr hole evacuation of right chronic subdural hematoma showing evacuation of subdural hematoma (**B**) with appearance of ipsilateral frontal hematoma away from burr hole site. (**C**) CT of the head done after 24 hours showing enlarging right frontal hematoma. (**D**) CT of the head done after 36 hours showing significant increase in hematoma size with midline shift. CT, computed tomography.

diameter) in right frontal lobe with increased midline shift (►**Fig. 2D**). Emergency craniotomy and hematoma evacuation was done. Intraoperatively, brain was full on dural opening. Hematoma was present in right frontal lobe far away from existing frontal burr hole. Brain was lax on dural closure. Bone flap was replaced. Postoperative CT of the head showed good evacuation of hematoma with reduced midline shift (►**Fig. 3**). The patient improved in motor dysphasia following surgery.

Discussion

CSDH is a common neurosurgical condition, whose incidence is likely to rise with the aging population. Although surgical treatment for CSDH is often simple and successful, unexpected complications may occasionally impair the postoperative course. These include cerebral edema, tension pneumocephalus, recurrence of hematoma, seizure, failure of the brain to reexpand, and intracerebral hemorrhage (ICH).[3,4]

Epidural, subdural, intracerebral, and intracerebellar hemorrhages have been described after surgical evacuation of CSDH.[5] Symptoms caused by the ICH appeared either immediately[6] or several days after surgery,[7] with life-threatening consequences in roughly 50% of patients.[5]

Choi et al[8] in their paper emphasized three different mechanisms for development of SICH with CSDH. First and the most common type is SICH occurring during or after evacuation of CSDH.[9] Diapedesis through increased permeability of

This document was downloaded for personal use only. Unauthorized distribution is strictly prohibited.

Fig. 3 CT of the head done after craniotomy and evacuation of right frontal hematoma showing evacuation of hematoma with reduced midline shift. CT, computed tomography.

parenchymal vessels due to the sudden increase in cerebral blood flow combined with defective cerebral autoregulation following the existence of a longstanding extracerebral mass is the most likely mechanism.[4] Second, Hirakawa et al[10] reported another type of CSDH with direct intracerebral rupture forming an acute subcortical hematoma. They speculated that fresh bleeding into the adjacent brain parenchyma directly resulted in subcortical ICH through a rupture of the inner membrane of CSDH. Rupture of a leptomeningeal artery adjacent to the dura with extravasation into both the brain parenchyma and subdural space is the most likely explanation.

Finally, remote or adjacent SICH from CSDH could also occur due to arterial hypertension, which might develop by CSDH progression with a mass effect on brainstem or increased intracranial pressure (IICP). Three possible mechanisms could be assumed: (1) SICH may have independently occurred during CSDH development and progression by each other mechanisms; (2) if the brainstem was compressed by the mass effect of CSDH, BP may have increased as a result of local ischemia on the brainstem and SICH may have developed due to elevated BP; and (3) IICP caused by increasing CSDH decreased cerebral perfusion pressure, and reduction in cerebral perfusion pressure gradually resulted in an increase in BP.[11] Pathogenesis of development of ipsilateral frontal hematoma away from burr hole site in our case along with sudden arterial hypertension during surgery may be explained by the aforementioned mechanism.

Conclusion

ICH is a possible complication when performing surgical evacuation of CSDH. It can be avoided with slow and gradual decompression of hematoma along with selective use of general anesthesia instead of local anesthesia, because the former can provide better control perioperatively. Preoperative control of BP cannot be overemphasized.

Funding
None.

Conflict of Interest
None.

References

1 McKissock W, Richardson A, Bloom WH. Subdural hematoma: a review of 389 cases. Lancet 1960; 1: 1365–1369
2 Ogasawara K, Koshu K, Yoshimoto T, Ogawa A. Transient hyperemia immediately after rapid decompression of chronic subdural hematoma. Neurosurgery 1999;45(03):484–488, discussion 488–489
3 Rohde V, Graf G, Hassler W. Complications of burr-hole craniostomy and closed-system drainage for chronic subdural hematomas: a retrospective analysis of 376 patients. Neurosurg Rev 2002;25(1-2):89–94
4 d'Avella D, De Blasi F, Rotilio A, Pensabene V, Pandolfo N. Intracerebral hematoma following evacuation of chronic subdural hematomas. Report of two cases. J Neurosurg 1986;65 (05):710–712
5 Sato M, Nakano M, Asari J, Watanabe K. Intracerebral haemorrhage during surgery for chronic subdural haematoma. J Clin Neurosci 2007;14 (01):81–83
6 Missori P, Salvati M, Polli FM, Conserva V, Delfini R Intraparenchymal haemorrhage after evacuation of chronic subdural haematoma. Report of three cases and review of the literature Br J Neurosurg 2002;16 (01):63–66
7 Kotwica Z, Brzeziński J. Chronic subdural haematoma treated by burr holes and closed system drainage: personal experience in 131 patients Br J Neurosurg 1991;5(05):461-465
8 Choi KY, Lee JK, Jang JW, Seo BR, Kim TS, Kim JH. Spontaneous Intracerebral Hemorrhage Occurring during Progression of Chronic Subdural Hematoma. J Kor Neurotraumatol Soc 2011; 7 (01):43–46
9 Akhaddar A, Ajja A, Elmostarchid B, Boucetta M. Combined epidural and intracerebral hematomas after evacuation of bilateral chronic subdural hematoma. Neurochirurgie 2008;54 (06):728–730
10 Hirakawa T, Tanaka A, Yoshinaga S, Ohkawa M, Tomonaga M. Calcified chronic subdural hematoma with intracerebral rupture forming a subcortical hematoma. A case report. Surg Neurol 1989;32 (01):51–55
11 Marmarou A, Shulman K, Rosende RM. A nonlinear analysis of the cerebrospinal fluid system and intracranial pressure dynamics. J Neurosurg 1978;48(03):332–344

This document was downloaded for personal use only. Unauthorized distribution is strictly prohibited.