

Epidemiological Features of Patients with Subdural Hygroma in a Prospective Case Series

Aspectos epidemiológicos de pacientes com higroma subdural numa série de casos prospectiva

Pedro Tadao Hamamoto Filho¹ Tamara Maria Ribeiro Pereira¹ Marco Antonio Zanini¹

¹ Faculdade de Medicina de Botucatu (FMB), Universidade Estadual Paulista (UNESP) Botucatu, SP, Brazil

Arq Bras Neurocir 2017;36:203–206.

Address for correspondence Pedro Tadao Hamamoto Filho, MD, MSc, Faculdade de Medicina de Botucatu, Universidade Estadual Paulista (UNESP), Botucatu, São Paulo, Brazil (e-mail: phamamoto@fmb.unesp.br).

Abstract

Subdural hygroma is an accumulation of a cerebrospinal fluid-like fluid in the subdural space. It is a common epiphenomenon after a traumatic brain injury (TBI), but it may also occur after brain surgeries. A total of 17 patients in a prospective case series with subdural hygromas were analyzed. A male predominance (82.4%) was found. The mean age was 58.6 years. Traumatic brain injury was the main mechanism (76.5%); however, other mechanisms, such as post-craniotomy (17.6%), post-chronic subdural hematoma drainage (5.9%), and post-ventricle shunt (5.9%), were also observed. Incidental findings were diagnosed in 11.8% of the cases (mainly in elderly patients). Four patients required subdural shunt (23.5%)—all of them had TBI. Small subdural effusions were present in 35.5% of the cases. The mean time from admission to diagnosis was 6.1 days. The majority of the cases must have involved lesions of the dura–arachnoid interface since TBIs were the main causes of hygroma. The findings of incidental hygroma in elderly patients and its development after a ventricle shunt suggest that brain atrophy also plays a significant role in subdural hygroma formation.

Keywords

- ▶ subdural hygroma
- ▶ traumatic brain injury
- ▶ cerebrospinal fluid
- ▶ hydrocephalus

Resumo

Higroma subdural é o acúmulo de fluido semelhante ao líquido no espaço subdural. É um epifenômeno comum após traumatismos crânio-encefálicos, mas também pode ocorrer após neurocirurgias. Nesta série de casos prospectiva, analisamos 17 pacientes com higroma subdural. Houve uma predominância no sexo masculino (82,4%). A idade média dos pacientes foi de 58,6 anos. Traumatismo crânio-encefálico foi o principal mecanismo (76,5%); porém outros mecanismos contribuíram para o surgimento de higroma: pós-craniotomia (17,6%), pós-drenagem de hematoma subdural crônico (5,9%), e pós-derivação ventricular (5,9%). Higromas incidentais foram diagnosticados em 11,8% dos casos (principalmente em pacientes mais velhos). Quatro pacientes necessitaram de derivação subdural (23,5%)—todos eles tiveram como mecanismo o

received
August 4, 2017
accepted
October 17, 2017
published online
November 28, 2017

DOI <https://doi.org/10.1055/s-0037-1608884>.
ISSN 0103-5355.

Copyright © 2017 by Thieme Revinter Publicações Ltda, Rio de Janeiro, Brazil

License terms



Palavras-chave

- ▶ higroma subdural
- ▶ traumatismo crânio-encefálico
- ▶ líquido
- ▶ hidrocefalia

traumatismo crânio-encefálico. Pequenas efusões subdurais estavam presentes em 35,5% dos casos. O tempo médio da admissão para o diagnóstico foi de 6,1 dias. A maioria dos casos deve ter tido lesão da interface duro-aracnoide, já que o traumatismo craniano foi a principal causa de higroma. Os achados de higromas incidentais em pacientes mais velhos e o seu desenvolvimento após derivações ventriculares sugerem que a atrofia cerebral desempenha também um papel significativo na formação de higromas subdurais.

Introduction

Subdural hygroma is an accumulation of cerebrospinal fluid (CSF)-like fluid in the subdural space. Macroscopically, it may be either limpid or xanthochromic and slightly dyed with blood, but on a conventional computed tomography (CT), it appears very similar to CSF.¹ The following terms have been used as synonyms: subdural effusion, benign subdural collection, subdural hygroma, traumatic serous meningitis, external hydrocephalus, and obstructive extraventricular hydrocephalus. This heterogeneity of nomenclature reflects the controversies regarding the pathophysiologic mechanisms that lead to its occurrence.^{2,3}

Subdural hygroma is a common epiphenomenon after a traumatic brain injury (TBI), but it may also occur after brain surgeries, with different treatment implications. Some authors believe that a traumatic lesion tears the dura-arachnoid interface, creating a valve mechanism that forces and traps the CSF into the subdural space.⁴ A CSF circulation imbalance should be also accounted for the hygroma origin.⁵ In fact, various mechanisms may be responsible for hygromas in different ages, considering the age predisposition to have an enlarged subdural space.⁶

In children, the pathophysiology of subdural collections is different, and some confusion exists regarding childhood subarachnoid space enlargement conditions and benign subdural effusion.⁷ This is the reason why subdural collections in children are considered differently from those of the adults.

Most subdural hygromas are managed conservatively. When necessary, surgical treatment of hygroma is performed, depending on the cause. A simple external or peritoneal drainage would generally be advocated in symptomatic cases or in cases with progressive mass effect on CT scans. A ventricular shunt may be needed when there is a CSF circulation imbalance.⁸

In this study, we describe the epidemiological features of subdural hygroma in a prospective case series.

Methods

This is an observational prospective study conducted at a hospital in the city of Botucatu, SP, Brazil. Patients who had a subdural hygroma diagnosed using the CT scan were enrolled from January of 2011 to December of 2013. The board of local Ethics Committee on Research approved the project (CEP 3747/2010), and the patients or family members signed the informed consent.

All patients from our neurosurgery department who presented a subdural hygroma of any etiology during their follow-

up period were included. Patients with other subdural collections (such as chronic or acute subdural hematomas and subdural empyemas) were excluded. Children were also excluded.

Data were collected focusing on sex, age, trauma mechanism or other neurosurgical intervention, presence of small subdural effusion and subarachnoid hemorrhage and score on the Glasgow coma scale (GCS) upon admission, time interval from admission to diagnosis of hygroma, and hygroma treatment.

Results

A total of 17 patients were included; 14 of them were males (82.4%) and 3 females (17.6%). The mean age was 58.6 ± 20.1 years. Traumatic brain injury (TBI) was the main mechanism for the occurrence of subdural hygroma (13 patients, 76.5%). Among these patients, five (38.5%) had been involved in a road traffic accident, four (30.8%) had fallen from height, and the other four had been beaten. A small subdural effusion on the initial CT scan was observed in 6 out of 13 patients with TBI (46.2%) and subarachnoid hemorrhage was observed in 4 (30.8%). Two of the TBI patients (15.5%) had transient hydrocephalus.

Three patients (17.6%) had the hygroma after a craniotomy, which had been performed due to other reasons (brain tumor resection, aneurysm clipping, and decompressive craniectomy). One patient (5.9%) developed the hygroma after a chronic subdural hematoma drainage, and another patient, after a ventricle-peritoneal shunt.

In our case series, two patients (11.8%) were diagnosed with hygroma through a CT scan performed to investigate other diseases, and hence considered as incidental hygromas. ▶ **Fig. 1** shows the distribution of cases based on the mechanism of the subdural hygroma.

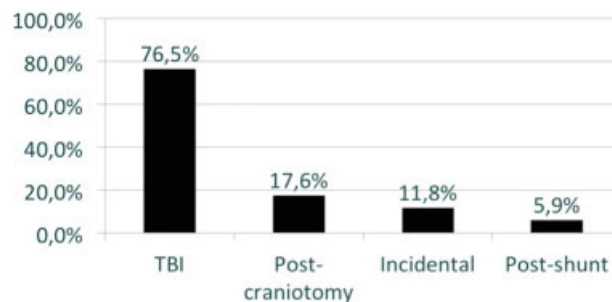


Fig. 1 Distribution of patients with subdural hygroma based on the developmental mechanism ($n = 17$).

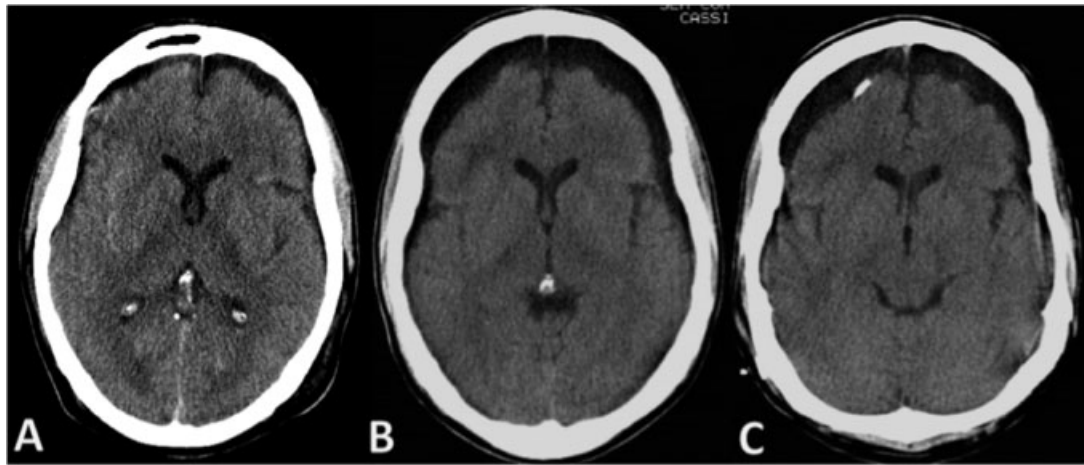


Fig. 2 Evolution from a small subdural effusion (A) to a subdural hygroma (B); after treating with a ventricle–peritoneal shunt (C).

The mean time interval between hospital admission and diagnosis of subdural hygroma was 6.1 ± 5.6 days. When considering patients with TBI only, the mean interval was still the same. The mean GCS score upon admission was $9.8 (\pm 3.8)$.

Four patients (23.5%) required a subdural-peritoneal shunt because of deteriorating clinical condition and enlarged hygroma in subsequent CT scans. All of these patients were from the TBI group and were victims of road traffic accidents. ► **Fig. 2** shows a case that needed a shunt.

Discussion

Subdural hygroma is a common epiphenomenon after head injuries. Despite the benign course of the majority of cases, some patients may present symptoms from mass effect and intracranial hypertension.

The first description that explains the occurrence of hygroma was provided by Naffziger, in 1924. He believed that CSF crosses a breach in the arachnoid membrane.⁹ This mechanism explains quite well the hygromas following head injuries and neurosurgeries, which were the main causes for hygroma in the present series.

However, we also observed incidental hygromas, especially in elderly patients. A possible explanation for this finding is the understanding that subdural hygromas and hematomas belong to the same spectrum of disease¹⁰ in which brain atrophy plays a key role.^{11,12} Previously, subdural hygromas have been observed to change their density on CT or magnetic resonance imaging (MRI) scans depending on the time, appearing as a subdural hematoma, and to finally resolve spontaneously.¹³

In patients with head injury, the recognition of early small subdural effusion on initial CT exam should alert to the risk of evolution to a subdural hygroma.¹⁴ In our series, it took ~ 6 days from the initial CT to the new CT with a definite diagnosis of subdural hygroma. Among the four patients who required a surgical intervention in our series, two had a small subdural effusion on initial CT. Therefore, clinical condition deteriorations in TBI patients can also be explained by a hygroma with mass effect.

Another concern in managing subdural hygromas is the concomitance of associated hydrocephalus. Zanini et al proposed a pathogenesis-based classification that considers the presence of mass effect and hydrocephalus.⁵ In patients with subdural hygroma and hydrocephalus, there is an association of CSF influx to the subdural space and CSF absorption impairment.⁵ Although Zanini et al did not observe hygromas with mass effect and hydrocephalus, Tsuang et al did; they then proposed that hygromas with mass effect and hydrocephalus should have drainage and a ventricle shunt.⁸

If identifying hydrocephalus is pivotal in managing subdural hygromas, a variety of case series has shown progressive extra-axial collections associated with craniectomy, even with treated hydrocephalus. In fact, subdural hygromas are also common after a decompressive craniectomy.¹⁵ In patients who underwent craniectomy, were treated for hydrocephalus, and had progressive extra-axial collection, early cranioplasty is the optimal choice for the collection resolution.¹⁶

Conclusions

Based on the analysis of our series, lesions in the dura–arachnoid interface may have accounted for the majority of cases, as TBI and craniotomy were the main causes of the subdural hygromas. The findings of incidental hygromas in elderly patients and their development after performing a ventricular shunt demonstrate that brain atrophy also plays a significant role in the subdural hygroma formation.

Conflict of Interest

The authors declare no conflict of interest.

References

- 1 Lee KS, Bae WK, Park YT, Yun IG. The pathogenesis and fate of traumatic subdural hygroma. *Br J Neurosurg* 1994;8(05):551–558
- 2 Stone JL, Lang RGR, Sugar O, Moody RA. Traumatic subdural hygroma. *Neurosurgery* 1981;8(05):542–550

- 3 Yoshimoto Y, Wakai S, Hamano M. External hydrocephalus after aneurysm surgery: paradoxical response to ventricular shunting. *J Neurosurg* 1998;88(03):485-489
- 4 Lee KS. The pathogenesis and clinical significance of traumatic subdural hygroma. *Brain Inj* 1998;12(07):595-603
- 5 Zanini MA, de Lima Resende LA, de Souza Faleiros AT, Gabarra RC. Traumatic subdural hygromas: proposed pathogenesis based classification. *J Trauma* 2008;64(03):705-713
- 6 Liu Y, Gong J, Li F, Wang H, Zhu S, Wu C. Traumatic subdural hydroma: clinical characteristics and classification. *Injury* 2009;40(09):968-972
- 7 Caldarelli M, Di Rocco C, Romani R. Surgical treatment of chronic subdural hygromas in infants and children. *Acta Neurochir (Wien)* 2002;144(06):581-588, discussion 588
- 8 Tsuang FY, Huang AP, Tsai YH, et al. Treatment of patients with traumatic subdural effusion and concomitant hydrocephalus. *J Neurosurg* 2012;116(03):558-565
- 9 Nafziger HC. Subdural fluid accumulations following head injury. *JAMA* 1924;82(22):1751-1752
- 10 Feng JF, Jiang JY, Bao YH, Liang YM, Pan YH. Traumatic subdural effusion evolves into chronic subdural hematoma: two stages of the same inflammatory reaction? *Med Hypotheses* 2008;70(06):1147-1149
- 11 Park CK, Choi KH, Kim MC, Kang JK, Choi CR. Spontaneous evolution of posttraumatic subdural hygroma into chronic subdural haematoma. *Acta Neurochir (Wien)* 1994;127(1-2):41-47
- 12 Kristof RA, Grimm JM, Stoffel-Wagner B. Cerebrospinal fluid leakage into the subdural space: possible influence on the pathogenesis and recurrence frequency of chronic subdural hematoma and subdural hygroma. *J Neurosurg* 2008;108(02):275-280
- 13 Zanini MA, Resende LA, Freitas CC, Yamashita S. Traumatic subdural hygroma: five cases with changed density and spontaneous resolution. *Arq Neuropsiquiatr* 2007;65(01):68-72
- 14 Ishibashi A, Yokokura Y, Miyagi J. Clinical analysis of nineteen patients with traumatic subdural hygromas. *Kurume Med J* 1994;41(02):81-85
- 15 Yuan Q, Wu X, Yu J, et al. Subdural hygroma following decompressive craniectomy or non-decompressive craniectomy in patients with traumatic brain injury: Clinical features and risk factors. *Brain Inj* 2015;29(7-8):971-980
- 16 Nalbach SV, Ropper AE, Dunn IF, Gormley WB. Craniectomy-associated Progressive Extra-Axial Collections with Treated Hydrocephalus (CAPECTH): redefining a common complication of decompressive craniectomy. *J Clin Neurosci* 2012;19(09):1222-1227