

Delayed Metallic Embolization of a Cor-Knot Fastener

H. Edward Garrett Jr.¹

¹Cardiovascular Surgery Clinic, Memphis, Tennessee, United States
Thorac Cardiovasc Surg Rep 2017;6:e40–e41.

Address for correspondence H. Edward Garrett, Jr., MD,
Cardiovascular Surgery Clinic, 6029 Walnut Grove Rd. Suite 401,
Memphis, Tennessee 38120, United States
(e-mail: egarretmd@cvsclinic.com; amber@cvsclinic.com).

Abstract

Keywords

- ▶ surgical equipment
- ▶ mitral valve surgery
- ▶ imaging
- ▶ neurology/neurologic

Background The Cor-Knot device is a titanium fastener which is widely used in cardiac valve procedures. Adverse events associated with use of the device have been rare.

Case Description A patient underwent robotic mitral valve repair using the Cor-Knot fastener. Five years later, he suffered a cerebral vascular accident secondary to embolization of a metallic foreign body. He had had no other medical procedures which could account for a source of metallic embolization.

Conclusion Long-term surveillance after use of the Cor-Knot fastener is limited. Metallic embolization may be possible with this device and warrants awareness within the medical community.

Introduction

The Cor-Knot device (LSI Solutions, Victor, New York, United States) is a titanium fastener designed to secure 2–0 polyester and 2–0 and 3–0 polypropylene suture, replacing a surgical knot. Rapidity and ease of use have led to widespread adoption in cardiac valve and annuloplasty ring implants, especially during limited access procedures. The titanium fastener has been used without risk of producing inflammation. In addition, performance of a magnetic resonance image (MRI) is not prohibited under standard testing conditions (static magnetic field of three Tesla or less with a whole body averaged specific absorption rate [SAR] value of 3 W/kg).

To date, there have been no reported cases of delayed titanium embolization associated with use of this device. A case of titanium embolization is now reported almost 5 years after use of the device for mitral valve repair. The patient has given consent for his data to be used in this case report.

Case Description

A 41-year-old male with no significant past medical history presented with increasing dyspnea on exertion. He was found

to have severe mitral valve insufficiency secondary to a ruptured posterior leaflet chord with well-preserved left ventricular function and normal coronary anatomy. In June of 2011, he underwent robotic mitral valve repair with triangular resection of the involved redundant P1 segment and implantation of a 32-mm Edwards Physio II annuloplasty ring (Edwards Lifesciences, Irvine, California, United States). An intraoperative transesophageal echocardiogram revealed mild residual mitral valve insufficiency with no stenosis.

He did well postoperatively. Two years later in August of 2013, he fell while playing tennis and was treated in the emergency room for a scalp laceration. A computerized tomography (CT) scan of his head at that time was normal.

In March of 2016, the patient suddenly developed transient diplopia followed 11 days later by aphasia and left facial weakness. CT angiography (CTA) and MRI scans revealed a right middle cerebral infarct associated with a metallic foreign body in the deep frontal parietal area near the corona radiata (▶ **Figs. 1** and **2**). Tissue plasminogen activator (tPA) was administered systemically with complete resolution of his neurological deficits the following day. A transesophageal echocardiogram revealed no mitral valve insufficiency and

received
August 29, 2017
accepted after revision
October 23, 2017

DOI <https://doi.org/10.1055/s-0037-1612613>.
ISSN 2194-7635.

© 2017 Georg Thieme Verlag KG
Stuttgart · New York

License terms



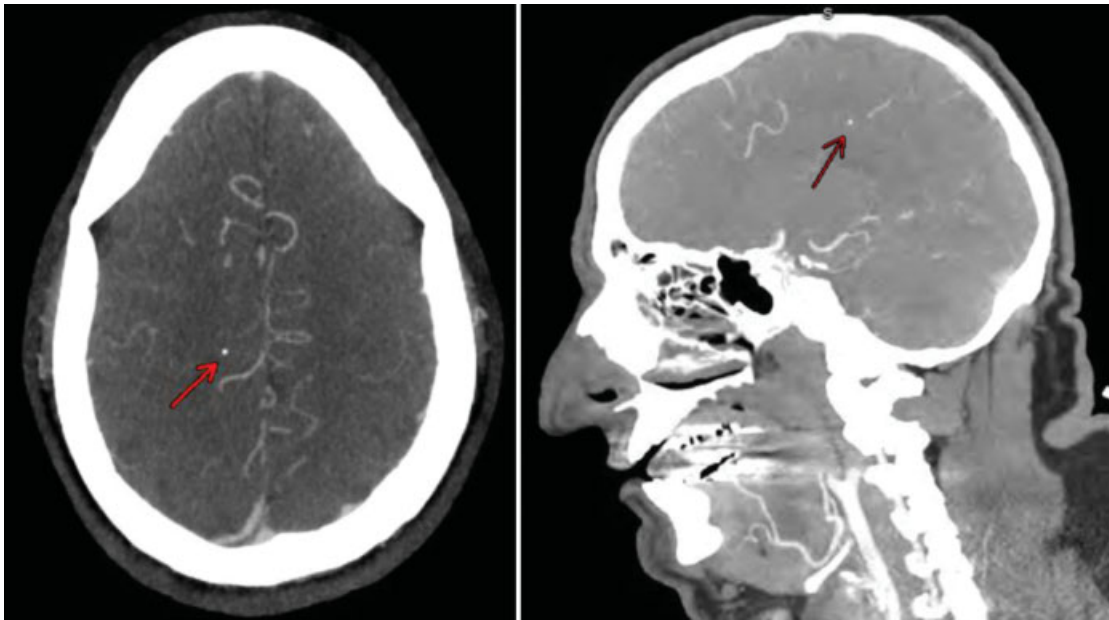


Fig. 1 Computed tomography angiography (CTA) scan demonstrating the intracerebral metallic foreign body.

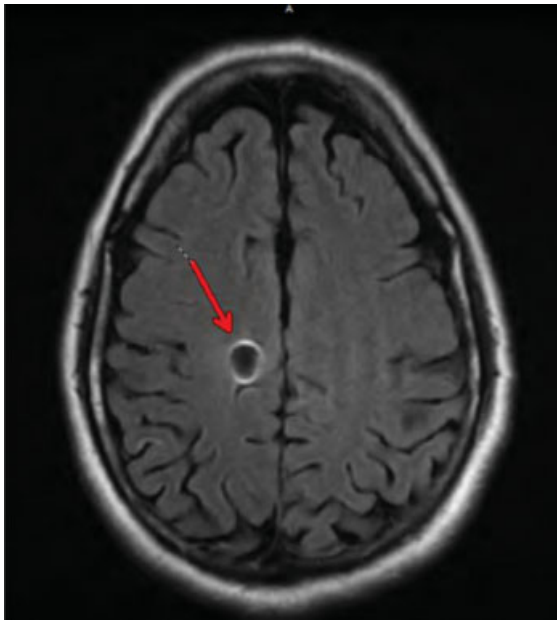


Fig. 2 Magnetic resonance image (MRI) scan demonstrating the focal cerebral infarction at the site of the metallic embolization.

moderate mitral valve stenosis. Close inspection of the annuloplasty ring suggested that all titanium clips were present.

Discussion

The patient had no medical encounters or surgical procedures other than the mitral valve repair and the scalp laceration. Presumably, tPA limited the thrombus adjacent to the foreign body, minimizing the area of ischemia. He has had no subsequent neurological symptoms 18 months after the initial event. The only possible source of embolization was the titanium Cor-Knot fastener. The risk of subsequent future embolization is unknown.

Long-term surveillance of the Cor-Knot fastener is limited. There have been reports of erosion of prosthetic valve leaflets which came into contact with the titanium fasteners that required subsequent redo valve replacement.^{1,2} According to the company, there have been no previous reports of embolization of the titanium fasteners.

Given the widespread use and limited long-term surveillance of this device, the medical community should be aware of the possibility of metallic embolization.

References

- 1 Balan R, Mogilansky C, Larsen AL, Massoudy P. Severe aortic regurgitation after implantation of a sutureless valve prosthesis using an automatic knot fastener device. *Interact Cardiovasc Thorac Surg* 2017;25(01):153–154
- 2 Brescia AA, Bolling SF, Patel HJ. Valvular regurgitation after implantation of prosthesis secured with Cor-Knot automated fasteners. *Ann Thorac Surg* 2017;103(06):e491–e492