

# Overutilization of Cross-Sectional Imaging in the Lower Extremity Trauma Setting

Clinton Protack, MD, PhD<sup>1</sup> Brian Wengerter, MD, PhD<sup>1</sup> Raymond A. Jean, MD<sup>1</sup> Shirley Liu, MD<sup>1</sup>  
Hamid Mojbibian, MD<sup>2</sup> Bauer Sumpio, MD, PhD<sup>3</sup> Alan Dardik, MD, PhD<sup>3</sup> Adrian A. Maung, MD<sup>1,\*</sup>  
Young Erben, MD<sup>3,\*</sup>

<sup>1</sup>Department of Surgery, Yale University, New Haven, Connecticut

<sup>2</sup>Section of Vascular and Interventional Radiology, Yale University, New Haven, Connecticut

<sup>3</sup>Section of Vascular and Endovascular Surgery, Yale University, New Haven, Connecticut

Address for correspondence Young Erben, MD, Section of Vascular Surgery, Yale University, 330 Cedar Street, New Haven, CT 06510 (e-mail: Young.Erben@Yale.edu).

Int J Angiol 2018;27:23–28.

## Abstract

**Objective** In an era of managed care and cost savings, we are faced with the question of whether another test is necessary to confirm our clinical suspicion. We hypothesized that a few computed tomography angiographies (CTAs) are necessary to identify lower extremity vascular injuries (LEVIs). We reviewed our trauma center's experience in the management of LEVI.

**Methods** A retrospective review of all trauma patients between 2012 and 2016 was performed. Four-thousand nine-hundred fourteen trauma patients were evaluated with 46 suspected LEVIs (either with cross-sectional imaging and/or operative exploration). Our primary end point was the utility of CTA in the setting of LEVI. Receiver operating characteristic curves were performed to evaluate sensitivity and specificity for hard signs and CTA identification of LEVI.

**Results** Out of the initial 46 patients with suspected LEVI, 41 (89%) had a CTA as part of their initial evaluation. Sixteen patients (35%) with LEVI were due to penetrating injuries. Seventeen patients (41%) had a CTA with LEVI. Fourteen of the 17 patients (82%) with injury on CTA also had hard signs of LEVI. Twenty-two patients (48%) underwent operative exploration: three had no LEVI that was previously believed to be on CTA; operative exploration identified two missed injuries not observed on CTA. Seven of forty-one (17%) CTA studies provided a false assumption of the presence/absence of LEVI. One patient (2%) underwent operative exploration and was found to have LEVI in the absence of hard signs, but with a CTA identifying LEVI.

**Conclusion** The recognition of hard signs through physical examination is paramount to assessing need for operative intervention with suspicion of LEVI. CTA should be reserved as an adjunct for identification of LEVI in patients with high clinical suspicion and absence of hard signs, rather than utilizing CTA as an initial screening tool for the identification of LEVI.

## Keywords

- ▶ trauma
- ▶ lower extremity
- ▶ artery
- ▶ ultrasound
- ▶ repair
- ▶ femoral artery
- ▶ ankle-brachial index

\* Both authors contributed equally to this manuscript.

The evaluation and management of patients with lower extremity vascular injury (LEVI) have continued to evolve over the past decades. Previously, lower extremity injuries that were concerning for vascular injury warranted automatic operative exploration and intervention.<sup>1</sup> However, a study conducted by Frykberg et al<sup>2</sup> demonstrated that physical examination findings should dictate the need for further vascular imaging rather than routine angiography. In the absence of hard signs of vascular injury, the decision to proceed with conventional angiography relied upon an abnormal ankle-brachial index (ABI). More recently, the use of conventional angiography as the imaging modality of choice has been called into question due to the availability of computed tomography angiography (CTA). Current guidelines by the Eastern Association for the Surgery of Trauma (EAST)<sup>3</sup> recommend CTA as the initial imaging modality to evaluate for LEVI due to its widespread availability, noninvasiveness, association with lower costs, and a sensitivity and specificity comparable to conventional angiography.<sup>4-6</sup>

We hypothesize the widespread availability and ease of obtaining CTA for trauma patients also undergoing concomitant CT evaluation to rule out hollow viscus organ injury have led to the overuse of CTA for patients with suspected LEVI.

## Methods

### Study Design

The study was approved by the Yale University School of Medicine Human Investigative Committee (No. 1606017934) and patient informed consent was not obtained since The Yale-New Haven Hospital Level I trauma center's registry stores completely de-identified data. This registry was queried to identify patients with concern for LEVI evaluated between January 2012 and December 2016. For each patient, the demographics, mechanism of injury, Glasgow Comas Scale (GCS), Injury Severity Score (ISS), evidence of hard signs, evidence of soft signs, imaging evaluation, and operative intervention were identified. Hard signs of vascular injury were defined as active hemorrhage, rapidly expanding hematoma, absent pulses, or palpable thrill/bruit. Soft signs of vascular injury were defined as nonexpanding hematoma, history of arterial bleeding, proximity of the wound to an artery, and a neurologic deficit.<sup>3</sup>

The inclusion criteria included age over 16 years, blunt or penetrating traumatic injury to the lower extremity distal to the inguinal ligament, and evaluation with CTA using a standard protocol in a 64-slices scanner (General Electric, Fairfield, CT) or operative exploration. During the study period, 4,914 patients presented as trauma activations. Of these trauma activations, 613 had lower extremity injuries prompting CT evaluation of which 41 were CTA investigations.

### Statistical Analysis

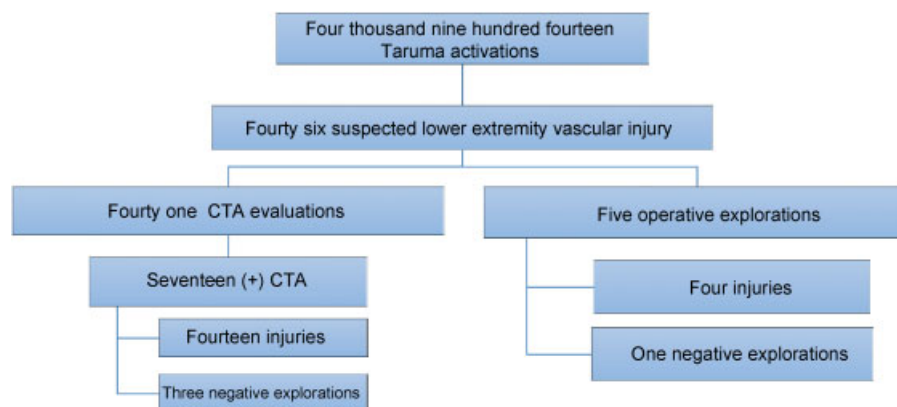
The positive predictive value (PPV) and negative predictive value (NPV) were calculated for all patients undergoing CTA evaluation and operative exploration. Receiver operating characteristic (ROC) curves were used to calculate the sensitivity and specificity of patients presenting with LEVI, who initially presented with hard signs of vascular injury or were explored due to a positive CTA finding of vascular injury. Patient demographics and injury characteristics are listed as mean  $\pm$  standard deviation or as a percentage, as appropriate.

## Results

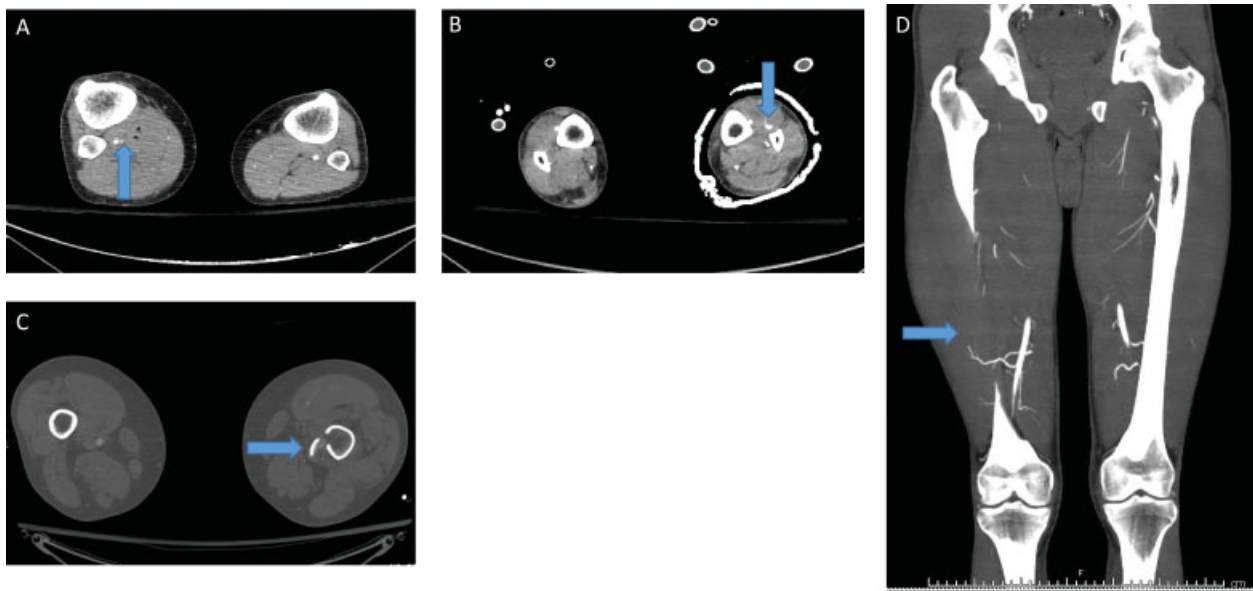
During the 5-year study period, 4,914 trauma activations occurred at our level 1 trauma center. Forty-six (1%) of the total trauma activations included patients who had a suspected LEVI. Of the 46 patients, the majority underwent CTA as the primary imaging modality (41 patients, 89%). The remaining five patients either underwent immediate exploration in the operating room after evaluation in the trauma bay or conventional angiography (**► Fig. 1**).

The mean age was 41 years with a range of 19 to 82 years of age. Eighty-five percent of the patients were male sex. The ratio of penetrating to blunt mechanisms was 35% to 65%, respectively. The mean ISS was 14.4. The mean GCS upon initial evaluation was 13.7.

Fifty-four percent of the patients had documented palpable pulses identified during the initial physical examination in the trauma bay. Fifty percent of patients had hard signs of vascular injury present in the trauma bay. Sixty-five percent of the patients had ABIs performed and documented. Of those patients with ABIs performed, the mean ABI was 0.81 with 40% of these patients with ABIs  $\geq 0.9$ .



**Fig. 1** Summary of treated cohort during our 5-year study period ( $n = 46$ ). CTA, computed tomography angiography.



**Fig. 2** Examples of computed tomography angiography (CTA) of several trauma patients: (A–C) false positive patients (blue arrow) demonstrating a blush without true arterial injury intraoperatively; (D) false negative patient demonstrating no injury; however, this patient required operative ligation of hemorrhaging branches of the profunda artery.

Seventeen of the forty-one (41%) patients who underwent a CTA were found to have a vascular injury on imaging (► **Fig. 2**). The following injuries were identified: four superficial femoral artery (SFA) lacerations/transections, four deep femoral artery lacerations/transections, three popliteal artery (PA) lacerations/transections, three tibial artery (TA) occlusions, two PA occlusions, one SFA occlusion, SFA dissection, TA laceration, plantar artery laceration, femoral vein laceration, popliteal vein laceration, and TA vasospasm, respectively (► **Table 1**).

Twenty-two patients (48%) ultimately underwent operative exploration. Four patients were found to have no evidence of LEVI. Of these four patients with no injury identified, three of these patients had CTAs done preoperatively that identified a vascular injury and two had hard signs present. Eighteen patients were found to have LEVI after operative exploration. The proce-

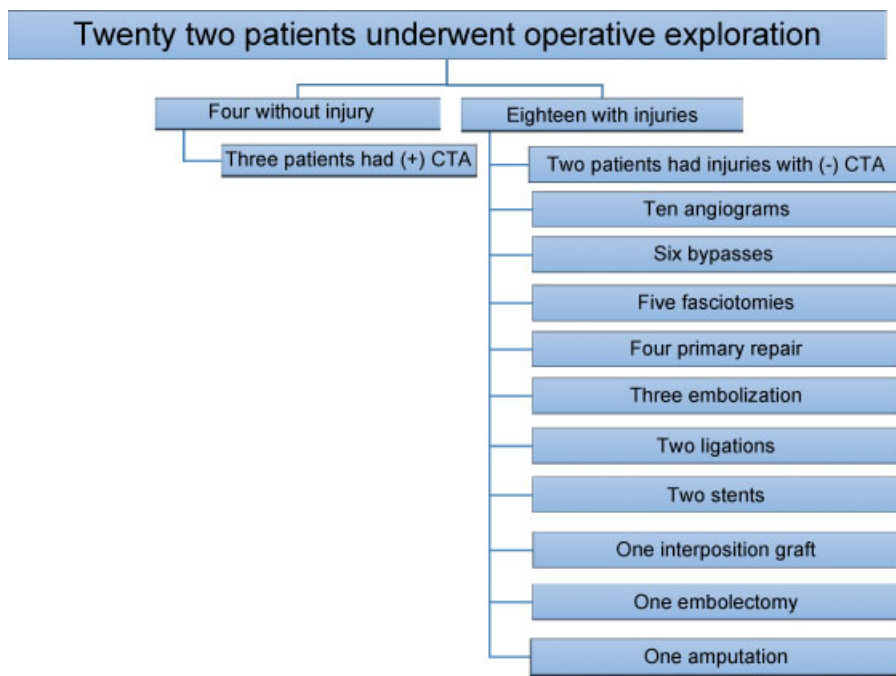
dures performed were conventional angiography (10 patients), bypass with vein (6 patients), fasciotomies (5 patients), primary repair (4 patients), embolization (3 patients), vessel ligation (2 patients), stent placement (2 patients), interposition graft (1 patient), embolectomy (1 patient), and amputation (1 patient) (► **Fig. 3**). Two patients who were found to have vascular injuries after operative exploration initially had CTAs preoperatively that were unable to identify a present injury. The reason these patients were explored was due to worsening symptoms and initial soft signs of vascular injury.

Of the 41 patients who underwent CTA evaluation, 2 patients were identified as having injuries on CTA, but deemed clinically occult and did not undergo subsequent operative exploration and/or intervention. Two additional patients had no evidence of injury on CTA, but were later identified as having an injury during operative exploration due to worsening symptoms. Three patients were ultimately found to have no vascular injury present, when CTA had initially identified an injury preoperatively. On the basis of the ROC curve, the sensitivity and specificity for CTA in identifying vascular injuries were 86% and 81% with an area under the curve of 0.744 (95% CI, 0.611–0.877) (► **Fig. 4A**). The PPV and NPV for CTA were 71% and 85%, respectively.

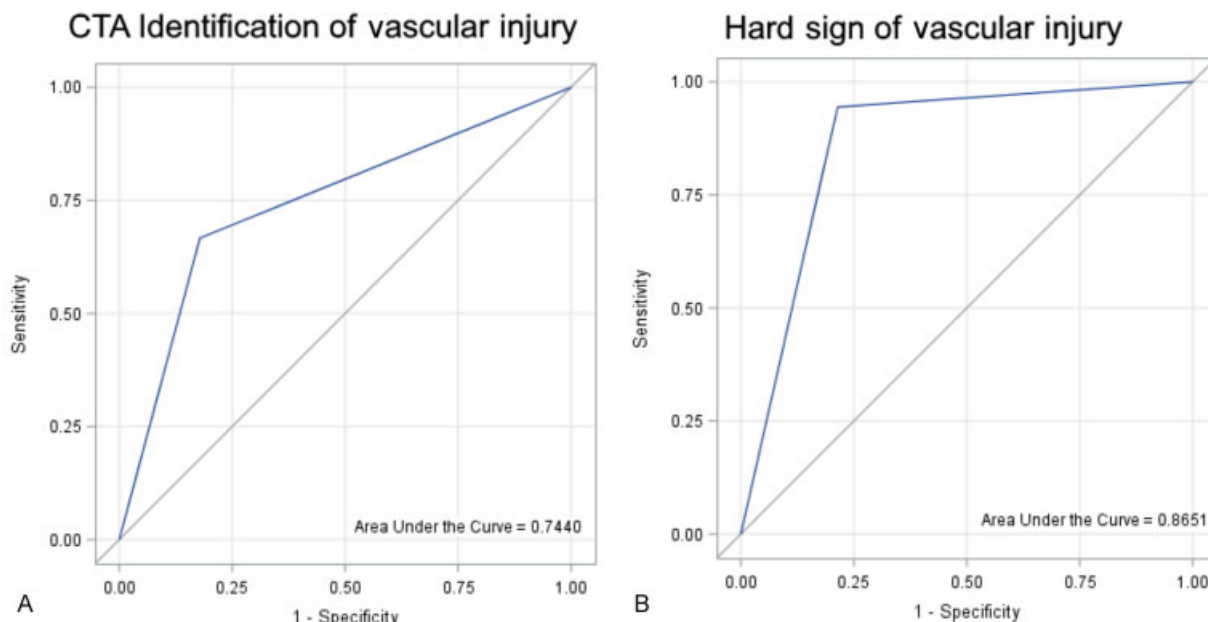
For all forty-six patients, twenty-three (50%) had hard signs present in the trauma bay. Of the 18 patients, which were ultimately found to have a vascular injury, 17 (94%) had the presence of hard signs on initial examination. Six patients with hard signs were subsequently not found to have a vascular injury. On the basis of the ROC curve, the sensitivity and specificity for CTA in identifying vascular injuries were 94% and 79% with an area under the curve of 0.865 (95% CI, 0.771–0.960) (► **Fig. 4B**). The PPV and NPV were 74% and 96%, respectively.

**Table 1** Summary of all lower extremity injuries

Vessel injured	Type of injury			
	Laceration/ Transection	Dissection	Occlusion	Vasospasm
Superficial femoral artery	4	1	1	
Deep femoral artery	4			
Popliteal artery	3		2	
Tibial artery	1		1	1
Plantar artery	1			
Femoral vein	1			
Popliteal vein	1			
<b>Total</b>	<b>15</b>	<b>1</b>	<b>4</b>	<b>1</b>



**Fig. 3** Summary of operative interventions ( $n = 22$ ). CTA, computed tomography angiography.



**Fig. 4** Receiver-operative curves (ROCs) for (A) computed tomography angiography (CTA) identification of vascular injury demonstrating a higher sensitivity utilizing hard signs of vascular injury instead of CTA for the identification of vascular injury; (B) hard signs of vascular injury.

**Discussion**

In this study, we present our single-center civilian level I trauma experience with the accuracy and utilization rates of CTA for suspected LEVI. Suspected LEVI constitutes only 1% of our center’s total trauma activations. As with most trauma populations, our patients were predominantly male (85%) with a mean age of 41 years and sustained a ratio of blunt to penetrating mechanisms of 1.9:1.

Most guidelines and recommendations regarding utilization of adjunctive imaging stem from predominantly trauma

populations due to penetrating mechanisms. Of just our patients with penetrating mechanisms of injury, 15 (94%) underwent CTA. The distribution of presence or absence of hard signs was evenly distributed at 56% and 47%, respectively. All nine patients (100%) with hard signs present and had a penetrating mechanism were found to have an injury. Of the seven patients without hard signs present in the trauma bay, only one patient (14%) was identified as having an injury. The patient had active extravasation from a common femoral artery branch that was successfully resolved with embolization. CTA missed two patients in this group who had injuries

later identified in the operating room. The PPV and NPV for hard signs in identifying LEVI in patients with penetrating mechanisms were 100% and 86%, respectively. The PPV and NPV for CTA in identifying LEVI in patients with penetrating mechanisms were 80% and 67%, respectively.

Patient sustaining blunt mechanisms of injury was found to have differing patterns of injury identification. Of just the patients sustaining blunt trauma, 26 (87%) underwent CTA evaluation. As with penetrating mechanism patients, we found an equal breakdown for those with or without hard signs presents at 47% and 53%, respectively. However, in marked contrast to those with penetrating injuries, only 57% of the blunt mechanism patients with hard signs present were eventually found to have a vascular injury present (compared with 100% for the penetrating mechanism population). No blunt mechanism patients were subsequently found to have a vascular injury in the absence of hard signs. The PPV and NPV for CTA in the blunt mechanism population were 50% and 83%, respectively. The PPV and NPV for hard signs in identifying LEVI were 57% and 100%, respectively.

Our findings overall suggest a widespread overuse of CTA in the evaluation of suspected LEVI. For patients with penetrating injuries, the presence of hard signs had a 100% predictive value for identifying vascular injury, thus obviating the need for CTA evaluation in this group. Patients sustaining blunt injury patterns without the presence of hard signs can and should be observed without additional need of CTA imaging as the absence of hard signs had a 100% NPV. The PPV for CTA and hard signs was much lower for patients with blunt mechanisms of injury at 50% and 57%, respectively. However, of the six patients with blunt injuries and an absence of hard signs, four had injuries identified on CTA and two had no injuries identified on CTA. Furthermore, these patients while observed during hospitalization and progression of symptoms could easily undergo conventional angiography to assure the location of the injury and aid in operative planning.<sup>7</sup>

Two of the patients with a positive CTA finding and a negative operative exploration and one patient with a negative CTA and a positive operative exploration had a vessel injury overcalled in the tibial region and a vessel injury overcalled in a small branch of the profunda artery (→ Fig. 2A, B, and D). One could presume that small vessel injuries are difficult to identify correctly on CTA due to either vessels spasms and/or imaging artifacts and therefore, rather careful observation is warranted in the absence of hard signs of vascular injury. Similar findings have been demonstrated in the blunt injury of the vertebral artery and hence, caution is recommended in the interpretation of small caliber vessels.<sup>8</sup>

Our study comes at an opportune time, in the current age of health care reform to achieve both cost-effectiveness for best medical management.<sup>9</sup> We were able to demonstrate with our study that limiting expenditures to mitigate the exploding cost of health care does not affect the quality of patient care. Similar findings have also been demonstrated by Jordaen et al, who assert that a poor physical examination at the time of presentation should not be replaced by ordering an extremity CTA to rule out vascular injury.<sup>10</sup> Furthermore, the trauma population is young and we can save this patient group from the

potential negative effects of radiation exposure at an early age.<sup>11</sup> Therefore, Montorfano et al<sup>12</sup> have explored options to spare patients from excessive radiation exposure by using duplex ultrasound in the same form as a FAST protocol for diagnosis of traumatic LEVIs.<sup>12</sup>

The limitations of our retrospective study are twofold. First, we have a small sample size that precludes generalization of our findings to all level I trauma centers, and second, there is a relative delay in the evaluation of patients with LEVI from the vascular surgery service standpoint, since this subspecialty is not in-house during overnight call. Therefore, the inconsistency in obtaining CTA of the lower extremities in all patients suspected of LEVI (41 CTA vs 5 operative explorations without cross-sectional imaging). This highlights the importance of educating our colleagues in trauma, orthopedics, and emergency medicine of most LEVI situations requiring simply an accurate and complete physical examination and that a cross-sectional imaging study rarely adds any additional information in the absence of hard signs of vascular injury.

## Conclusion

The recognition of hard signs via a thorough physical examination is paramount to assessing the need for operative intervention in the suspicion of LEVIs. CTA should be reserved as an adjunct for identifying vascular injuries in those patients with high clinical suspicion in the absence of hard signs, rather than utilizing CTA as an initial screening tool for identification of vascular injury.

### Declaration

No competing interests declared.

### Note

Presented at the 45th Annual Symposium of the Society of Clinical Vascular Surgery on March 20th, 2017.

## References

- 1 Perry MO, Thal ER, Shires GT. Management of arterial injuries. *Ann Surg* 1971;173(03):403–408
- 2 Frykberg ER, Dennis JW, Bishop K, Laneve L, Alexander RH. The reliability of physical examination in the evaluation of penetrating extremity trauma for vascular injury: results at one year. *J Trauma* 1991;31(04):502–511
- 3 Fox N, Rajani RR, Bokhari F, et al; Eastern Association for the Surgery of Trauma. Evaluation and management of penetrating lower extremity arterial trauma: an Eastern Association for the Surgery of Trauma practice management guideline. *J Trauma Acute Care Surg* 2012;73(05, Suppl 4):S315–S320
- 4 Seamon MJ, Smoger D, Torres DM, et al. A prospective validation of a current practice: the detection of extremity vascular injury with CT angiography. *J Trauma* 2009;67(02):238–243, discussion 243–244
- 5 Inaba K, Branco BC, Reddy S, et al. Prospective evaluation of multidetector computed tomography for extremity vascular trauma. *J Trauma* 2011;70(04):808–815
- 6 Inaba K, Potzman J, Munera F, et al. Multi-slice CT angiography for arterial evaluation in the injured lower extremity. *J Trauma* 2006; 60(03):502–506, discussion 506–507

- 7 Johnson ON, Fox CJ, O'Donnell S, et al. Arteriography in the delayed evaluation of wartime extremity injuries. *Vasc Endovascular Surg* 2007;41(03):217-224
- 8 Malhotra AK, Camacho M, Ivatury RR, et al. Computed tomographic angiography for the diagnosis of blunt carotid/vertebral artery injury: a note of caution. *Ann Surg* 2007;246(04):632-642, discussion 642-643
- 9 Jha AK. How would the next president ensure competitiveness in the health care marketplace? *JAMA* 2017;317(02):125-126
- 10 Jordaan P, Roche S, Maqungo S. Computerised tomographic angiography (CTA) in extremity trauma - a level one hospital experience. *S Afr J Surg* 2016;54(04):11-16
- 11 Boice JD Jr. Radiation epidemiology and recent paediatric computed tomography studies. *Ann ICRP* 2015;44(1, Suppl):236-248
- 12 Montorfano MA, Montorfano LM, Perez Quirante F, Rodríguez F, Vera L, Neri L. The FAST D protocol: a simple method to rule out traumatic vascular injuries of the lower extremities. *Crit Ultrasound J* 2017;9(01):8