

Case Report

Dual Chronic Ossified Epidural Hematomas Presented with Seizures 23 Years after Head Injury in an Adult Male: Case Report and Literature Review

Vivek Mahesh Agrawal¹ Pramod Janardhan Giri¹

¹Department of Neurosurgery, Government Medical College and Super Specialty Hospital, Nagpur, Maharashtra, India

Address for correspondence: Vivek Mahesh Agrawal, MS, MCh, Flat no. 404, Maharishi Sandipani Appts, Shastri Layout, Khamla, Nagpur 440025, Maharashtra, India (e-mail: vivekmaheshagrawal21@gmail.com).

Indian J Neurotrauma 2018;15:41–42

Abstract

Keywords

- ▶ ossified epidural hematoma
- ▶ seizures
- ▶ craniotomy

The authors report a rare case of dual chronic ossified epidural hematomas (EDHs) in a 35-year-old man with complaint of seizures after 23 years of head injury. Ossified EDH is a rare entity, and it commonly presents in pediatric age group. Presenting symptoms include headache and very rarely seizures. Asymptomatic cases may produce symptoms after decades; hence, regular follow-up is required. Treatment includes craniotomy or conservative management.

Introduction

Chronic ossified epidural hematoma (EDH) is a rare entity. Only few case reports have been published, and dual extradural hematomas account for 2 to 25% of all the EDHs.^{1–13} Most reported cases are in pediatric age group.^{2,4,5,9} Ossified EDH may remain asymptomatic or present with headache or very rarely with seizures. However, the exact mechanism is not known. Treatment includes craniotomy or conservative management. The authors report a rare case of dual chronic ossified EDH in a 35-year-old man who presented 23 years following head injury with complaint of seizures that we managed conservatively.

Case History

A 35-year-old man presented with complaint of headache and recent-onset seizures. On examination, the patient was conscious, oriented without any neurologic deficit. At the institution, computed tomographic (CT) scan of the brain was done, which revealed dual ossified double-outline EDH (▶ **Figs. 1, 2**). One in right frontal region and another in left parietal region. When further history was taken, the patient remembered history of fall from tree at the age of 12 years. He was conscious and oriented at that time. We advised electroencephalogram (EEG) and surgery for the

same, but the patient refused due to financial condition, and finally we started anticonvulsants with regular follow-up.

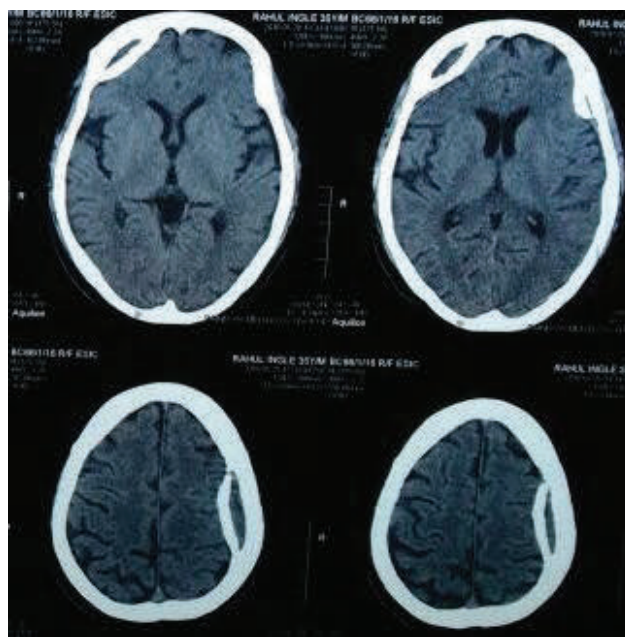


Fig. 1 Axial view (calcification present in right frontal and left parietal regions).

received

August 24, 2017

accepted

November 20, 2017

published online

August 10, 2018

Copyright ©2017 Neurotrauma Society of India

DOI <https://doi.org/10.1055/s-0037-1616032>.

ISSN 0973-0508

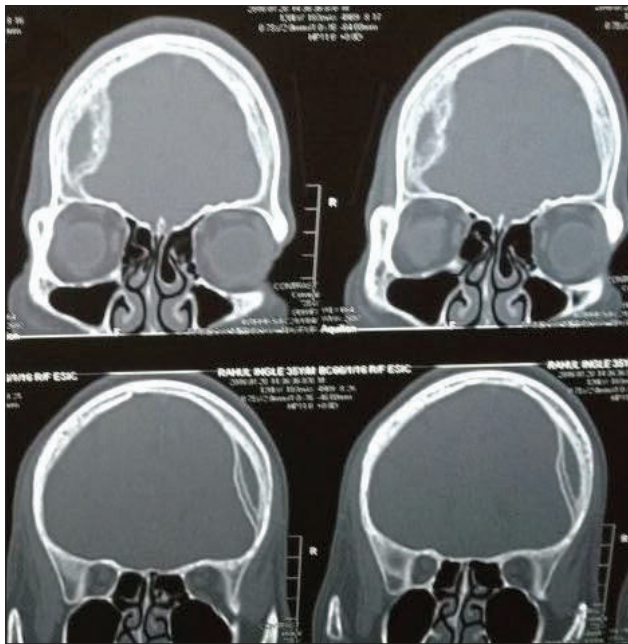


Fig. 2 Coronal view (bony window showing calcification).

Discussion

Dual extradural hematomas account for 2 to 25% of all the EDHs.¹ Most EDHs occur on opposite side due to coup and counter-coup injury, but calcification is a very rare phenomenon and is reported in literature mainly as isolated cases.²⁻⁹ EDH mostly occurs because of trauma, but it can be iatrogenic.²⁻⁴ Ossification is mainly reported in pediatric age group.^{2,4,5,9} Very few cases reported ossified EDH in adults.^{7,10,11} Ossification was identified at variety of intervals from 10 to 50 years.^{5,7,11} In this case, dual ossified EDH were detected after 23 years of head injury, which is the third longest duration.^{7,11} The ossification of EDH was found on the dural side of the hematoma in all case. Very few cases have reported ossified EDH with seizures.^{6,9,12} This case is unique as the patient complains of seizures after 23 years of head injury.

The exact mechanism is poorly understood, but it may be attributed to damage to vascularized tissues such as the bone and dura that provokes inflammation. According to Nagane et al, a fibroblast layer emerges adjacent to the dura at as early as 4 days, developing sinusoidal channel layers in 2 weeks, and then fibrous layers and subsequently forming connective tissue layers.⁷ The outer layer of the dura is derived from endosteum of the inner surface of the calvarium. Stimulation by hematoma could actively evoke extradural ossification between the capsule and the dura.^{6,13} Rapid ossification may prevent absorption or resolution of the hematoma, and thus it can cause neurologic deficits secondary to mass effect.¹³ Radiologically, ossified EDHs characteristically have double-outlined contour on plain skull X-ray and CT scan, which represents bone formation and calcification of hematoma capsule adjacent to the dura. For asymptomatic ossified EDH, close follow-up is recommended. Whether

to start anticonvulsants prophylactically or not has not been cleared in the literature. For ossified EDH causing mass effect or neurologic deterioration, urgent surgical evacuation is recommended.

Conclusion

Dual ossified EDH is rare. Ossification occurs mainly in pediatric age group. Asymptomatic ossified EDH may present with symptoms after decades; hence, it is advisable to have close follow-up with anticonvulsants. Clinicians should go for radiologic investigation even for subtle signs and symptoms, and if ossified EDH causes mass effect or presented with neurologic deterioration, immediate craniotomy is recommended.

Funding

None.

Conflict of Interest

None.

References

- Huda MF, Mohanty S, Sharma V, Tiwari Y, Choudhary A, Singh VP. Double extradural hematoma: an analysis of 46 cases. *Neurol India* 2004;52(4):450-452
- Bayri Y, Ulas AK, Aykan U, Kaya AH, Dalgıncı A. Iatrogenic chronic calcified/ossified epidural hematoma: case report. *J Nervous Sys Surgery* 2009;2(2):91-94
- Whisler WW, Voris HC. Ossified epidural hematoma following posterior fossa exploration. Report of a case. *J Neurosurg* 1965;23(2):214-216
- Trivedi A, Hiran S. Calcified epidural hematoma in pediatric age group: a report of two cases. *J Neurosci Rural Pract* 2010;1(2):89-91
- Erdogan B, Sen O, Bal N, Cekinmez M, Altınors N. Rapidly calcifying and ossifying epidural hematoma. *Pediatr Neurosurg* 2003;39(4):208-211
- Mathuriya SN, Kak VK, Banerjee AK. Ossified epidural haematoma. Report of two cases. *Clin Neurol Neurosurg* 1989;91(3):269-272
- Nagane M, Oyama H, Shibui S, Nomura K, Nakanishi Y, Kamiya M. Ossified and calcified epidural hematoma incidentally found 40 years after head injury: case report. *Surg Neurol* 1994;42(1):65-69
- Yu DK, Heo DH, Cho SM, Cho YJ. Rapidly calcified epidural hematoma in a neonate. *J Korean Neurosurg Soc* 2008; 44(2):98-100
- Han SR. Conservative management of a rapidly calcifying epidural hematoma in a young male patient. *Interdisciplinary Neurosurgery* 2015;2(4):183-185
- Nitta T, Hatashita S, Koga, N, Sugimura, J, Sakakibara, T, Takagi, S. A case of calcified epidural hematoma. Article in Japanese]. *Jpn J Clin Radiol* 1984;29:603-605
- Cambria S, Marra GA, Di Perri R, Bramanti P. Ossified epidural hematoma. Report of a case with epilepsy. *J Neurosurg Sci* 1985;29(3):285-288
- Iwakuma T, Brunngraber CV. Extradural ossification following an extradural hematoma. Case report. *J Neurosurg* 1974;41(1):104-106
- Kawata Y, Kunimoto M, Sako K, et al. [Ossified epidural hematomas: report of two cases] [in Japanese] *No Shinkei Geka* 1994;22(1):51-54