

The Posterior Transpetrosal Approach in a Case of Large Retrochiasmatic Craniopharyngioma: Operative Video and Technical Nuances

Moujahed Labidi^{1,2} Kentaro Watanabe¹ Marie-Pier Loit¹ Shunya Hanakita¹ Sébastien Froelich^{1,3}

¹Department of Neurosurgery, Hôpital Lariboisière, Paris, France

²Division of Neurosurgery, Centre Hospitalier de l'Université de Montréal, Montréal, Québec, Canada

³Paris VII-Diderot University, Paris, France

Address for correspondence Moujahed Labidi, MD, FRCSC, Department of Neurosurgery, Hôpital Lariboisière, Assistance Publique-Hôpitaux de Paris 2, Rue Ambroise Paré, Paris, France (e-mail: Moujahed.l@gmail.com).

J Neurol Surg B 2018;79(suppl S2):S205–S207.

Abstract

Objectives To discuss the use of the posterior petrosal approach for the resection of a retrochiasmatic craniopharyngioma.

Design Operative video.

Results In this case video, the authors discuss the surgical management of a large craniopharyngioma, presenting with mass effect on the third ventricle and optic apparatus. A first surgical stage, through an endoscopic endonasal transtuberular approach, allowed satisfactory decompression of the optic chiasma and nerves in preparation for adjuvant therapy. However, accelerated growth of the tumor, with renewed visual deficits and mass effect on the hypothalamus and third ventricle, warranted a supplementary resection. A posterior transpetrosal^{1,2} (also called “retro-labyrinthine transtentorial”) was performed to obtain a better exposure of the tumor and the surrounding anatomy (floor and walls of the third ventricle, perforating vessels, optic nerves, etc.)³. Nuances of technique and surgical pearls related to the posterior transpetrosal are discussed and illustrated in this operative video, including the posterior mobilization of the transverse–sigmoid sinuses junction, preservation of the venous anatomy during the tentorial incision, identification and preservation of the floor of the third ventricle during tumor resection, and a careful multilayer closure.

Conclusion Retrochiasmatic craniopharyngiomas are difficult to reach tumors that often require skull base approaches, either endoscopic endonasal or transcranial. The posterior transpetrosal approach is an important part of the surgical armamentarium to safely resect these complex tumors.

The link to the video can be found at: https://youtu.be/2MyGLJ_v1kl.

Keywords

- ▶ craniopharyngioma
- ▶ transtuberular approach
- ▶ petrosal approach
- ▶ endoscopic assistance
- ▶ skull base



www.thieme.com/skullbasevideos

www.thieme.com/jnlsvideos

received
October 20, 2017
accepted
November 29, 2017
published online
January 16, 2018

DOI <https://doi.org/10.1055/s-0037-1620252>.
ISSN 2193-6331.

© 2018 Georg Thieme Verlag KG
Stuttgart · New York

License terms



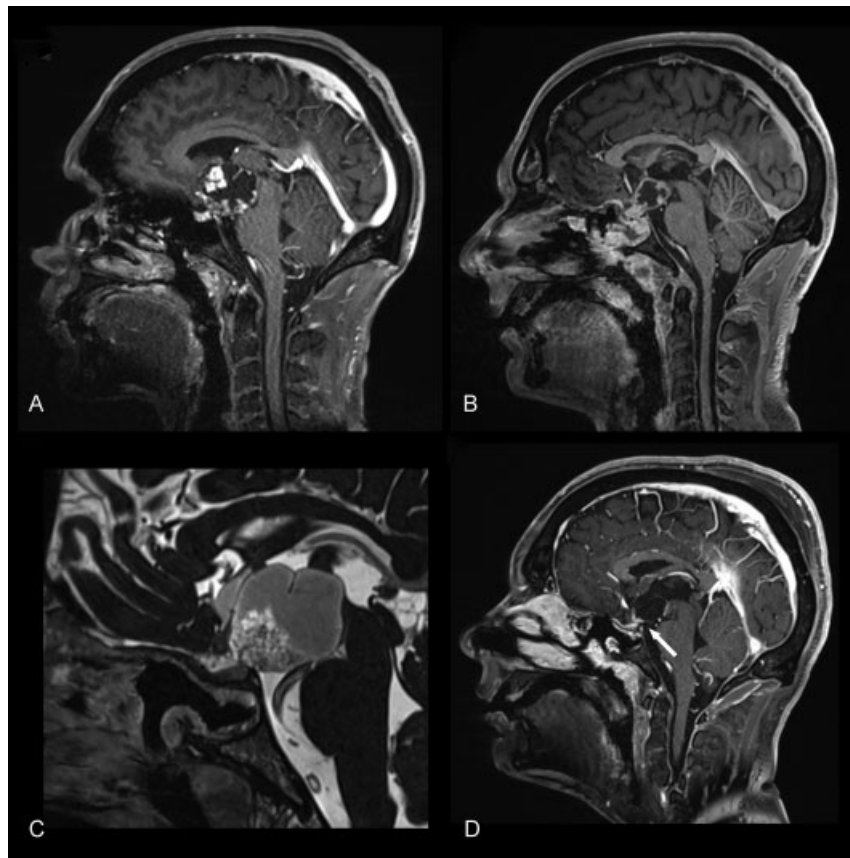


Fig. 1 Preoperative and postoperative imaging. Sagittal gadolinium-enhanced T1 preoperative (A) and (B) postoperative images of the endoscopic transtubercular approach for a large retrochiasmatic craniopharyngioma. Preoperative sagittal CISS image (C) and postoperative sagittal gadolinium-enhanced T1 (D) of the posterior transpetrosal approach.

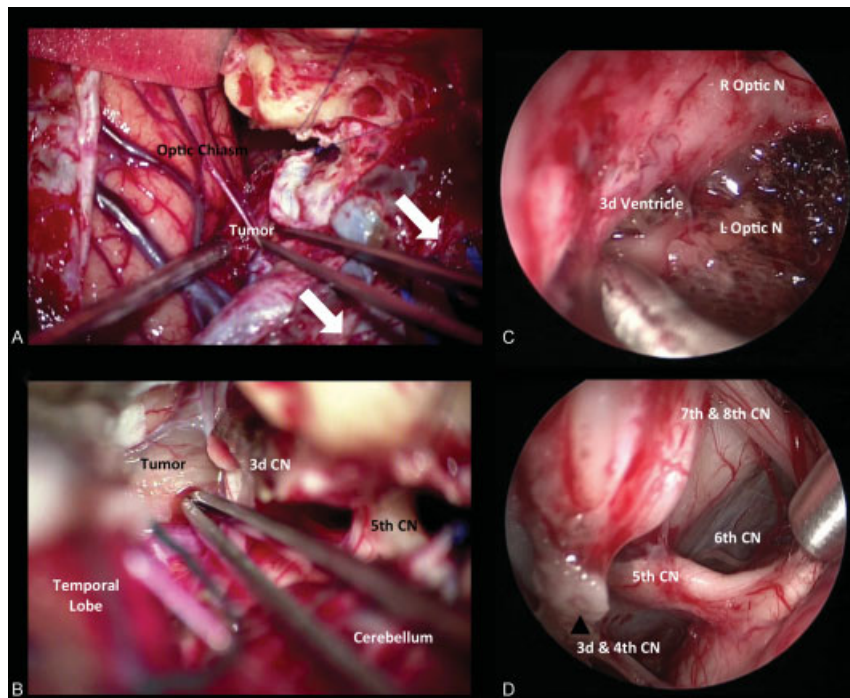


Fig. 2 Intraoperative images. (A) In posterior transpetrosal approach, posterior mobilization of the transverse–sigmoid junction opens up the surgical corridor between the temporal lobe and posterior fossa (white arrows). (B) Initial dissection of the arachnoid of the interpeduncular fossa and exposure of the tumor. Endoscopic assistance allows detailed inspection of the surgical bed (C) and a better appreciation of the surrounding neurovascular anatomy (D). CN, cranial nerve; L optic N, left optic nerve; R optic N, right optic nerve.

Funding

Local funds.

Conflict of Interest

None.

References

- 1 Al-Mefty O, Ayoubi S, Kadri PAS. The petrosal approach for the total removal of giant retrochiasmatic craniopharyngiomas in children. *J Neurosurg* 2007;106(2, Suppl)87–92
- 2 Al-Mefty O, Ayoubi S, Kadri PAS. The petrosal approach for the resection of retrochiasmatic craniopharyngiomas. *Neurosurgery* 2008;62(05, Suppl 2):ONS331–ONS335, discussion ONS335–ONS336
- 3 Pascual JM, Prieto R, Carrasco R, Barrios L. Displacement of mammillary bodies by craniopharyngiomas involving the third ventricle: surgical-MRI correlation and use in topographical diagnosis. *J Neurosurg* 2013;119(02):381–405