

# Endoscopic Endonasal Approach to a Suprasellar Craniopharyngioma

Alexandre B. Todeschini<sup>1</sup> Alaa S. Montaser<sup>1,2</sup> Mostafa Shahein<sup>1</sup> Juan Manuel Revuelta<sup>1</sup>  
Bradley A. Otto<sup>1,3</sup> Ricardo L. Carrau<sup>1,3</sup> Daniel M. Prevedello<sup>1,3</sup>

<sup>1</sup> Department of Neurological Surgery, Wexner Medical Center, The Ohio State University College of Medicine, Columbus, Ohio, United States

<sup>2</sup> Department of Neurological Surgery, Ain Shams University, Cairo, Egypt

<sup>3</sup> Department of Otolaryngology – Head and Neck Surgery, Wexner Medical Center, The Ohio State University, College of Medicine, Columbus, Ohio, United States

Address for correspondence Daniel M. Prevedello, MD, Department of Neurological Surgery, The Ohio State University Wexner Medical Center, 410 W 10th Ave, N-1049 Doan Hall, Columbus, OH 43210, United States (e-mail: dprevedello@gmail.com).

J Neurol Surg B 2018;79(suppl S3):S237–S238.

## Abstract

We present the case of a 57-year-old male who presented with progressive right side vision loss whose workup revealed a large suprasellar lesion with invasion of the third ventricle. The pituitary stalk was not visible.

Hormonal panel showed no hormonal deficits. The initial diagnosis was of a type II transinfundibular craniopharyngioma (as classified by Kassam et al).

An endoscopic endonasal transplanum transtuberculum approach was done using a standard binostril four-hand technique, with the patient positioned supine with the head turned to the right side and tilted to the left, fixed in a three-pin head clamp, under imaging guidance. The tumor was carefully dissected away from the optic apparatus while preserving the vessels, mainly the superior hypophyseal artery. The stalk was identified around the tumor and preserved. The third ventricle was entered and inspected at the end of the procedure and a near-total resection (a small residual in the right hypothalamus) with decompression of the optic apparatus was achieved. Reconstruction was done in a multilayered fashion, using collagen matrix and a nasoseptal flap. Patient had an uneventful postoperative stay and was discharged on POD 4, neurologically stable with no hormonal deficits. Pathology confirmed an adamantinomatous craniopharyngioma. Due to a small growth of the residual, patient underwent fractionated stereotactic radiation (50.4Gy in 28 sessions). He presented with panhypopituitarism 2 years after radiation therapy. At 3-month follow-up, his vision was back to normal and 6-year postoperative magnetic resonance imaging showed no signs of recurrence.

The link to the video can be found at: [https://youtu.be/chG7Xlz7a\\_A](https://youtu.be/chG7Xlz7a_A).

## Keywords

- ▶ endoscopic surgery
- ▶ neurosurgery
- ▶ skull base
- ▶ craniopharyngioma



[www.thieme.com/skullbasevideos](http://www.thieme.com/skullbasevideos)

[www.thieme.com/jnlbsvideos](http://www.thieme.com/jnlbsvideos)

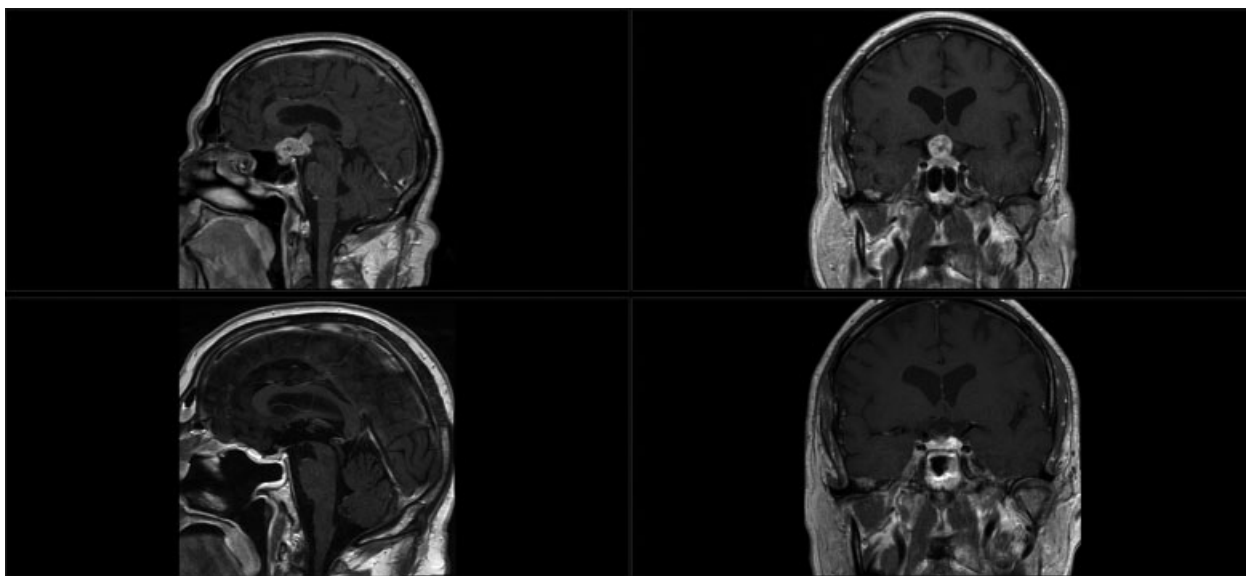
received  
October 18, 2017  
accepted after revision  
December 7, 2017  
published online  
February 7, 2018

DOI <https://doi.org/10.1055/s-0038-1623526>.  
ISSN 2193-6331.

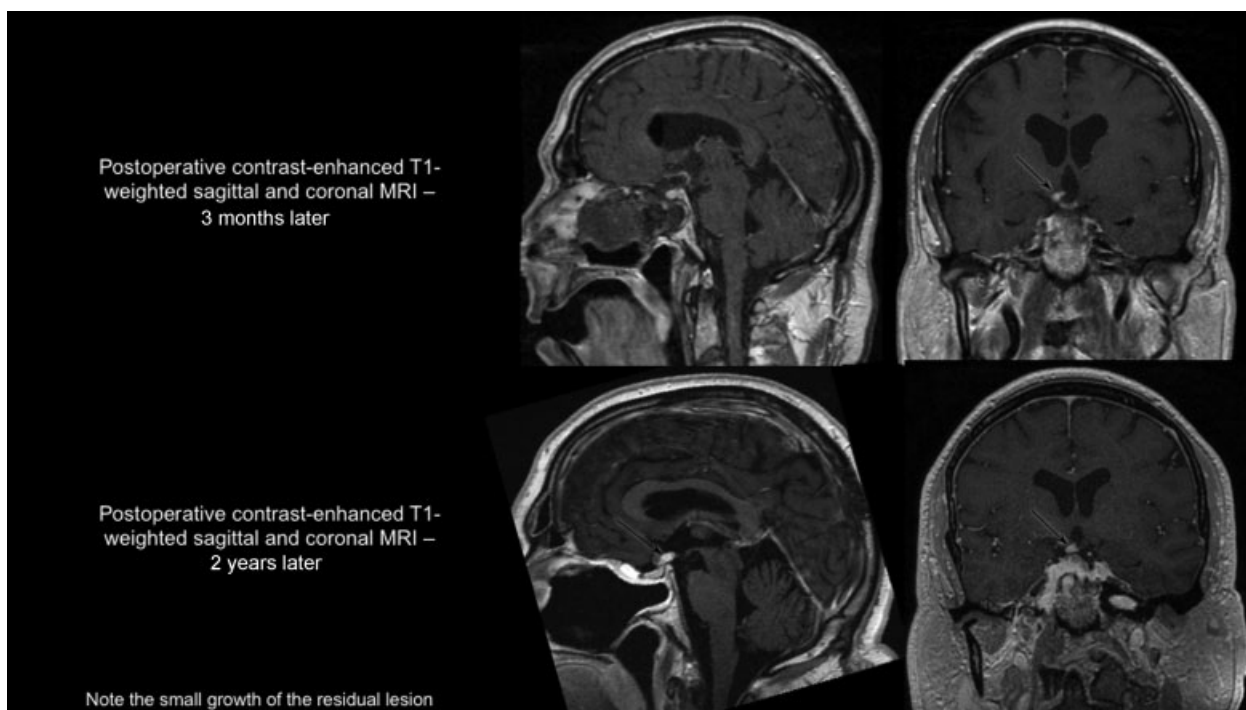
© 2018 Georg Thieme Verlag KG  
Stuttgart · New York

License terms





**Fig. 1** Pre- and postoperative/postradiation T1-weighted contrast enhanced magnetic resonance images in the sagittal and coronal planes.



**Fig. 2** T1-weighted contrast enhanced magnetic resonance imaging (MRIs) in the sagittal and coronal planes. Upper row shows the 3-month postoperative images and bottom row shows 2-year postoperative images. The residual had a small growth and patient underwent fractionated radiotherapy.

**Conflict of Interest**

None.

**Financial Disclosure**

Ricardo Carrau is a consultant for Medtronic. Daniel M. Prevedello is a consultant for Medtronic, Codman, and Stryker. He has received honorarium from Leica Microsystems and has a royalty agreement with KLS-Martin.

**Reference**

- 1 Kassam AB, Gardner PA, Snyderman CH, Carrau RL, Mintz AH, Prevedello DM. Expanded endonasal approach, a fully endoscopic transnasal approach for the resection of midline suprasellar craniopharyngiomas: a new classification based on the infundibulum. *J Neurosurg* 2008;108(04):715–728