

Endoscopic Endonasal Transplanum–Transtuberculum Sellae Approach for the Resection of a Diaphragma Sellae Meningioma

Juan M. Revuelta Barbero¹ Alaa S. Montaser^{1,2} Alexandre B. Todeschini¹ Mostafa Shahein¹
Bradley A. Otto^{1,3} Ricardo L. Carrau^{1,3} Daniel M. Prevedello^{1,3}

¹Department of Neurological Surgery, Wexner Medical Center, The Ohio State University, Columbus, Ohio, United States

²Department of Neurosurgery, Ain Shams University Faculty of Medicine, Cairo, Egypt

³Department of Otolaryngology–Head and Neck Surgery, Wexner Medical Center at The Ohio State University, Columbus, Ohio, United States

Address for correspondence Daniel M. Prevedello, MD, Department of Neurological Surgery, Wexner Medical Center at The Ohio State University, N-1049 Doan Hall, 410 West 10th Avenue, Columbus, OH 43210, United States (e-mail: daniel.prevedello@osumc.edu).

J Neurol Surg B 2018;79(suppl S3):S271–S272.

Abstract

The endoscopic endonasal approach (EEA) provides a direct access to diaphragma sellae meningiomas. We present a case of a 56-year-old-female with an incidentally diagnosed sellar/suprasellar lesion with no hormonal deficit; thus, she opted for conservative management initially. During her annual follow-up appointment with her ophthalmologist, it was noticed that the patient had right eye peripheral deficit on formal visual field testing. Magnetic resonance imaging (MRI) revealed an enlargement of the sellar/suprasellar mass, causing displacement of the optic chiasm. A transplanum–transtuberculum EEA was performed. Gross-total removal was achieved and closure was done in a multilayer fashion using a collagen matrix, nasoseptal flap. Histopathological examination confirmed a meningioma WHO grade I. There were no intra- or postoperative complications. At 4-year-follow-up, the patient has stable vision and MRI brain showed no recurrence.

The link to the video can be found at: <https://youtu.be/xY8T9hotlDs>.

Keywords

- ▶ diaphragma sellae meningioma
- ▶ endoscopic endonasal approach
- ▶ expanded approaches
- ▶ transplanum
- ▶ transtuberculum



www.thieme.com/skullbasevideos

www.thieme.com/jnlsbvideos

received
October 15, 2017
accepted
December 12, 2017
published online
February 20, 2018

DOI <https://doi.org/10.1055/s-0038-1624587>.
ISSN 2193-6331.

© 2018 Georg Thieme Verlag KG
Stuttgart · New York

License terms



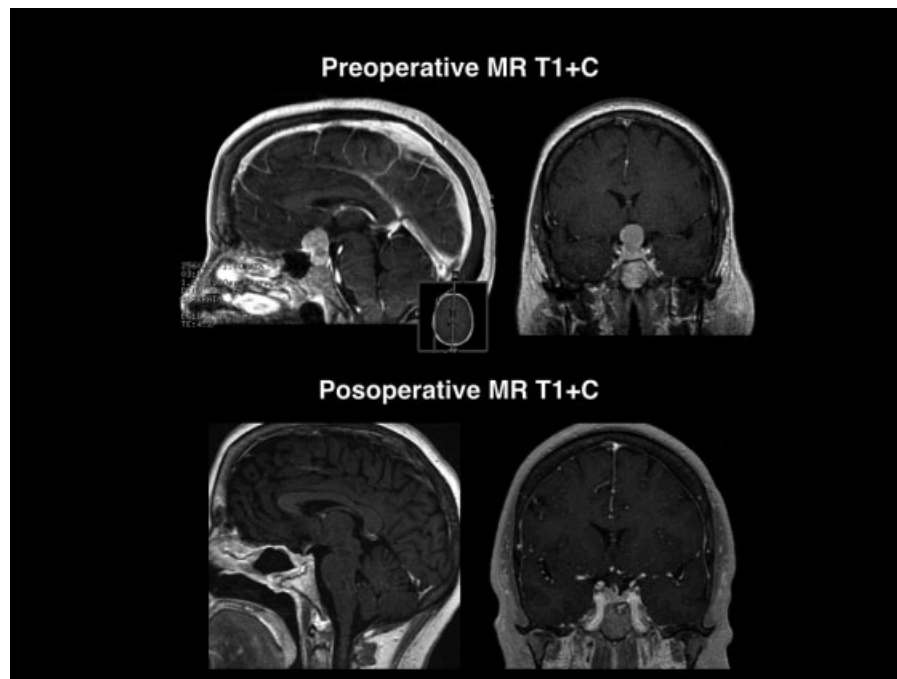


Fig. 1 Pre- and postoperative magnetic resonance imaging showing complete resection and no recurrence in 4 years.

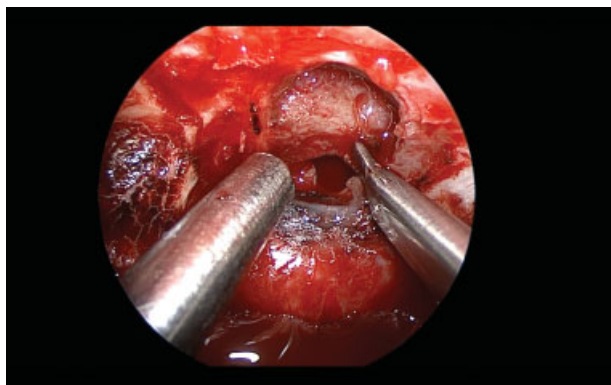


Fig. 2 Intraoperative image.

Funding Source

No funding was obtained for this study.

Financial Disclosure

Ricardo Carrau is a consultant for Medtronic. Daniel M. Prevedello is a consultant for Medtronic, Codman and Stryker. Daniel M. Prevedello has received honorarium from Leica Microsystems. Daniel M. Prevedello has a royalty agreement with KLS-Martin.

Conflict of Interest

None.