

Craniocervical fixation using *inside-outside* instrumentation

José Alberto Landeiro¹, Bruno C. da Rocha Lázaro², Igor de Castro³

Hospital da Força Aérea do Galeão, Ilha do Governador, Rio de Janeiro, Brasil..

ABSTRACT

The clinical knowledge of biomechanics of atlantoaxial complex demonstrated that progressive instability typically occurs after anterior decompression of the craniocervical junction. We report the so-called inside-outside technique for occipitocervical fixation, originally described by Pait et al. applied in two patients. One patient with rheumatoid arthritis underwent a transoral resection of basilar invagination; in another case the craniocervical junction instability was due to the presence of tumor. The "inside-outside" occipitocervical fixation technique consists in the use of a titanium rod bended according with occipital cervical angle, placed and fixed laterally over the cervical spine. The rod is fixed to the occipital bone using a screw with the flat portion positioned onto the epidural space. In the cervical spine the rod is attached to transarticular screws placed at the superolateral quadrant of the articular mass. In the axis the screw is introduced through the pars interarticularis finishing at the axis body or the lateral mass of the atlas. In both patients, stabilization was achieved immediately. This technique proved to be safe and easily applied in the patients who developed instability in the craniocervical junction procedure.

KEY WORDS

Occipitocervical fixation. Odontoidectomy. Transoral approach.

RESUMO

Técnica inside-outside para fixação occipito-cervical

Os estudos sobre a biomecânica do complexo occipito-atlanto-axial explicam a alta incidência da instabilidade que ocorre após a descompressão anterior da junção craniocervical. O objetivo deste relato é apresentar a técnica de fixação occipito-cervical tipo inside-outside proposta por Pait e cols. São apresentados dois pacientes operados pela via transoral e submetidos à fixação occipito-cervical com instrumentação tipo inside-outside: um paciente portador de artrite reumatóide, com severa compressão ventral da junção craniocervical, e outro portador de um volumoso tumor acometendo o corpo, a apófise odontóide e invadindo o canal vertebral cervical. A técnica utiliza uma haste de titânio moldada para adaptar-se à curvatura occipital e implantada lateralmente até a coluna cervical, a haste é fixada por meio de parafuso, cuja parte achatada é colocada no espaço epidural. Na coluna cervical, a haste é fixada por parafusos que são introduzidos no quadrante supero-lateral das massas articulares. No axis, o parafuso é introduzido na pars interarticularis podendo terminar no corpo desta vértebra ou na massa articular do atlas. A técnica de fixação occipito-cervical tipo inside-outside, nos casos descritos, mostrou-se segura e de fácil aplicabilidade.

PALAVRAS-CHAVE

Fixação occipitocervical. Acesso transoral. Odontoidectomia.

The treatment of the instability of the occipital bone articulate complex, atlas and axis is more difficult when compared to the treatment of the instability of the lower cervical spine. Techniques of external occipitocervical stabilization with orthesis, bone grafts,

handles and wires, metilmetacrilate, bone growing induction substances and finally the use of more complex instruments as connecting plates, wire and screw have been used^{3,7,9,19}. Fixation techniques as plates and screws promote immediate stabilization guaranteeing

1 Professor Adjunto IV da Disciplina de Neurocirurgia do Centro de Ciências Médicas da Universidade Federal Fluminense, RJ. Chefe do Serviço de Neurocirurgia do Hospital da Força Aérea do Galeão.

2 Residente do Serviço de Neurocirurgia do Hospital da Força Aérea do Galeão, Rio de Janeiro, RJ.

3 Assistente do Serviço de Neurocirurgia do Hospital da Força Aérea do Galeão, Rio de Janeiro, RJ.

the security of the patient. The instability verified after anterior approach decompression for diseases as basilar impression, rheumatoid arthritis and tumors occurs in a great number of patients, demanding that the fixation embraces the occipital condilum (CO) and the first and the second cervical vertebrae (C1 and C2).

The present article describes the technique described by Pait et al.¹⁹, for occipital-cervical fixation – a method denominated as “inside-outside” with material especially assigned for this purpose, illustrated by the cases in the following.

Operative technique

The patients are submitted pre-operatively to magnetic resonance imaging (MRI) of the brain and craniocervical junction (CCJ). Computed tomography with three-dimensional (3D-CT scan) reconstruction was also performed to assess the thickness of the occipital bone, integrity of the cervical vertebrae, thickness of the pedicle and the diameter of the vertebral foramina.

The patients are operated in prone position, under general anesthesia, with cervical traction around 2kg and the head located in appropriate support covered with silica foam. The neck is placed in neutral position and the radioscope located to get lateral images of the CCJ. Midline incision is performed extending from theinion to C5. The occipital bone, the foramen magnum, C1 and C2 are exposed including at least two segments below. We have used titanium implants, compatible with MRI and to the occipital bending and craniocervical transition. Initially, a plate model is molded to the bending and placed over the occipital and the articulate masses as a point marking for the future vertical alignment of the screws in the occipital bone and the cervical articular masses. It is followed by trepanation in the middle line of the occipital convexity for promoting the access for the flattened part of the screw. The next step is the lateral positioning of the screw obtained through a bone key way with the use of a drill, with a lateral or medial cut coming from the entry hole to the marked exit site. The screw is attached to a guide rod and inserted into the entry site. The reconstruction plate is placed over the inside-outside screw, and the nut is attached to the screw. The epidural location of the screw can now be visualized. After control images for verification of the correct position of the screws, the final squeeze is then performed. Bone grafts are interposed between the reconstructing plate and the arcs of the involved vertebrae, after drilling the bone surface. The patients are transferred post operatively

to the Intensive Care Unit (ICU). This technique was applied in the following cases.

Case 1

The first case was a 32-year-old woman with a diagnosis of rheumatoid arthritis. She presented to the hospital with neck pain, quadriparesis, hyperreflexia and dysesthesia, with two episodes of sudden loss of conscience followed by prompt recovery. She was confined to a wheelchair. On physical examination a high level quadriparesis was noted (motor grade 3). Hoffman sign and ankle clonus were present bilaterally, with hyperactive deep tendon reflexes. MRI revealed pannus formation in the epidural space and 3D-CT scan of the JCC evidenced vertical subluxation of the odontoid process (Figure 1). This lesion was irreducible and had a compressive effect on the cervico-medullary transition. An odontoidectomy was performed using the transoral approach. In the same operation she was submitted to the occipitocervical “inside-outside” stabilization (System Occifix - G.M Reis, Campinas, SP) (Figure 2). The patient who was once restricted to a wheelchair presented gradual strength improvement on the lower limbs and in the last medical evaluation she could stay in the stand up position using an arm support .

Case 2

The second patient was a 37-year-old woman who presented with a 12-month history of progressive head and neck pain, bilateral hand numbness and subjective weakness. There were no bowel or bladder difficulties, or difficulty in swallowing or respiration. The neurological examination was normal, but she had limitation on neck movement. The MRI showed a large and heterogeneous mass involving the CCJ. The mass caused significant spinal cord compression (Figure 3). CT scan of the CCJ demonstrated a bone destruction of first and second cervical segments and inferior edge of clivus. The surgery consisted in transoral approach with removal of the mass, from superior border of C2 to inferior edge of clivus. On the same procedure the patient was placed in prone position under cervical traction, then a far-lateral approach was performed, resulting in adequate removing of the rest of the tumor; we performed the occipitocervical fixation using the “inside-outside” method plus bone grafting with the same system as described above (Figure 4). The histological examination of the resected mass demonstrated a chordoma. Her symptoms have diminished and she resumed her activities at home.

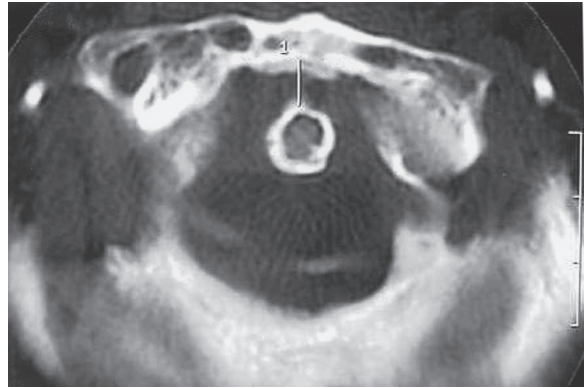


Figure 1
Preoperative sagittal and axial CT scan obtained in patient with reumathoid arthritis revealing dorsal displacement of odontoid apex (case 1)

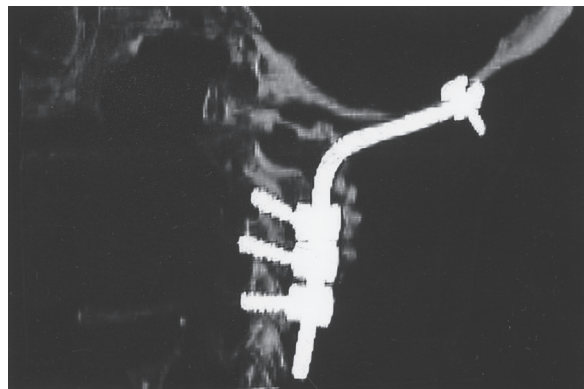
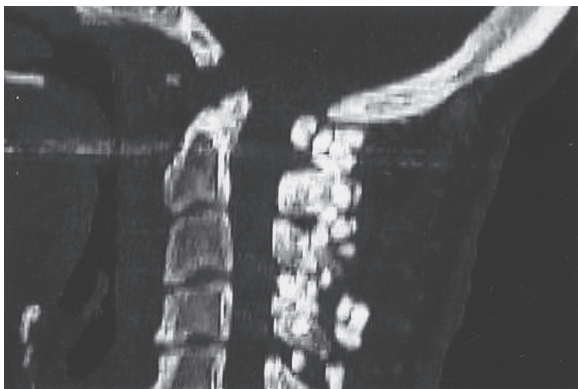


Figure 2
*Postoperative sagittal CT scan showing ventral resection of odontoid apex (left).
Postoperative CT scan after occipitocervical fusion with inside-outside technique (right) (case 1)*

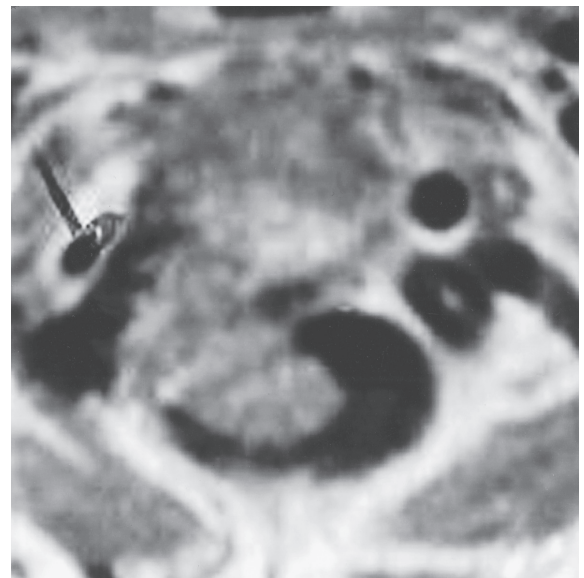
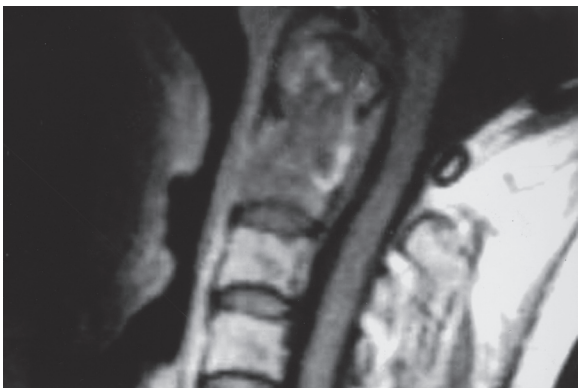

Figure 3
Preoperative MRI demonstrating a chordoma (case 2)

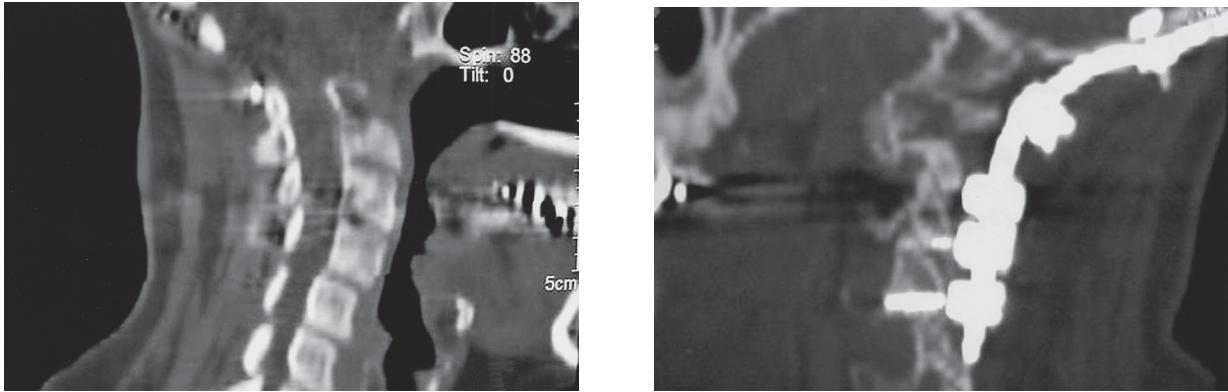


Figure 4
 Postoperative CT scan after radical resection of the tumor (left).
 Postoperative lateral CT scan showing posterior stabilization (right) (case 2)

Discussion

Craniocervical instability is associated with significant mortality and morbidity. The objective of the fixation methods is to provide immediate stabilization, relief of the symptoms and correction of the deformity in only one procedure. The occipitocervical stabilization using the “inside-outside” system, described by Pait et al.¹⁹, provides immediate stabilization of the craniocervical junction. The ways of stabilization vary from the use of external ortesis²¹ to systems of internal fixation using bone or substitutes¹¹ and instruments especially assigned for this¹⁹. Although the traditional methods of stabilization with bone grafts associated with the use of the halo have been useful, new systems of reconstructing plates settled with screws, hooks or sublaminar wires helps to provide immediate stability of the craniocervical junction until arthrodesis is completed^{9,10,14,19}.

Studies of the biomechanics of the CCJ have demonstrated that after previous anterior decompression with odontoidectomy and transcondylar approaches with removal of more than 50% of bone may cause instability^{5,6,23}. Although the stabilization via anterior approach has its adepts^{1,8} the majority of authors perform posterior approach to obtain stabilization with some consensus on the incorporation of the occipital condile to the atlas-axis complex^{3,7,9,10,12,14,16-18}. This becomes imperious to the cases in which odontoidectomy is performed for treatment of rheumatoid arthritis and in cases of C2 vertebral body tumors.

On the presented cases, one patient with rheumatoid arthritis developed severe neurological deficit and CT scan showed a vertical subluxation with upward migration of odontoid process. MRI revealed *pannus*

formation in the epidural space. The lesion was irreducible. She was submitted to odontoid resection via transoral approach and on the same surgical time was performed an occipitocervical instrumentation. Other patient presented with tumor involvement of the CCJ. MRI revealed a voluminous mass involving the atlantoaxial complex with intracanal components. The mass caused significant spinal cord compression. C1-C2 CT scan revealed significant bone destruction of the second vertebral body, the odontoid process and the articular process of C1-C2. The patient was submitted to anterior and postero-lateral decompression, and occipitocervical stabilization. In this case we could not perform an atlantoaxial fixation because the lesions had destroyed the bone. In the other patient with rheumatoid arthritis we could not applied the screw in C2 because of an anomalous vertebral artery.

While the craniocervical stabilization using Luque/Hartschill¹⁴ rectangles requires the integrity of the occipital bone in midline, in this procedure the screw can be placed more laterally. In cases of high cervical laminectomy, as in the technique proposed by Mori et al.¹⁷, it is necessary to extend the sublaminar knotting to the most inferior segments.

Although the systems of stabilization with wire, as used in the techniques of Rogers and Lovely & Carls², have proven biomechanical effectiveness, studies have demonstrated the superiority of the methods of stabilization with screws, providing superior immobilization, best resistance to fatigue tests when compared to those that use metallic wires and hooks⁷, and the number of involved cervical segments is lesser on methods using transarticular screws^{9,10,13,16}. One of the main advantages of the occipitocervical stabilization with “inside-

outside” is the rank of the screws on the inside of the connecting plates and perpendicular to the articulate process. This process diminishes the risks of injury to the vertebral artery while on transarticular C1-C2 fixation the main limitation is the proximity of the vertebral artery. Paramore et al.²⁰, in a study using CT scan of 94 patients, concluded that 18% to 23% of the patients were not candidates to the setting of transarticular screws at least in one side because of the passage of the artery inside of the transverse foramina. Madawi et al.¹⁵ in 61 patients submitted C1-C2 stabilization with transarticular screw, with the majority of patients bearing the diagnosis of rheumatoid arthritis, there were five cases with injury of vertebral artery and one case presenting transitory paralysis of the XII cranial nerve. In the cases with injury of the vertebral artery, only one presented symptoms attributed to it, consisting in ischemic brain stem lesions occurred two weeks after the surgery. They have identified as risk factors the incomplete reduction before the implantation of the screws, previous transoral surgery with removal of the anterior tubercle of C1, and imperfections in identifying the correct position of the vertebral artery adjacent to the lateral mass and pedicle of C1. Studies of the “American Association of Neurological Surgeons presented at the Congress Neurological Surgeons Section on Disorders of the Spine and Peripheral Nerves²⁴ with 847 neurosurgeons, who had implanted 2492 transarticular screws in 1318 patients, have found 31(2,4%) of the patients with injury of the vertebral artery and suspicion of injury in 23 (1,7%). Of these, two had only shown neurological deficits and one had died because of bilateral injury of the vertebral artery. Other complications were described, as dural laceration, screw break and suboccipital paresthesias²⁴.

The occipitocervical stabilization in the cases of instability of the atlantoaxial joint presents peculiarities because of the complex anatomy of the region. It depends on the thickness of the occipital bone, the bone integrity around of the foramen magnum, the presence or not of the vertebral lamina, to articulate joints and the positioning and the size of the vertebral arteries. The “inside-outside” method offers advantages in relation to the traditional methods of “outside-inside” cervical spine stabilization or to the techniques that utilizes wires and handles transfixing the occipital. Although Heywood et al.¹² had not described cerebral complications with the traditional technique, they had prevented to penetrate the screw in the internal occipital bone. In the “inside-outside” method the screw is placed under direct vision with the flattened part in contact with the dura and the screw turned toward the surgeon. However it is necessary to know the thickness of the occipital bone what provide the support for the

setting of the inverted screw. The patients often presented significant improvement of the pain syndrome and the diminished use of orthosis. The control images confirm the correct positioning of the system and the occurrence of arthrodesis.

Stabilization methods must be simple, safe and represent low risk to adjacent structures. The “inside-outside” technique fills these requirements and provides solid craniocervical stabilization until the consolidation of the cycle of the arthrodesis.

References

1. ANDRADE JR, MACNAB I: Anterior occipital cervical fusion using extrapharyngeal approach exposure. *J Bone Surg (Am)* 51:1621-6, 1969.
2. BRASIL ABV: Tratamento da instabilidade traumática da coluna cervical: avaliação biomecânica das técnicas de Rogers e de Lovely & Carls. Tese (doutorado). São Paulo, 1997.
3. CROCKARD HA, POZO JL, RANSFORD AO, STEVENS JM, KENDALL BE, ESSIGMAN WK: Transoral decompression and posterior fusion for rheumatoid atlanto-axial subluxation. *J Bone Joint Surg (Br)*68:350-6, 1986.
4. DICKMAN CA. Biology of the spine fusion. In Dickman CA, Spetzler RF, Sonntag VKH(eds): *Surgery of the Craniovertebral Junction*. New York, Thieme, 1998, pp 685-98.
5. DICKMAN CA, CRAWFORD NR, BRANTLEY AGU, SONNTAG VKH: Biomechanical effects of transoral odontoidectomy. *Neurosurgery* 36:1146-53, 1995.
6. DICKMAN CA, LOCANTRO J, FESSLER RG: The influence of transoral odontoid resection on stability of craniovertebral junction. *J Neurosurg* 77:525-30, 1992.
7. FAURE A, BORD E, MONTEIRO DA SILVA R, ROBERT R: Occipitocervical fixation with a single occipital a single clamp inverted hooks. *Eur Spine J* 7:80-3, 1998.
8. GOEL A, BHATJIMAKE M, DESAI K: BASILAR INVAGINATION: A study based on 190 surgically treated patients. *J Neurosurg* 88:962-8, 1998.
9. GROB D, DVORACK J, PANJABI, FROELICH M, HAYEK J: Posterior occipitocervical fusion: a preliminary report of a new technique. *Spine*16:17-24, 1991.
10. GROB D, DVORAK J, PANJABI MM, ANTINNES JA: The role of plate and screw fixation in occipitocervical fusion in rheumatoid arthritis. *Spine*19:2545-51, 1994.
11. HABAL MB: DIFFERENTS FORMS OF BONE GRAFTS. In Habal MB, Reddi AH (eds): *Bone Grafts and Bone substitutes*. Philadelphia, Saunders, 1992, pp 6-8.
12. HEYWOOD AW, LEARMONTH ID, THOMAS M: Internal fixation for occipito-cervical fusion. *J Bone Joint Surg (Br)*70:708-11, 1988.
13. HURLBERT JR, CRAWFORD NR, CHOI WG, DICKMAN CA: A biomechanical evaluation of occipitocervical instrumentation: screw compared with wire fixation. *J Neurosurg (Spine)* 90:84-90, 1999.
14. MACKENZIE AI, UTLEY D, MARSH HT, BELL BA: Craniocervical stabilization using Luque/Hartshill rectangles. *Neurosurgery* 26:32-6, 1990.
15. MADAWI AA, CASEY ATH, SOLANKI GA, TUIE G, VERES R, CROCKARD HA: Radiological and anatomical evaluation of the atlantoaxial transarticular screw fixation technique. *J Neurosurg* 86:961-8, 1997.

16. MARCOTTE P, DICKMAN CA, SONNTAG VKH, KARAHALLOS DG, DRABIER J: Posterior atlantoaxial facet screw fixation: J Neurosurg 79:234-7, 1993.
17. MORI T, MATSUNAGA S, SUNAHARA N, SAKOU T: 3-to 11-year follow-up of occipitocervical fusion for rheumatoid arthritis. Clin Orthop Relat Res 351:169-79, 1998.
18. MURPHY M, SOUTHWICH WO: Posterior approaches and fusions. In Cervical Spine Research Society (ed): The Cervical Spine. Ed 2. Philadelphia, Lippincot, 1989, pp 775-91.
19. PAIT TG, AL-MEFTY O, BOOP FA, ARNAUTOVIC KI, RAHMAN S, CEOLA W: Inside-outside technique for posterior occipitocervical spine instrumentation and stabilization: preliminary results. J Neurosurg 90(Suppl):1-7, 1999.
20. PARAMORE CG, DICKMAN CA, SONNTAG VKH: The anatomical suitability of C1-C2 complex for screw fixation. J Neurosurg 85: 221-4, 1996.
21. PIERCE DS, BARR JS JR: Fractures and dislocations at the base of the skull and upper cervical spine. In Cervical Spine Research Society (ed): The Cervical Spine. Ed 2. Philadelphia, JB Lippincot, 1989, pp 312-24.
22. ROY-CAMILLE R, SAILLANT G, MAZEL C: Internal fixation of the unstable cervical spine by a posterior osteosynthesis with plates and screws. In Cervical Spine Research Society (ed): The Cervical Spine. Ed 2. Philadelphia, JB Lippincott, 1989, pp 390-403.
23. VISHTEH AG, CRAWFORD NR, MELTON MS, SPETZLER RF, SONNTAG VKH, DICKMAN CA: Stability of the craniovertebral junction after unilateral occipital condyle resection: a biomechanical study. J Neurosurg (Spine1) 90:91-98, 1999.
24. WRIGHT MN, LAURYSSEN C: Vertebral artery injury in C1-C2 transarticular screw fixation: results of survey of the AANS/CNS Sections on Disorders of the Spine and Peripheral Nerves. J Neurosurg 88:634-40, 1998.

Original recebido em abril de 2005

Aceito para publicação em agosto de 2005

Endereço para correspondência:

José Alberto Landeiro

Av. Monsenhor Ascâneo 591/202

2261-060 – Rio de Janeiro, RJ