

Hemiparkinsonism associated with mesencephalic cavernoma: case report and review of literature

Carlos Eduardo Dall'aglio Rocha¹, Fábio de Nazaré Oliveira², Lucas Crociati Meguins³

Department of Neurological Sciences, Hospital de Base da Faculdade de Medicina de São José do Rio Preto (Famerp), São José do Rio Preto, SP.

ABSTRACT

Parkinsonism is a movement disorder characterized by resting tremor, slow and decreased movements (hypokinesia and akinesia), rigidity, postural instability, problems with gait, and coordination. Parkinson's disease (PD) is the most common cause of parkinsonism and its prevalence is estimated to range from 0.1% to 0.3% in the general population and from 1% to 2% in persons 65 years of age or older. Although the majority of cases of PD are describe to be sporadic, many identifiable etiologies have been included as possible causes of parkinsonism, such as genetic disorders, cerebrovascular events and intoxication. However, mesencephalic cavernoma is an extremely rare condition associated to hemiparkinsonism. In the present report, we describe the case of a Brazilian woman that evolved symptoms of hemiparkinsonism and presented a ventral mesencephalic cavernoma on radiological investigation.

KEY-WORDS

Cavernous hemangioma, mesencephalon, Parkinson disease.

RESUMO

Hemiparkinsonismo associado à presença de cavernoma mesencefálico: relato de caso e revisão da literatura

O parkinsonismo corresponde a um transtorno do movimento caracterizado por tremores de repouso, redução e lentidão dos movimentos (hipocinesia e acinesia), rigidez, instabilidade postural e problemas relacionados a marcha e coordenação. A doença de Parkinson (DP) é a causa mais comum de parkinsonismo e sua prevalência é estimada em torno de 0,1% a 0,3% em relação à população geral e 1% a 2% em pessoas acima de 65 anos de idade. Embora a maioria dos casos de DP tenha sido descrita como casos esporádicos, muitas etiologias identificáveis foram incluídas como possíveis causas de parkinsonismo, tais como alterações genéticas, eventos cerebrovasculares e intoxicações. No entanto, o cavernoma mesencefálico é uma causa de hemiparkinsonismo extremamente rara. No presente relato, descreve-se o caso de uma mulher brasileira que apresentou sintomas de hemiparkinsonismo relacionados à presença de um cavernoma mesencefálico ventral na investigação radiológica.

PALAVRAS-CHAVE

Hemangioma cavernoso, mesencéfalo, doença de Parkinson.

Introduction

Cavernomas are an uncommon lesion seen in neurological practice that can occasionally rupture. It is characterized as a mulberry-like assembly of thin-walled vascular sinusoids lined by a thin endothelium lacking smooth muscle, elastin, and intervening pa-

renchyma, surrounded by hemosiderin deposits and gliosis, which may or may not be thrombosed.^{5,14,16-18}

Cavernomas represent around 5% to 10% of all central nervous system (CNS) vascular malformation.^{8,25} They are usually located in the supratentorial space and are uncommonly found in the brainstem, with few cases reported in the mesencephalon.^{2,4,7,8} Symptomatology

1. Neurosurgeon, Head of the Division of Functional Neurosurgery, Department of Neurological Sciences, Hospital de Base da Faculdade de Medicina de São José do Rio Preto (Famerp), São José do Rio Preto, SP, Brazil.
2. Neurologist, Head of the Division of Movement Disorders, Department of Neurological Sciences, Hospital de Base da Famerp, São José do Rio Preto, SP, Brazil.
3. Resident of Neurosurgery, Department of Neurological Sciences, Hospital de Base da Famerp, São José do Rio Preto, SP, Brazil.

tends to correspond with the deficits that would be predicted by the site of the lesion in various parts of the CNS. In brainstem, cranial nerves, sensory and motor (including ataxia) deficits are referred as the most common clinical presentation of cavernomas. However, hemiparkinsonism is an extremely rare clinical manifestation of mesencephalic cavernomas with only five cases previously reported in English medical literature.

The aim of the present report is to describe the case of an adult Brazilian woman with a ventral mesencephalic cavernoma that progressively evolved symptoms of hemiparkinsonism.

Case report

A 44 year-old Brazilian woman was referred to neurological evaluation presenting an 18-months history of progressive rest tremor on the left arm that usually worsened during quotidian stressful events and apparently deteriorated during the last 2 months. In addition, she also affirmed gradual slow and decreased movements of the left arm that significantly affected her daily activities as a teacher. She denied any symptoms of rigidity, postural instability or gait disorders, as well as any previous event

of brain trauma, drug use or allergies. Her past medical and familial history was unremarkable. On general clinical assessment, the patient was afebrile, blood pressure 110 x 70 mmHg, pulse 72 and respiratory rate 12. Heart rate regular with no murmurs or gallops and lungs were clear. On neurological examination, the patient present rest tremor of the left hand and mild bradykinesia of the left arm. The remaining of the neurological assessment was essentially normal. Laboratorial blood exams were within normal range. Magnetic resonance imaging (MRI) of the encephalon revealed an isolated lesion on the right ventral area of the mesencephalon exerting a mass effect on the surrounding neurological structures, suggestive of cavernoma (Figures 1, 2 and 3). As no other structural abnormality was found, a diagnosis of mesencephalic cavernoma was made and the symptoms of hemiparkinsonism were attributed to it. The patient was offered surgical and/or clinical treatment of the lesion with pros and cons well explained and decided in favor of conservative therapy with levodopa plus benserazide hydrochloride on a posology of 100 mg/25 mg, taken orally three times daily. The patient presented a remarkable recovery of motor symptoms two weeks after the beginning of medication. She is currently being followed on outpatient appointments and is completely free of hemiparkinsonism symptoms or any movement disorders during three years of follow-up.

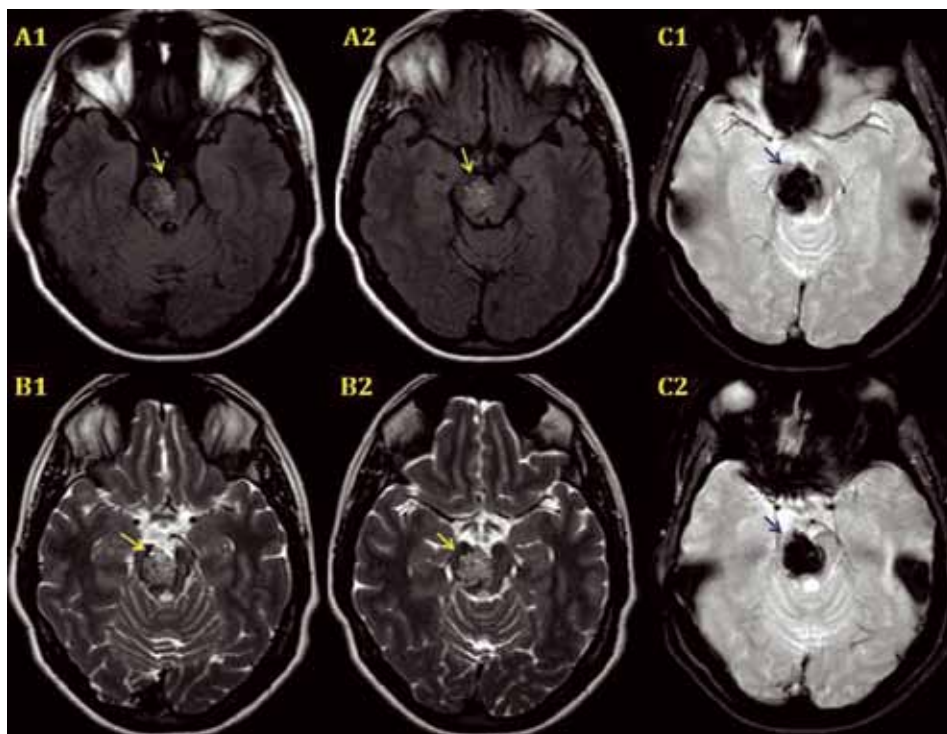


Figure 1 – Axial MRI showing a right mesencephalic cavernoma (arrows) (A1/A2: FLAIR-Weighted; B1/B2: T2/TSE- Weighted; C1/C2: EPI-Weighted).

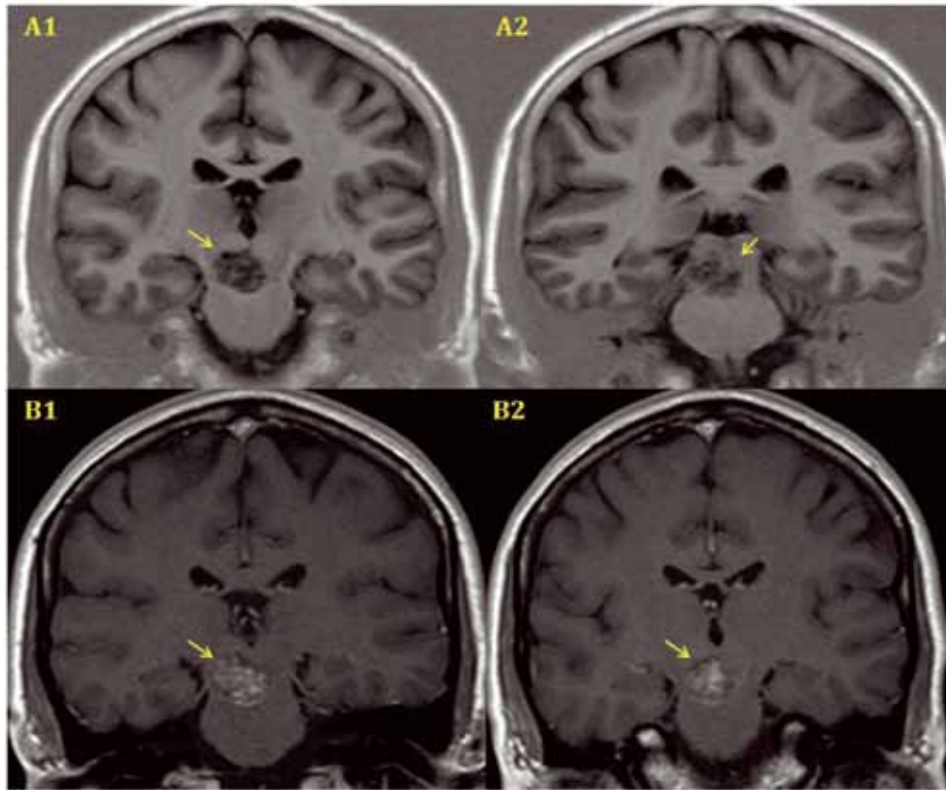


Figure 2 – Coronal MRI showing a right mesencephalic cavernoma (arrows) (A1/A2: T1/IR-Weighted; B1/B2: T1-Weighted with Gadolinium contrast).

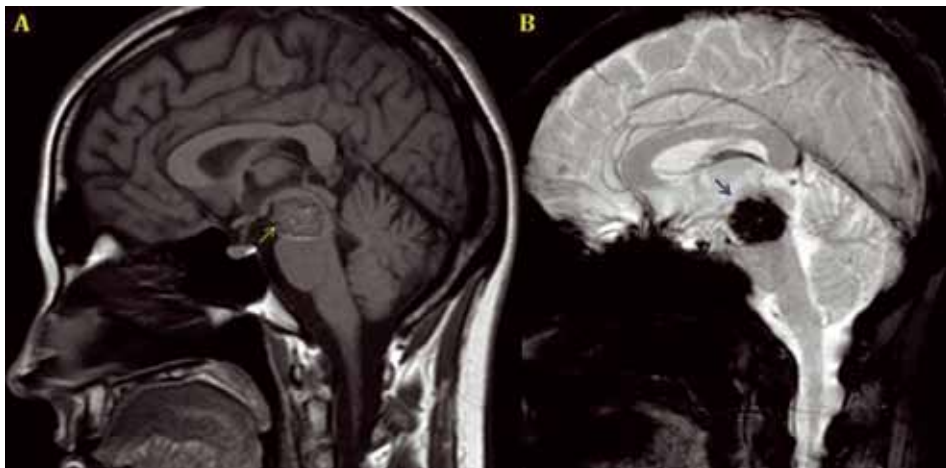


Figure 3 – Sagittal MRI showing a right mesencephalic cavernoma (arrows) (A: T1-Weighted with Gadolinium contrast; B: EPI-Weighted).

Discussion

Cavernous angioma or cavernoma is a vascular malformation which can be found in any region within the central nervous system (CNS) and accounts for about 5% to 10% of all CNS vascular abnormalities.^{8,25} Its first clinical report is attributed to Luschka, in 1854 *apud* El-Koussy *et al.*,⁶ and Virchow, in 1863 *apud* Iza-Vallejo *et*

al.,¹³ first described the histological diagnostic criteria for CNS cavernous angiomas. Since then, although much knowledge has been achieved regarding its etiology, epidemiology, anatomical location, clinical presentation and possible therapeutic approaches, cavernomas have been challenging and amazing neurologists and neurosurgeons that deal with patients presenting vascular abnormalities of the CNS. Blocq and Marinesco³

first published a case of tuberculoma affecting the cerebral peduncle in 1893 and, after that, several cases of tumor-induced parkinsonism have been reported. Cavernous malformations are usually described as a single or multiple mulberry-like mass of immature blood vessels lined by a thin endothelium, lacking of muscle cells, elastic fibers and intervening parenchyma. Its pathological characteristics are responsible for recurrent hemorrhages, thrombosis and lesion growth, which may cause pressure on the surrounding brain tissue.^{22,24}

Cavernous angiomas are usually found in supratentorial regions, accounting for more than 75% of all cases.^{1,8} Infratentorial lesions are uncommon and cavernous malformations of the brainstem account for less than 20% of all cases.^{1,6,8} Approximately 57% of brainstem cavernomas occur in the pons, followed by midbrain (20%), medulla oblongata (10%), pontomesencephalic junction (6.7%) and pontomedullary junction (6.7%).¹¹ Additionally, patients presenting brainstem cavernous angiomas may manifest a wide variety of clinical symptoms, ranging from totally asymptomatic to devastating neurological deficits. The most common clinical presentation usually involves a single or combined cranial nerve deficit, followed by hemiparesis and hemisensory deficit.²¹ Symptoms of parkinsonism resulting from mesencephalic cavernomas have been rarely report in English medical literature.^{9,10,12,19,20} In the present study, we described the case of a patient presenting a right ventral mesencephalic cavernoma (Figures 1, 2 and 3) that evolved symptoms of parkinsonism on the left hemibody, including resting tremor and bradykinesia.

The therapeutic approach of patients with parkinsonism associated to mesencephalic cavernomas varies from conservative management with levodopa to neurosurgical procedures on the attempt to remove the lesion and relief the compressive mass effect on the surround mesencephalic structures.^{9,10,12,19,20} The operative procedures performed so far have demonstrated clinical improvement of all patients,^{9,12,20} whilst the conservative therapy, according to Leung *et al.* case description, in 1999,¹⁹ may be unsuccessful. However, long-term follow-up of patients has not been investigated and no superior therapy has been proven on controlled trials. Moreover, mortality with conservative management of patients with brainstem cavernomas have been describe to range from 0% to 3.7%, while clinical improvement vary from 46.7% to 96%, during four to six years of follow-up.^{15,21,23} Our patient decided to initiate conservative therapy with levodopa plus benserazide hydrochloride on a posology of 100 mg/25 mg, taken orally three times daily. The patient presented a remarkable recovery of motor symptoms two weeks after the beginning of medication.

In conclusion, the present report reinforces that mesencephalic vascular malformations, especially cavernous angiomas, may be associated with clinical symptoms of hemiparkinsonism. Therefore, neuroimaging investigation of patient present symptoms on early adulthood is extremely important to rule out any structural abnormality affecting the cortico-nigrostriatal pathways.

References

1. Bernotas G, Rastenyte D, Deltuva V, Matukevicius A, Jaskeviciene V, Tamasauskas A. Cavernous angiomas: an uncontrolled clinical study of 87 surgically treated patients. *Medicina (Kaunas)*. 2009;45(1):21-8.
2. Bertalanffy H, Benes L, Miyazawa T, Alberti O, Siegel AM, Sure U. Cerebral cavernomas in the adult. Review of the literature and analysis of 72 surgically treated patients. *Neurosurg Rev*. 2002;25(1-2):1-53.
3. Blocq P, Marinesco G. Sur un cas tremblement arkinsonien hémiplégique symptomatique d'une tumeur du pédoncule cérébral. *CR Cos Biol (Paris)*. 1893;45:105-11.
4. Bozinov O, Hatano T, Sarnthein J, Burkhardt JK, Bertalanffy H. Current clinical management of brainstem cavernomas. *Swiss Med Wkly*. 2010;140:w13120.
5. Clatterbuck RE, Eberhart CG, Crain BJ, Rigamonti D. Ultrastructural and immunocytochemical evidence that an incompetent blood-brain barrier is related to the pathophysiology of cavernous malformations. *J Neurol Neurosurg Psychiatry*. 2001;71(2):188-92.
6. El-Koussy M, Stepper F, Spreng A, Lukes A, Gralla J, Brekenfeld C, et al. Incidence, clinical presentation and imaging findings of cavernous malformations of the CNS. A twenty-year experience. *Swiss Med Wkly*. 2011;141:w13172.
7. Fahlbusch R, Strauss C, Huk W. Pontine-mesencephalic cavernomas: indications for surgery and operative results. *Acta Neurochir Suppl (Wien)*. 1991;53:37-41.
8. Faria MP, Fagundes-Pereyra WJ, Carvalho GT, Sousa AA. [Cavernous malformations: surgical management in Belo Horizonte Santa Casa Hospital]. *Arq Neuropsiquiatr*. 2004;62(4):1079-84.
9. Ghaemi K, Krauss JK, Nakamura M. Hemiparkinsonism due to a pontomesencephalic cavernoma: improvement after resection. Case report. *J Neurosurg Pediatr*. 2009;4(2):143-6.
10. Gil R, Neau JP, Vandermarcq P, Agbo C, Dumas P. Hemiparkinsonism with dystonia due to a cavernous angioma of the substantia nigra. *Mov Disord*. 1994;9(Suppl 1):35.
11. Huang AP, Chen JS, Yang CC, Wang KC, Yang SH, Lai DM, et al. Brain stem cavernous malformations. *J Clin Neurosci*. 2010;17(1):74-9.
12. Inci S, Celik O, Soylemezoglu F, Ozgen T. Thalamomesencephalic ossified cavernoma presenting with Holmes' tremor. *Surg Neurol*. 2007;67(5):511-6.
13. Iza-Vallejo B, Mateo-Sierra O, Mosqueira-Centurión B, Ruiz-Juretschke F, Carrillo R. [Cerebral cavernomas. A review and update of aetiological, clinical and therapeutic features]. *Rev Neurol*. 2005;41(12):725-32.

14. Jellinger K. Vascular malformations of the central nervous system: a morphological overview. *Neurosurg Rev.* 1986;9(3):177-216.
15. Karlsson B, Kihlström L, Lindquist C, Ericson K, Steiner L. Radiosurgery for cavernous malformations. *J Neurosurg.* 1998;88(2):293-7.
16. Kononov A, Samii M, Porter RW, Spetzler RF, Houtteville JP, Yoshimoto T, et al. Brainstem cavernoma. *Surg Neurol.* 2000;54(6):418-21.
17. Lechevalier B, Houtteville JP. [Intracranial cavernous angioma]. *Rev Neurol (Paris).* 1992;148(3):173-9.
18. Lechevalier B. [Neuropathologic study of cavernomas]. *Neurochirurgie.* 1989;35(2):78-81.
19. Leung GK, Fan YW, Ho SL. Rubral tremor associated with cavernous angioma of the midbrain. *Mov Disord.* 1999;14(1):191-3.
20. Li ST, Zhong J. Surgery for mesencephalic cavernoma: case report. *Surg Neurol.* 2007;67(4):413-7.
21. Menon G, Gopalakrishnan CV, Rao BR, Nair S, Sudhir J, Sharma M. A single institution series of cavernomas of the brainstem. *J Clin Neurosci.* 2011;18(9):1210-4.
22. Steiger HJ, Markwalder RV, Reulen HJ. [Cerebral cavernoma as a cause of recurrent cerebral hemorrhage and epileptic insults]. *Schweiz Med Wochenschr.* 1988;118(13):471-7.
23. Tarnaris A, Fernandes RP, Kitchen ND. Does conservative management for brain stem cavernomas have better long-term outcome? *Br J Neurosurg.* 2008;22(6):748-57.
24. Van Lindert EJ, Tan TC, Grotenhuis JA, Wesseling P. Giant cavernous hemangiomas: report of three cases. *Neurosurg Rev.* 2007;30(1):83-92.
25. Viruega AJ, Herrera R, Rojas HP. Cavernomas del tronco encefálico: presentación de dos casos y revisión bibliográfica. *Rev Argent Neuroc.* 2006;20:25-35.

Correspondence address

Lucas Crociati Meguins
 Rua Pedro Palotta, 101/31B
 15092-205 – São José do Rio Preto, SP, Brazil
 Telephone: (+55 17) 8108-5530/(+55 17) 9197-6029/(+55 17) 330-14573
 E-mail: lucascrociati@libero.it