

Microsurgical Resection of Suprasellar Craniopharyngioma—Technical Purview

Anil Nanda¹ Vinayak Narayan¹ Nasser Mohammed¹ Amey R. Savardekar¹ Devi Prasad Patra¹

¹Department of Neurosurgery, Louisiana State Health Sciences Center – Shreveport, Shreveport, Louisiana, United States

Address for correspondence Anil Nanda, MD, MPH, FACS, Department of Neurosurgery, Louisiana State Health Sciences Center – Shreveport, P O Box 33932, 1501 Kings Highway, Shreveport, LA 71130-3932, United States (e-mail: ananda@lsuhsc.edu).

J Neurol Surg B 2018;79(suppl S3):S247–S248.

Abstract

Objectives Complete surgical resection is an important prognostic factor for recurrence and is the best management for craniopharyngioma. This operative video demonstrates the technical nuances in achieving complete resection of a suprasellar craniopharyngioma.

Design and Setting The surgery was performed in a middle-aged lady who presented with the history of progressive bitemporal hemianopia and excessive sleepiness over 8 months. On imaging, suprasellar craniopharyngioma was identified. The tumor was approached through opticocarotid cistern and lamina terminalis. Exposure of bilateral optic nerves, right internal carotid artery, anterior cerebral artery, and its perforator branches was then afforded and the tumor was gross totally resected.

Results The author demonstrates step-by-step technique of microsurgical resection of suprasellar craniopharyngioma. The narrow corridor to deeper structures, intricacies of multiple perforator vessels, and the technique of arachnoid and capsule dissection are the main challenging factors for the gross total resection of craniopharyngioma. The tumor portion which lies under the ipsilateral optic nerve is a blind spot region with a high chance of leaving residual tumor. Mobilization of optic nerve may endanger visual function too. The use of handheld mirror [‘mirror-technique’] helps in better visualization of this blind spot and achieve complete excision.

Conclusions The technical pearls of craniopharyngioma surgery include the optimum utilization of translamina terminalis route, wide opening of the cisterns, meticulous separation of deep perforator vessels, capsular mobilization/traction avoidance, and the use of “mirror-technique” for blind-spot visualization. These surgical strategies help to achieve complete resection without causing neurological deficit.

The link to the video can be found at: <https://youtu.be/9wHJ4AUg50>.

Keywords

- ▶ craniopharyngioma
- ▶ suprasellar
- ▶ resection
- ▶ mirror-technique

Conflict of Interest

None.



www.thieme.com/skullbasevideos

www.thieme.com/jnlsbvideos

received
September 26, 2017
accepted
December 14, 2017
published online
February 14, 2018

DOI <https://doi.org/10.1055/s-0038-1625941>.
ISSN 2193-6331.

© 2018 Georg Thieme Verlag KG
Stuttgart · New York

License terms



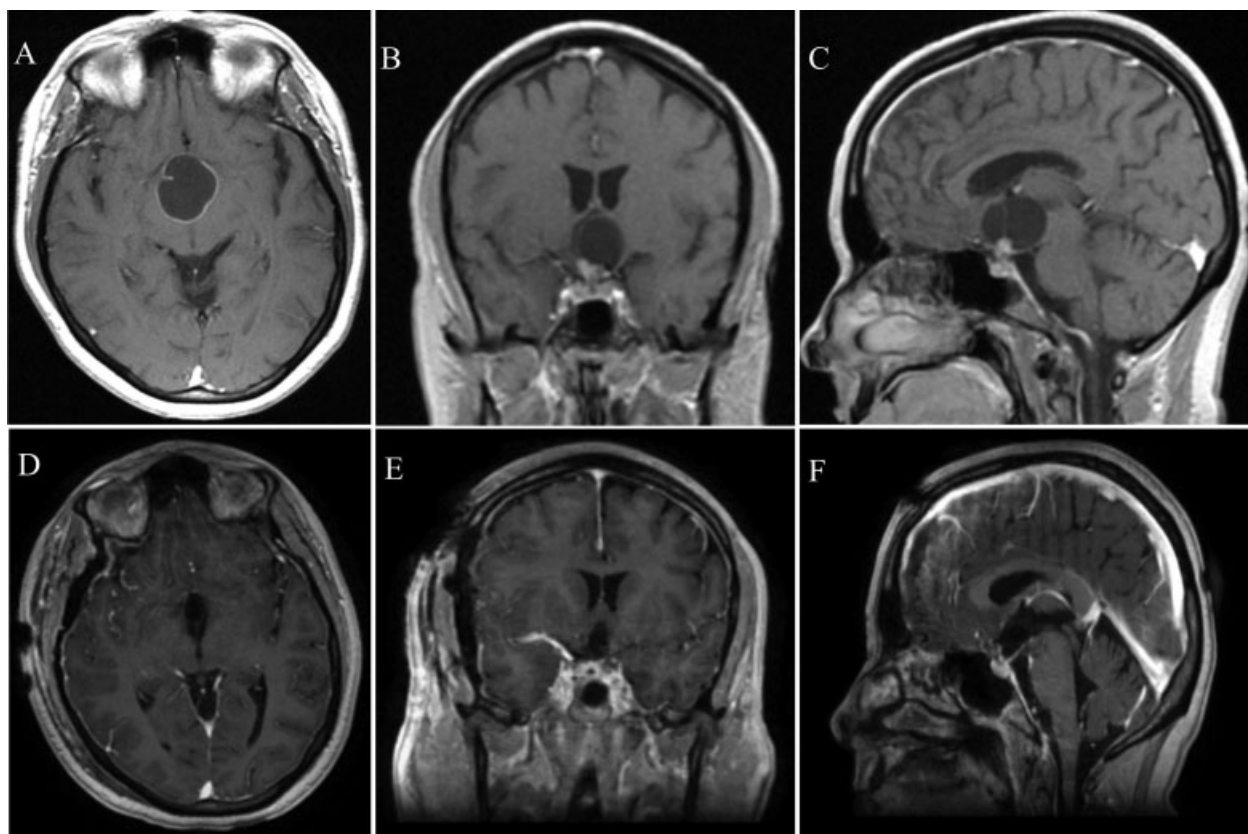


Fig. 1 Radiology panel showing pre-op (A–C) and post-op (D–F) gadolinium magnetic resonance images.

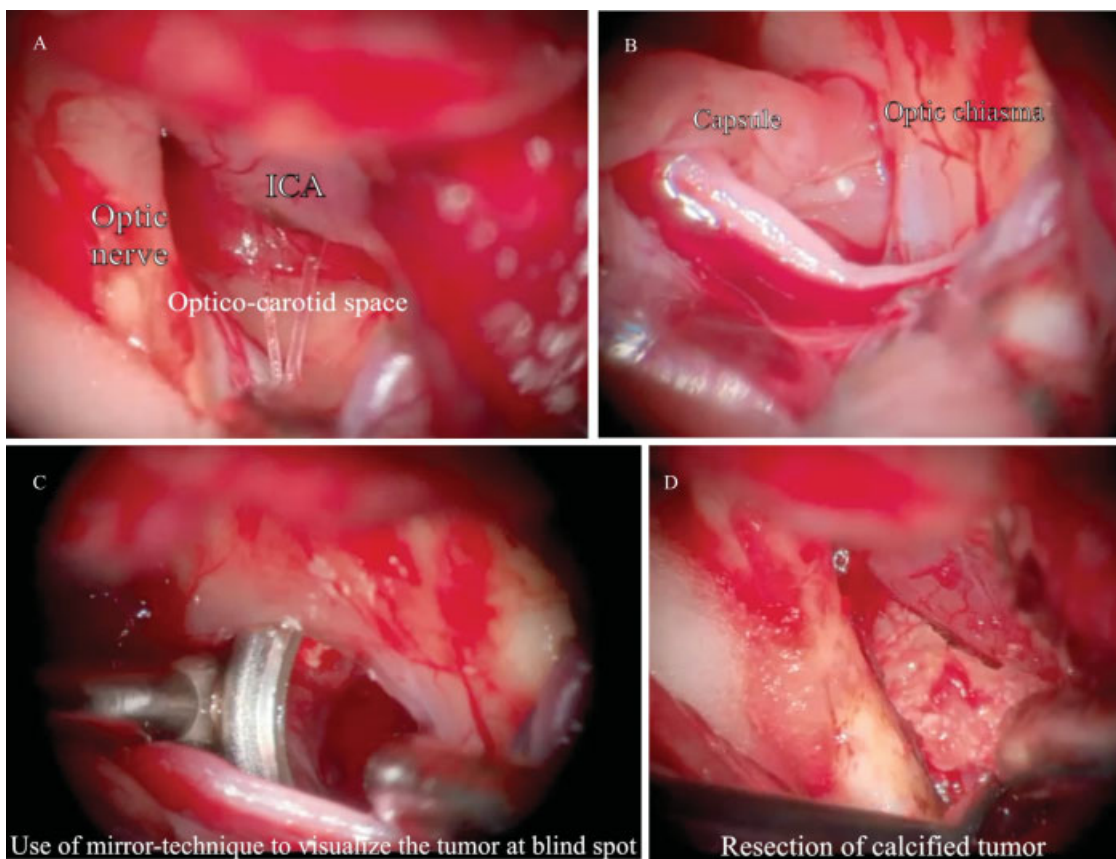


Fig. 2 Panel of intraoperative images of craniopharyngioma surgery. (A) After opening the Sylvian fissure. (B) After excision of the capsule. (C) Use of “mirror-technique” to visualize the blind spot. (D) Excision of the calcified tumor component. ICA, internal carotid artery.