

Endoscopic third ventriculostomy may have long term efficacy in low birth weight preterm newborns

Matheus Fernandes de Oliveira¹, Koshiro Nishikuni², José Marcus Rotta²

Hospital do Servidor Público Estadual de São Paulo, São Paulo, SP, Brazil.

ABSTRACT

Endoscopic third ventriculostomy (ETV) is an established treatment for hydrocephalus and is an alternative method avoiding shunts and its complications. There is still controversy regarding the higher risk of failure in younger infants. NARF was a male preterm newborn of 33 weeks old, with Moebius syndrome and 1,800 grams at birth. Detailed neonatal evaluation revealed hydrocephalus with bilateral ventricular index of 0.6. It was then decided, in spite of prematurity and low birth weight to perform ETV with the age of 25 days, with 1,850 grams. After discharge, follow-up was lost due to family moving to another city. By chance, after seven years child returned to our medical facility and a follow-up magnetic resonance revealed pervious ETV with high flow, demonstrating functionality of ventriculostomy. Patient's age and etiology of hydrocephalus are the most important factors influencing the success rate of ETV. Recently, the age between 6 months and 1 year old became a cutoff below which failure rates are reported to be particularly high and there are dichotomized experience. The results in low birth weight and preterm infants is not widely known and can be poor. Our case illustrates a successful ETV in a both preterm and low birth weight newborn and a satisfactory long term result, reinforcing the security and efficacy of ETV even in newborns.

KEYWORDS

Third ventricle/surgery, infant newborn, neuroendoscopy.

RESUMO

Terceiro-ventriculostomia endoscópica pode ter eficácia em longo prazo em pacientes pré-termos e de baixo peso

A terceiro-ventriculostomia endoscópica (TV) é um tratamento estabelecido para hidrocefalia e é um método alternativo para evitar próteses e suas complicações. Ainda há controvérsia a respeito de seu uso e falha em crianças menores. NARF foi um pré-termo nascido com 33 semanas de gestação, apresentava síndrome de Moebius e 1.800 gramas ao nascer. Avaliação neonatal detalhada revelou hidrocefalia com índice ventricular bilateral de 0,6. Foi submetido à TV com 25 dias de vida e 1.850 gramas. Após alta hospitalar, o seguimento foi perdido, pois a família se mudou de cidade. Após sete anos, a criança retornou ao hospital para tratamento de pneumonia, e a ressonância magnética de controle demonstrou trajeto endoscópico pérvio e com alto fluxo. A idade do paciente e a causa da hidrocefalia são os fatores mais importantes na taxa de sucesso da TV. Recentemente, vários casos vêm sendo publicados de crianças com menos de 1 ano. Os resultados em crianças pré-termo e de baixo peso ainda são desconhecidos. Nosso caso ilustra uma TV com trajeto pérvio sete anos após a cirurgia, denotando bom status em longo prazo.

PALAVRAS-CHAVE

Terceiro ventrículo/cirurgia, recém-nascidos, neuroendoscopia.

1 Resident physician, Department of Neurosurgery, Hospital do Servidor Público Estadual de São Paulo, São Paulo, SP, Brazil.
2 Neurosurgeon, Department of Neurosurgery, Hospital do Servidor Público Estadual de São Paulo, São Paulo, SP, Brazil.

Introduction

Endoscopic third ventriculostomy (ETV) is an established treatment for hydrocephalus and consists in communicating third ventricle with interpeduncular and pre pontine cistern.¹ ETV alone or associated in some patients with choroid plexus cauterization represents an alternative method to manage hydrocephalus avoiding shunts and its complications, and is a very useful technique to manage hydrocephalus specially in cases of aqueductal stenosis, arachnoid cysts, Chiari II malformation, ventricular and subarachnoid hemorrhage, ventriculitis as a consequence of meningitis, neurocysticercosis, and brain tumors causing hydrocephalus, such as midbrain, pineal, tectal plate, third ventricle, thalamic and posterior fossa tumors.^{1,2} It may also be employed instead of shunt revision.^{3,4}

Although endoscopic third ventriculostomy (ETV) is a procedure for the treatment of congenital and acquired hydrocephalus, there is still controversy regarding the higher risk of failure in younger infants compared to older children, especially below 2 years old.^{5,6} There is few experience concerning the success of ETV in low birth weight and preterm newborns and

its long term functionality.^{7,8} Consequently, we illustrate such a case and review the pertinent current literature.

Case description

NARF was born in July 2005. He was the first son of a 31-year-old mother with 32 weeks of gestation. His mother performed prenatal visit at a tertiary hospital, with 4 consultations. Mother sorology was positive for rubella (immunized) and other blood tests were normal. The morphological ultrasonography of second quarter revealed changes of cephalic segment suggestive of nonspecific syndromic disease. After prolonged labor, NARF was born with 1,800 grams and cephalic perimeter of 31 cm. Shortly after birth, had tachycardia (HR > 100 bpm) and respiratory distress hypoactivity, requiring mask ventilation. Detailed neonatal examination showed Pierre Robin sequence, bilateral paralysis of sixth and seventh cranial nerves and stenosis of the larynx causing stridor and short neck. Further evaluation showed hydrocephalus with bilateral ventricular index of 0.6 (Figure 1).

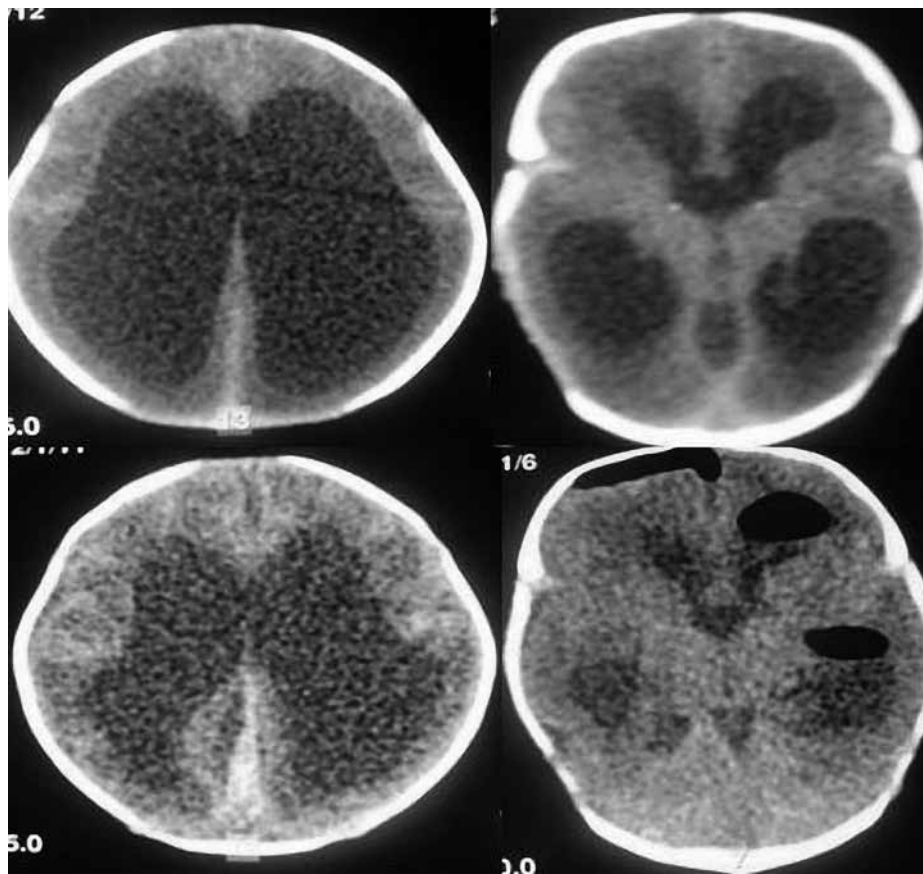


Figure 1 – Skull tomography aspects before (above) and in the post-operative control (below) of the ETV.

Parents had no genetic diseases and were not consanguineous. NARF karyotype was 46 XY with 22ps+ polymorphism, which corresponds to an enlarged satellite of short arm of chromosome 22. Moebius Syndrome was then disclosed. Due to stenosis of larynx, an early tracheostomy was performed and neurosurgical evaluation was required because of a severe supratentorial hydrocephalus with cerebral aqueduct stenosis. It was then decided, in spite of prematurity and low birth weight to perform ETV with the age of 25 days, with 1,850 grams.

Surgery was uneventful and child developed with marked cognitive impairment, with limited language and motor skills, being bedridden and dependent to progenitor, remaining with permanent tracheostomy and recurrent pneumonia.

After discharge, follow-up was lost due to family moving to another city. By chance, after seven years, in the course of new severe pneumonia, child returned to our medical facility and a follow-up magnetic resonance revealed pervious ETV with high flow, surprisingly demonstrating functionality of ventriculostomy (Figure 2).

Discussion

ETV can be considered an alternative to ventricular shunt for the treatment of occlusive hydrocephalus in infants.⁸ However, patient's age and etiology of hydrocephalus are the most important factors influencing the success rate of ETV.⁹⁻¹³

Some previous studies reported the success of ETV in children younger than 2 years old, and the prognosis seemed to be more linked to the etiology of hydrocephalus than the age of surgery.^{6,11} More recently, the age between 6 months to 1 year old seemed to be a cutoff, below which failure rates are reported to be particularly high and there are dichotomized experience and results.^{9,13-15}

Other reports reinforce that there is a clear impact of age on ETV failure rate even excluding etiological factors, with the probability of ETV success gradually increasing during the first months of life, with a median age of 120 days.¹⁰ At last, ETV may be effective in full-term infants while the results in low birth weight and preterm infants may be poor.⁸

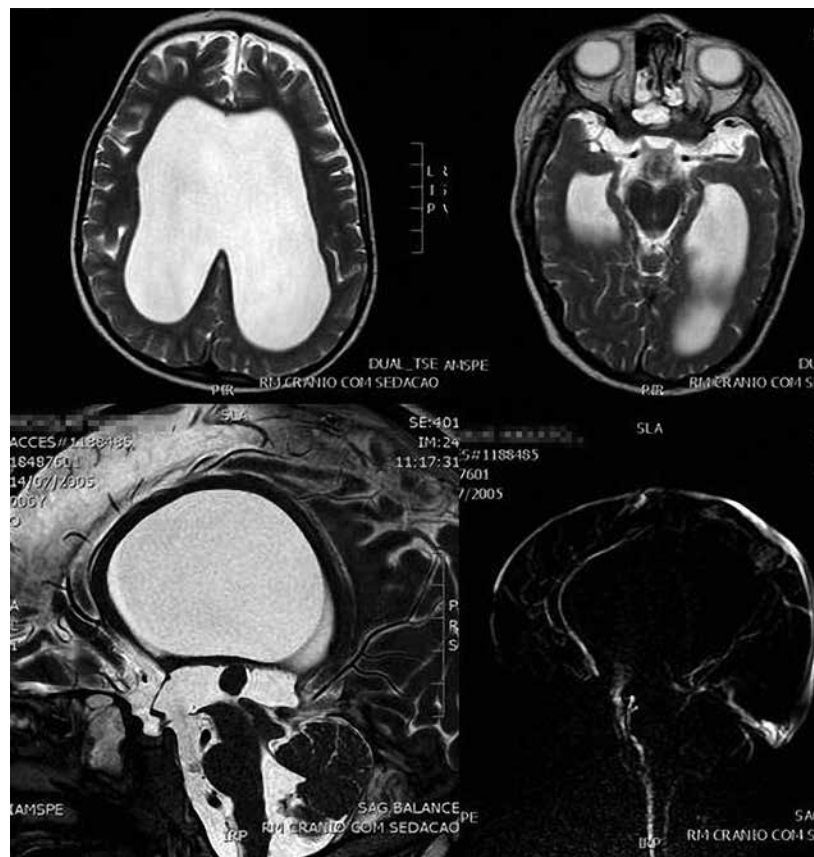


Figure 2 – Current MRI images of the subject revealing hydrocephalus with pervious ventriculostomy with high flow rate seven years after ETV.

Our experience with 14 children below 1 year old (mean age of 5 months) submitted to ETV by several causes revealed a success rate of 64%. From those, three children were below 1 month (mean age of 19 days old) and two of them have successfully proceeded (non-published).

The case presented above highlights the possible applicability of ETV to a case with both preterm and low birth weight features and a satisfactory long term result, reinforcing the security and efficacy of ETV even in newborns. Although the current MRI of NARF is still compatible with hydrocephalus, the functioning ETV ensures the reliability of the procedure, even in a long term basis. Besides, some studies state that functionality of the ventriculostomy and neurocognitive outcome are not always correlated with smaller sized ventricles after ETV.^{16,17}

We agree that age does not present a contraindication for ETV, nor does increase the perioperative risk.⁵ Nevertheless, our own experience is somehow limited and further studies are expected to bring new light into the question.

Although still questionable, the use of ETV appears to be a valid, safe and reliable option for the treatment of hydrocephalus even in preterm and low birth weight newborns.

Conflicts of interest

The authors declare no conflicts of interest.

References

- Bouras T, Sgouros S. Complications of endoscopic third ventriculostomy: a systematic review. *Acta Neurochir Suppl.* 2012;113:149-53.
- Warf BC. Comparison of endoscopic third ventriculostomy alone and combined with choroid plexus cauterization in infants younger than 1 year of age: a prospective study in 550 African children. *J Neurosurg.* 2005;103(Suppl 6):475-81.
- Goyal PK, Meher SK, Singh D, Singh H, Tandon M. Rescue endoscopic third ventriculostomy for repeated shunt blockage. *J Pediatr Neurosci.* 2011;6(1):82-3.
- Bilginer B, Oguz KK, Akalan N. Endoscopic third ventriculostomy for malfunction in previously shunted infants. *Childs Nerv Syst.* 2009;25(6):683-8.
- Fritsch MJ, Kienke S, Ankermann T, Padoin M, Mehdorn HM. Endoscopic third ventriculostomy in infants. *J Neurosurg.* 2005;103(Suppl 1):50-3.
- Etus V, Ceylan S. Success of endoscopic third ventriculostomy in children less than 2 years of age. *Neurosurg Rev.* 2005;28(4):284-8.
- Kadrian D, van Gelder J, Florida D, Jones R, Vonau M, Teo C, et al. Long-term reliability of endoscopic third ventriculostomy. *Neurosurgery.* 2008;62(Suppl 2):614-21.
- Scavarda D, Bednarek N, Litre F, Koch C, Lena G, Morville P, et al. Acquired aqueductal stenosis in preterm infants: an indication for neuroendoscopic third ventriculostomy. *Childs Nerv Syst.* 2003;19(10-11):756-9.
- Ogiwara H, Dipatri AJ Jr, Alden TD, Bowman RM, Tomita T. Endoscopic third ventriculostomy for obstructive hydrocephalus in children younger than 6 months of age. *Childs Nerv Syst.* 2010;26(3):343-7.
- Koch-Wiewrodt D, Wagner W. Success and failure of endoscopic third ventriculostomy in young infants: are there different age distributions? *Childs Nerv Syst.* 2006;22(12):1537-41.
- García LG, López BR, Botella GI, Páez MD, da Rosa SP, Rius F, et al. Endoscopic Third Ventriculostomy Success Score (ETVSS) predicting success in a series of 50 pediatric patients. Are the outcomes of our patients predictable? *Childs Nerv Syst.* 2012;28(8):1157-62.
- Schroeder HW. Success of endoscopic third ventriculostomy: what does really matter? *World Neurosurg.* 2012;78(3-4):233-4.
- Faggin R, Bernardo A, Stieg P, Perilongo G, d'Avella D. Hydrocephalus in infants less than six months of age: effectiveness of endoscopic third ventriculostomy. *Eur J Pediatr Surg.* 2009;19(4):216-9.
- Elgamal EA, El-Dawlatly AA, Murshid WR, El-Watidy SM, Jamjoom ZA. Endoscopic third ventriculostomy for hydrocephalus in children younger than 1 year of age. *Childs Nerv Syst.* 2011;27(1):111-6.
- Costa Val JA, Scaldaferrri PM, Furtado LM, de Souza Baptista G. Third ventriculostomy in infants younger than 1 year old. *Childs Nerv Syst.* 2012;28(8):1233-5.
- Warf B, Ondoma S, Kulkarni A, Donnelly R, Ampeire M, Akona J, et al. Neurocognitive outcome and ventricular volume in children with myelomeningocele treated for hydrocephalus in Uganda. *J Neurosurg Pediatr.* 2009;4(6):564-70.
- Lacy M, Oliveira M, Austria E, Frim MD. Neurocognitive outcome after endoscopic third ventriculocisternostomy in patients with obstructive hydrocephalus. *J Int Neuropsychol Soc.* 2009;15(3):394-8.

Correspondence address

Matheus Fernandes de Oliveira
Av. Pedro de Toledo, 1800, Vila Clementino
04039-004 – São Paulo, SP, Brazil
E-mail: mafernoliv@yahoo.com.br