

Supratentorial primary neuroectodermal tumor (PNET) inside the third ventricle in adult: an rare case report

Tiago de Paiva Cavalcante¹, Siegfried Pimenta Kuehnitzsch², George Santos dos Passos³, José Eduardo Souza Dias Júnior⁴, Tobias Engel Ayer Botrel⁵, Emerson Oliveira Barbosa²

Hospital Universitário Alzira Velano, Alfenas, MG, Brasil.

ABSTRACT

The PNET of CNS are considered malignant undifferentiated tumors, and it represents about 2,8% of all tumors found on infants and teenagers, more rarely found on adults. In the present article will report the case of a patient, male, 23 years-old, with nodular lesion inside the third ventricle, admitted on emergency room with acute intense headache, drowsiness, vomiting and visual clouding, started three days before. Although there have been advances in diagnosis and treatment of PNET in children, few publications were found on the efficiency of available treatment options on adults. In our patient the lesion was completely removed by a anterosuperior interhemispheric transcallosal craniotomy, and subsequently diagnosed as PNET by anatomopathological. Postoperative hydrocephaly was installed and reverted with a ventriculoperitoneal shunt, with clinical and neurological status improvement. The patient died 18 months after diagnosis, due to respiratory hospitalar infection.

KEYWORDS

Neuroectodermal tumors, neuroectodermal tumors primitive, medulloblastoma, cerebral ventricle neoplasms, third ventricle.

RESUMO

Tumor neuroectodérmico primário (PNET) supratentorial no terceiro ventrículo em adulto: um raro relato de caso

Os PNET do SNC são considerados tumores malignos indiferenciados e representam cerca de 2,8% de todos os tumores encontrados em crianças e adolescentes, sendo mais raramente encontrados em adultos. Neste presente artigo, relatamos o caso de um paciente, do sexo masculino, com 23 anos de idade, com lesão nodular dentro do terceiro ventrículo, que foi admitido na emergência com cefaleia intensa e aguda, sonolência, vômitos e turvação visual, iniciados três dias antes da admissão. Embora tenha havido avanços no diagnóstico e tratamento de PNET em crianças, poucas publicações foram encontradas sobre a eficiência de opções de tratamento disponíveis em adultos. No nosso paciente a lesão foi completamente removida por uma craniotomia ântero-transcalosa inter-hemisférica; posteriormente, ele foi diagnosticado como PNET por meio do exame anatomopatológico. A hidrocefalia instalada no pós-operatório foi revertida com uma derivação ventrículo-peritoneal, com melhora do quadro clínico e neurológico. O paciente morreu 18 meses após o diagnóstico, em decorrência de uma infecção hospitalar respiratória.

PALAVRAS-CHAVE

Tumores neuroectodérmicos, tumores neuroectodérmicos primitivos, medulloblastoma, neoplasias do ventrículo cerebral, terceiro ventrículo.

- 1 Neurocirurgião da Fundação de Neurologia e Neurocirurgia do Instituto do Cérebro, Salvador, BA, Brasil, especialista em Neurocirurgia pela Universidade de Rouen, França.
- 2 Neurocirurgião da Fundação de Neurologia e Neurocirurgia do Instituto do Cérebro, Salvador, BA, Brasil.
- 3 Acadêmico de medicina da Escola Bahiana de Medicina e Saúde Pública, Salvador, BA, Brasil.
- 4 Neurocirurgião do Hospital A. C. Camargo, São Paulo, SP, Brasil.
- 5 Oncologista do Hospital Universitário Alzira Velano, Alfenas, MG, Brasil.

Introduction

The primary neuroectodermal tumors (PNET) of central nervous system (CNS) are genetically classified on a subset of heterogenic embryonic tumors with divergent differentiation, and an aggressive behavior like cerebellar medulloblastoma and other medulloblastoma-like tumors located on other sites.^{1,2} They are found mainly in children and adolescents, and more rarely found in adults, and when they occur, are predominant in the brain parenchyma or in the suprasellar region.³ We report an adult patient with a supratentorial PNET, located inside the third ventricle, describing its clinical course, and discussing the anatomic presentation and the immunopathology of this rare case.

Case report

Patient, male, 23 years-old (YO), admitted on emergency room with acute intense headache, drowsiness, with vomiting and visual clouding, started three days ago. No history of fever or seizures. Patient had not family history of brain tumors or known genetic syndromes. Neurological examination showed a patient in Glasgow Coma Scale: 14, drowsy, cranial nerves normal, without motor or sensitive deficit, and deep tendon reflexes was normal. In ocular fundus exam had not signs of papilledema.

The computer tomography (CT) showed a nodular lesion (2,1 x 2,0 cm), inside the 3rd ventricle, with small enhancement after iodinated contrast, interrupting liquoric flow, causing non-communicant hydrocephalus. In the same day was performed a ventriculoscopy to approach the lesion, causing bleeding during the procedure, hindering complete tumor removal. After hemostasis (Figure 1), an external ventricular drainage was inserted, and in a second time it was performed an anterosuperior interhemispheric transcalsal craniotomy, removing the hole lesion (Figure 2). Permanent postoperative hydrocephalus was installed and reverted with a ventriculoperitoneal shunt, with clinical and neurological status improvement (Figure 3).

The CSF analysis obtained during surgical procedure did not detect neoplastic cells. The patient was set free for clinical oncologic following. During oncologic follow and before beginning the complementary adjuvant treatment, it has been installed a subacute paraparesis, grade 3/5 in left lower extremity, grade 4/5 in right lower extremity, with a sensibility loss level at T2 and neurogenic bladder dysfunction, secondary to upper thoracic myelopathy. It was performed a whole vertebral spine Magnetic Resonance Imaging (Figure 4), that showed multiple lesions on cervical, dorsal and lumbar

extramedullary epidural space. It has been performed a decompressive laminectomy, from T4 to T6, with thoracic medullary lesion removal. The anatomopathology result was PNET. Gallium bone scan does not show any abnormalities, as thoracic CT scan as well. Twelve weeks after that (1 year and 6 months after first symptom), the patient died, due to respiratory hospitalar infection.

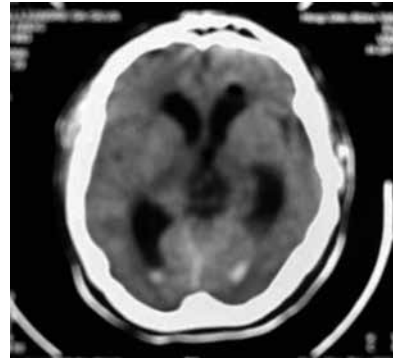


Figure 1 - Head CT without contrast, realized after neuroendoscopy, showing an intraventricular (3rd ventricle) heterogenic nodular lesion, with evidence of intraventricular hemorrhage and frontal pneumocephalus.

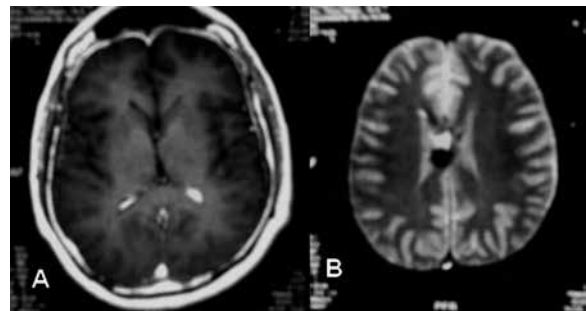


Figure 2 - Head MRI on postoperative, T1 with contrast (A) and T2 (B), showing no evidence of macroscopic intraventricular lesion.

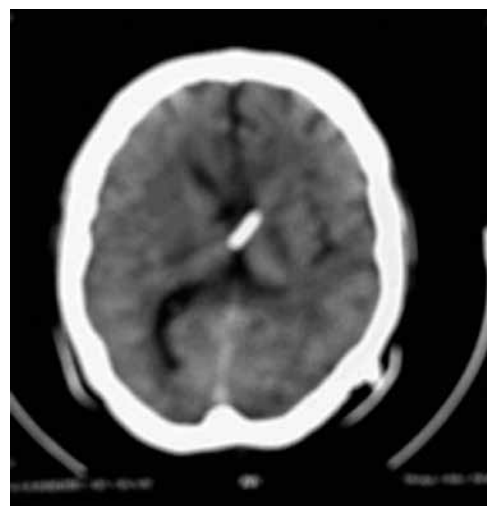


Figure 3 - Control head CT without contrast after ventriculoperitoneal shunt.

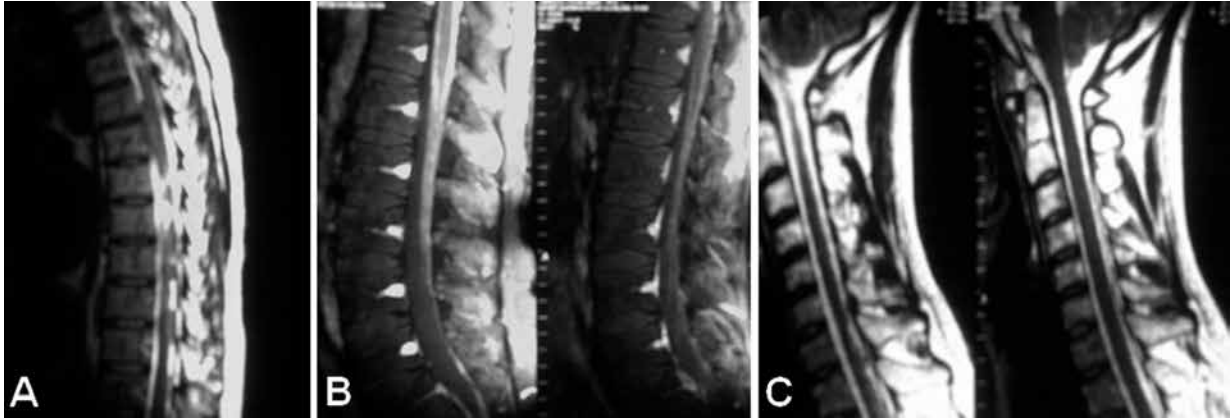


Figure 4 – Sagittal neuroaxial T2 MRI, showing multiple lesions in extramedullary intradural space; cervical (A), thoracic (B) and lumbar (C).

Pathology findings

The result of the anatomopathology was a high-grade malignant neoplasm, characterized by rounded or oval-shaped atypical cells, with evident stained nucleus and conspicuous nucleolus. Atypical mitosis and apoptotic bodies were easily seen. Also, there were areas where tumor cells had been presented more united, with clear and ample cytoplasm (Figure 5). Immunohistochemical study revealed chromogranin A, synaptophysin, CD99 and sparse S-100 presence (Table 1). These findings are consistent with PNET grade IV, according to the classification of the World Health Organization. By the histopathological study of medullary lesion, it has been found an immature neoplasia, characterized by

typical PNET presentation as in the 3rd ventricle tumor (rounded and oval-shaped cells, high-stained, with atypical mitosis, on an infiltrative pattern).

Discussion

The PNET are considered malignant embryonic tumors, with cerebellar medulloblastoma as its most frequent form, about 80%, occurring mostly younger than 15 years old. Medulloblastomas may also occur at other sites, in addition to the cerebellum, without to have histological differences, but with clinical outcome

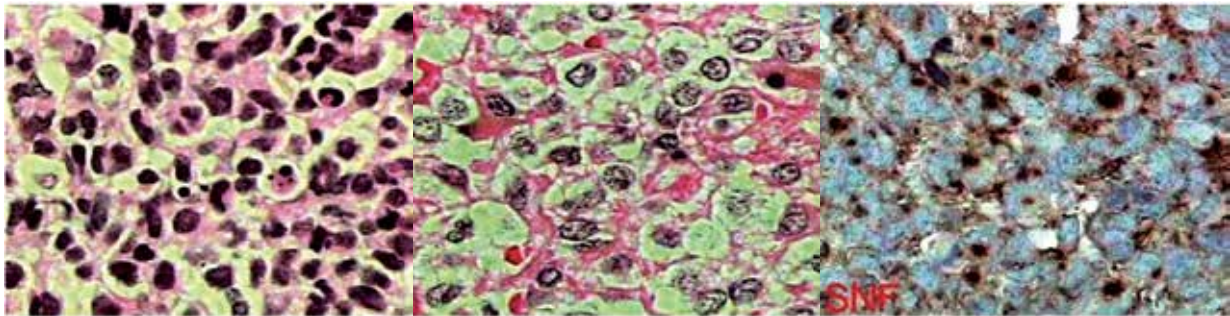


Figure 5 – PNET microscopic images.

Table 1 – PNET immunohistochemical results

Antibodies	Clone	Result	Result
Antigen of cellular proliferation Ki-67	MIB1	Positive	40%
CD99 – Protein MIC-2 (p30/32)	O13	Positive	Focally
Cytokeratin of 40, 48, 50 and 50,6 kDa	AE1/AE3	Negative	
Chromogranin A	DAK-A3	Positive	
Protein S-100	Policlonal	Positive	Focal
Synaptophysin	SP11	Positive	

and response to therapy differently. It is known that supratentorial PNET have a worse prognosis compared to infratentorial location.⁴ In adults the PNET represent only 1% of adult tumors and when they occur the predominant subtype is the desmoplastic.⁵ Balafouta *et al.*,¹ after literature revision, reported in adults only 21 supratentorial PNET cases (29 YO average, ranging 19-57 years/male = female), with high prevalence to temporo-parietal area. Only one case the tumor was located on 3rd ventricle, seemed with our case, presenting also in a 23rd years-old male patient. In a wide search result from PubMed, in the last ten years just four intraventricular PNET cases on adults were reported.^{6,7}

The capacity of differentiation into various neural cell lineages and the anatomical proximity of the suprasellar region and the third ventricle with the sharing of oncogenic potential cells could explain that localization, theory shared by the authors, although by definition the supratentorial PNET are located in the cerebral hemispheres or suprasellar region.

PNET may have cystic formations, but they are commonly solid masses, with variable consistency, and necrosis areas and vascular proliferation. Calcifications and hemorrhages are rare.⁸ Histologically they show a basic cells pattern, undifferentiated, capable to differentiate on glial, neuronal, myogenic and melanocytic lineages and a neuronal arrange with Homer-Wright rosettes-like (neuroblastic rosettes with tumoral nuclei in a circular disposition around typical, but not pathognomonic, cytoplasmic processes, and with high mitosis activity and cellular pleomorphism).^{4,8,9}

Some clinical conditions are strong association with PNET: Gorlin's syndrome (combined neoplasias and malformations including basal cell nevoid carcinoma, odontogenic cysts in the jaw, skeletal abnormalities, ovarian fibroma and early medulloblastomas), Turcot's syndrome (autosomic dominant disorder with colorectal neoplasias, medulloblastomas or glioblastomas) and Li-Fraumeni's syndrome (autosomic dominant disorder characterized by multiple tumors on infants including sarcomas, breast cancer, leukemia and brain tumors) are more associated, generally occurring on infants; normally they have abnormal cariotypes.⁸

On immunohistochemistry, PNET are positive for GFAP (glial fibrillary acid protein), neuron specific enolase, synaptophysin and CD-99. In our patient, we found also positivity chromogranin and S-100. The ultra-structural analysis showed only neurosecretory granules, there was no microtubular or intermediate filaments structures.⁹ The MIB1 index is usually high, showing the high cellularity and differentiation of these kind of tumors. Chromosome 17 short-arm lose (17p13.3) is the most common genetic mutation, and this finding is directly related with worse prognostic, mainly on medulloblastomas. Another genetic *loci*

possibly related to medulloblastoma pathogenesis includes PAX and SSH (*sonic hedgehog* gene) genes, under investigation.⁸ but these alterations or mutations of components of the *sonic hedgehog* pathway are uncommon in supratentorial PNET.⁴

It is already known that rachimedular metastasis is the most common dissemination form these tumors,⁸ also found in the described patient, justifying the screening done for these kind of lesion. Primary intraspinal PNET are rare and when occurs, it also leads to a worse prognostic.

The treatment for adults should not significantly differ from the one for children. However according to the study of Sarkar *et al.*¹⁰ the survival benefit in adults does not seem related with the histological variant (classical *versus* desmoplastic variant) but rather with the age. Although the total resection improve survival and be the first step on PNET handling, staging must include neurospinal MRI and CSF analysis, looking for posterior radiotherapy and adjuvant chemotherapy.¹¹ In despite of standard screening, recommended just in symptomatic patients, and the fact of extraspinal metastasis be uncommon, our patient was submitted to a bone scan with scintigraphy and thorax TC scan, no pathologic findings.

Although radiotherapy seems to improve survival on these patients, the evolution in general is poor, and the majority of patients develop multiple metastasis on CNS, or loco-regional recurrences. And the adjuvant chemotherapy with agents like Vincristine, CCNU and Cisplatin may have benefits comparing to radiotherapy, once that PNET seem to be more radioresistents than medulloblastomas, indicating greater survival rates.¹

The main survival on adults is around 22 months, and it seems to be equivalent on children. In this case report, the patient died 18 months after diagnosis, a little less than the average found on literature.

Although there has been advanced on diagnosis and treatment of PNET in this decade in children, mainly after the huge advance of image techniques and adjuvant treatments, we can find just a few publications approaching the efficiency of available treatment options on adults. Our case report, as the others we found, might be an important substratum to posterior important studied.

Acknowledgment

We are grateful to MD Sergio H. Suzuki, a neurosurgeon at Hospital A. C. Camargo, SP, by the reviewing the article; to MD Eduardo Fuziki, neurosurgeon and former head of the Department of Neurosurgery HUAUV,

MG, by the his collaboration in neurosurgical treatment of the our patient; and MD Otacilio Guimarães, head of the Department of Neurosurgery at HUAV, by the support in preparing this case report.

Conflict of interest disclosure statement

This study presents no conflict of interest and its publication has been authorized by the legal responsible of the patient this case report, through the terms of informed consent.

References

- Balafouta MJ, Kouvaris JR, Miliadou AC, Papacharalampous XN, Kolokouris DV, Kouloulis VE, et al. Primitive neuroectodermal tumour in a 60-year-old man: a case report and literature review. *Br J Radiol.* 2003;76(901):62-5.
- Louis DN, Ohgaki H, Wiestler OD, Cavenee WK, Burger PC, Jouvet A, et al. The 2007 WHO classification of tumours of the central nervous system. *Acta Neuropathol.* 2007;114(2):97-109.
- Gaffney CC, Sloane JP, Bradley NJ, Bloom HJ. Primitive neuroectodermal tumours of the cerebrum. *Pathology and treatment. J Neurooncol.* 1985;3(1):23-33.
- Paulino AC, Melian E. Medulloblastoma and supratentorial primitive neuroectodermal tumors: an institutional experience. *Cancer.* 1999;86(1):142-8.
- Kraus JA, Felsberg J, Tonn JC, Reifenberger G, Pietsch T. Molecular genetic analysis of the TP53, PTEN, CDKN2A, EGFR, CDK4 and MDM2 tumour-associated genes in supratentorial primitive neuroectodermal tumours and glioblastomas of childhood. *Neuropathol Appl Neurobiol.* 2002;28(4):325-33.
- Davis PC, Wichman RD, Takei Y, Hoffman JC Jr. Primary cerebral neuroblastoma: CT and MR findings in 12 cases. *AJR Am J Roentgenol.* 1990;154(4):831-6.
- Pearl GS, Takei Y, Bakay RA, Davis P. Intraventricular primary cerebral neuroblastoma in adults: report of three cases. *Neurosurgery.* 1985;16(6):847-9.
- Ghosh S, Jichici D. Primitive neuroectodermal tumors in central nervous system. *eMedicine Neurology* [serial on the internet] 2006 [Accessed 23 Oct 2011]. Available from: <<http://emedicine.medscape.com/article/1157440-overview>>.
- Masuda K, Yutani C, Akutagawa K, Yamamoto S, Hatsuyama H, Ishibashi-Ueda H, et al. Cerebral primitive neuroectodermal tumor in an adult male. A case report. *Acta Cytol.* 2000;44(6):1050-8.
- Sarkar C, Pramanik P, Karak AK, Mukhopadhyay P, Sharma MC, Singh VP, et al. Are childhood and adult medulloblastomas different? A comparative study of clinicopathological features, proliferation index and apoptotic index. *J Neurooncol.* 2002;59(1):49-61.
- Dunkel I. A trial of radioimmunotherapy, reduced-dose external beam craniospinal radiation therapy with IMRT boost, and chemotherapy for patients with standard-risk medulloblastoma. National Cancer Institute [serial on the internet] last modified July 2009 [Accessed 13 Oct 2011]. Available from: <<http://www.healthtreatment.com/clinical-trial/NCT00058370/>>.

Correspondence address

Tiago de Paiva Cavalcante
Av. Anita Garibaldi, Edifício Garibaldi Prime, 1901, ap. 1106, Federação
40210-750 – Salvador, BA, Brasil
E-mail: tiagoneuro@hotmail.com