

Pelvic Congestion Syndrome: Systematic Review of Treatment Success

Candace L. Brown, MA, MD¹ Magda Rizer, MS, DO² Ryan Alexander, DO³
Emerson E. Sharpe III, MD⁴ Paul J. Rochon, MD⁵

¹Diagnostic and Interventional Radiology, Advanced Radiology Services, Grand Rapids, Michigan

²Department of Radiology, Brigham and Women's Hospital, Boston, Massachusetts

³Department of Interventional Radiology, Massachusetts General Hospital, Boston, Massachusetts

⁴Department of Interventional Radiology, Kaiser Permanente, Denver, Colorado

⁵Division of Vascular and Interventional Radiology, Department of Radiology, University of Colorado Anschutz Medical Campus, Aurora, Colorado

Address for correspondence Candace L. Brown, MA, MD, RPVI, Diagnostic and Interventional Radiology, Advanced Radiology Services, 3264 North Evergreen Dr., Grand Rapids, MI 49525 (e-mail: cbrown@advancedrad.com).

Semin Intervent Radiol 2018;35:35–40

Abstract

Pelvic venous insufficiency is now a well-characterized etiology of pelvic congestion syndrome (PCS). The prevalence of CPP is 15% in females aged 18 to 50 years in the United States and up to 43.4% worldwide. In addition to individual physical, emotional, and quality-of-life implications of CPP, there are profound healthcare and socio-economic expenses with estimated annual direct and indirect costs in the United States in excess of 39 billion dollars. PCS consists of clinical symptoms with concomitant anatomic and physiologic abnormalities originating in venous insufficiency. The etiology of PCS is diverse involving both mechanical and hormonal factors contributing to venous dilatation (>5 mm) and insufficiency. Factors affecting the diagnosis of PCS include variance of causes and clinical presentations of pelvic pain and relatively low sensitivity of noninvasive diagnostic imaging and laparoscopy to identify insufficiency compared with catheter venogram. A systematic review of the literature evaluating patient outcomes following percutaneous treatment of PCS is presented.

Keywords

- ▶ interventional radiology
- ▶ pelvic congestion syndrome
- ▶ pelvic pain
- ▶ venous reflux
- ▶ embolization

Objectives: Upon completion of this article, the reader will be able to describe the etiology of and risk factors contributing to the development of pelvic congestion syndrome. Readers will also be able to discuss the role of endovascular treatment for the disease process.

Accreditation: This activity has been planned and implemented in accordance with the accreditation requirements and policies of the Accreditation Council for Continuing Medical Education (ACCME) through the joint providership of Tufts University School of Medicine (TUSM) and Thieme Medical Publishers, New York. TUSM is accredited by the ACCME to provide continuing medical education for physicians.

Credit: Tufts University School of Medicine designates this journal-based CME activity for a maximum of **1 AMA**

PRA Category 1 Credit™. Physicians should claim only the credit commensurate with the extent of their participation in the activity.

Pelvic venous insufficiency, initially described around 1850s¹ and correlated with pelvic pain in the 1940s to 1950s,^{2–4} is now a well-characterized etiology of pelvic congestion syndrome (PCS).^{1,5–7} Thirty percent to 40% of cases of chronic pelvic pain (CPP)⁸ are associated with PCS.^{2,9} Prevalence of CPP is 15% in females aged 18 to 50 years in the United States¹⁰ and up to 43.4% worldwide.^{11–13} CPP accounts for up to 40% of outpatient gynecologic visits^{14,15} and up to 40% of gynecologic laparoscopies.¹⁶ In addition to individual physical, emotional, and quality-of-life implications¹³ of CPP, there

Issue Theme Women's Health; Guest Editors, Kimi L. Kondo, DO, FSIR and Laura K. Findeiss, MD, FSIR

Copyright © 2018 by Thieme Medical Publishers, Inc., 333 Seventh Avenue, New York, NY 10001, USA.
Tel: +1(212) 584-4662.

DOI <https://doi.org/10.1055/s-0038-1636519>.
ISSN 0739-9529.

are profound healthcare and socioeconomic expenses with estimated annual direct and indirect costs in the United States in excess of 39 billion dollars.^{10,14}

PCS consists of clinical symptoms with concomitant anatomic and physiologic abnormalities originating in venous insufficiency.^{17–19} Clinical symptoms of PCS are consistently reported as chronic, noncyclic pelvic pain or heaviness which is commonly exacerbated by prolonged standing and often occurring in association with dysmenorrhea, dyspareunia, urinary urgency, and perineal or lower extremity varices.^{1,5,7,11,13,17,19–21}

The etiology of PCS is diverse involving both mechanical and hormonal factors contributing to venous dilatation (>5 mm) and insufficiency.⁷ Absence or dysfunction of valves, variant anatomy, venous kinking from uterine malposition, and structural and hormonal changes of parity all correspond to primary PCS,^{1,7,17,20} whereas extrinsic compression corresponds with secondary PCS.¹⁷ Slow flow, inflammation, thrombosis, and insufficiency are thought to be responsible for symptom development as pelvic varices can be present in asymptomatic individuals.^{7,22–25}

Factors affecting the diagnosis of PCS include variance of causes and clinical presentations of pelvic pain^{1,2,20,26,27} and relatively low sensitivity of noninvasive diagnostic imaging and laparoscopy^{6,22} to identify insufficiency compared with catheter venogram. Despite diagnostic challenges, studies show promising results for percutaneous management of PCS delineating it as a treatable syndrome of significant prevalence, morbidity, and systemic costs.^{10,14,15,28} A systematic review of literature evaluating patient outcomes following percutaneous treatment of PCS is presented.

Methods

Data Sources and Study Selection

A systematic review of the MEDLINE database was conducted using PubMed, Ovid SP, and Google Scholar search engines. Methodologic framework followed PRISMA guidelines.²⁹ Search parameters included full text articles published between 1974 and February 2015 using key words “pelvic congestion syndrome,” “pelvic congestion,” “pelvic varices,” and “ovarian vein embolotherapy.” Articles were manually reviewed for treatment of PCS, rendering 25 studies.

Inclusion Criteria

Inclusion criteria are as follows: (1) all studies with intervention for PCS with the method of intervention identified as percutaneous; (2) a minimum sample size of 10 study participants, excluding case reports or small case series; (3) studies that report assessment of patient symptoms pre- and posttreatment. Fourteen studies met inclusion criteria.^{21,22,30–41}

Exclusion Criteria

One study utilizing percutaneous ovarian vein embolization in patients with perineal and lower extremity varix without symptoms of PCS was excluded. Four studies utilizing surgical treatment were excluded. Six studies were excluded for having a sample population of less than 10 patients. Studies

were excluded if the full text was not available. Review articles, letters, and editorials were also excluded.

Quality Assurance and Appraisal

Each eligible study was evaluated for methodology and potential bias.

Data Extraction

Included studies were reviewed to extract the following information from patient subsets undergoing percutaneous treatment for PCS: population size, study design, age, follow-up duration, type of intervention, embolic agent(s), and outcomes via change in pre- and posttreatment self-reported symptoms. Additional information including reported complications, symptom resolution, symptom type, parity, and postprocedure length of stay are reported according to the subset of studies providing these data points. Applicable PRISMA guidelines were followed in data collection, analysis, and reporting.

Cumulative Data Synthesis

Detailed description of extracted data was tabulated. Summary results are reported as proportions, medians (M) with corresponding interquartile range (IQR_{Q3–Q1}), or weighted means (average_w), as applicable.

Limitations of Review

Studies meeting inclusion criteria for review are heterogeneous in method of treatment, endpoints, and in study populations and size precluding meta-analysis. Included studies consist of case series study design (lacking control groups). Use of subjective patient reporting to determine clinical success invites recall and interviewer bias. Nonetheless, there exist certain characteristics of patients, pitfalls, and percutaneous treatment, which are consistently described in the literature.

Results

Study Demographics

Fourteen studies of percutaneous treatment for PCS yield a total of 828 patients and 994 unique percutaneous interventions: 979 for initial sclerosis or embolization of ovarian or internal iliac veins (accounting for staged procedures),^{21,22,30–41} 14 repeat interventions for recurrent symptoms,^{30,34,40,41} and 1 repeat intervention for technical failure at initial intervention.⁴¹

Indication for intervention requires symptom(s) of PCS in combination with signs of pelvic venous incompetence on catheter-based venography.^{21,22,30–41}

Average_w patient age is 40 years (range: 16–72 years).^{21,22,30–41}

Average_w follow-up is 36.1 months (range: 1–288 months).^{21,22,30–41}

Postprocedure length of stay ranges from 4 to 24 hours with procedures occurring in the outpatient setting^{30,32,33,35,40,41} or overnight observation.^{21,22,37,40}

Reported complications range from 0.85 to 10% (M: 4.95, IQR_{Q3–Q1}: 5.4) and were minor without sequelae: 6 cases of vessel perforation, 20 cases of nontarget embolization, 6

groin hematomas, 1 arrhythmias, 1 internal iliac venous thrombus, and 2 contrast reactions among 944 unique procedures.^{21,22,31,32,35-41}

Clinical Outcomes

Patients reporting improvement of clinical symptoms following percutaneous treatment ranges from 68.3 to 100% (M: 95.1, IQR_{Q3-Q1}: 17.4).^{21,22,30-41} Of 828 patients, 762 (92%) patients complete respective study follow-up endpoints.^{21,22,30-41} Following intervention, 697 (range: 68.3-100%, M: 95.1, IQR_{Q3-Q1}: 17.4) report some degree of symptomatic improvement, 57 (range: 0-31.7%, M: 4.6, IQR_{Q3-Q1}: 14.2) report no symptom change, and 6 (range: 0-4.1%, M: 0, IQR_{Q3-Q1}: 0) report worsening of symptoms.^{21,22,30-41} Of studies reporting resolution, 191 of 488 (range: 7.5-87.5%, M: 58.2, IQR_{Q3-Q1}: 27.1) report complete symptom resolution at follow-up.^{21,30-34,37,41}

Of patients initially reporting symptom improvement, 18 (range: 0-18.2%, M: 2.1, IQR_{Q3-Q1}: 5.4) report symptom recurrence occurring over a range from 4 to 12 months.^{21,22,30-32,34-36,38-41}

Repeat Interventions of Percutaneous and Surgical Natures

Fourteen repeat percutaneous interventions were performed for recurrent symptoms: 1 case recurring 5 years after embolization following multiple pregnancies;³⁴ 11 cases recurring in venous territories not originally embolized;^{30,40,41} and 2 cases recurring in previously treated territories.³⁰ Follow-up of repeat interventions in these patients report improved symptoms for the patient experiencing recurrence following pregnancies³⁴ and in two of five patients retreated for new or persistent varices.³⁰

One study provides follow-up of nine patients undergoing hysterectomy due to lack of symptomatic improvement of pelvic pain following percutaneous treatment: hysterectomy yielded no additional symptom improvement.³¹

Kim et al²² reported a subset of 25 patients who failed to experience improvement of pelvic pain following hysterectomy, all 25 report symptomatic improvement following percutaneous treatment.

Percutaneous Techniques

Clinical improvement following coil embolization ranges from 82.1 to 100% (M: 95.8, IQR_{Q3-Q1}: 6.1) in 473 patients.^{21,31,34,35,37-39} Clinical improvement following embolization with glue and lipiodized oil ranges from 68.3 to 73.7% (M: 71, IQR_{Q3-Q1}: 5.4) in 60 patients.^{30,32} A single study of isolated ovarian vein sclerosis reports 100% clinical success in 33 patients.³³ Clinical success of studies involving mixed percutaneous methods including sclerosant with coil and/or Gelfoam embolization ranges from 83 to 100% (M: 94.9, IQR_{Q3-Q1}: 17.1) in 196 patients^{22,36,40,41} (► **Figs. 1-3**).

Territory of Intervention

Six studies report treatment of ovarian veins with clinical improvement in 198 of 228 patients ranging from 68.3 to 100% (M: 91.1, IQR_{Q3-Q1}: 29).³⁰⁻³⁵ Five studies report treat-

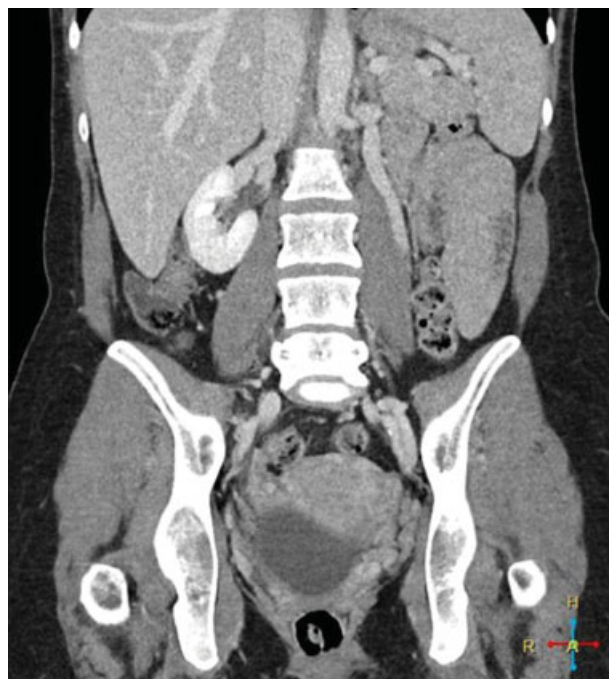


Fig. 1 Coronal CT venogram with dilated left gonadal vein.

ment of ovarian and internal iliac veins with clinical improvement in 334 of 348 patients ranging from 93.9 to 100% (M: 95.8, IQR_{Q3-Q1}: 5.9).^{21,36-39} Three studies report treatment of ovarian, internal iliac, and additional pelvic varices with clinical improvement in 165 of 186 patients ranging from 83 to 96% (M: 93.9, IQR_{Q3-Q1}: 13.4).^{22,40,41}

Studies specify 483 bilateral and 290 unilateral ovarian vein interventions, almost invariably left sided.^{21,22,30-35,37-40}

Variceal Diameter

The diameter of ovarian veins based on catheter venogram ranges from 6.2 to 14.6 mm; no correlation is identified comparing diameter to symptom improvement.^{21,31-35}

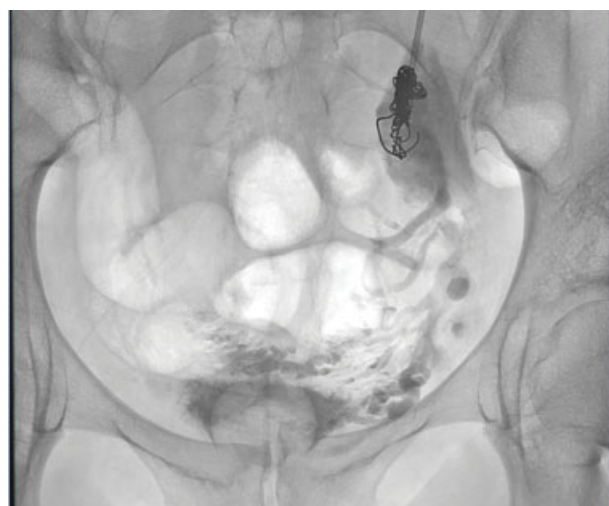

Fig. 2 Fluoroscopic view of the abdomen and pelvis demonstrates sodium tetradecyl sulfate and contrast in the deep pelvic varices with a coil in the left gonadal vein.

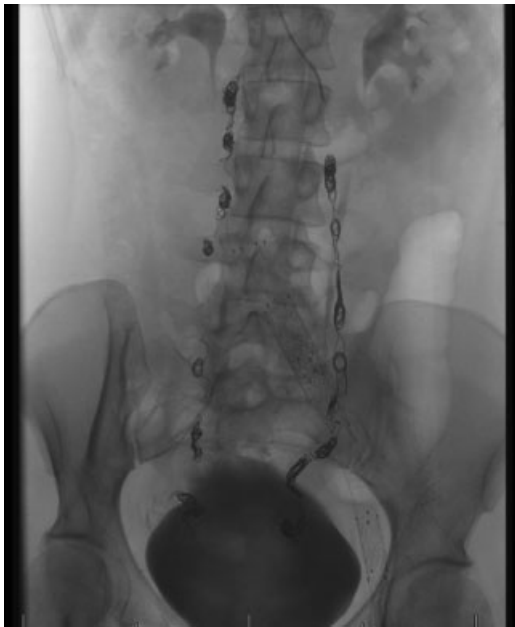

Fig. 3 Fluoroscopic view of the abdomen and pelvis demonstrates coils in the bilateral gonadal veins.

Patient Assessment

Studies utilize various endpoints to assess clinical success including patient report of symptom improvement,^{30,31} pre- and posttreatment questionnaires,^{32–34} decrease in variceal size,^{30,33} and a VAS.^{21,22,35–41}

Parity

Of 655 patients in studies reporting parity, 86.6% were parous^{21,22,30–32,35–38} having an average_w parity of 2.6 (range: 0–8).^{21,30–32,35–39,41} Kwon et al³⁶ reported no statistically significant difference between parity (P1 through P5) and outcomes. Maleux et al³² reported no statistically significant difference in outcomes between multiparous and uniparous patients. Five studies include nulliparous patients,^{22,30,35,39,41} of which two studies having 21%³⁰ and 63%²² nulliparous patients report no significant differences in outcomes between parous and nulliparous subpopulations.

Symptom Breakdown

From a total of 266 patients, 75.2% of patients report improvement of dysmenorrhea.^{21,37} From a total of 210 patients, 85.2% of patients report improvement of dyspareunia.^{21,30,32–34,37,41} From a total of 149 patients, 98.7% of patients report improvement of urinary urgency.^{21,32,33,37}

Discussion

Efficacy of Percutaneous Treatment in PCS

Percutaneous embolization for PCS is an effective method of treatment having a high percentage of symptom improvement (reported in 697 of 762 patients).^{21,22,30–41} Studies utilizing a VAS as a quantitative measure of symptom improvement⁴² report statistically significant overall symptom improvement comparing posttreatment and pretreat-

ment values with an average_w decrease of 5.7 within 0 to 10 scale.^{21,22,35–41}

Safety

Procedural complications in percutaneous treatment of PCS are minor and uncommon, reported in 36 of 944 procedures.^{21,22,31,32,35–41} Reports of worsening symptoms after percutaneous treatment for PCS are rare, reported in 6 of 710 patients.^{22,31} No additional treatment-related sequelae were identified.

To date, no studies specifically address attempted conception following percutaneous treatment for PCS. Galkin et al reported a series of ovarian varix embolization to treat infertility, with improvement of clinical symptoms, laboratory tests, and 14 of 19 patients conceiving.⁴³ Capasso et al³¹ reported no significant change in menstrual cycle posttreatment. Kim et al²² reported no change in pre- and postembolization levels of follicle-stimulating hormone, luteinizing hormone, or estradiol. Notably, percutaneous gonadal vein variceal embolization is recommended as treatment for both pain and infertility in the male population.^{44,45}

Interval of Clinical Improvement

Studies reporting intervals of symptom change demonstrate improvement in the early postprocedural period ranging from 1 day to 3 months.^{30–32,35,38,40} A large-scale study with 5-year follow-up²¹ reports greatest decreases in VAS scores occurring within the first 6 months. Moreover, time frames may be falsely elevated reflecting documentation at the time of follow-up rather than time to symptom improvement.

Similarly, studies report little to no increase of symptom improvement beyond the early postprocedural period. Pieri et al³⁴ reported changes in symptom levels and characteristics at 1-month follow-up, but no further changes at subsequent follow-up intervals. Kwon et al³⁶ reported that for patients without symptom improvement during the initial 3 months, no improvement was experienced within the follow-up period. Chung and Huh³⁵ and Nasser et al⁴¹ reported average VAS scores for follow-up intervals, showing marked improvement at 1-month follow-up with mild gradual improvement at 3, 6, and 12-month intervals.

Recurrence, Reintervention, and Predictors

Percutaneous intervention for PCS incurs minimal reported symptom recurrence,^{21,22,30–41} which may be artificially low compared with clinical practice given time frame of and reporting within studies. The majority of reported symptom recurrence occurs in territories not previously embolized.^{30,40,41}

Repeat percutaneous intervention is sparsely reported with mixed results.^{30,34,40,41}

Percutaneous treatment has been reported effective when prior interventions including hysterectomy²² and medication²⁹ have failed.

No consistent predictors of outcome following percutaneous intervention for PCS are identified within the studies. Specifically, parity, varix size, symptom severity, or territory embolized were not found to be independent predictors of outcome.

Percutaneous Technique

Symptom improvement is similar between coil embolization, sclerosant, and combined use of agents, whereas that of glue and lipidized oil is relatively lower.

Treatment Territory

Study techniques vary in territory and laterality of embolization, without accounting for different combinations of territories in reported results. There are divergent opinions as to whether limited^{30,31,39,41} or complete embolization^{21,40} should be performed. Combination of ovarian, internal iliac, and additional variceal intervention^{22,40,41} has a range of clinical success lower than that of ovarian and iliac interventions,^{21,36–39} though median values are similar between these groups and isolated ovarian intervention.^{30–35}

Studies reporting outcomes analysis comparing unilateral and bilateral embolization^{30,32} report no statistically significant difference. Capasso et al³¹ noted that 76.9% of patients treated with left ovarian vein embolization did not develop right ovarian varices at follow-up.

Pitfalls of Diagnosis

Patients with PCS are generally described as multiparous and premenopausal with reports of symptom resolution occurring at menopause.^{19,31,32} Five studies include nulliparous patients^{22,30,35,39,41} and no statistical difference in outcomes is identified based on number of pregnancies or between parous and nulliparous patients.^{22,30–32} Eight studies include patients aged 56 years and older^{21,30–33,39–41} exceeding an average age of postmenopausal patients as determined by a large-scale population study.⁴⁶ Nulliparous and postmenopausal patients present with PCS and these populations should not be overlooked.

Imaging findings of PCS are well described by Knuttinen et al including dilated ovarian, pelvic, arcuate, perineal, and lower extremity veins demonstrating slow flow, stasis, or reflux.¹⁸ However, studies report insensitivity of noninvasive imaging compared with catheter venogram. Cross-sectional imaging has a wide variance of reported sensitivities for detection of pelvic varices including, 12.5% on CT²² and 58.6 to 100% on MRI,^{18,22,47,48} related to venous drainage with supine positioning and lack of dynamic imaging sequences.^{1,19,20,40} Ultrasound offers advantages in dynamic and positional image acquisition allowing demonstration of venous reflux with upright positioning and Valsalva maneuver,⁴⁹ yet studies report insensitivity⁵⁰ compared with catheter venography with ultrasound identification of varices in as little as 53%⁵¹ and 20%²² of cases. Diagnostic laparoscopy underestimates the presence and number of varices as both positioning and insufflation pressure facilitate drainage or effacement of varices^{40,50} with reports of pelvic variceal identification ranging from less than 20%⁶ to 40%.²²

Adding to diagnostic confusion, ovarian vein dilatation, though associated⁵² and predictive,¹⁸ is not synonymous with venous incompetence or symptoms.^{22–25}

Conclusion

PCS is a prevalent and treatable condition for which percutaneous treatment is safe and effective. Thorough clinical and imaging evaluation by a provider who is familiar with the associated diagnostic pitfalls is imperative, as the indication for treatment of PCS requires both clinical symptom(s) and associated venous incompetence. Catheter-directed venography demonstrates improved sensitivity in detecting venous insufficiency compared with noninvasive imaging, as well as the benefit of simultaneous diagnosis and treatment, and a high rate of success in improving clinical symptoms.

References

- Ganeshan A, Upponi S, Hon LQ, Uthappa MC, Warakaulle DR, Uberoi R. Chronic pelvic pain due to pelvic congestion syndrome: the role of diagnostic and interventional radiology. *Cardiovasc Intervent Radiol* 2007;30(06):1105–1111
- Duncan CH, Taylor HC Jr. A psychosomatic study of pelvic congestion. *Am J Obstet Gynecol* 1952;64(01):1–12
- Taylor HC Jr. Vascular congestion and hyperemia; their effect on function and structure in the female reproductive organs; the clinical aspects of the congestion-fibrosis syndrome. *Am J Obstet Gynecol* 1949;57(04):637–653
- Taylor HC. Pelvic pain based on a vascular and autonomic nervous system disorder. *Am J Obstet Gynecol* 1954;67(06):1177–1196
- Beard RW, Reginald PW, Wadsworth J. Clinical features of women with chronic lower abdominal pain and pelvic congestion. *Br J Obstet Gynaecol* 1988;95(02):153–161
- Beard RW, Highman JH, Pearce S, Reginald PW. Diagnosis of pelvic varicosities in women with chronic pelvic pain. *Lancet* 1984;2(8409):946–949
- Phillips D, Deipolyi AR, Hesketh RL, Midia M, Oklu R. Pelvic congestion syndrome: etiology of pain, diagnosis, and clinical management. *J Vasc Interv Radiol* 2014;25(05):725–733
- Beard RW, Kennedy RG, Gangar KF, et al. Bilateral oophorectomy and hysterectomy in the treatment of intractable pelvic pain associated with pelvic congestion. *Br J Obstet Gynaecol* 1991;98(10):988–992
- Soysal ME, Soysal S, Vicdan K, Ozer S. A randomized controlled trial of goserelin and medroxyprogesterone acetate in the treatment of pelvic congestion. *Hum Reprod* 2001;16(05):931–939
- Mathias SD, Kuppermann M, Liberman RF, Lipschutz RC, Steege JF. Chronic pelvic pain: prevalence, health-related quality of life, and economic correlates. *Obstet Gynecol* 1996;87(03):321–327
- Latthe P, Latthe M, Say L, Gülmezoglu M, Khan KS. WHO systematic review of prevalence of chronic pelvic pain: a neglected reproductive health morbidity. *BMC Public Health* 2006;6:177–183
- Ahangari A. Prevalence of chronic pelvic pain among women: an updated review. *Pain Physician* 2014;17(02):E141–E147
- Zondervan KT, Yudkin PL, Vessey MP, et al. The community prevalence of chronic pelvic pain in women and associated illness behaviour. *Br J Gen Pract* 2001;51(468):541–547
- Kuligowska E, Deeds L III, Lu K III. Pelvic pain: overlooked and underdiagnosed gynecologic conditions. *Radiographics* 2005;25(01):3–20
- Klock S. Psychosomatic issues in obstetrics and gynecology. In: Ryan KJ, Barbieri RL, eds. *Gynecology Principles and Practice*. St. Louis: Mosby; 1995:399–402
- Howard FM. The role of laparoscopy in chronic pelvic pain: promise and pitfalls. *Obstet Gynecol Surv* 1993;48(06):357–387
- Durham JD, Machan L. Pelvic congestion syndrome. *Semin Intervent Radiol* 2013;30(04):372–380

- 18 Knuttinen MG, Xie K, Jani A, Palumbo A, Carrillo T, Mar W. Pelvic venous insufficiency: imaging diagnosis, treatment approaches, and therapeutic issues. *AJR Am J Roentgenol* 2015;204(02):448–458
- 19 Koo S, Fan CM. Pelvic congestion syndrome and pelvic varicosities. *Tech Vasc Interv Radiol* 2014;17(02):90–95
- 20 Ignacio EA, Dua R, Sarin S, et al. Pelvic congestion syndrome: diagnosis and treatment. *Semin Intervent Radiol* 2008;25(04):361–368
- 21 Laborda A, Medrano J, de Blas I, Urriaga I, Carnevale FC, de Gregorio MA. Endovascular treatment of pelvic congestion syndrome: visual analog scale (VAS) long-term follow-up clinical evaluation in 202 patients. *Cardiovasc Intervent Radiol* 2013;36(04):1006–1014
- 22 Kim HS, Malhotra AD, Rowe PC, Lee JM, Venbrux AC. Embolotherapy for pelvic congestion syndrome: long-term results. *J Vasc Interv Radiol* 2006;17(2, Pt 1):289–297
- 23 Dos Santos SJ, Holdstock JM, Harrison CC, Lopez AJ, Whiteley MS. Ovarian vein diameter cannot be used as an indicator of ovarian venous reflux. *Eur J Vasc Endovasc Surg* 2015;49(01):90–94
- 24 Nascimento AB, Mitchell DG, Holland G. Ovarian veins: magnetic resonance imaging findings in an asymptomatic population. *J Magn Reson Imaging* 2002;15(05):551–556
- 25 Rozenblit AM, Ricci ZJ, Tuvia J, Amis ES Jr. Incompetent and dilated ovarian veins: a common CT finding in asymptomatic parous women. *AJR Am J Roentgenol* 2001;176(01):119–122
- 26 Latthe P, Mignini L, Gray R, Hills R, Khan K. Factors predisposing women to chronic pelvic pain: systematic review. *BMJ* 2006;332(7544):749–755
- 27 Stones RW, Price C. Health services for women with chronic pelvic pain. *J R Soc Med* 2002;95(11):531–535
- 28 Cheong YC, Smotra G, Williams AC. Non-surgical interventions for the management of chronic pelvic pain. *Cochrane Database Syst Rev* 2014;3(03):CD008797
- 29 Moher D, Liberati A, Tetzlaff J, Altman DG; PRISMA Group. Preferred reporting items for systematic reviews and meta-analyses: the PRISMA statement. *PLoS Med* 2009;6(07):e1000097
- 30 Meneses L, Fava M, Diaz P, et al. Embolization of incompetent pelvic veins for the treatment of recurrent varicose veins in lower limbs and pelvic congestion syndrome. *Cardiovasc Intervent Radiol* 2013;36(01):128–132
- 31 Capasso P, Simons C, Trotteur G, Dondelinger RF, Henroteaux D, Gaspard U. Treatment of symptomatic pelvic varices by ovarian vein embolization. *Cardiovasc Intervent Radiol* 1997;20(02):107–111
- 32 Maleux G, Stockx L, Wilms G, Marchal G. Ovarian vein embolization for the treatment of pelvic congestion syndrome: long-term technical and clinical results. *J Vasc Interv Radiol* 2000;11(07):859–864
- 33 Venbrux AC, Chang AH, Kim HS, et al. Pelvic congestion syndrome (pelvic venous incompetence): impact of ovarian and internal iliac vein embolotherapy on menstrual cycle and chronic pelvic pain. *J Vasc Interv Radiol* 2002;13(2, Pt 1):171–178
- 34 Pieri S, Agresti P, Morucci M, de' Medici L. Percutaneous treatment of pelvic congestion syndrome. *Radiol Med (Torino)* 2003;105(1-2):76–82
- 35 Chung MH, Huh CY. Comparison of treatments for pelvic congestion syndrome. *Tohoku J Exp Med* 2003;201(03):131–138
- 36 Kwon SH, Oh JH, Ko KR, Park HC, Huh JY. Transcatheter ovarian vein embolization using coils for the treatment of pelvic congestion syndrome. *Cardiovasc Intervent Radiol* 2007;30(04):655–661
- 37 Creton D, Hennequin L, Kohler F, Allaert FA. Embolisation of symptomatic pelvic veins in women presenting with non-saphenous varicose veins of pelvic origin - three-year follow-up. *Eur J Vasc Endovasc Surg* 2007;34(01):112–117
- 38 Asciutto G, Asciutto KC, Mumme A, Geier B. Pelvic venous incompetence: reflux patterns and treatment results. *Eur J Vasc Endovasc Surg* 2009;38(03):381–386
- 39 Hocquet A, Le Bras Y, Balian E, et al. Evaluation of the efficacy of endovascular treatment of pelvic congestion syndrome. *Diagn Interv Imaging* 2014;95(03):301–306
- 40 Nemark AI, Shelkovich NV. Endovascular treatment of persistent dysuria and chronic pelvic pain in women with pelvic varicose veins [in Russian]. *Urologiia* 2012;4(04):20–24
- 41 Nasser F, Cavalcante RN, Affonso BB, Messina ML, Carnevale FC, de Gregorio MA. Safety, efficacy, and prognostic factors in endovascular treatment of pelvic congestion syndrome. *Int J Gynaecol Obstet* 2014;125(01):65–68
- 42 Grossman SA, Sheidler VR, McGuire DB, Geer C, Santor D, Piantadosi S. A comparison of the Hopkins Pain Rating Instrument with standard visual analogue and verbal descriptor scales in patients with cancer pain. *J Pain Symptom Manage* 1992;7(04):196–203
- 43 Galkin EV, Grakova LS, Naumova EB. Roentgeno-endovascular surgery of hypofunctional ovaries in varicosities of the ovarian veins [in Russian]. *Vestn Rentgenol Radiol* 1991;5(05):51–59
- 44 Bittles MA, Hoffer EK. Gonadal vein embolization: treatment of varicocele and pelvic congestion syndrome. *Semin Intervent Radiol* 2008;25(03):261–270
- 45 Practice Committee of the American Society for Reproductive Medicine. Report on varicocele and infertility. *Fertil Steril* 2006;86(05, Suppl 1):S93–S95
- 46 Triebner K, Johannessen A, Puggini L, et al. Menopause as a predictor of new-onset asthma: a longitudinal Northern European population study. *J Allergy Clin Immunol* 2015;6749(15):1243–1249
- 47 Asciutto G, Mumme A, Marpe B, Köster O, Asciutto KC, Geier B. MR venography in the detection of pelvic venous congestion. *Eur J Vasc Endovasc Surg* 2008;36(04):491–496
- 48 Yang DM, Kim HC, Nam DH, Jahng GH, Huh CY, Lim JW. Time-resolved MR angiography for detecting and grading ovarian venous reflux: comparison with conventional venography. *Br J Radiol* 2012;85(1014):e117–e122
- 49 Giacchetto C, Cotroneo GB, Marincolo F, Cammisuli F, Caruso G, Catizone F. Ovarian varicocele: ultrasonic and phlebographic evaluation. *J Clin Ultrasound* 1990;18(07):551–555
- 50 Little AD, Davies AH. Pelvic congestion syndrome: chronic pelvic pain caused by ovarian and internal iliac varices. *Phlebology* 2007;22(03):100–104
- 51 Park SJ, Lim JW, Ko YT, et al. Diagnosis of pelvic congestion syndrome using transabdominal and transvaginal sonography. *AJR Am J Roentgenol* 2004;182(03):683–688
- 52 Belenky A, Bartal G, Atar E, Cohen M, Bachar GN. Ovarian varices in healthy female kidney donors: incidence, morbidity, and clinical outcome. *AJR Am J Roentgenol* 2002;179(03):625–627