**W. L. Nowinski**

Medical Imaging Lab
Kent Ridge Digital Labs
Singapore

# Review

# *Model-enhanced neuroimaging: clinical, research, and educational applications*

## 1. Introduction

During the past 30 years medical imaging has been propelled by advances in the computational, biomedical, and physical sciences. Modern medical imaging technologies offer unprecedented views into the human body's structure, function, metabolism, hemodynamics, and pathology. Our ability to generate images is much greater than our ability to understand and interpret them. Processing of medical images involves image acquisition, display, analysis, and interpretation. Deformable body models along with warping techniques facilitate analysis of medical images. Deformable brain atlases in particular are useful for analysis and interpretation of brain scans.

Medical imaging covers numerous areas, including image acquisition and formation, image processing and enhancement, segmentation, analysis, registration, visualization, modeling, compression, picture archiving and communication systems, computer-aided diagnosis, computer-aided surgery, and on-line medical imaging. We briefly review some of them from the point of view of neuroimaging, and focus on four groups of model-enhanced applications for education, medical research, diagnosis, and treatment. We illustrate these applications by the systems and technologies developed in our lab.

## 2. Medical imaging

Medical imaging has come a long way since 1895, when Roentgen discovered X-rays and produced an image of the bones of his wife's hand. Today's medical imaging modalities are based not only on X-rays but also on a variety of other energy sources including ultrasound, nuclear magnetic resonance, radionuclides, electrons, light, and lasers. The images obtained are characterized by their spatial, contrast, and temporal resolutions. Medical imaging covers a wide range of areas. We briefly review image acquisition, segmentation, registration, visualization, and modelling from the point of view of neuroimaging.

### 2.1 Image acquisition

Medical imaging modalities, such as X-rays, Computed Tomography (CT), Magnetic Resonance Imaging (MRI), ultrasound (US), Single Proton Emission CT (SPECT), and Positron Emission Tomography (PET) provide views of human anatomy, pathology, and function. Conventional X-ray images are still the most commonly used. An X-ray is a projection image showing the distribution of tissue attenuation of X-rays passing through the body. CT images show a spatial distribution of the tissue attenuation coefficients reconstructed mathematically from multiple X-ray projections. Conventional CT acquires projections in parallel axial planes. Spiral CT allows the projections to be acquired along a spiral trajectory providing high-resolution volumetric images. X-rays and CT use ionizing radiation, as opposed to MRI which is non-invasive. MRI is based on the magnetic resonance phenomenon and uses a magnet and radio signals to generate multi-modal images. Conventional MRI studies exploit the concentration of water protons (i.e., proton density PD) and two relaxation times, T1 (spin-lattice relaxation rate) and T2 (spin-spin relaxation rate). T1-weighted studies demonstrate normal and abnormal anatomy particularly well. T2-weighted studies are particularly sensitive to the detection of pathological processes. US is based on the interaction of acoustic energy with tissue, which provides a signal containing information on tissue properties. US systems vary in terms of the range of acoustic frequencies and energies, and beam divergence. Low cost and real-time scanning make US popular. SPECT is able to detect functional and pathological changes. It shows the distribution of injected or inhaled radiopharmaceuticals that emit protons upon decay. SPECT images are reconstructed from multiple projections, similar to CT, recorded by

gamma cameras. PET demonstrates glucose and oxygen consumption as well as metabolic abnormalities. PET images show the distribution of positron-emitting radionuclides administered to the patient.

Vasculature can be examined by using Digital Subtraction Angiography (DSA), CT Angiography (CTA), MR Angiography (MRA), and X-ray rotational angiography. In MRA, a variety of subtraction methods are available to differentiate rapidly moving protons in blood from the relatively static protons in surrounding tissues.

Magnetic Resonance Spectroscopy (MRS) is a biochemical tool for the identification of variety of metabolites in tissue. It can serve as a non-invasive tissue biopsy. Brain connections can be traced by Diffusion Tensor Imaging (DTI).

Functional neuroimaging, with functional magnetic resonance imaging (fMRI), PET, and magnetoencephalography (MEG), has been used extensively to identify brain regions associated with motor, sensory, visual, auditory, and cognitive tasks. Functional brain mapping has tremendous potential as a tool for basic neuroscientific investigation as well as the diagnosis of stroke and tumors, and presurgical planning.

## 2.2. Segmentation

Segmentation refers to the partitioning of the image into components that are homogeneous with respect to some feature(s). Segmentation is an important step in applications involving quantitative analysis, registration, visualization, compression, and computer-aided surgery. Segmentation methods can be broadly divided into interactive (manual), semiautomatic, and automatic, see examples in Figures 1 and 3. Segmentation algorithms operate on the intensity or texture variations of the image using a variety of techniques including thresholding, region growing, edge detection, deformable models, pattern recognition (neural networks and fuzzy clustering), or combination of some of them [14], [23], [73]. Deformable models are curves or surfaces defined within the image that can move under the external forces computed from the image data and the internal forces coming within the model itself [46]. The model is drawn towards the edges by external forces and the internal forces keep the model together and restrain it from bending too much. Deformable models, being able to represent complex shapes and a wide range of shape variability, overcome many of the limitations of the traditional low-level image segmentation techniques.

An accurate segmentation of brain images is a challenging task. Hybrid methods combining image-processing and model-based techniques are particularly effective for brain segmentation [4], [33].

a)

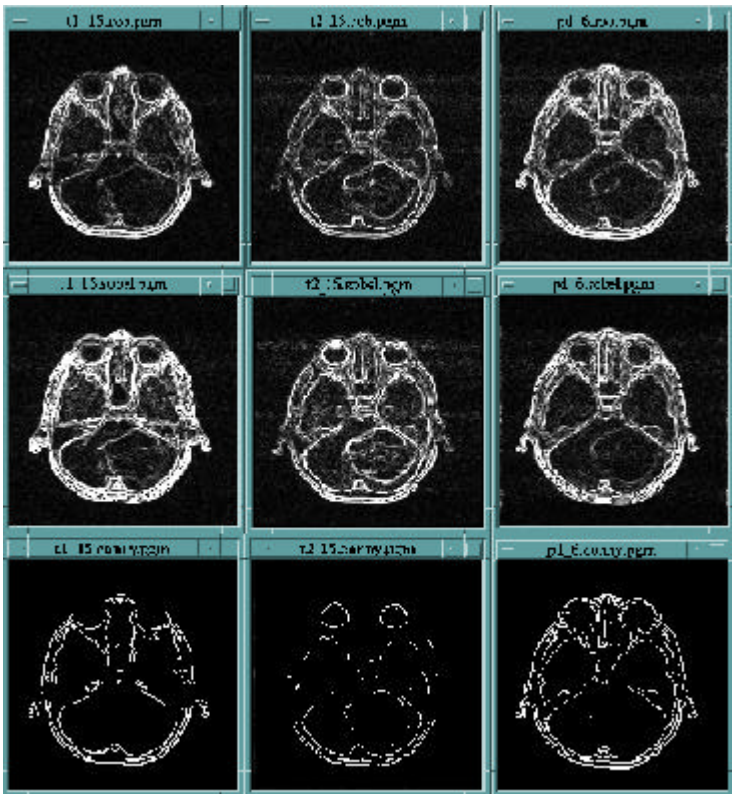

b)

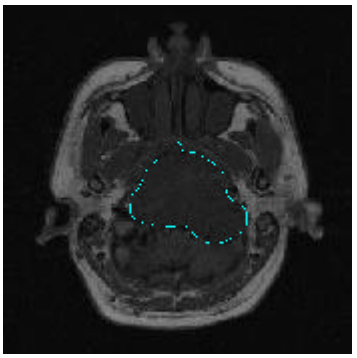

c)

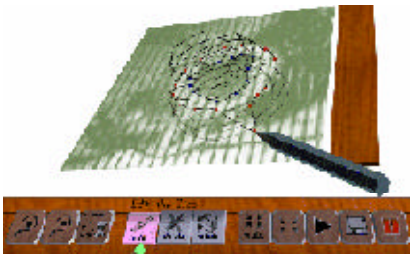

Fig. 1. Image-based and interactive segmentation of medical images: a) edge detection of T1-, T2-, and PD-weighted MR images using three different edge detectors: Roberts, Sobel, and Canny; note that none of them is able to delineate the tumor completely; b) interactive segmentation of a brain tumor in a 2D case; c) interactive segmentation in a 3D case by using a customized 3D contour editor.

Image segmentation may be preceded by image enhancement to accentuate certain features in the image. Image enhancement usually suppresses the noise or increases the image contrast.

### 2.3. Registration

Registration, also termed as matching or alignment, involves a spatial transformation that maps locations in one image to their corresponding locations in another image or model. These two images may be acquired by different imaging modalities, be taken for the same patient at a different time, correspond to two different patients, or correspond to a patient and a model. Registration usually involves translating, rotating, scaling, and possible non-linear warping of one image into the other. As the images once registered can be compared or combined, registration is useful for:

- model-based segmentation and labeling
- fusion of multi-modal data.

A registration process may involve up to four components: 1) a feature space, 2) a search space of the allowed transformations (such as rigid, affine, or elastic), 3) a similarity or difference measure between the matched images, and 4) a search strategy used to determine the transformation which maximizes the similarity measure or minimizes the difference measure.

There are numerous non-linear registration methods, such as [5], [9], [11], [12], [13], [15], [24], [88], [95], [96], [98], [99], [100]. A general overview of registration methods can be found in [10], while [42] overviews medical image registration. These methods are usually divided into two groups: feature-based and voxel-based. A simple feature may be the set of corresponding points in the registered images. These points may be internal anatomical landmarks or external markers attached to the patient. More complicated features may include the corresponding curves (such as edges, ridges, or crest lines) or surfaces. Voxel-based methods use the full contents of the images and exploit features such as grey values, correlation, and, recently mutual information. An example of MRI and CT registration by using a fast maximization of mutual information approach [99] is shown in Figure 2.

a)

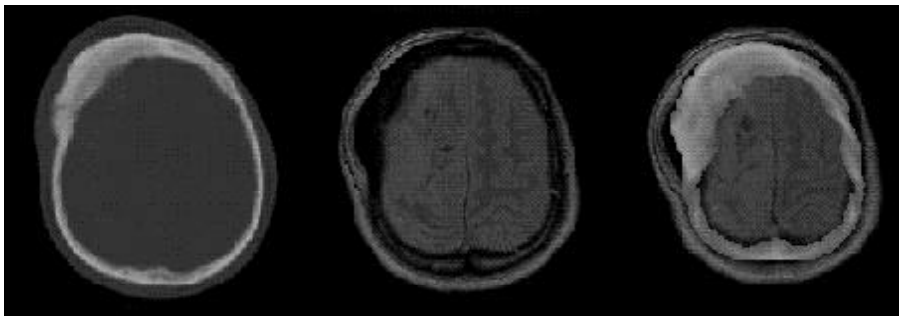

b)

Fig. 2. Registration of MRI and CT brain images in the presence of pathology: a) from left to right: CT, MRI, and fused axial images; b) axial and coronal fused images.

Despite their advantages and tremendous potential, non-linear registration methods have several limitations that make them difficult to use in today's clinical setting. Homologous landmark matching suffers from the need for a large number of landmarks and a subjectivity in selecting them. Iterative methods are often initial guess-dependent, which may not be acceptable in a clinical environment. The registration accuracy of boundary-based methods decreases when one moves away from the boundary. The major practical limitation, however, is a prohibitively large computational time required, as compared in [68].

A practical and clinically accepted registration method overcoming these limitations is the Talairach proportional grid system transformation [85]. It normalizes brains piecewise linearly and is based on the Talairach point landmarks: two internal landmarks lying on the midsagittal plane and six external landmarks lying on the smallest bounding box encompassing the cortex. The Talairach transformation can be performed in real time using hardware-assisted texture mapping [60] or in near real-time when implemented optimally [58], [61].

The Talairach approach can further be speeded up by using a new, equivalent set of landmarks [64]. These new (Talairach-Nowinski) landmarks are defined in a more constructive way and can be easier identified automatically. Figure 3 illustrates registration-based segmentation of MR images by using the Talairach transformation applied to the *Cerefy* brain atlases. Note that this approach is able to segment small brain structures that are not discernible in the image data.

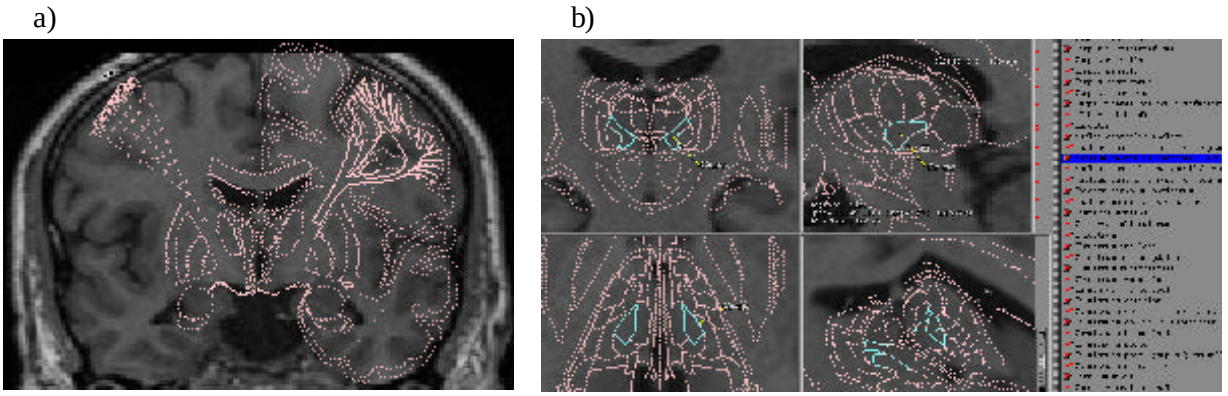


Fig. 3. Atlas-based segmentation. a) Gross anatomy is segmented by using the atlas in contour representation. b) The subcortical structures are segmented on axial, coronal, sagittal, and triplanar views. The structure of interest, i.e. the nucleus centralis magnocelluralis of the thalamus is highlighted and labeled.

## 2.4. Visualization

CT and MRI data sets have traditionally been interpreted and displayed as cross-sectional images. Recent advances in diagnostic imaging, such as multi-detector CT, faster MRI acquisitions, and rotational X-ray angiography, result in the routine acquisition of large, high-resolution volumetric datasets the effective interpretation of which requires the use of volume visualization. An efficient visualization of these datasets is also becoming a critical step in planning and performing therapeutic interventions.

Numerous 2D and 3D techniques have been developed for visualization, such as multiplanar reformatting, maximum intensity projection, surface rendering, and volume rendering. Multiplanar reformatting includes orthogonal, oblique, and curved reformatting. Surface rendering requires the rendered object(s) to be segmented first. Then standard computer graphics techniques, such as hidden surface removal, lighting, and shading, are used. One of the most popular iso-surface extraction techniques is *Marching Cubes* [41]. Volume rendering techniques, such as [18], [40] provide direct visualization of the complete volumetric data. Prior segmentation is not required explicitly, however, the color and transparency of the image data are determined by the transfer functions [52]. Several approaches have been proposed to accelerate volume rendering, including adaptive methods, shell rendering, volume encoding, and the most efficient hardware-assisted 3D texture mapping [97]. Figures 4, 5cd, and 9 show examples of volume visualization techniques, while multiplanar reformatting is illustrated in Figures 7 and 10.

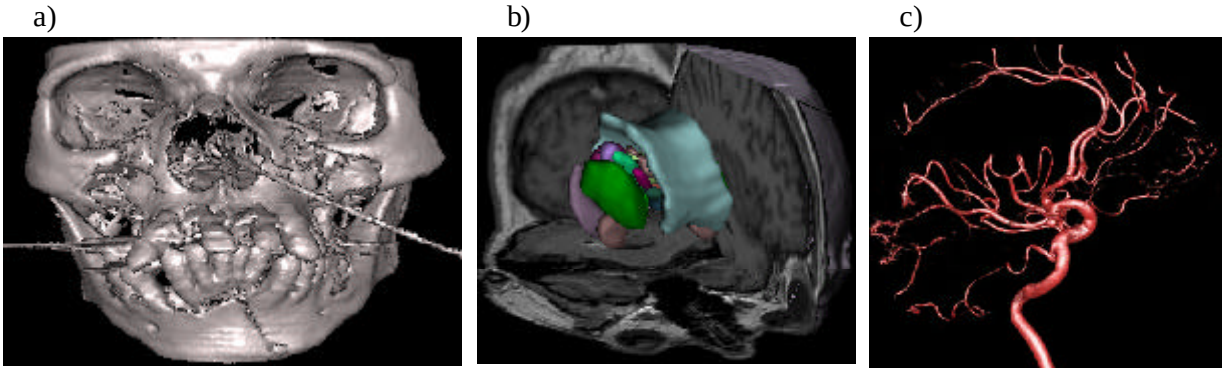


Fig. 4. Volume visualization: a) surface rendered skull from CT data of a car-accident victim; b) hybrid volume and surface rendering of MRI head and the 3D atlas represented as polygonal models; c) volume rendering of cerebral angiographic data.

## 2.5. Human body modeling

Human body modeling provides the means for prediction, evaluation, simulation, validation, and for enhancing the outcomes of diagnosis and treatment. When models are adapted to the patient, information that is inherent in them is then automatically mapped to the patient-specific data. This is achieved via registration, which in its simpler form is rigid and in a more complex form is deformable.

Making maps, the collections of which form atlases, is an ancient art-science. The map represents, organizes, and communicates data on the object of interest. Throughout history man has been producing maps of objects around him, initially the land and sea, later on other planets and solar systems, and most recently the human

genome and human brain. Numerous types of brain atlases have been constructed varying in the material used as well as their functionality and applications. A taxonomy of brain atlases with the associated tools is presented in [57].

**Printed atlases**. A number of brain atlases have been published, such as [16], [19], [21], [37], [47], [48], [49]. In addition, several stereotactic brain atlases have been constructed since the 1950s, including [2], [3], [72], [75], [76], [83], [84], [85], [86], [92].

**Electronic stereotactic atlases**. Deformable electronic atlases overcome several limitations of the printed atlases and open new possibilities. In addition to atlas warping, they offer new features not available in printed atlases, such as interactive labeling of scans, flexible ways of presentation in 2D and 3D (or even in *n*-dimensional space capturing dynamic changes or multi-modal atlases), defining regions of interest, mensuration, searching capabilities, and integration of information from multiple sources.

To combine the widely accepted stereotactic printed atlases with the capabilities offered by electronic atlases, several printed atlases have been converted into electronic form, including: Schaltenbrand-Bailey atlas [29], [34], [101]; Schaltenbrand-Wahren atlas [32], [51], [53), [81); Talairach-Tournoux atlas [29], [53]; Referentially Oriented Talairach-Tournoux atlas [53]; Ono *et al* atlas [54]; Afshar *et al* atlas [50] and Van Buren-Borke atlas [29]. Computerized versions of printed atlases may vary substantially from a simple, direct digitization of the original material to a sophisticated, fully segmented, labeled, enhanced, and three-dimensionally extended deformable atlas.

**Other electronic brain atlases**. Many other types of brain atlases have been developed. They include MRI-based atlases [30], [35], [39], [79]; cryosection-based atlases [8], [17], [28], [89]; multi-modal Visible Human-derived atlases [31], [77]; brain animations [82]; probabilistic anatomical atlases [20], [44], [45], [87], [91]; surface-based atlases [93]; surface-based probabilistic atlases [94]; and probabilistic functional atlases constructed from microrecordings [66].

***Cerefy* electronic brain atlas database**. The *Cerefy* electronic brain atlas database, [54], [62], [63] contains complementary atlases with gross anatomy, subcortical structures, brain connections, and sulcal patterns. It was derived from the classic printed brain atlases edited by Thieme:

- *Atlas for Stereotaxy of the Human Brain* by Schaltenbrand and Wahren [76];
- *Co-Planar Stereotactic Atlas of the Human Brain* by Talairach and Tournoux [85];
- *Atlas of the Cerebral Sulci* by Ono, Kubik, and Abernathey [72];
- *Referentially Oriented Cerebral MRI Anatomy: Atlas of Stereotaxic Anatomical Correlations for Gray and White Matter* by Talairach and Tournoux [86].

We digitized these complementary printed atlases and then enhanced, segmented, labeled, extended, aligned, and organized them into atlas volumes, Figure 5.

The anatomical index has about 1000 structures per hemisphere and more than 400 sulcal patterns. The electronic atlas images were pre-labeled to speed up structure labeling in atlas-based applications. About 17,000 labels were placed manually for the entire *Cerefy* brain atlas database. Three-dimensional extensions of the atlases were also constructed. In addition, all 2D and 3D atlases were mutually co-registered.

The *Cerefy* brain atlas database is applicable to neurosurgery [55], [56], [60], [65]; neuroradiology [61], [63], [67], [69]; brain mapping [59], [68]; and neuroeducation [70].

## 3. Model-assisted neuroeducation

Electronic atlases are commonly used in neuroeducation. Pioneering applications include *ADAM* [1], *BrainStorm* [17], *Digital Anatomist* [82], *VOXEL-MAN* [30], and several other reviewed in [54]. Most existing electronic brain atlases are teaching programs for education. They are typically HyperCard type systems, based on a collection of planar images. The *Digital Anatomist*, as opposed to 2D systems, contains animated 3D images of the human brain. Most of these atlases use predefined images and fixed animations, and offer limited visualization capabilities. Those limitations are overcome by constructing 3D brain atlases based on radiological images (CT, MRI) or Visible Human Data, such as the *VOXEL-MAN* [30], *Anatomy Browser* [25], and some other listed in the previous section. The limitations of these 3D atlases include lack of registration capabilities and a coarse anatomical parcellation of cerebral structures.

The *Cerefy Student Brain Atlas* [70] is a user-friendly application on CD-ROM for wide use in neuroeducation. It is useful for medical students, residents, and teachers. This application contains MRI and atlas images of gross anatomy and related textual materials. It also provides testing and scoring capabilities for exam preparation, as illustrated in Figure 6.

The *Cerefy Student Brain Atlas* is a comprehensive, powerful, extensible yet simple tool. Its novelty includes:

- atlas-assisted localization of cerebral structures on radiological images
- atlas-assisted interactive labeling simultaneously on axial, coronal, and sagittal planes
- atlas-assisted testing against location and name of cerebral structures
- saving of the labeled images suitable for preparing teaching materials.

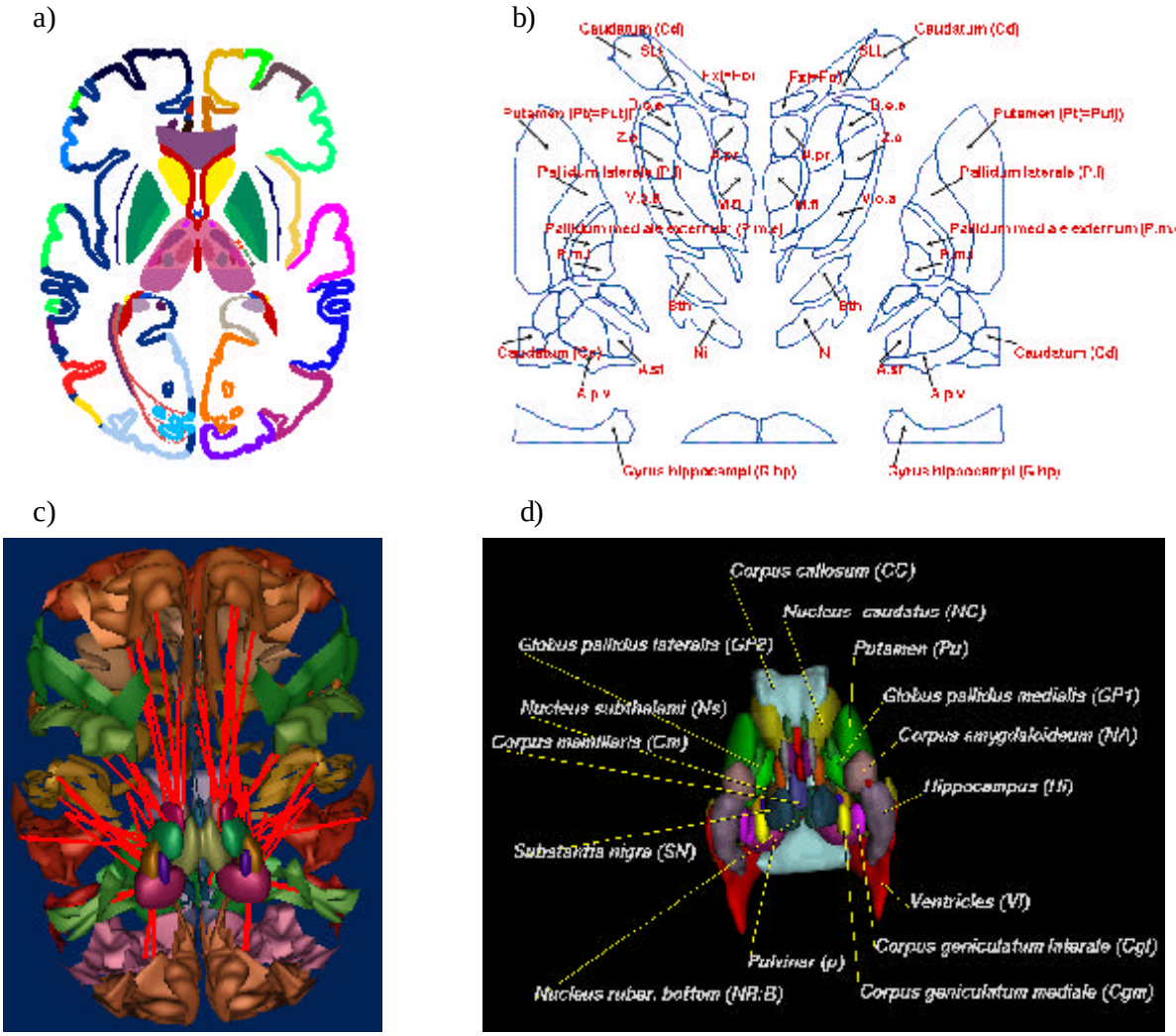


Fig. 5. *Cerefy* electronic brain atlas database: a) 2D axial atlas image with color-coded subcortical structures and cortical areas; b) 2D coronal contour image labeled with subcortical structures; c) 3D atlas with cortical areas, subcortical structures, and brain connections; d) 3D atlas labeled with subcortical structures.

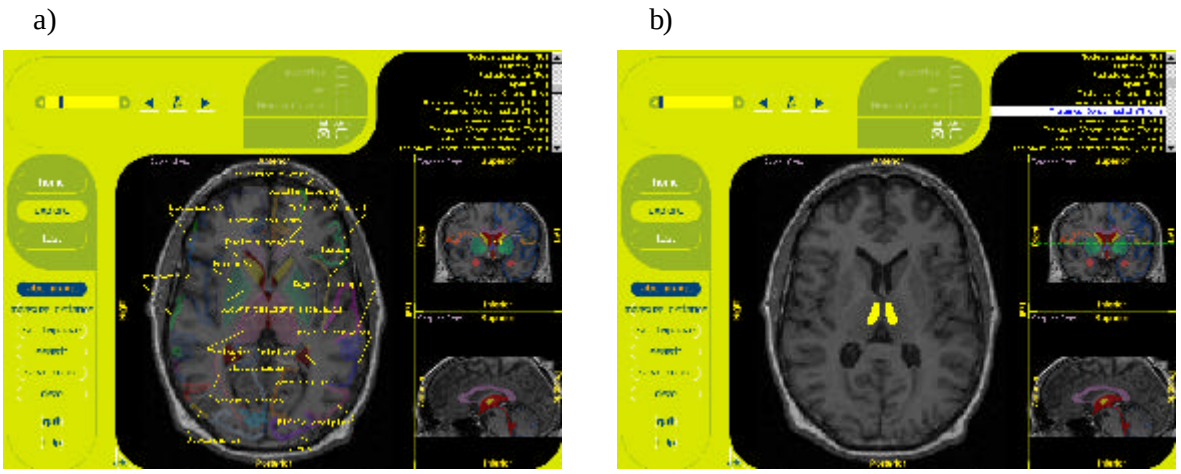


Fig. 6. The *Cerefy Student Brain Atlas*: a) interactive labeling of brain structures on the orthogonal MRI images; b) localization of the cerebral structure selected from the anatomical index (the thalamic dorso-medial nucleus is highlighted).

The *Cerefy Student Brain Atlas* exploits a part of the *Cerefy* brain atlas database and its future versions will include more components from this database (including 3D models) as well as more imaging modalities.

## 4. Use of brain atlases in medical research

The usefulness of electronic brain atlases in medical research is growing, particularly in medical image analysis and human brain mapping.

### 4.1. Medical image analysis

The gold standard in medical image analysis is the *ANALYZE* system from the Mayo Clinic [74]. This is a powerful, comprehensive visualization tool for multi-dimensional display, processing, and analysis of biomedical images from multiple imaging modalities. To facilitate analysis of brain images, the *Cerefy* brain atlas has been integrated with *ANALYZE*, Figure 7.

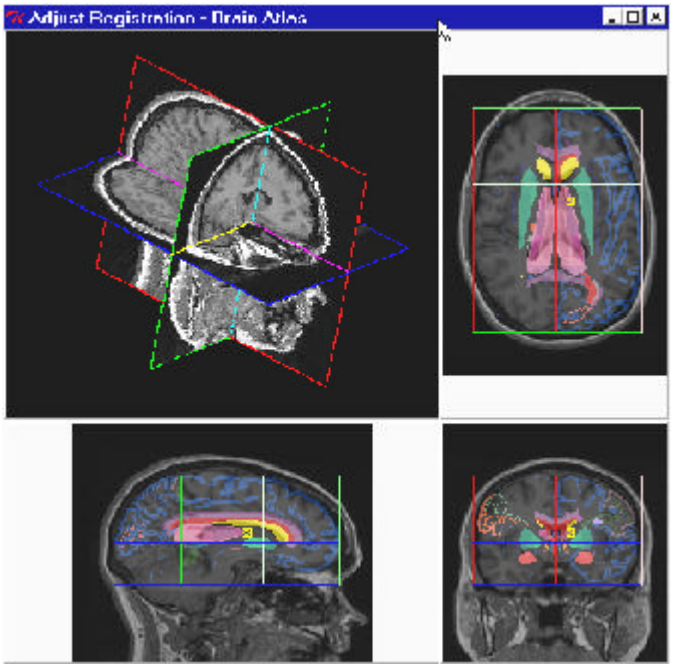


Fig. 7. The *Cerefy* atlas inside Mayo's *ANALYZE*. The Talairach grid is displayed allowing the user to warp interactively the atlas against the data by using the Talairach transformation.

### 4.2. Human brain mapping

Human brain mapping has tremendous potential as a tool for basic neuroscientific investigation. Its goal for the normal human brain is to clarify how the brain works in general rather than for any particular individual. Human brain mapping studies are based on behavioral conditions. A subject performs a task while his or her brain is imaged. The human brain varies across subjects and no single study can fully characterize a mental operation and its location in the population. Therefore, processes of knowledge discovery require combining studies from various sources. To compare individual brains, it is necessary to: (*i*) establish a standard, reference brain representation into which the results will be transformed; (*ii*) determine a transformation warping one brain into the standard reference brain; (*iii*) establish a coordinate system for specifying positions within the brain.

There are numerous software packages for functional image generation as reviewed in [26], [59]. None of them, however, provides atlas-assisted analysis of functional images. *BrainMap* [22] and the *Brain Atlas for Functional Imaging* [59] allow for labeling of functional images. *BrainMap* is an Internet application that does not provide direct access to the atlas. The definition of activation locus and its labeling are separated, and the information about the activation regions is lost during labeling. To label loci located beyond the atlas structures, *BrainMap* uses a so-called Talairach Daemon [38] that looks for the cortical area closest to the activation locus, and the label of this cortical area is assigned to the locus. The *Brain Atlas for Functional Imaging* provides direct access to the atlas and the user can display the activation regions superimposed on the atlas, and place and edit the marks corresponding to activation regions to have them labelable.

Besides providing labeling, the *Brain Atlas for Functional Imaging* has numerous features supporting localization analysis of functional images. None of the existing software packages for functional image generation contains the Talairach-Tournoux atlas, which is the gold standard in human brain mapping research. In addition, it provides numerous functions such as fast data normalization, readout of the Talairach coordinates, and data-atlas display. It has also several unique features including interactive warping, facilitating fine tuning of the data-to-atlas fit, backtracking mechanism compensating for missing Talairach landmarks and enhancing the outcome of the overall process of data analysis, multi-atlas multi-label labeling, navigation on the triplanar formed by the data and the atlas, multiple-images-in-one display with atlas-anatomy-function blending, loci editing in terms of content and placement, fast locus-controlled generation of results, and reading and saving of the loci list, see Figure 8.

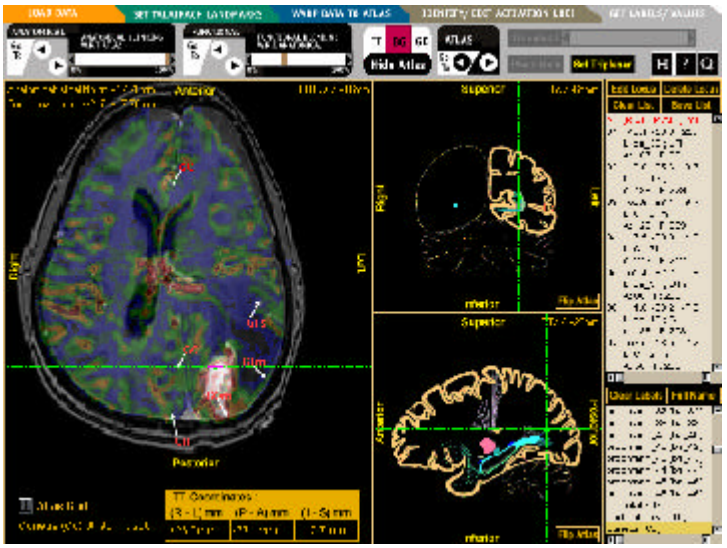

Fig. 8. The *Brain Atlas for Functional Imaging*. The MRI anatomical dataset is fused with a color-coded functional dataset. The region of the tumor is labeled by using the atlas.

## 5. Model-enhanced diagnosis

Early studies showed a considerable optimism regarding the capabilities of computers and artificial intelligence to automatically generate complete diagnosis. From several categories of systems, such as fully automatic computer diagnosis, interactive computer diagnosis, and computer-supported diagnosis, only the last has survived. Currently, it generally understood is that the computer should provide a physician with the necessary information to make a diagnosis rather than to act as a diagnostician.

To our best knowledge, the only model-enhanced application for neuroradiology used globally is our Internet-enabled *Cerefy Neuroradiology Atlas* [69].This application assists the neuroradiologist in speeding up scan interpretation by rapid labeling of morphological and/or functional scans, displaying the underlying anatomy for functional studies, and facilitating multi-modal fusion.

The understanding of underlying anatomy in the scan is easy for a neuroradiologist, but communicating this knowledge to others may be tedious and time-consuming. The *Cerefy Neuroradiology Atlas* which contains a deformable and labeled atlas is well suited for an efficient transfer of this knowledge to other clinicians, such as neurosurgeons, neurologists, referring physicians, and to medical students. It allows the neuroradiologist to annotate the scan with text, regions of interest and measured distances, and then label the structures of interest. The annotated and labeled scan can be saved in Dicom and/or XML formats, giving the neuroradiologist the possibility to store the atlas-enhanced scan in a PACS and to use it in web-enabled applications. In this way, the scan interpretation done by the neuroradiologist can easily be communicated to other clinicians and medical students. As illustrated in [63], [67], the advantages of the use of brain atlases in neuroradiology include:

- reduced time in image interpretation by providing interactive multiple labeling, triplanar display, higher parcellation than the scan itself, multi-modal fusion, and display of underlying anatomy for functional images;
- facility to communicate information about the interpreted scans from the neuroradiologist to other clinicians and medical students;
- increased neuroradiologist confidence in terms of anatomy and spatial relationships by providing interactive multiple labeling of the scan on the orthogonal planes and triplanar display with one plane from the scan and the other two from the atlas;
- potentially reduced cost by providing some information from mutually co-registered atlases which otherwise has to be acquired from other modalities;
- reduced time in learning neuroanatomy and scan interpretation by providing 3D and triplanar displays and labeling of multi-modal scans.

## 6. Model-enhanced neurosurgery

The successful use of flight simulators has inspired their application to surgical training and planning. Advances in computer graphics, tissue modeling, haptic instrumentation, and computer capabilities have enabled the development of computer-based surgical simulators. Before performing a neurosurgical procedure on a real patient, the neurosurgeon is able to practice on high-fidelity computer models of patient-specific data to simulate the intervention. In this way, safer and more effective surgical approaches can be planned, requiring less time in an operating room.

Computer-based surgical simulation is useful for education, training, pre-operative planning, and skill assessment. Virtual reality-based surgical simulators only recently have become available due to the complexity of anatomy and the demanding performance to interact directly with volumetric, usually multi-modal, images. A virtual reality simulator should be able to simulate surgical procedures, such as cutting, drilling, grasping, sucking, suturing, and knot tying. Requirements for this type of simulator include: real-

time interaction; realism to represent the accurate and detailed shape of patient's organ; quantitative deformation; haptic feedback; and simulation of a variety of surgical operations.

Two types of models are used in computer-aided systems for brain intervention:

- those directly derived from patient-specific data by using segmentation and modeling techniques
- pre-defined ones, such as brain atlases, which are matched to the patient-specific data by using registration techniques.

The first type of model is used in our two applications, *VIVIAN* and *NeuroCath*. The second type of model is used particularly in stereotactic and functional neurosurgery systems.

*VIVIAN*, or Virtual Intracranial Visualization And Navigation [36], is a system developed for preoperative neurosurgical planning and simulation. It is used to plan complicated cases such as tumor resection in the skull base region, vascular malformation, and separations of craniopagus twins. By using 3D, two-hand intuitive interaction, the neurosurgeon interacts with multi-modal images of a patient's skull, brain, tumor, and blood vessels fused together and displayed as a single 3D virtual object. The surgeon simulates bone and tissue removal in the image to plan the optimal entry path for tumor resection. *VIVIAN* provides 3D interactive segmentation tools to extract and model critical objects of a patient's anatomy and pathology.

*NeuroCath* is a computer environment for planning interventional neuroradiology procedures [71]. It supports the extraction of vasculature from patient-specific data, models the physical behaviors between the interventional devices and cerebral vasculature, and provides the tactile apparatus that gives the clinician the sense of touch during intervention planning and training, as shown in Figure 9.

The first stereotactic brain atlases in printed form, such as [75], [84], were constructed in the 1950s. It took about two decades to make the first brain atlases in electronic form available in clinical settings [7]. After another two decades, at the end of the 1990s, electronic brain atlases have become commonplace in stereotactic and functional neurosurgery [29], [60], [66].

Our *Cerefy* brain atlas database [54], [62], [63] has become the standard in stereotactic and functional neurosurgery. It has already been integrated with major image guided surgery systems including the *StealthStation* (Medtronic/Sofamor-Danek), *Target* (BrainLab), *SurgiPlan* (Elekta), *SNN 3 Image Guided Surgery System* (Surgical Navigation Network), and a neurosurgical robot *NeuroMate* (Integrated Surgical Systems). One of the simplest atlas-assisted approaches is to use *The Electronic Clinical Brain Atlas* on CD-ROM [53]. It allows individualized atlases to be generated without loading the patient-specific data. This is useful for anatomical targeting. The planning procedure for stereotactic and functional neurosurgery by using this CD-ROM was proposed in [56]. The atlas is conformed to the patient's scan by means of a 2D local deformation done by matching the atlas' rectangular region of interest to the corresponding data region of interest.

The *NeuroPlanner* is another application developed by us for stereotactic and functional neurosurgery, as illustrated in Figure 10.

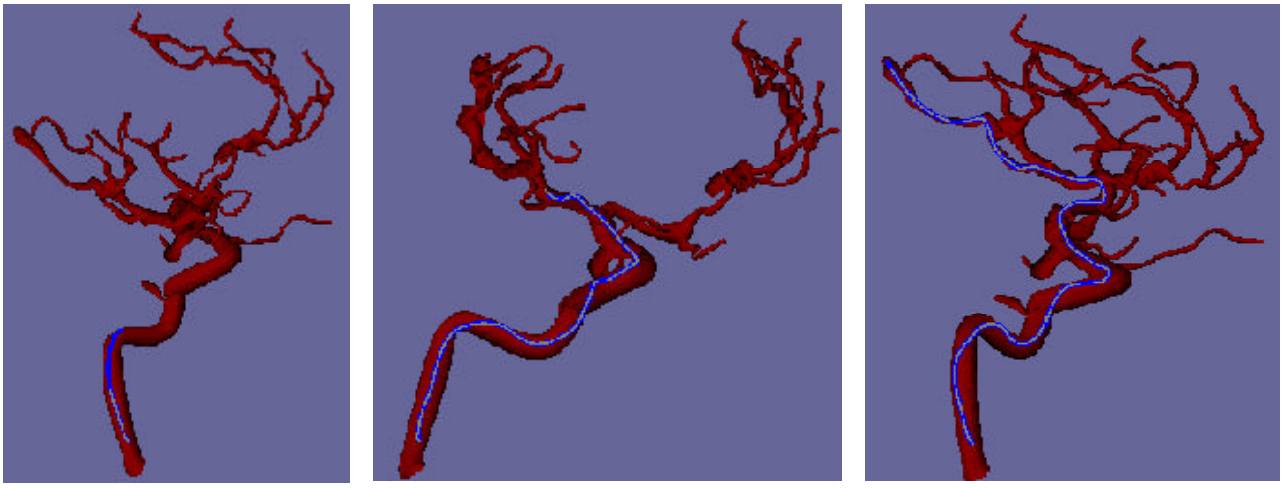

Fig. 9. Interventional neuroradiology simulation: subsequent stages of interventional device navigation. The interventional neuroradiologist can interactively insert the guidewire and the catheter, and manipulate the cerebral vascular model along with the interventional devices by rotating and zooming them.

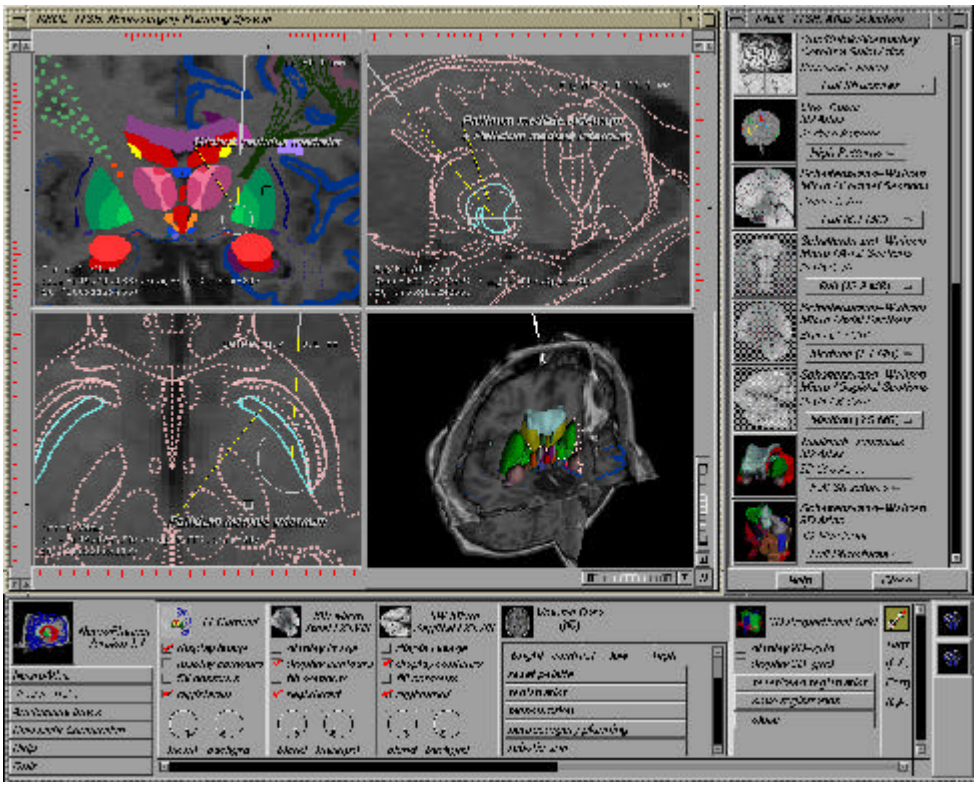

Fig. 10. The *NeuroPlanner*. Functional neurosurgery planning using multiple atlases in multiple orientations. (Center): four views showing the orthogonal data sections registered with the atlases in image and contour representations, and the data-atlas triplanar registered with the 3D atlas. The target structure is highlighted and labeled. The stereotactic trajectory (the thin line) along with the current position of the microelectrode (the thick line) are displayed in all views. (Right): atlas selection panel with multiple atlases in multiple resolutions. (Bottom): control panel with the surgery planning modules and atlas controls.

It supports preoperative planning and training, intraoperative procedures, and postoperative follow-up [60]. It comprises mutually co-registered atlases from the *Cerefy* brain atlas database including their 3D extensions [54]. The *NeuroPlanner* provides four groups of functions: data-related (data interpolation, reformatting, image processing); atlas-related (atlas-to-data interactive 3D warping, 2D and 3D interactive multiple labeling); atlas-data exploration-related (interaction in three orthogonal and one 3D views, continuous data-atlas exploration); and neurosurgery-related (targeting, path planning, mensuration, simulating the insertion of a microelectrode, simulating therapeutic lesioning). The advantages of using the *Cerefy* brain atlases for stereotactic and functional neurosurgery are summarized in [62].

The *BrainBench* [80] is a virtual reality-based surgical planning system for stereotactic frame neurosurgery. It contains a suite of neurosurgery supporting tools and the *Cerefy* brain atlas. The *BrainBench* helps the neurosurgeon to prepare faster plans; have more accurate anatomical targeting; improve the avoidance of critical structures; have fewer sub-optimal frame attachments and speedier, more effective planning and training.

Our recent development in functional neurosurgery is a probabilistic functional atlas constructed from microrecordings collected during the treatment of hundreds of Parkinson's disease patients. This atlas along with the method for its generation will be delivered to the neurosurgeons via an Internet portal [66].

Acknowledgment

Numerous individuals and institutions contributed to this multiple year work. *The Electronic Clinical Brain Atlas* was a joint development with Prof. R. N. Bryan of the Johns Hopkins Hospital, USA. The *Brain Atlas for Functional Imaging* was developed in consultation with Dr. D. N. Kennedy of Massachusetts General Hospital, USA. The integration of the atlas with *ANALYZE* was done by the Mayo Clinic, USA and Figure 7 is courtesy of Prof. R. A. Robb of Mayo. The *NeuroPlanner* was developed within a joint project with Dr. T. T. Yeo of Tan Tock Seng Hospital/National Neuroscience Institute, Singapore. The construction of the probabilistic functional atlas is ongoing joint work with Prof. A. L. Benabid, France. *NeuroCath* is a joint development with Prof. J. Anderson of Johns Hopkins Hospital. The development of *NeuroPlanner* and *Brain Bench/VIVIAN* was supported by grants from the National Science and Technology

Board, Singapore. Key contributors to the development of applications described here include D. Belov, C. K. Chui, A. Fang, L. Jagannathan, R. A. Kockro, H. Ng, L Serra, A. Thirunavuukarasuu, Y. P. Wang, and G. L. Yang.

## References


1. A.D.A.M. Animated Dissection of Anatomy for Medicine. Users's Guide. A.D.A.M. Software Inc.; 1994.
2. Afshar E, Watkins ES, Yap JC. Stereotactic Atlas of the Human Brainstem and Cerebellar Nuclei. New York: Raven Press; 1978.
3. Andrew J, Watkins ES. A Stereotaxic Atlas of the Human Thalamus and Adjacent Structures. A Variability Study. Baltimore: Williams and Wilkins; 1969.
4. Atkins MS, Mackiewich B. Fully automatic segmentation of the brain in MRI. IEEE Trans Med Imaging 1998;17(1):98-107.
5. Bajcsy R., Lieberson R. and Reivich M. A computerized system for elastic matching of deformed radiographic images to idealized atlas images. J Comput Assist Tomogr 1983;7(6):618-25.
6. Bajcsy R, Kovacic S. Multiresolution elastic matching. Computer Vision, Graphics and Image Processing, 1989;46:1-21.
7. Bertrand G, Olivier A, Thompson CJ. Computer display of stereotaxic brain maps and probe tracts. Acta Neurochir Suppl 1974;21:235-43.
8. Bohm C, Greitz T, Eriksson L. A computerized adjustable brain atlas. Eur J Nucl Med 1983;15:687-9.
9. Bookstein F. Principal warps: thin-plate splines and the decomposition of deformations. IEEE Trans. Pattern Analysis and Machine Intelligence 1989;11(6):567-85.
10. Brown LG. A survey of image reconstruction techniques. ACM Computing Surveys 1992;24(4):325-76.
11. Collins DL, Neelin P, Peters TM, Evans AC. Automatic 3D intersubject registration of MR volumetric data into standardized Talairach space. J Comput Assist Tomogr 1994;18(2):192-205.
12. Collins DL, Evans AC. Animal: validation and application of non-liner registration-based segmentation. International Journal of Pattern Recognition and Artificial Intelligence 1997;11:1271-94.
13. Christensen GE, Joshi SC, Miller MI. Volume geometric transformations for mapping anatomy. IEEE Trans Med Imaging 1997;16:864-77.
14. Clarke LP, Velthuizen RP, Camacho MA, Heine JJ, Vaidyanathan M, Hall LO, Thatcher RW, Silbiger ML. MRI segmentation: methods and applications. Magn Reson Imaging 1995;13(3):334-68.
15. Davatzikos C. Spatial transformation and registration of brain images using elastically deformable model. Comput Vis Image Underst 1997;66(2):207-22.
16. DeArmond SJ, Fusco MM and Dewey MM. Structure of the Human Brain. A Photographics Atlas. 3rd ed. New York: Oxford University Press; 1989.
17. Dev P, Coppa G. P. and Tancred E. BrainStorm: desiging an interactive neuroanatomy atlas. Radiology 1992;185(P):413.
18. Drebin R, Carpenter L, Harrahan P. Volume rendering. Comput Graph (ACM) 1988;24(4):64-75.
19. Duvernoy H.M. The Human Hippocampus: an Atlas of Applied Anatomy. Bergman, Munch; 1988.
20. Evans AC, Collins DL, Milner B. An MRI-based stereotactic brain atlas from 300 young normal subjects. Proceedings of the 22nd Symposium of the Society for Neuroscience; Anaheim. 1992:408.
21. Fix JD. Atlas of the Human Brain and Spinal Cord. Rockville: Aspen;1987.
22. Fox PT, Mikiten S, Davis G, Lancaster JL. BrainMap: a database of human functional brain mapping. In: Thatcher RW, Hallett M, Zeffiro T, John ER, Huerta M, editors. Functional Neuroimaging: Technical Foundations.; 1994. p. 95-106.
23. Fu KS, Mui JK. A survey of image segmentation. Pattern Recognition 1981;13(1):3-16.
24. Gee JC, Reivich M, Bajcsy R. Elastically deforming an atlas to match anatomical brain images. J Comput Assist Tomogr 1993;17(2):225-36.
25. Golland P, Kikinis R, Halle M, Umans C, Grimson WE, Shenton ME, et al. Anatomy Browser: a novel approach to visualization and integration of medical information. Comput Aid Surg 1999;4:129-43.
26. Gold S, Christian B, Arndt S, Zeien G, Cizadlo T, Johnson DL, et al. Functional MRI statistical software packages: a comparative analysis. Hum Brain Mapp 1998;6:73-84.
27. Grachev D, Berdichevsky D, Rauch SL, Heckers S, Kennedy DN, Caviness VS, et al. A method for assessing the accuracy of intersubject registration of the human brain using anatomic landmarks, Neuroimage 1999 Feb;9(2):250-68.
28. Greitz T, Bohm C, Holte S et al. A computerized brain atlas: construction, anatomical content, and some applications. J Comput Assist Tomogr 1991;15(1):26-38.
29. Hardy TL, Deming LR, Harris-Collazo R. Computerized stereotactic atlases. In: Alexander III E, Maciunas RJ, editors. Advanced Neurosurgical Navigation. New York: Thieme; 1999. p. 115-24.
30. Höhne KH. VOXEL-MAN, Part 1: Brain and Skull. Heidelberg: Springer-Verlag; 1995.
31. Höhne KH, Pflesser B, Pommert A, Riemer M, Schubert R, Schiemann T, et al. A realistic model of human structure from the Visible Human data, Methods Inf Med 2001:83-9.
32. Kall BA. Computer-assisted stereotactic functional neurosurgery. In: . Kelly PJ, Kall BA, editors. Computers in Stereotactic Neurosurgery. Boston: Blackwell; 1992. p.134-42.
33. Kapur T, Grimson WEL, Wells III WM, Kikinis R. Segmentation of brain tissue from magnetic resonance images. Med Image Anal 1996;1(2):109-27.
34. Kazarnovskaya MI, Borodkin SM, Shabalov VA, Krivosheina VY, Golanov AV. 3-D computer model of subcortical structures of human brain. Comput Biol Med 1991;21(6):451-7.
35. Kikinis R, Shenton ME, Iosifescu DV, et al. A digital brain atlas for surgical planning, model-driven segmentation, and teaching. IEEE Transactions on Visualization and Computer Graphics 1996;2(3):232-41.
36. Kockro RA, Serra L, Yeo TT, Chan C, Sitoh YY, Chua GG, et al. Planning and simulation of neurosurgery in a virtual reality environment. Neurosurgery 2000;46(1):118-37.
37. Kraus GE, Bailey GJ. Microsurgical Anatomy of the Brain. A Stereo Atlas. Baltimore: Wiliams & Wilkins; 1994.
38. Lancaster JL, Woldorff MG, Parsons LM, Liotti M, Freitas CS, Rainey L, et al. Automated Talairach atlas labels for functional brain mapping. Hum Brain Mapp 2000;10(3):120-31.
39. Lehmann ED, Hawkes D, Hill D, Bird CF, Robinson GP, Colchester AC, et al. Computer-aided interpretation of SPECT images of the brain using an MRI-derived neuroanatomic atlas. Med Inform 1991;16:151-66.
40. Levoy M. Display of surfaces from volume data. IEEE Computer Graphics and Applications 1988;8(5):29-37.
41. Lorensen W, Cline H. Marching cubes: a high resolution 3D surface construction algorithm. Comput Graph 1987;21:163-9.
42. Maintz JBA, Viergever MA. A survey of medical image registration. Med Image Anal 1998;2(1):1-36.

43. Martin J. Neuroanatomy. Text and Atlas. Norwalk: Appleton & Lange;1989.
44. Mazziotta JC, Toga AW, Evans AC, Fox P, Lancaster J. A probabilistic atlas of the human brain: theory and rationale for its development. NeuroImage 1995;2:89-101.
45. Mazziotta JC. Imaging: window on the brain. Arch Neurol 2000;57(10):1413-21.
46. McInerney T, Terzopoulos D. Deformable models in medical image analysis: a survey. Med Image Anal 1996;1(2):91-108.
47. McMinn RMH, Hutchings RT, Pegington J, Abrahams P. Color Atlas of Human Anatomy. 3rd ed. Mosby Year Book. St. Louis; 1993.
48. Netter FH. The CIBA Collection of Medical Illustrations. Vol 1: Nervous System. CIBA; 1991.
49. Nieuwennhuys R, Voogd J, van Huijzen C. The Human Central Nervous System. A Synopsis and Atlas. 2nd ed. Berlin: Springer-Verlag; 1981.
50. Niemann K, van den Boom R, Haeselbarth K, Afshar F. A brainstem stereotactic atlas in a three-dimensional magnetic resonance imaging navigation system: first experiences with atlas-to-patient registration. J Neurosurg 1999;90(5):891-901.
51. Niemann K, van Nieuwenhofen I. One atlas - three anatomies: relationships of the Schaltenbrand and Wahren microscopic data. Acta Neurochir (Wien) 1999;141(10):1025-38.
52. Nowinski WL, Ho WC. Generalized transfer functions and their use for three-dimensional neuroimaging. Proc SPIE Medical Imaging 1994: Image Capture, Formatting, and Display, Newport Beach, CA, USA, February 1994, SPIE Vol. 2164. p. 34-45.
53. Nowinski WL, Bryan RN, Raghavan R. The Electronic Clinical Brain Atlas. Multiplanar Navigation of the Human Brain. New York – Stuttgart: Thieme; 1997.
54. Nowinski WL, Fang A, Nguyen BT, Raphel JK, Jagannathan L, Raghavan R, et al. Multiple brain atlas database and atlas-based neuroimaging system. Comput Aid Surg 1997;2(1):42-66.
55. Nowinski WL Anatomical targeting in functional neurosurgery by the simultaneous use of multiple Schaltenbrand-Wahren brain atlas microseries. Stereotact Funct Neurosurg 1998;71:103-16.
56. Nowinski WL, Yeo TT, Thirunavuukarasuu A. Microelectrode-guided functional neurosurgery assisted by Electronic Clinical Brain Atlas CD-ROM. Comput Aid Surg 1998;3(3):115-22.
57. Nowinski WL. Analysis of medical images by means of brain atlases. Computer Graphics and Vision 1999:8(3);449-468.
58. Nowinski WL, Thirunavuukarasuu A. Methods and apparatus for processing medical images. Patent application PCT/SG00/00185; 2000.
59. Nowinski WL, Thirunavuukarasuu A, Kennedy DN. Brain Atlas for Functional Imaging. Clinical and Research Applications. New York – Stuttgart: Thieme; 2000.
60. Nowinski WL, Yang GL, Yeo TT. Computer-aided stereotactic functional neurosurgery enhanced by the use of the multiple brain atlas database. IEEE Trans Med Imaging 2000;19 (1):62-9.
61. Nowinski WL, Thirunavuukarasuu A, Srinivasan R. Brain atlas for neuroradiology. Scientific Program, 86th Radiological Society of North America Annual Meeting, Nov-Dec 2000, Chicago, IL, USA, Supplement to Radiology, 217 (P). p. 620.
62. Nowinski WL Computerized atlases for surgery of movement disorders. Seminars in Neurosurgery 2001;12(2):183-94.
63. Nowinski WL. Electronic brain atlases: features and applications. In: Caramella D, Bartolozzi C, editors. 3D Image Processing: Techniques and Clinical Applications. Medical Radiology series, Heidelberg: Springer-Verlag; 2002.
64. Nowinski WL. Modified Talairach landmarks. Acta Neurochir 2001;143(10): 1045-57.
65. Nowinski WL. Computer-aided brain surgery: present and future. In: Caramella D, Bartolozzi C, editors. 3D Image Processing: Techniques and Clinical Applications. Medical Radiology series, Heidelberg: Springer-Verlag; 2002.
66. Nowinski WL, Benabid AL. New directions in atlas-assisted stereotactic functional neurosurgery. In: Germano IM, editor. Advanced Techniques in Image-Guided Brain and Spine Surgery. Thieme, New York: Thieme; 2002.
67. Nowinski WL, Thirunavuukarasuu A. Electronic atlases show value in brain studies. Diagnostic Imaging Asia Pacific 2001;8(2):35-9.
68. Nowinski WL, Thirunavuukarasuu A. Atlas-assisted localization analysis of functional images. Med Image Anal 2001;5(3):207-20.
69. Nowinski WL, Thirunavuukarasuu A, Belov A, Yang YJ. Web-based atlas for neuroradiology. Proc American Society of Neuroradiology 39th Annual Meeting ASNR2001, 23-27 April 2001, Boston, MA, USA. p.500. Available from http://www.cerefy.com
70. Nowinski WL, Thirunavuukarasuu A Bryan RN. Cerefy Student Brain Atlas. KRDL, Singapore: KRDL; 2001.
71. Nowinski WL, Chui CK. Simulation of interventional neuroradiology procedures. Proc Medical Imaging and Augmented Reality MIAR2001, Hong Kong, 10-12 June 2001. IEEE Computer Society Press. p. 87-94.
72. Ono M, Kubik S, Abernathey CD. Atlas of the Cerebral Sulci. Stuttgart - New York: Georg Thieme Verlag/Thieme Medical Publishers; 1990.
73. Pal NR, Pal SK. A review of image segmentation techniques. Pattern Recognition 1993;26(9):1227-49.
74. Robb RA, Hanson DP. The ANALYZE software system for visualization and analysis in surgery simulation. In: Lavallee S, Tayor R, Burdea G, Mosges R, editors. Computer Integrated Surgery. Cambridge MA: MIT Press;1995. p. 175-90.
75. Schaltenbrand G, Bailey. Introduction to Stereotaxis with an Atlas of the Human Brain. Stuttgart: Georg Thieme Verlag; 1959.
76. Schaltenbrand G, Wahren W. Atlas for Stereotaxy of the Human Brain. Stuttgart: Georg Thieme Verlag; 1977.
77. Schiemann T, Freudenberg J, Pflesser B, Pommert A, Priesmeyer K, Riemer M, et al. Exploring the Visible Human using the VOXEL-MAN framework. Comput Med Imaging Graph 2000;24(3):127-32.
78. Schitzlein HN, Murtagh FR. Imaging Anatomy of the Head and Spine. A Photographic Color Atlas of MRI, CT, Gross, and Microscopic Anatomy in Axial, Coronal, and Sagittal Planes. 2nd ed. Baltimore: Urban & Schwarzenberg; 1990.
79. Schmahmann JD, Doyon J, McDonald D, Holmes C, Lavoie K, Hurwitz AS, et al. Three-dimensional MRI atlas of the human cerebellum in proportional stereotaxic space. Neuroimage 1999;10(3 Pt 1):233-60.
80. Serra L, Nowinski WL, Poston T, Hern N, Meng LC, Guan CG, et al. The Brain Bench: virtual tools for stereotactic frame neurosurgery. Med Image Anal 1997;1(4):317-29.
81. Sramka M, Ruzicky E, Novotny M. Computerized brain atlas in functional neurosurgery. Stereotact Funct Neurosurg 1997;69(1-4 Pt 2):93-8.
82. Sundsten JW, Brinkley JF, Eno K, Prothero J. The Digital Anatomist. Interactive Brain Atlas. CD ROM for the Macintosh, University of Washington, Seattle; 1994.
83. Szikla G, Bouvier G, Hori T, Petrov V. Angiography of the Human Brain Cortex: Atlas of Vascular Patterns and Stereotactic Localization. Berlin: Springer-Verlag; 1977.
84. Talairach J, David M, Tournoux P, Corredor H, Kvasina T. Atlas d'Anatomie Stereotaxique des Noyaux Gris Centraux. Paris: Masson; 1957.
85. Talairach J, Tournoux P. Co-Planar Stereotactic Atlas of the Human Brain.

Stuttgart - New York: Georg Thieme Verlag/Thieme Medical Publishers; 1988.
86. Talairach J, Tournoux P. Referentially Oriented Cerebral MRI Anatomy. Atlas of Stereotaxic Anatomical Correlations for Gray and White Matter. Stuttgart - New York: Georg Thieme Verlag/Thieme Medical Publishers; 1993.
87. Thompson PM, Woods RP, Mega MS, Toga AW. Mathematical/computational challenges in creating deformable and probabilistic atlases of the human brain. Hum Brain Mapp 2000;9(2):81-92.
88. Thirion JP. Image matching as a diffusion process: an analogy with Maxwell's demons. Med Image Anal 1998;2:243-60.
89. Toga AW, Ambach KL, Schluender S. High-resolution anatomy from in situ human brain. Neuroimage 1994;1(4):334-44.
90. Toga AW, editor. Brain Warping. San Diego: Academic Press; 1998.
91. Toga AW, Thompson PM. Maps of the brain. Anat Rec 2001;265(2):37-53.
92. Van Buren JM, Borke RC. Variations and Connections of the Human Thalamus. New York: Springer-Verlag; 1972.
93. Van Essen DC, Drury HA. Structural and functional analyses of human cerebral cortex using a surface-based atlas. J Neurosci 1997;17(18):7079-102.
94. Van Essen DC, Lewis JW, Drury HA, Hadjikhani N, Tootell RB, Bakircioglu M, et al. Mapping visual cortex in monkeys and humans using surface-based atlases. Vision Res 2001;41(10-11):1359-78.
95. Wang Y, Staib LH. Physical model-based non-rigid registration incorporating statistical shape information. Med Image Anal 2000;4:7-20.
96. Wells WM, Viola P, Atsumi H, Nakajima S, Kikinis R. Multi-modal volume registration by maximization of mutual information. Med Image Anal 1997;1(1):35-51.
97. Westermann R, Ertl T. Efficiently using graphics hardware in volume rendering applications. Proc SIGGRAPH'98, Computer Graphics Proceedings, July 1998, Orlando, FL. p. 169-78.
98. Woods RP, Mazziotta JC, Cherry SR. MRI-PET Registration with Automated Algorithm. J Comput Assist Tomogr 1993;17:536-46.
99. Xu MH, Srinivasan R, Nowinski WL. A fast mutual information method for multi-modal registration. Lecture Notes in Computer Science, Vol. 1613, Proc Information Processing in Medical Imaging, 16th International Conference IPMI'99, June 28- July 2, Visegrad, Hungary. p. 466-71.
100. Xu MH, Nowinski WL. Talairach-Tournoux brain atlas registration using a metalforming principle based finite element method. Med Image Anal 2001;5(4):271-9.
101. Yoshida M. Three-dimensional maps by interpolation from the Schaltenbrand and Bailey atlas. In: Kelly PJ, Kall BA, editors. Computers in Stereotactic Neurosurgery. Boston: Blackwell; 1992. p. 143-52.

Address of the author:
Wieslaw L. Nowinski, DSc, PhD
Medical Imaging Lab
Kent Ridge Digital Labs
21 Heng Mui Keng Terrace
119613 Singapore
wieslaw@krdl.org.sg