

# Civilian Occult Orbitocranial Penetrating Injury Presenting with Cerebral Abscess in Elderly Patient

Mazhar Mulla<sup>1</sup> Bhagyashri Bhende<sup>1</sup> Swapnil Patil<sup>1</sup> Aditya Patil<sup>1</sup> Batuk Diyora<sup>1</sup>

<sup>1</sup>Department of Neurosurgery, LTMG Hospital, Sion, Mumbai, India

**Address for correspondence** Batuk Diyora, DNB, Department of Neurosurgery, LTMG Hospital, Second Floor, College Building, Sion, Mumbai 22, India (e-mail: bddiyora@gmail.com, batuk73@yahoo.co.in).

Indian J Neurotrauma 2017;14:145–148

## Abstract

Orbital penetrating injuries are uncommon and occur following accidental entry of objects through orbit. The authors report an interesting case of right frontal abscess resulting from orbitocranial penetrating injury due to accidental penetration of wooden stick into the right eye, which remained undiagnosed. A 70-year-man presented with complaints of headache and vomiting for few days. His computed tomographic (CT) scan of the brain revealed peripheral rim-enhancing cystic lesion in the right frontal lobe with perilesional edema, mass effect, and midline shift. Orbital CT scan revealed hyperdense lesion just lateral to medial orbital wall. Magnetic resonance imaging of the brain showed cystic peripheral rim-enhancing lesion that was homogenous hypointense on T1-weighted images and homogenous hyperintense on T2-weighted images. The patient underwent right frontal craniotomy. Pus was drained out, and abscess wall was excised. Foreign bodies protruding through fractured orbital roof were found and removed. He made good clinical recovery. He has received intravenous antibiotics for 2 weeks followed by 4 weeks of oral antibiotics. He had no visual symptoms. The authors report the case, review the literature, and highlight need for imaging in every case of orbital penetrating injury to prevent the life-threatening cerebral parenchymal complications.

## Keywords

- ▶ orbital injury
- ▶ cranial injury
- ▶ penetrating injury
- ▶ abscess

## Introduction

Brain abscess most commonly occurs from hematogenous dissemination from a distant infection. Other causes are local spread from a contagious infection following penetrating foreign-body injury or as a postoperative complication. Penetrating cranial injuries constitute 0.4% of all head injuries.<sup>1</sup> Transorbital craniocerebral penetrating injuries account for 24% of penetrating head injuries in adults and around 45% in children. These injuries are associated with significant morbidity and mortality.<sup>2–4</sup> Often, these injuries can be easily missed and remain undiagnosed until patients present with complications, as in this case. A variety of complications such as orbital cellulitis, cerebral abscess, meningitis, delayed neurologic deterioration related to slowly expanding intracranial hematoma, and mortality have been reported due to delayed diagnosis.<sup>5,6</sup> Therefore, early recognition of foreign bodies by appropriate radiologic images can prevent life-threatening complication.

## Case Report

A 70-year-man was brought to the emergency neurosurgery department from another hospital with complaints of headache and vomiting for few days. He was drowsy but easily arousable. His neurologic examination revealed no other abnormality except papilledema on funduscopy. He had no history of head trauma, middle ear infection, or paranasal sinus infection. He was nondiabetic. On detailed inquiry, the family gave a history of right-sided cataract surgery 4 months back from which he recovered well. About 8 weeks later, a thin wooden stick accidentally entered into the patient's right eye while playing with his grandchildren, following which he had excessive bleeding from the injury site that was controlled by compression dressing. Within the next few hours, in addition to significant swelling of the eyelid, he developed a red eye. The previous ophthalmologist was consulted once again who administered oral medications

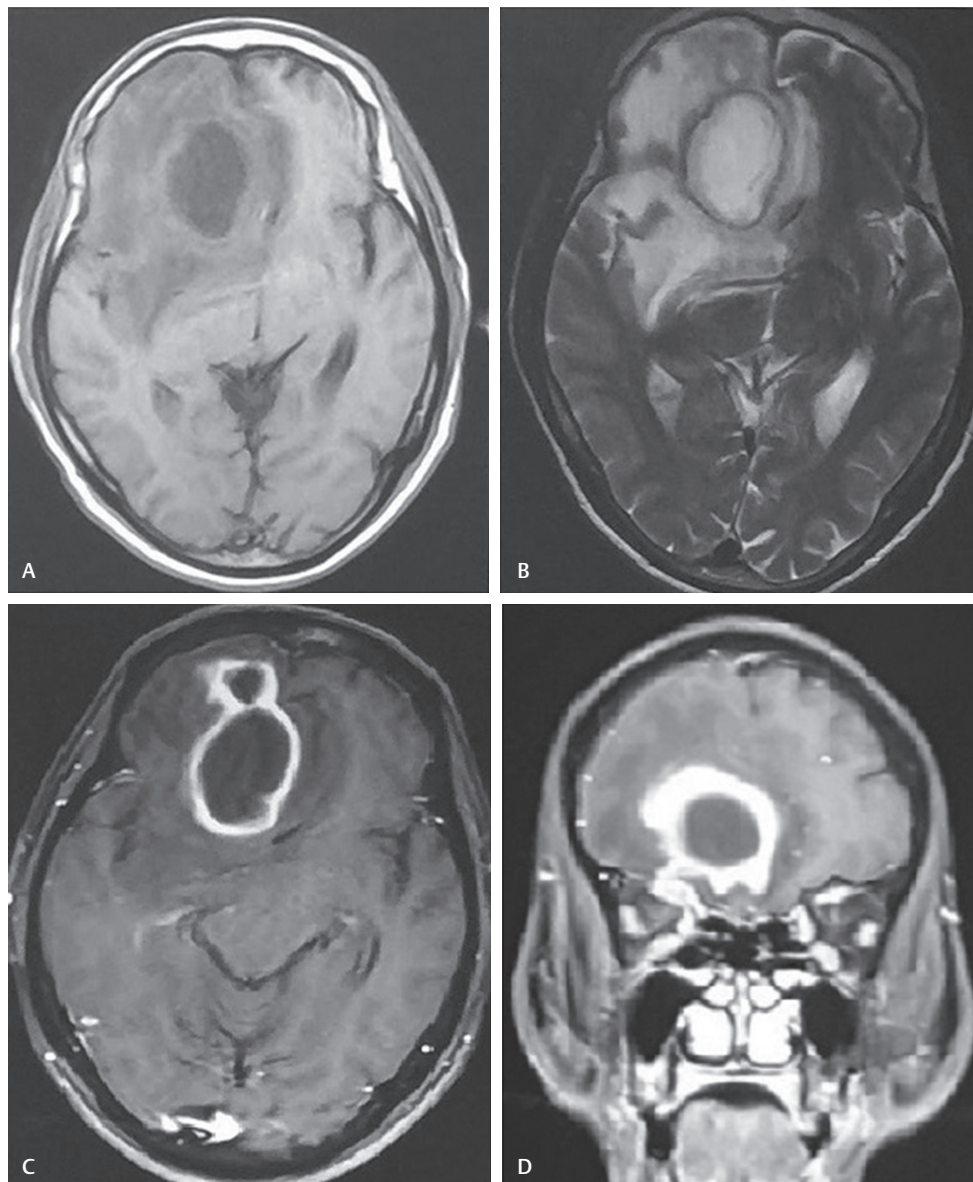
received  
October 12, 2017  
accepted  
December 4, 2017

Copyright ©2017 Neurotrauma  
Society of India

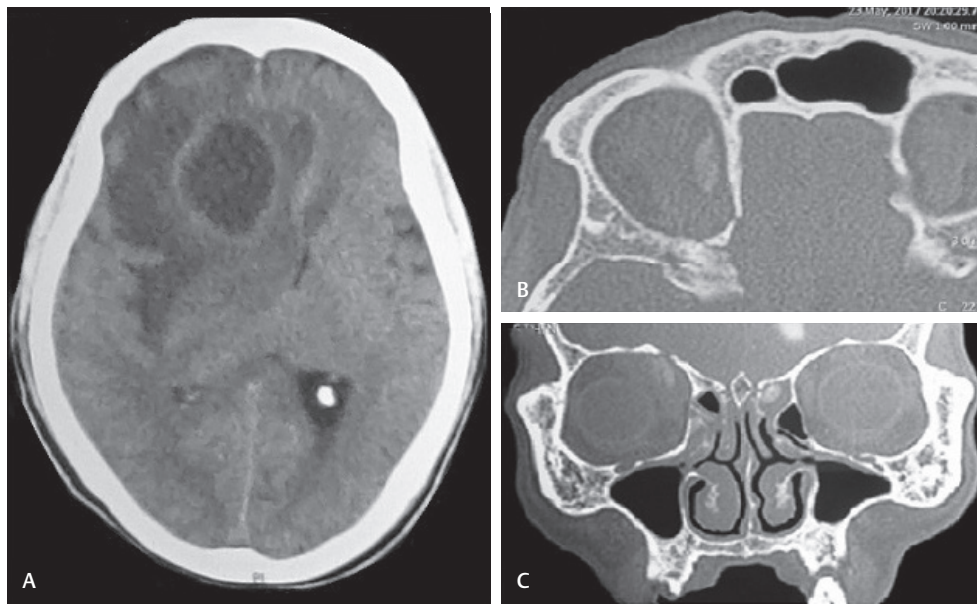
DOI <https://doi.org/10.1055/s-0038-1649284>.  
ISSN 0973-0508.

following a complete examination. The swelling subsided in a few days and eyeball congestion disappeared. Three weeks after accidental orbital injury, the patient developed headache and vomiting. He was referred to the authors with magnetic resonance imaging (MRI) of the brain that revealed  $3.5 \times 4.2 \times 4$  cm size mass lesion in the right frontal lobe, which was homogenous hypointense on T1-weighted images and homogenous hyperintense on T2-weighted images. Lesion showed peripheral rim of enhancement on axial and coronal view (►Fig. 1A–D). When all the other causes of frontal lobe abscess were ruled out, in view of the clinical history of orbital injury, computed tomographic (CT) scan of the orbit and brain was performed. CT brain revealed cystic mass lesion in the right frontal lobe (►Fig. 2A). Orbital coronal cut CT of the bone window showed fracture orbital roof and axial cut showed presence of foreign body in the right orbit, very close to the medial orbital wall (►Fig. 2B, C). Under general anesthesia, the patient underwent right frontal craniotomy. Brain

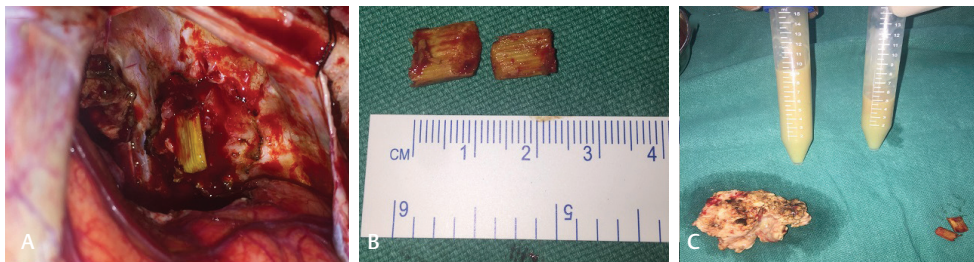was full and edematous. With the help of a brain cannula, the abscess cavity was entered and approximately 40 cc of brownish colored non-foul-smelling thick pus was aspirated out (►Fig. 3C). The brain became lax following the abscess tap. On gentle retraction of the frontal lobe, adhesions were noticed between frontal pole and the underlying dura over the orbital roof. On separation of the same, a defect in the orbital roof was noticed through which bone pieces were protruding out and communicating with the abscess cavity. The abscess wall was defined and excised completely (►Fig. 3C). The defect in the orbital roof was full of inflammatory tissue and small bone pieces that were removed. To the surprise, two pieces of greenish yellow wooden foreign body were seen in the orbit, which were removed (►Fig. 3A, B). Frontal base and orbital roof were cleaned with antiseptic solution and normal saline. Orbital roof was covered with Spongostan (Johnson & Johnson). Dura was then closed primarily. Gram stain study showed presence of pus cells, but no growth of any organism.



**Fig. 1** Magnetic resonance imaging of the brain showing mass lesion in the right frontal lobe, which was homogenous hypointense on T1-weighted images (A) and homogenous hyperintense on T2-weighted images (B). Lesion showing peripheral rim of contrast enhancement on axial (C) and coronal view (D).



**Fig. 2** CT scan of the brain plain study axial view showing right frontal cystic lesion with mass effect and midline shift (A), CT bone window axial and coronal cuts showing presence of hyperdense foreign body (B, C).



**Fig. 3** Intraoperative picture showing foreign body into the orbit (A), approximately 1 × 1 cm size two wooden foreign bodies (B) and (C) in the abscess wall.

Postoperative course was uneventful. Patient received intravenous antibiotics for two weeks followed by oral antibiotics for four weeks. Postoperative ophthalmic examination revealed no abnormality. At three months follow up, there was no evidence of orbital infection or recurrence of intracranial abscess.

## Discussion

Penetrating brain injuries are more common in war-related condition and occurred due to bullets and pellets. Penetrating injuries in civilian setup are uncommon. The various objects reported include pencil,<sup>6</sup> metal,<sup>7</sup> bicycle handle,<sup>8</sup> knife,<sup>9</sup> penetrating gunshot,<sup>10</sup> toothbrush,<sup>11</sup> and arrow.<sup>12</sup> Transorbital penetrating craniocerebral injuries are more common in the pediatric population as compared with adults and are very rare in the geriatric age group. These injuries can be easily missed and remain undiagnosed until patients present with the complications such as orbital cellulitis, cerebral abscess, and meningitis. Incidence of brain abscesses in children as a result of penetrating cranial injuries range from 4.8 to 16%.<sup>13</sup> They are associated with significant morbidity and mortality. The authors have reviewed the cases of craniocerebral penetrating injuries and noticed their rarity in the elderly population.<sup>6</sup>

The hard bony cranium protects the brain and prevents easy entry of foreign objects into the skull. However, there are certain weak points in the skull that allows easy entry of foreign objects. Temporal bone (especially in children) and orbit are the two common sites of foreign-body entry. Superior orbital fissure, inferior orbital fissure, and optic canal are the natural areas of an orbit that provide a direct access to the brain. In addition to these, the medial wall and roof are weak areas of the orbit that allows easy entry of the foreign body into the brain. These different routes of injury produce different types of craniocerebral injuries. Classification based on orbital bone anatomy and associated injury helps in the management of these injuries, decision making for surgical approaches, and anticipating potential types and sites of intracranial complications related to foreign-body penetration.<sup>12</sup> Turbin and colleagues analyzed the pattern of trans orbital intracranial injury and divided the orbital surface into different zones.<sup>5</sup> This case fits the zone 4 of the proposed classification.

Orbital penetrating injury can be diagnosed on the basis of clinical history, examination, and imaging. Nonoccult transorbital penetrating injury occurs when a part of the foreign body is still attached to the proximal wound, and the occult injury is the one in which the trivial superficial proximal

penetration tract does not draw medical attention to the presence of a foreign body. In some cases, penetrating foreign body might be missed and remain undiagnosed especially when eyelid laceration is sutured without any exploration, as in this case.

The surgical approach depends on the type of injury sustained, location of the foreign body, and probable complications. In this case, the primary injury as well as penetrating object was completely missed, which resulted in a delayed presentation in the form of an intracranial abscess. Orbital penetrating injury was a retrospective diagnosis. The authors approached the abscess through right frontal craniotomy, and during the surgical procedure, adhesions between the dura mater of the frontal lobe and the periorbital defect provided a hint to look for the presence of a foreign body. Various pathogens for abscess formation were reported in the literature. Among them, *Streptococcus* and *Staphylococcus* are the most common.<sup>13</sup> There were no organisms found in this case. Outcome following penetrating injury depends on the nature of the object, injury sustained from the object, the extent of intracranial injury, and the presence or absence of infection.

## Conclusion

Transorbital craniocerebral penetrating injury can be easily missed, especially in elderly patients, and can result in life-threatening complications. High index of suspicion in clinical and radiologic examination can help in the early diagnosis of retained foreign body and prevent delayed onset of life-threatening neurologic sequelae.

### Conflict of Interest

None.

### Source(s) of Support

None.

### Acknowledgments

None.

## References

- Gennarelli TA, Champion HR, Sacco WJ, Copes WS, Alves WM. Mortality of patients with head injury and extracranial injury treated in trauma centers. *J Trauma* 1989;29(9):1193–1201, discussion 1201–1202
- Yamaguchi T, Hata H, Hiratsuka H, Suganuma Y, Inaba Y. [Penetrating transorbital brain injury and intracranial foreign body (author's transl)]. *No Shinkei Geka* 1978;6(2):179–184
- Kasamo S, Asakura T, Kusumoto K, et al. [Transorbital penetrating brain injury] [in Japanese]. *No Shinkei Geka* 1992;20(4):433–438
- Bursick DM, Selker RG. Intracranial pencil injuries. *Surg Neurol* 1981;16(6):427–431
- Turbin RE, Maxwell DN, Langer PD, et al. Patterns of transorbital intracranial injury: a review and comparison of occult and non-occult cases. *Surv Ophthalmol* 2006;51(5):449–460
- Abdulbaki A, Al-Otaibi F, Almalki A, Alohaly N, Baesa S. Transorbital Craniocerebral Occult Penetrating Injury with Cerebral Abscess Complication. *Case Reports in Ophthalmological Medicine* 2012; Article ID 742186:6 pages
- Kasper EM, Luedi MM, Zinn PO, Rubin PA, Chen C. Retained transorbital foreign body with intracranial extension after pipe bomb explosion. *Surg Neurol Int* 2010;1:94
- Huiszoon WB, Noë PN, Manten A. Fatal transorbital penetrating intracranial injury caused by a bicycle hand brake. *Int J Emerg Med* 2012;5(1):34
- Cackett P, Stebbing J. Transorbital brain injuries. *Emerg Med J* 2005;22(4):299
- Kim TW, Lee JK, Moon KS, et al. Penetrating gunshot injuries to the brain. *J Trauma* 2007;62(6):1446–1451
- Atay M, Alkan A, Hanimoglu H, Sharifov R, Kilicarslan R, Aralasmak A. CT angiography evaluation of unusual transorbital penetrating injury: a toothbrush. *J Neuroimaging* 2013;23(2):314–316
- Mono J, Hollenberg RD, Harvey JT. Occult transorbital intracranial penetrating injuries. *Ann Emerg Med* 1986;15(5):589–591
- Frazier JL, Ahn ES, Jallo GI. Management of brain abscesses in children. *Neurosurg Focus* 2008;24(6):E8