

6 and 14 Hz Positive Spikes on Scalp Electroencephalogram

Kalpesh Sanariya¹ Arun Garg¹ Aniruddha More² Atma Ram Bansal³

¹Department of Neurology, Institute of Neurosciences, Medanta-The Medicity, Haryana, India

²Department of Epilepsy, Institute of Neurosciences, Medanta-The Medicity, Haryana, India

³Department of Neurology, Institute of Neurosciences, Medanta-The Medicity, Gurugram, Haryana, India

Address for correspondence Atma Ram Bansal, MBBS, MD, DM, Institute of Neurosciences, Medanta, Sector-38, Gurugram, Haryana, India (e-mail: atmarambansal@yahoo.com).

Int J Epilepsy 2018;5:9–12

Abstract

Keywords

- ▶ EEG
- ▶ benign epileptiform variants
- ▶ 6 and 14 Hz

Benign epileptiform variants (BEVs) are often noted in routine electroencephalogram (EEG) monitoring and are sometimes misinterpreted as epileptiform discharges. Six and 14 Hz positive spikes are one of such BEVs seen especially in children. However, these variants can also be seen in intensive care unit EEG recordings. Here, we have reviewed the history and electrical details of these 6 and 14 Hz variants with their clinical significance.

Introduction

Electroencephalogram (EEG) is a diagnostic test primarily used in patients with suspected epilepsy. It consists of various waveforms and different patterns seen over different brain regions and in different age groups. These waveforms and patterns could be normal or abnormal. However, certain waveforms mimic the morphology of epileptiform discharges but have no association with epilepsy. These waveforms are known as benign epileptiform variants (BEVs). An inexperienced electroencephalographer may report it as epileptiform discharges and this can lead to a wrong diagnosis and management. Classically, there are six variants of BEVs described, classification of which is shown ▶ **Table 1**.

Six and 14 Hz Positive Spikes

Six and 14 Hz positive spikes are patterns seen frequently in routine EEG screening. They are usually benign in nature, and no correlation was found with any epilepsy disorder in various case reports and studies. This article describes their normal appearance, distribution, pathological phenotypes, and their significance.

Historical Background and Nomenclature

This unique EEG pattern was originally described by Gibbs and Gibbs in 1951; since then there has been growing

interest in this EEG finding.¹ They found this pattern in EEG of young and adolescent children with the history of the epileptiform disorder. It has also been described in young children with headache.² Subsequently, many electroencephalographers have positively identified this pattern in many young children in various case studies and scenarios.^{3–12} Gibbs and Gibbs had originally coined the term 6 and 14 Hz positive spikes because the pattern comes in a frequency of either 6 or 14 Hz.¹³ The term positive spikes denote spiky morphology and positive polarity at the site of origin of the pattern. Lombroso et al called this pattern “ctenoids” because of its morphology resemblance with a

Table 1 Classification of benign epileptiform variants

Sharply contoured BEVs	BEVs occurring in bursts or runs
<ul style="list-style-type: none"> • Wicket wave • BSSS 	<ul style="list-style-type: none"> • 6 Hz spike and wave (FOLD and WHAM) • 6 and 14 Hz positive spikes • RMTD • SREDA subclinical rhythmic electrographic discharges of adults

Abbreviations: BSSS, benign sporadic sleep spike; BEV, benign epileptiform variant; FOLD; female, occipital, low amplitude, drowsiness; RMTD, rhythmic mid-temporal discharges; SREDA, subclinical rhythmic electrographic discharges of adults; WHAM, wake, high amplitude, anterior, male.

comb (Greek meaning of ktenos).⁹ Although till date 6 and 14 Hz positive spikes were the most common term for this pattern, presently it is being replaced by 6 and 14 Hz positive bursts.

Characteristics

In general population, 6 and 14 Hz positive bursts begin to appear at the age of 1 to 5 years and maximally seen in children aged between 13 and 15 years, thereafter its incidence progressively decreases with age.⁸ The 6-Hz positive spikes predominate in infants and after the age of 40 years, while 14-Hz positive spikes predominate or combine with 6-Hz spikes in the other age groups. The amplitude is usually less than 60 microvolt. Prevalence of this BEV varies from 0.5 to 6% among children undergoing EEG for various reasons.^{14,15} However, different case studies show variable incidence rates in different age groups of the patients.^{4,9,16} Differences in incidence of this BEV could be due to different age group studied, amount of EEG recorded in sleep, and awake state and the type of the montage used in the recording. As the name suggests, it appears as a burst of positive spikes at a frequency of 6 Hz or 14 Hz. Although named

6 and 14 Hz positive spikes, a burst may have the frequency that ranges from 5 to 7 Hz and 12 to 15 Hz. Usually, either 6 Hz or 14 Hz positive spikes predominate in an individual but occasionally both can be seen in the same patient. It lasts from 0.5 to 2 seconds in duration and most frequently seen over the posterior or mid-temporal region. As mentioned previously, its morphology resembles that of a comb and appears as “arc like” waveform over posterior temporal leads. The pattern consists of an alternating positive spiky component with negative smooth and rounded waveform. Superficially it mimics sleep spindles with sharp positive phases.

Six and 14 Hz positive spikes usually appear in stages of drowsiness and light sleep; however, sometimes they can be seen in rapid eye movement sleep also.¹⁷ The pattern is usually small in amplitude and best seen in a referential montage (► Fig. 1A) and may not be clearly visible in the bipolar montage (► Fig. 1B). It usually appears asynchronously or independently over both the hemisphere. Sometimes, it is seen synchronously on both the sides. It may have a predilection for one hemisphere, which may change over time from one hemisphere to another hemisphere in the

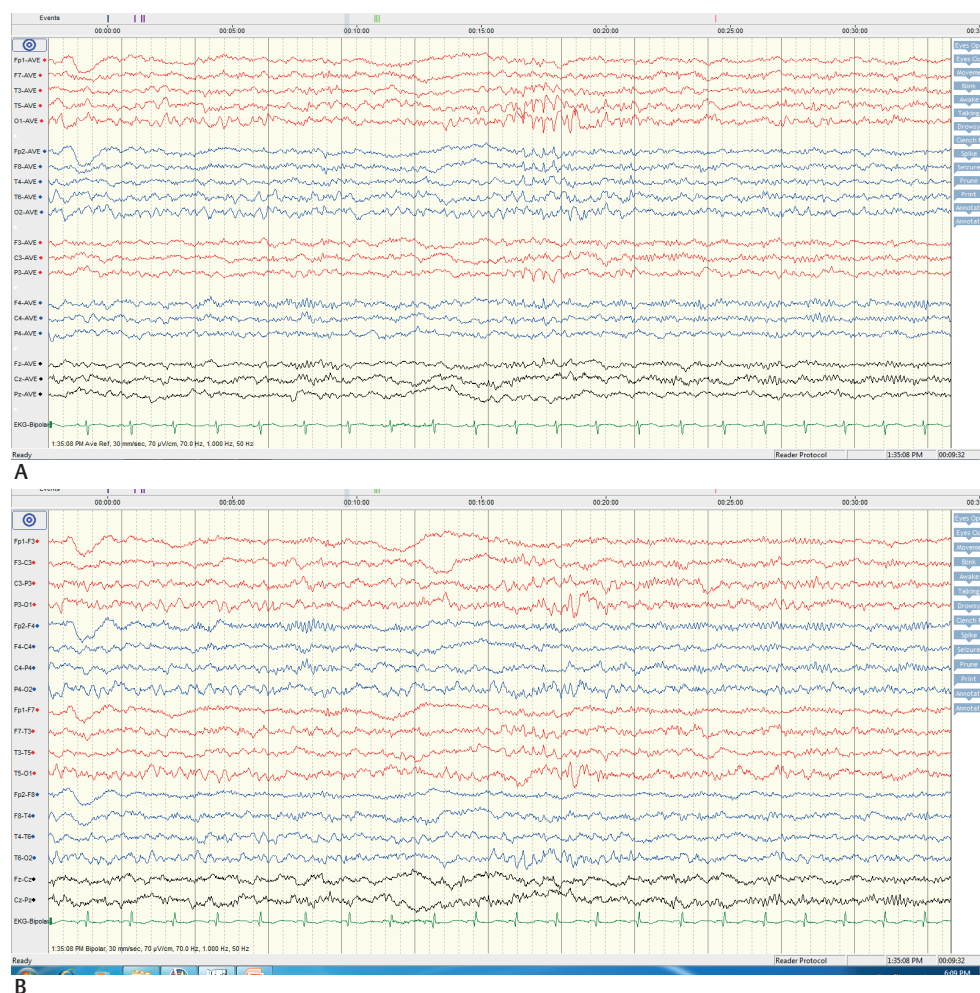

Fig. 1 (A) Average referential montage in a young child during light sleep showing 6 Hz positive spikes. (B) Longitudinal bipolar montage of the same discharge.

Table 2 Distinguishing points between 6 and 14 Hz positive spikes and Mu rhythm

6–14 Hz positive spikes	Mu rhythm
Positive spikes, occurring in bursts of < 1 sec	Spiky negative and rounded positive component, usually lasts for several seconds
Frequency is either 14 or 6 Hz	Frequency is 8–10 Hz (α range)
Appears in drowsiness and disappears in sleep	Occurs in wakeful state and attenuates on movement the contralateral limb
Occurs mostly over posterior temporal and parietal regions	Occurs predominantly over central head region (C3, C4, Cz electrode)

same patient.^{8,18,19} Occasionally, it can be confused with mu rhythm, which also has arciform or comb-like appearance; however, there are several distinctive features between the two, which can easily help in distinguishing between them (►Table 2).

Clinical Significance

Many studies were done in the past to find out the significance of this pattern, but none of the studies had shown a direct causal relationship of this pattern with any of the neurological disorders. There are a few case reports that raise the possibility of an association between 6 and 14 Hz positive spikes and some neurological disorders. In past, this pattern has also been described with some psychiatric symptoms such as behavior abnormality, violence, rage, emotional lability, and in some cases of neurovegetative symptoms such as a nonspecific headache, vertigo, dizziness, abdominal discomfort, and psychogenic nonepileptiform disorders.^{8,9}

Six and 14 Hz Positive Spikes in Pathological Conditions

The occurrence of 6 and 14 Hz positive spikes in hepatic encephalopathy was first described in 1958 by Poser and Zeigler in a patient of alcoholic cirrhosis.²⁰ In 1963, Silverman described a case of acute liver failure with hepatic encephalopathy who had similar spikes.²¹ Correlation between these spikes and hepatic encephalopathy was ascertained by the fact that these spikes disappeared after patient recovered from hepatic coma. We have also seen this pattern in hepatic encephalopathy (►Fig. 2). Yamada et al had described few cases of Reye syndrome with 6 and 14 Hz positive spikes in their EEG and stated that this pattern is found in a certain stage of the illness and may have diagnostic importance.²² Although mainly seen in patients with hepatic encephalopathy, any patient with encephalopathy can have 6 and 14 Hz positive spikes in their EEG.^{23,24} In one case report, 6 and 14 Hz positive burst had been noted preceding 3 Hz spike and wave discharges in a young girl with absence epilepsy.²⁵ Unilateral 6 and 14 Hz positive bursts had also been described in young women after surgical resection of arteriovenous malformation.²⁶ Association has been found between this controversial pattern and children with attention-deficit hyperactivity disorder symptoms and in patients with periodic lateralized epileptiform discharges.^{27,28}

Conclusion

Six and 14 Hz positive bursts or spikes are normal findings in young adolescent children, but the presence of this pattern in a setting of encephalopathy warrants assessment of the underlying hepatic function.

Conflict of Interest

None.

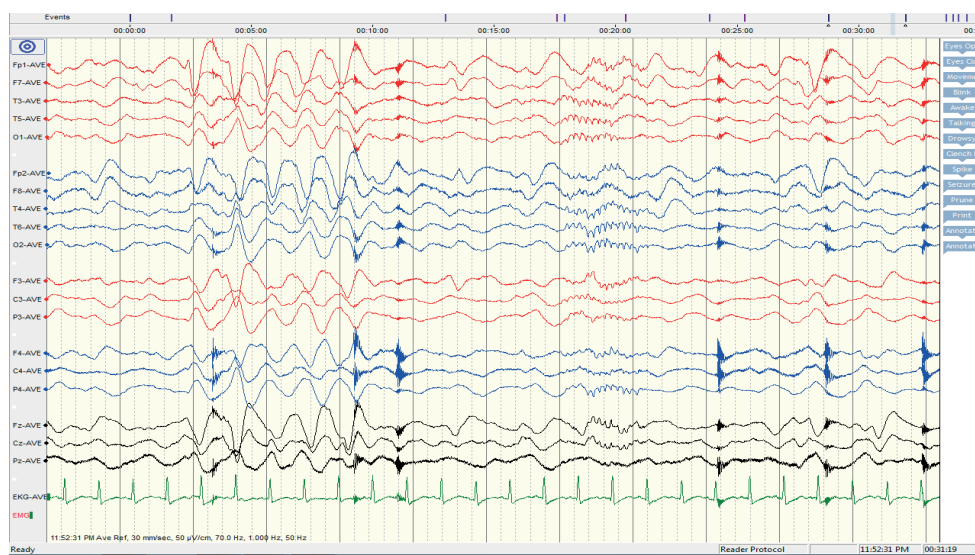


Fig. 2 Fourteen Hz positive spikes in average referential montage in patients with hepatic encephalopathy. Note moderate-to-severe slowing of background electrical activity.

References

- 1 Gibbs EL, Gibbs FA. Electroencephalographic evidence of thalamic and hypothalamic epilepsy. *Neurology* 1951;1(2):136–144
- 2 Silva DF, Lima MM, Kanda PM, Anghinah R, Zanoteli E, Lima JG. Atypical pattern related to 14 Hz positive spikes. *Arq Neuropsiquiatr* 1995;53(2):262–265
- 3 Chatrian GE. A glossary of terms most commonly used by clinical electroencephalographers. *Electroencephalogr Clin Neurophysiol* 1974;37(5):538–548
- 4 Eeg-Olofsson O. The development of the electroencephalogram in normal children from the age of 1 through 15 years. 14 and 6 Hz positive spike phenomenon. *Neuropediatrics* 1971;2(4):405–427
- 5 Henry CE. Positive spike discharges in the EEG and behavior abnormality. In Glaser GH, ed. *EEG and Behavior*. New York: Basic Books; 1963:315–344
- 6 Yamada T, Meng E. Benign EEG patterns. *Practical Guide for Clinical Neurophysiologic Testing: EEG*. Philadelphia, PA: Wolters Kluwer/Lippincott Williams & Wilkins; 2010
- 7 Hughes JR, Cayaffa JJ. Positive spikes revisited--in the adult. *Clin Electroencephalogr* 1978;9(2):52–59
- 8 Klass DW, Westmoreland BF. Nonpileptogenic epileptiform electroencephalographic activity. *Ann Neurol* 1985;18(6):627–635
- 9 Lombroso CT, Schwartz IH, Clark DM, Muench H, Barry PH, Barry J. Ctenoids in healthy youths. Controlled study of 14- and 6-per-second positive spiking. *Neurology* 1966;16(12):1152–1158
- 10 Mulsby RL. EEG Patterns of Uncertain Diagnostic Significance. *Current Practice of Clinical Electroencephalography*. New York: Raven; 1979
- 11 Pedley TA. EEG patterns that mimic epileptiform discharges but have no association with seizures. In: Henry CE, ed. *Current Clinical Neurophysiology: Update on EEG and Evoked Potentials*. New York, NY: Elsevier; 1980:307–336
- 12 Reiher J, Klass DW. Two common EEG patterns of doubtful clinical significance. *Med Clin North Am* 1968;52(4):933–940
- 13 Gibbs FA, Gibbs EL. Fourteen and six per second positive spikes. *Electroencephalogr Clin Neurophysiol* 1963;15:553–558
- 14 Santoshkumar B, Chong JJ, Blume WT, et al. Prevalence of benign epileptiform variants. *Clin Neurophysiol* 2009;120(5):856–861
- 15 Radhakrishnan K, Santoshkumar B, Venugopal A. Prevalence of benign epileptiform variants observed in an EEG laboratory from South India. *Clin Neurophysiol* 1999;110(2):280–285
- 16 Wang PJ, Tseng CL, Lin LH, Lin MY, Shen YZ. Analysis and clinical correlates of the 14 and 6 Hz positive electroencephalographic spikes in Chinese children. *Zhonghua Min Guo Xiao Er Ke Yi Xue Hui Za Zhi* 1991;32(5):272–279
- 17 Beun AM, van Emde Boas W, Dekker E. Sharp transients in the sleep EEG of healthy adults: a possible pitfall in the diagnostic assessment of seizure disorders. *Electroencephalogr Clin Neurophysiol* 1998;106(1):44–51
- 18 Tatum WO IV, Husain AM, Benbadis SR, Kaplan PW. Normal adult EEG and patterns of uncertain significance. *J Clin Neurophysiol* 2006;23(3):194–207
- 19 Ebersole JS, Pedley TA, eds. *Current Practice of Clinical Electroencephalography*. Philadelphia, PA: Lippincott Williams & Wilkins; 2003
- 20 Poser CM, Ziegler DK. Clinical significance of 14 and 6 per second positive spike complexes. *Neurology* 1958;8(12):903–912
- 21 Silverman D. 14 and 6 per second positive spike pattern in a patient with hepatic coma. *Electroencephalogr Clin Neurophysiol* 1964;16:395–398
- 22 Yamada T, Young S, Kimura J. Significance of positive spike burst in Reye syndrome. *Arch Neurol* 1977;34(6):376–380
- 23 Stern J, Engel J. *Atlas of EEG Patterns*. 2nd ed. Philadelphia, PA: Lippincott Williams and Wilkins; 2013:198
- 24 Drury I. 14-and-6 Hz positive bursts in childhood encephalopathies. *Electroencephalogr Clin Neurophysiol* 1989;72(6):479–485
- 25 Oletsky H, Greenfield J, Sato S. 14 and 6 Hz positive spikes preceding 3 Hz generalized spike and wave in a 15 year old patient with absence: a case report. *Electroencephalogr Clin Neurophysiol* 1998;106(3):262–264
- 26 Beydoun A, Drury I. Unilateral 14 and 6 Hz positive bursts. *Electroencephalogr Clin Neurophysiol* 1992;82(4):310–312
- 27 Boutros N, Fristad M, Abdollohian A. The fourteen and six positive spikes and attention-deficit hyperactivity disorder. *Biol Psychiatry* 1998;44(4):298–301
- 28 Mirzadjanova Z, Peters AS, Freilinger T, Rémi J, Noachtar S. 14 & 6Hz positive spikes coinciding with PLEDs. *Clin Neurophysiol* 2009;120(8):1489–1491