

A Study to Analyze the Tentorial Incisura in Indian Population, for Racial Differences and Its Impact in the Outcome of Patients with Head Injury

Deiveegan Kunjithapatham¹ Jeyaselvasenthilkumar Thotalampatti Pachiyappan¹
 Maria Subison Soosai Fernand²

¹Department of Neurosurgery, SRM Medical College Hospital and Research Centre, Kattankulathur, Kanchipuram, Tamil Nadu, India

²Department of Neurosurgery, Velammal Medical College Hospital, Madurai, Tamil Nadu, India

Address for correspondence Deiveegan Kunjithapatham, MS, MCh (Neuro), Department of Neurosurgery, SRM Medical College Hospital and Research Centre, Kattankulathur, Kanchipuram 603203, Tamil Nadu, India (e-mail: drdeiveegan@gmail.com).

Indian J Neurosurg 2018;7:122–128

Abstract

Aim To measure the size of tentorial notch in Indian population, compare it with the western population from the literature available, and analyze the relation between size of tentorial notch and the outcome in patients with head injury.

Materials and Methods The study was done using 10 cadavers and 15 autopsy specimens. In all the specimens, tentorial incisura was measured using vernier caliper after opening the skull and cutting the midbrain at the level of tentorial edge carefully without damaging the tentorium. All measurements were done in millimeters.

Results Mean values, age-dependent mean values, and percentile values were calculated for various parameters in the tentorial incisura. Majority of the tentorial incisura are of typical type. Cases of tentorial incisura are significantly smaller in the age group of 20 to 25 years. Rate of deterioration of Glasgow coma scale (GCS) is rapid when the tentorial incisura is large.

Conclusion There were no significant variations in measurements of tentorial incisura in Indian population compared with the western population. Rate of deterioration of GCS is higher in patients who had large tentorial incisura compared with other groups, which is statistically significance. However, this is to be confirmed by further study using large groups of patients to be used for clinical applications.

Keywords

- ▶ tentorial incisura
- ▶ tentorial herniation
- ▶ tentorial notch

Introduction

Tentorial incisura is the hiatus through which supra- and infratentorial spaces communicate. Knowledge about anatomy of tentorium and tentorial incisura is more important for various surgical approaches—both for supra- and infratentorial lesions.

The important neural structures related to tentorial incisura include the cerebrum, cerebellum, olfactory, optic, oculomotor, trochlear, trigeminal, abducent nerve, and midbrain.¹

Size of the tentorial incisura varies from person to person even in same-age groups. Its size plays an important role in tentorial herniation that occurs due to supratentorial hematoma or supratentorial space-occupying lesion. There are only few studies in the literature analyzing the size of the

tentorial incisura and the correlation between the tentorial incisura size and tentorial herniation. There are hardly any studies available in the literature analyzing the tentorial size of Indian population and its clinical importance. In this study, the authors analyzed the size of tentorial incisura in Indian population both in cadaver and in autopsy cases and tried to correlate the size with the outcome in patients with head injury. In autopsy cases, antemortem clinical conditions were recorded, and the relationship between tentorial incisura size and tentorial herniation was analyzed.

Aim of the Study

Aim of the study is to measure the size of tentorial notch in Indian population, compare it with the western population

received

January 17, 2018

accepted after revision

April 3, 2018

published online

August 24, 2018

DOI <https://doi.org/>

10.1055/s-0038-1667284.

ISSN 2277-954X.

©2018 Neurological Surgeons' Society of India

License terms



from the literature available, and analyze the relation between size of tentorial notch and the outcome in patients with head injury.

Materials and Methods

The study was initially started with cadavers, as the number of cadavers during the study period was less. Autopsy samples were analyzed, and the tentorial notch anatomy was found to be comparable to that of cadaver samples. Hence autopsy cases were also included in the study.

For cadaveric study, 10 cadavers in the Institute of Anatomy, Madras Medical College and Rajiv Gandhi Government General Hospital, Chennai, were studied.

For autopsy study, 15 specimens in the Institute of Forensic Medicine, Madras Medical College and Rajiv Gandhi Government General Hospital, Chennai, were studied.

Clearance (No. 03022013, dated March 11, 2013) from institutional ethical committee was obtained.

Inclusion Criteria

- Ten cadavers from the Institute of Anatomy, Madras Medical College, during the study period
- Fifteen autopsy specimen from the Institute of Forensic Medicine, Madras Medical College, during the study period

Exclusion Criteria

- All cadaveric specimen with damaged tentorium cerebelli on examination
- All autopsy specimen with damaged tentorium cerebelli on examination
- All pediatric specimens

In all the specimens, tentorial incisura was measured using vernier caliper after opening the skull and cutting the midbrain at the level of tentorial edge carefully without damaging the tentorium (► **Figs. 1, 2**). Measurements were done in millimeters.

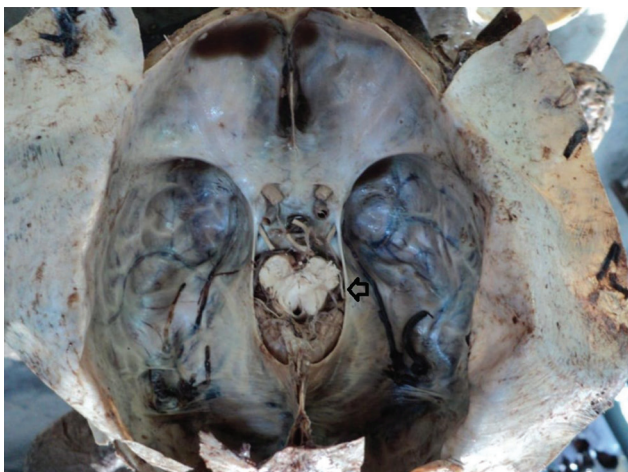

Fig. 1 Autopsy specimen showing tentorial notch (arrow).

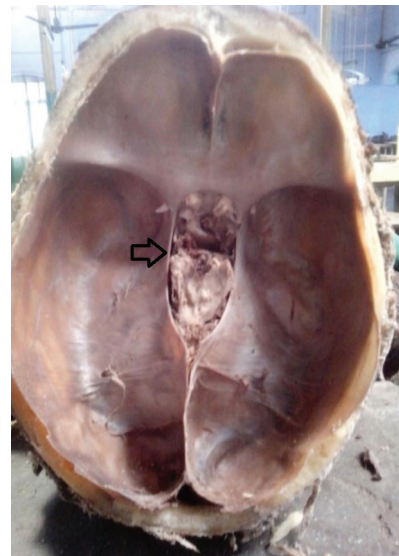


Fig. 2 Cadaver specimen showing tentorial notch (arrow).

Parameters studied were (► **Fig. 3**) as follows:

- Anterior notch width (ANW) is the width of the tentorial notch in the axial plane through the posterior aspect of the dorsum sellae.
- Maximum notch width (MNW) is the maximum width of the notch in the axial plane.
- Notch length (NL) is the length of the tentorial notch from the superoposterior edge of the dorsum sellae to the apex of the notch of tentorium.
- Posterior tentorial length (PTL) is the shortest distance between the apex of the notch and the most anterior part of the confluence of sinuses.
- Interpedunculoclival (IC) distance is the distance from the interpeduncular fossa to the superoposterior edge of the dorsum sellae.

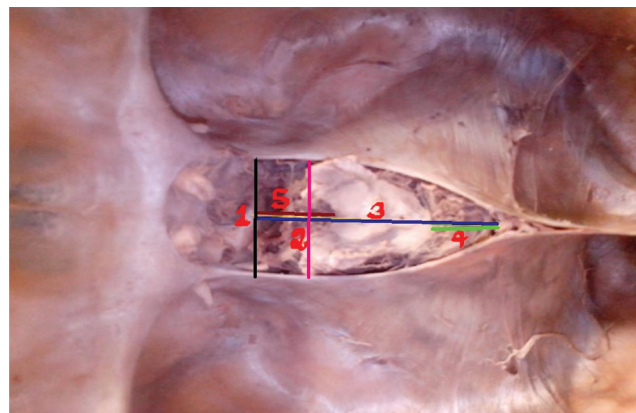


Fig. 3 Various parameters measured in tentorial notch. The black line (1) measures the anterior notch width, the pink line (2) the maximum notch width, the blue line (3) the notch length, the green line (4) the posterior tentorial length, and the red line (5) the interpeduncular clival distance.

- Apicotectal (AT) distance is the distance from the tectum in the median plane to the perpendicular line dropped from the apex of tentorial notch to the cerebellum.

Among the 10 cadavers studied, the authors could measure all the six parameters only in six cadavers. As the brain was liquefied in the remaining four cadavers, IC and AT distances could not be measured.

In autopsy specimens, only ANW, MNW, NL, and PTL were measured as IC and AT distances could not be measured because the midbrain was not rigid as in cadaveric specimens.

To study the association between tentorial size and incidence of coning, demographic details of all the 15 autopsy cases were noted and they were retrospectively analyzed for admission Glasgow coma scale (GCS), computed tomographic (CT) findings, degree of midline shift, and rate of deterioration of GCS. Out of the 15 autopsy cases, 4 deaths were nontraumatic without antemortem brain imaging and 11 deaths were trauma related with positive findings in the antemortem brain imaging.

Out of the 11 traumatic cases,

- Four cases underwent surgery immediately after admission in view of their poor admission GCS with intracranial hematoma with significant midline shift (> 5 mm). These cases succumbed to severe head injury even after adequate management.
- Four cases were initially managed conservatively in view of good GCS and less midline shift (< 5 mm) on admission, but these four cases deteriorated in spite of appropriate medical management, and all these four cases developed midline shift of more than 5 mm on deterioration.

- Three cases were managed conservatively throughout the period because there were no indications for surgery even in follow-up imaging.

Observations

The following analyses were performed from the data collected:

- Mean values of all the parameters in all the 25 cases were calculated and compared with western population in the literature.
- Age-dependent mean value calculated for all the four values: ANW, MNW, NL, and PTL.
- 25th percentile (1st quartile), 50th percentile (2nd quartile), and 75th percentile (3rd quartile) values calculated for all the parameters except AT and IC distance because this value was available only for five cadavers not for other cases.

Classification of Tentorial Incisura

Based on MNW and NL values, tentorial incisura was classified into wide, narrow, long, short, typical, large, small, and mixed. Cases of large tentorial incisura have MNW of more than 33 mm and NL of more than 59 mm in contrast to the smaller type with MNW values less than 27 mm and NL values less than 48 mm, as detailed in ►Table 1.

The autopsy cases were further divided into five age groups as shown in ►Table 2, to study the effect of age on tentorial size. Cases in each group were further classified according to the tentorial incisura size in which they fall, based on previously described tentorial incisura classification.

Table 1 Classification of tentorial incisura based on MNW and NL

S. No.	Types	Criteria for MNW and NL
1	Wide	MNW more than 3rd quartile and NL between 1st and 3rd quartile
2	Narrow	MNW less than 1st quartile and NL between 1st and 3rd quartile
3	Long	NL more than 3rd quartile and MNW between 1st and 3rd quartile
4	Short	NL less than 1st quartile and MNW between 1st and 3rd quartile
5	Typical	MNW between 1st and 3rd quartile and NL between 1st and 3rd quartile
6	Large	MNW more than 3rd quartile and NL more than 3rd quartile
7	Small	MNW less than 1st quartile and NL less than 1st quartile
8	Mixed	MNW more than 3rd quartile and NL less than 1st quartile or NL more than 3rd quartile and MNW less than 1st quartile

Abbreviations: MNW, maximum notch width; NL, notch length.

Table 2 Distribution of cases among various age groups

S. No.	Age group (y)	No. of cases
1	20–25	2
2	45–50	3
3	51–55	5
4	56–60	2
5	61–65	3

For 11 trauma-related deaths in autopsy cases, average deterioration of GCS per day was calculated during the treatment period, and this was compared with the tentorial size to study the correlation between tentorial size and patient deterioration. For this purpose, these cases were divided into two groups based on the tentorial size as

- Large tentorial size (MNW more than 3rd quartile and NL more than 3rd quartile)
- Others

Rate of deterioration of GCS per day was recorded and compared for these two groups.

Statistical Analysis and Results

Mean, median, and standard deviation (SD) values of ANW, MNW, NL, PTL, IC distance, and AT distance of all 25 cases were calculated; 25th, 50th, 75th percentile values were calculated for ANW, MNW, PTL, and NL (► **Table 3**). Mean values

of all the measurements are comparable with western population from the available studies in the literature. There was no significant variation in the size of tentorial incisura found in our part of Tamil Nadu, India.

Groups' Frequency Percent

Frequency distribution of various types of tentorial incisura and percentage of various types of incisura were analyzed in the samples studied (► **Table 4**).

Out of 25 cases, nearly 10 (40%) of cases had typical incisura type, 5 had small, 4 had large, 2 had wide, and the incisural types narrow, short, long, and mixed type are seen in one specimen each.

Age-dependent mean value was calculated for all the four values (ANW, MNW, NL, PTL) (► **Table 5**). It shows that the tentorial size is significantly smaller in the age group between 20 and 25 years (mean value of both ANW and MNW is less than 1st quartile). However, after the age of

Table 3 Mean values of ANW, MNW, NL, PTL, IC distance, AT distance, and percentiles of ANW, MNW, NL, and PTL of 25 cases

	ANW	MNW	PTL	NL	AT	IC
Mean	27.7024	30.7496	39.2604	53.8484	15.7475	11.815
Median	28.1000	32.0500	38.9800	56.0000	16.42	14.36
SD	2.82120	3.89572	9.49341	6.67189	11.21627	7.580
25%	25.6900	27.1400	32.3200	48.6700		
50%	28.1000	32.0500	38.9800	56.0000		
75%	30.2000	33.0750	44.3400	59.6250		

Abbreviations: ANW, anterior notch width; AT, apicotectal; IC, interpedunculoclival; MNW, maximum notch width; NL, notch length; PTL, posterior tentorial length; SD, standard deviation.

Table 4 Frequency and percentage of various types of incisura

Groups	Frequency	Percent
Wide (MNW more than 3rd quartile and NL between 1st and 3rd quartile)	2	8
Narrow (MNW less than 1st quartile and NL between 1st and 3rd quartile)	1	4
Short (NL less than 1st quartile and MNW between 1st and 3rd quartile)	1	4
Large (MNW more than 3rd quartile and NL more than 3rd quartile)	4	16
Typical (MNW between 1st and 3rd quartile and NL between 1st and 3rd quartile)	10	40
Long (NL more than 3rd quartile and MNW between 1st and 3rd quartile)	1	4
Small (MNW less than 1st quartile and NL less than 1st quartile)	5	20
Mixed (MNW more than 3rd quartile and NL less than 1st quartile or NL more than 3rd quartile and MNW less than 1st quartile)	1	4

Abbreviations: MNW, maximum notch width; NL, notch length.

Table 5 Age-dependent mean value

Age group (y)	ANW mean	MNW mean	PTL mean	NL mean
20–25	22.1800	24.0500	43.1600	41.5000
40–45	29.0333	32.2667	32.7667	57.0667
51–55	29.1760	32.1880	30.6880	60.7380
61–65	28.2333	31.7400	32.8467	54.2167

Abbreviations: ANW, anterior notch width; MNW, maximum notch width; NL, notch length; PTL, posterior tentorial length.

Table 6 Age-wise distribution of tentorial incisura

Age group (y)	Total no. of cases	Wide	Narrow	Short	Large	Typical	Long	Small	Mixed
20–25	2							2	
45–50	3				1	2			
51–55	5				3		1		1
56–60	2					2			
61–65	3					3			

Table 7 Rate of deterioration of GCS in wide and other tentorial groups

	Group	No. of patients	Mean	SD
Rate of deterioration of GCS	1.00	4	2.7300	0.69995
	2.00	7	1.0329	1.11476

Abbreviations: GCS, Glasgow coma scale; SD, standard deviation.

Table 8 *t*-Test to assess the significance

	<i>t</i>	Df	<i>p</i> Value	Mean difference	Lower	Upper
Rate of deterioration of GCS	-2.719	9	0.024	-1.69714	-3.10918	-0.28511

Abbreviation: GCS, Glasgow coma scale.

45 years, there is no significant age-dependent variation in tentorial size (►Table 6) and majority are typical. Large incisura was noted in the 45–50 and 51–55 years age groups.

All the 11 trauma cases were divided into two groups. All the trauma patients who had large tentorial incisura (MNW more than 3rd quartile and NL more than 3rd quartile) were considered as group 1; they were four patients. Others were considered as group 2; they were seven patients. Mean value of rate of deterioration of GCS per day for each group was recorded and compared (►Table 7). For the group with wide tentorial incisura, rate of deterioration of GCS was rapid with fall of more than 2 points per day, as compared with other tentorial types.

t-Test

Statistical analysis was done using *t*-test that showed that rate of deterioration of GCS is higher in patients who had large tentorial incisura compared with other groups, which is statistically significant ($p = 0.024$) (►Table 8).

Summary of Results

- Measurements of tentorial incisura in Indian population are comparable with those in western population, and there was no significant demographic variation.
- Distribution of various types of tentorial incisura shows that 10 cases had typical; 5 had small; 4 had large; 2 had wide; and the remaining 4 had narrow, short, long, and mixed type of tentorial incisura each.
- Age-wise distribution of tentorial size in autopsy cases shows that tentorial size was significantly small in the age group between 20 and 25 years (mean value of both ANW

and MNW is less than 1st quartile). However, after the age of 45 years, there was no significant variation in tentorial size with respect to age.

- On comparing rate of deterioration of GCS (per day) in trauma patients who had large tentorial incisura (MNW more than 3rd quartile and NL more than 3rd quartile) with others, it is significantly higher in patients who had large incisura compared with others, which was found to be statistically significant ($p = 0.024$).

Discussion

The tentorial incisura is the opening that connects the supra- and infratentorial spaces. The incisura is triangular in shape, base is situated anteriorly over dorsum sellae, and apex is situated posteriorly, dorsal to the midbrain and pineal gland. The incisural space is divided into anterior incisural, middle incisural, and posterior incisural spaces.² First one is anterior incisural space that is situated anterior to the brainstem, second is paired middle incisural space that is located lateral to the brainstem, and posterior incisural space that is located posterior to the brainstem. Some variations may be there in the tentorial incisura for some people because of the developmental defects³ of tentorium.

Tentorial herniation is the most common and important form of brain herniation. In descending herniation caused by the supratentorial mass lesions, uncus and parahippocampal gyri herniate downward through the incisura, and in ascending herniation,⁴ superior part of cerebellum herniates upward through the tentorial incisura. This brain herniation causes compression of vessels and stretching and compression of the

brainstem and cranial nerves.⁵ Compression of arteries causes arterial infarction and compression of vein causes venous infarction, increasing the edema and elevation of intracranial pressure (ICP). In herniation of the tentorial incisura and foramen magnum, it is believed to be caused by the progressive obliteration of subarachnoid space with the mass lesion. Thus, the important factor in preventing or treating herniation of the brain is maintenance or reestablishment of the subarachnoid space at the site of the herniation.⁶ Type of tentorial herniation depends on the position and rate of expansion of the lesion and size and shape of the incisura. Signs appear early when structures are deformed rapidly, but in chronic herniation, clinical signs develop very slowly. Wide tentorial notch, while not only increasing the chances of herniation, also causes more brain tissue to impact on the brainstem. Descending herniation is subdivided into anterior, posterior, and complete types. In the anterior type, uncus herniates to the interpeduncular and crural cisterns. This shift pushes the brainstem to opposite side and thus increases the space between free edge and the brainstem, thus facilitating a further shift of tissue through the tentorial aperture. As a result, the parahippocampal gyrus, from the splenium to the uncus, forces through the opening and the incisura becomes packed with herniated temporal lobe, deformed hypothalamus, and compressed midbrain. Compression of the midbrain reticular activating pathways causes decreased level of consciousness. Compression of ipsilateral cerebral peduncle causes the contralateral pyramidal signs, and if the lateral displacement of brainstem is very severe, contralateral cerebral peduncle is forced against the free edge, thus producing a groove on the peduncle called a Kernohan's notch, with the ipsilateral pyramidal signs. In the terminal stage, deformation of the midbrain causes decerebrate rigidity. Distortion and compression of the posterior hypothalamus cause cardiovascular, respiratory, and thermoregulatory⁷ disturbances. Pituitary stalk may stretch and compress against the dorsum sellae, thus causing diabetes insipidus. Oculomotor nerve courses between medial border of the uncus and the posterior petroclinoid fold and may be kinked or pressed here or between the posterior cerebellar artery (PCA) and superior cerebellar artery (SCA), or it may be stretched as the hernia pushes the midbrain posteriorly. First, the pupilloconstrictor fibers, which are concentrated over the superior surface of the nerve, are compressed. Later, somatic nerve fibers to the extraocular muscles are disturbed. In the initial stages, irritation of pupilloconstrictor fibers causes pupillary constriction, but later this usually gives way to a paralytic effect with pupillary dilation when the hernia enlarges. Optic tract is displaced medially and below, but the resulting visual loss is often masked by the deepening coma. Compression of the uncus, amygdala, parahippocampal gyrus, and hippocampal formation against the free edge of tentorium may cause memory, behavioral, and personality changes. Scarring of the hippocampal formation may cause seizures. Trochlear nerve usually escapes involvement in such herniation, but downward displacement of the brainstem may result in a palsy of abducent nerve by stretching it. Uncal herniation at the level of the notch was characterized and termed as "temporal pressure cone," "tentorial pressure

cone," and "transtentorial herniation of the brainstem"⁸⁻¹⁰ that were applied to this pathologic process. Experimentally, the group of signs and symptoms associated with herniation were reproduced in the monkey¹¹ and pathologically examined by Scheinker,¹⁰ Munro and Sisson,¹² and Schwarz and Rosner.¹³ Neuropathologic sequelae of tentorial herniation were found and demonstrated grooving and contralateral displacement of the brainstem, medial shift and herniation of the hippocampal gyrus, compression of the third cranial nerves, and brainstem hemorrhages. In 1958, Sunderland¹⁴ classified tentorial notches as broad or narrow, and Corsellis¹⁵ suggested that the patterns of herniation should be affected by notch size and shape. Although Sunderland and Corsellis demonstrated anatomical variations in the tentorial notch and the relation to the brainstem, well-defined classification system was not developed and no hypotheses were presented to explain patterns of transtentorial herniation and the variable clinical sequelae that arise after concussive and inertial brain injury. There are only a few studies in the literature, analyzing the tentorial incisura and classification of incisura, and none of those are from Indian population. Keeping in mind that there may be little demographic variations in the anatomy, the authors decided to analyze tentorial incisura in the Indian population. The studies available in the literature analyzed only the cadaveric tentorial incisura, but no studies were available in the literature analyzing fresh autopsy specimen. This study analyzed both cadaveric and autopsy specimen's tentorial incisura.

Notch Width and Transtentorial Herniation

The clinical manifestations and neuroanatomical distortions occurring in tentorial herniations are well established by several studies in the literature. Neuropathologic sequelae of tentorial herniation were found and demonstrated grooving and contralateral displacement of the brainstem, medial shift and herniation of the hippocampal gyrus, compression of the third cranial nerves, and brainstem hemorrhages. Despite the clinical pathologic understanding of transtentorial herniation, the reasons for the different signs of neurologic deterioration that appear among patients remain unclear. Similarly, the anatomical mechanism for the occurrence of the false localizing sign is understood, but its incidental occurrence has been difficult to explain. Dissimilarity in tentorial notch morphology and regional anatomy may help elucidate this phenomenon. It has been demonstrated that long and wide notches contain a greater amount of cerebellar tissue than short and narrow notches. Some variations may be there in the tentorial incisura for some people because of the developmental defects³ of tentorium. The relationship between tentorial incisura type and other herniations is not studied.

Tentorial incisura can be studied in detail with magnetic resonance imaging (MRI) noninvasively. The authors can anticipate sudden deterioration in patients having large tentorial incisura as per the observations in this study and in the literature. That way it will benefit the management of patients with head injury.

The authors also noticed in this study a strong relationship between large apertures and fast deterioration of patients because of tentorial herniation that is supported

by the study done by Rhoton.² These findings may have implications regarding the propensity for transtentorial herniation of cerebellar or cerebral parenchyma in the rostral or caudal direction, respectively. Thus, the important factor in preventing or treating herniation of the brain is maintenance or reestablishment of the subarachnoid space at the site of the herniation occurrence.¹⁶ For the surgery of the lesions around the incisura, incising the tentorium or retraction of tentorium is necessary most times. For the incision of the tentorium, incision should be posterior to the point of tentorium where trochlear nerve joins the tentorial edge. Sectioning of the tentorium also can be used rarely for reducing the supratentorial pressure and the pressure over the brainstem in the situation where the original pathology cannot be removed. This procedure was first used by Cushing for the control of ICP.

From this study, the authors have noticed that patients with head injury admitted with good GCS (GCS > 13) who had large tentorial incisura subsequently deteriorated faster compared with others who have lesser tentorial size, which is statistically significant.

From this study, the authors found that patients with good GCS and midline shift of less than 5 mm deteriorated fast and severely (implying massive brain tissue herniation) because of the availability of large tentorial notch. Hence it is worthwhile to ponder whether the accepted guidelines of more than 5 mm as the surgical indicator for decompression will hold good for the patients with large tentorial notch. Perhaps they require surgical intervention for the midline shift of less than 5 mm. This theory has to be validated with larger study and fast and reliable method of measuring the tentorial notch radiologically. This may produce new algorithm for managing patients with midline shift.

Conclusion

A study of tentorial incisura involving 10 cadavers and 15 autopsy specimen has led to following conclusions:

- There were no significant variations in the tentorial incisura measurements in Indian population compared with western population.
- Rate of deterioration of GCS is higher in patients who had large tentorial incisura compared with other groups, which is statistically significance. However, this is to be confirmed by further study using large groups of patients to be used for clinical applications.

Limitations of the Study

- The number of trauma patients used in this study is only 11. Study with large series of patients is necessary to confirm the finding that the large tentorial incisura size is associated with high chance of tentorial herniation.
- Age-wise distribution of patients is not equal; that is, there are only two patients in age range between 20 and 25 years, and there are no patients between 26 and 45 years, so age-wise classification of tentorial incisura may not be accurate.

- All the cases analyzed in this study are males, so variations in the tentorial size between sexes could not be analyzed.
- As the total number of cases is less, individual intracranial pathologies in relation to herniation are not studied.

Note

The article is not presented in any form in any conferences or not submitted in any another journal for publication.

Financial Support

None.

Conflict of Interest

None.

References

- 1 Ono M, Ono M, Rhoton AL Jr, Barry M. Microsurgical anatomy of the region of the tentorial incisura. *J Neurosurg* 1984;60(2):365-399
- 2 Rhoton AL Jr. Tentorial incisura. In: Rhoton's Cranial Anatomy and Surgical Approaches. Philadelphia, PA: Lippincott Wilkins & Williams; Chapter 5
- 3 Bisaria KK. Developmental defects of the tentorium cerebelli. *J Neurosurg* 1983;58(3):402-405
- 4 Osborn AG, Heaston DK, Wing SD. Diagnosis of ascending transtentorial herniation by cranial computed tomography. *AJR Am J Roentgenol* 1978;130(4):755-760
- 5 Needham CW, Bertrand G, Myles ST. Multiple cranial nerve signs from supratentorial tumors. *J Neurosurg* 1970;33(2):178-183
- 6 Langfitt TW, Weinstein JD, Kassell NF, Simeone FA. Transmission of increased intracranial pressure. within the craniospinal axis. *J Neurosurg* 1964;21:989-997
- 7 Morrell RM. Effect of cutting the tentorium cerebelli on the response to craniocerebral trauma. *J Neurosurg* 1960;17:374-384
- 8 Vincent C, David M, Thiebaut F. Le cône de pression temporel dans les tumeurs des hémisphères cérébraux. Sa symptomatologie; sa gravité; les traitements qu'il convient de lui opposer. *Rev Neurol* 1936;65:536-545
- 9 Jefferson G. The tentorial pressure cone. *Arch Neurol Psychiatry* 1938;40(5):857-876
- 10 Scheinker IM. Transtentorial herniation of the brain stem. A characteristic clinicopathologic syndrome; pathogenesis of hemorrhages in the brain stem. *Arch Neurol Psychiatry* 1945;53(4):289-298
- 11 Reid WL. Cerebral herniation through the incisura tentorii. A clinical, pathological, and experimental study. *Surgery* 1940;8(5):756-770
- 12 Munro D, Sisson WR Jr. The recognition and treatment of incisural herniation caused by craniocerebral injuries. *Trans Am Neurol Assoc* 1950;51:62-65
- 13 Schwarz GA, Rosner AA. Displacement and herniation of the hippocampal gyrus through the incisura tentorii. A clinicopathologic study. *Arch Neurol Psychiatry* 1941;46(2):297-321
- 14 Sunderland S. The tentorial notch and complications produced by herniations of the brain through that aperture. *Br J Surg* 1958;45(193):422-438
- 15 Corsellis JAN. Individual variation in the size of the tentorial opening. *J Neurol Neurosurg Psychiatry* 1958;21(4):279-283
- 16 Kusumi M, Fukushima T, Mehta AI, et al. Tentorial detachment technique in the combined petrosal approach for petroclival meningiomas. *J Neurosurg* 2012;116(3):566-573