

Functional Dissociation between Cognitive Estimation and Object Naming in Focal Temporal and Frontal Lobe Epilepsies

Isabella Braun¹ Michael Schwarz¹ Katrin Walther¹ Mark Stemmler² Burkhard S. Kasper¹
Hajo Hamer¹

¹Department of Neurology, Epilepsy Center Erlangen, University Hospital Erlangen, Erlangen, Germany

²Department of Psychology, Friedrich-Alexander University Erlangen-Nuernberg, Erlangen, Germany

Address for correspondence Michael Schwarz, MD, Department of Neurology, Epilepsy Center Erlangen, University Hospital Erlangen, Schwabachanlage 6, 91054 Erlangen, Germany (e-mail: michael.schwarz@uk-erlangen.de).

Int J Epilepsy 2018;5:44–49

Abstract

Purpose This study addresses specific impairments of cognitive estimation and object naming in patients with focal temporal lobe epilepsy (TLE) and frontal lobe epilepsy (FLE). It was investigated whether selective impairments can be explained by differences in lesion localization and functional hemispheric specialization.

Materials and Methods Seventy-eight patients (39 females, 39 males) with FLE and TLE were investigated using the German “Test zum Kognitiven Schätzen” and the “Boston Naming Test” to assess cognitive estimation abilities and visual object naming.

Questions According to theoretical models that support a distinct hemispheric dominance for estimation and naming, it was expected that epilepsy localization in the right hemisphere would result in impairments of cognitive estimation, whereas patients with left epileptogenic foci would show deficits in object naming.

Results In comparison to a healthy control group, a significant impairment in estimation performance was present in patients with right temporal mesial and right frontal epilepsy. A significant impairment of naming performance was found in patients with left temporal mesial, right temporal mesial, left temporal neocortical, and left frontal epilepsy. Overall, localization-dependent deficits were detected in patients with hippocampal sclerosis (cognitive estimation and object naming), right frontal epilepsy (cognitive estimation), and left temporal neocortical/left frontal epilepsy (object naming). In patients with right temporal neocortical epilepsy, no functional deficits were found.

Conclusion It is hypothesized that there is a functional dissociation between cognitive estimation processes and object naming due to different functional specialization of the left and right hemispheres, respectively.

Keywords

- ▶ cognitive estimation
- ▶ object naming
- ▶ confrontation naming
- ▶ temporal lobe epilepsy
- ▶ frontal lobe epilepsy
- ▶ cognition

Introduction

Neuropsychological dysfunctions in chronic epilepsies provide important evidence for the localization of the epileptic zone. These negative changes in cognitive functioning could include deficits in cognitive estimation of physical and metrical properties and object naming. Cognitive estimation requires problem-solving abilities for tasks where

exact solution is not known as well as certain strategies, such as checking of plausibility and semantic knowledge. Visual object naming includes the activation of the visual system, semantic knowledge, and memory as well as speech production. Cognitive estimation and object naming abilities are important for multiple everyday life challenges, for example, verbal communication with others and estimating the actual size of objects. Because of their importance it is

essential to know where these functions are localized in the human brain.

Several studies have shown evidence that the functionality of the right hemisphere is essential for cognitive estimation processes. Smith and Milner¹ examined patients with resection of the unilateral frontal lobe and the temporal lobe in comparison to a healthy control group. They found that patients with resection of the right frontal area had significant deficits in estimation of prices and objects in comparison to the control group. No deficits were seen in patients with left frontal lobectomy. Further evidence for the right lateralization of cognitive estimation has been provided.^{2,3} Tsujii et al⁴ explained the involvement of the right hemisphere in cognitive estimation with the “dual-process theory of reasoning”⁵: human thinking is based on two different processes, namely heuristic and analytic processing of tasks. Heuristic processes are fast, automatic, and dependent on certain existing beliefs and knowledge whereas analytical conclusions are characterized as slow, sequential, and deductive. In this context, Tsujii et al⁴ investigated the role of the inferior frontal lobe and the superior parietal lobe when subjects solved tasks that required deductive thinking, as it is the case with estimation tasks. The researchers identified the left inferior frontal lobe for the heuristic system and the bilateral superior parietal lobe for analytic thought processes. The role of the right inferior frontal lobe was to block the heuristic system when analytical deductive thinking was needed. Thus, the right frontal lobe seems to play a crucial role in suppressing nonrelevant thought processes when need to be solved that require cognitive estimation. Other authors found a dominance of the right hemisphere in deductive thinking (occipital and parietal regions).⁶ There are several findings regarding the impact of the left hemisphere in cognitive estimation. Studies have also shown a participation of the left hemisphere in tasks requiring cognitive estimation.^{7–10} Additionally, an impairment of cognitive estimation processes was found in patients with left-hemispheric epilepsy.⁷

Research has shown that anomia and aphasia are common symptoms of temporal lobe epilepsy (TLE).¹¹ Numerous studies have reported strong correlations between the temporal lobe and naming ability.^{12–15} Especially the left temporal lobe seems to play an important role in object naming. Hermann et al¹⁶ detected a significant decrease of visual naming performance after left temporal lobectomy. This could be explained by pathology of the left speech dominant hippocampus and lesions in speech-related temporal areas.^{17,18} In addition, the left frontal lobe also seems to play a crucial role in naming.^{19–21} Various neuroimaging studies conclude that naming involves a widespread neuronal network connecting both hemispheres.^{22–24} For visual naming, network-like activities have been found in bilateral occipitotemporal and parietal regions as well as in the left frontal cortex,²⁵ the left inferior temporal lobe as well as in the bilateral middle and inferior occipital cortex and inferior frontal parts.²⁶

In summary, there is evidence that both naming and estimating functions involve specific brain areas in the left and right hemispheres. Hence, the question arises if both functions are relatively dissociated regarding left or right hemispheric

involvement. Therefore, the aim of this study was to show that because of the hypothesized differences in hemispheric specialization, there are distinct deficit patterns in patients with lesional TLE and frontal lobe epilepsy (FLE) for cognitive estimation and object naming. Additionally, results of the patient groups were compared with those of healthy control group. In this study, two central hypotheses were tested:

1. Impairments of cognitive estimation are found especially in right hemispheric TLE and FLE.
2. Object naming deficits are found especially in left hemispheric TLE and FLE.

Materials and Methods

Participants

In this study, 78 patients (39 females, 39 males) from the Epilepsy Center Erlangen with pharmaco-resistant epilepsy and diagnosed with focal FLE and TLE were investigated. The mean age was 36.9 years (range: 17–66 years). Exclusion criteria included currently existing drug abuse and psychiatric or other neurologic disorders.

Patients were divided into six groups according to epilepsy localization in the temporal lobe (right mesial, right neocortical, left mesial, left neocortical focus) or the frontal lobe (left frontal, right frontal focus). Furthermore, patients with TLE were differentiated according to the criterion hippocampal sclerosis (HS) or lateral-neocortical localization. Overall, the following groups were investigated: left frontal (LF), right frontal (RF), left temporal mesial (LT-mes), left temporal neocortical (LT-neo), right temporal mesial (RT-mes), and right temporal neocortical (RT-neo). In addition, a control group consisting of 16 healthy patients (7 women, 9 men, age range: 20–75 years) without any history of psychiatric or neurologic disorders was included.

Study Design

The study was approved by the local medical ethics committee (Ethikkommission Friedrich-Alexander University). The study was performed in accordance with the code of ethics of the World Medical Association (Declaration of Helsinki) for experiments involving humans. Neuropsychological testing was administered by an experienced neuropsychologist. In this study, an experimental cross-sectional design was used. The independent variable was the localization of epilepsy (temporal or frontal, left or right hemisphere, mesial or neocortical temporal), and the dependent variables were estimation performance and performance in visual object naming.

Measures

To examine the relationship between cognitive estimation and object naming two standardized tests were used: the German “Test zum Kognitiven Schätzen” (test of cognitive estimation, TKS; Brand, Kalbe & Kessler, 2002)²⁷ and the Boston Naming Test (BNT; Kaplan, Goodglass & Weintraub, 1983).²⁸ The TKS includes four dimensions (size, weight, number, and time), each with four questions. An example for an item related to the dimension time is “How long does it take to travel from Hamburg to Munich by train?” Overall test performance was

given as the sum score of all correctly estimated items (total score: 16 points). The internal consistency (Cronbach's α) of the TKS is 0.77.²⁹ The BNT consisted of 60 line drawings that were presented in an order with increasing difficulty. A naming failure was noticed if the patient's response deviated from the target name either semantically or phonologically. Overall test performance was given as the sum score of all incorrectly named items. The internal consistency of the BNT ranged from $r = 0.78$ to 0.96 .³⁰

Statistical Analysis

Data analysis was performed using SPSS Statistics 22 (IBM Corp. Released 2013. IBM SPSS Statistics for Windows, Version 22.0. Ehningen, Germany). To detect statistically significant group differences, Welch analysis of variance (Welch-ANOVA) was performed with group as independent factor and performance in the neuropsychological tests BNT and TKS as dependent factors. The ANOVAs were followed by t -tests for independent samples. Furthermore, the correlation between the naming performance in the BNT and the estimation performance in the TKS was examined for patients with focus localization in the left and right hemispheres, respectively. The significance level was set $p < 0.05$. Demographic and clinical data of the patients and control subjects are presented in ►Table 1.

Results

Cognitive Estimation

Analysis of variance regarding estimation performance in the TKS revealed significant differences between the groups [$F(6, 36.86) = 5.51, p < 0.01$]. Post-hoc t -tests showed significantly worse estimation performance for the patient groups

RF ($t^{26} = -2.66, p = 0.01$) and RT-mes ($t^{27} = -3.63, p < 0.01$) compared with the control group. ►Table 2 specifies mean Z-scores and standard deviations (SD) in the TKS for each group. In patients with LF epilepsy, LT-mes epilepsy, LT-neo epilepsy, and RT-neo epilepsy, no deficit was found. ►Fig. 1 illustrates mean Z-scores for cognitive estimation (white bar) and naming (black bar) for all patient groups and the control group.

Object Naming

There was a significant group effect regarding performance in the BNT ($F(6, 36.49) = 4.09, p < 0.01$). Post-hoc t -tests showed worse performance for the LF ($t^{25} = -2.20, p < 0.03$), LT-mes ($t^{32} = -3.74, p < 0.01$), LT-neo ($t^{28} = -2.25, p < 0.03$), and RT-mes ($t^{27} = -3.30, p < 0.01$) group compared with the control group. As with cognitive estimation in patients with RF epilepsy, no

Table 2 Overview of means and standard deviations of correct responses for estimation performance (Z-scores)

Group	M	SD	p-Value
LF	-0.6	1.4	0.52
RF	-1.8	1.6	0.01
LT-mes	-1.0	1.6	0.18
LT-neo	-0.1	1.0	0.66
RT-mes	-2.2	1.3	0.00
RT-neo	-0.1	1.1	0.56
Controls	-0.2	1.5	

Abbreviations: LF, left frontal; LT-mes, left temporal mesial; LT-neo, left temporal neocortical; M, mean score; p , significance level; RF, right frontal; RT-mes, right temporal mesial; RT-neo, right temporal neocortical; SD, standard deviation.

Each p value represents the comparison between the control group and the corresponding patient group.

Table 1 Demographic and clinical characteristics

	LF (n = 11)	RF (n = 12)	LT-neo (n = 14)	LT-mes (n = 18)	RT-neo (n = 10)	RT-mes (n = 13)	Control group (n = 16)
Sex (% female)	36.4	58.3	57.1	38.8	50.0	61.5	43.7
Mean age in years (SD)	29.4 (8.8)	33.2 (12.0)	34.4 (15.9)	43.6 (13.3)	33.3 (12.8)	42.5 (14.0)	34.2 (19.2)
Mean age at seizure onset in years (SD)	20.3 (9.9)	15.9 (13.0)	27.7 (15.1)	25.8 (19.1)	23.4 (17.1)	19.6 (8.7)	
Mean duration of epilepsy in years (SD)	9.0 (7.3)	17.3 (10.9)	6.6 (9.1)	17.1 (15.2)	9.8 (8.6)	22.8 (14.9)	
Mean seizure frequency per month (SD)	6.4 (10.7)	12.6 (13.7)	5.5 (10.9)	3.8 (6.3)	4.1 (9.4)	6.4 (11.0)	
Handedness right (%)	100	91.6	92.8	85.0	100	84.6	
Pathology (%)							
Tumor	36.4	25.0	42.9	22.0	37.5	23.1	
Dysplasia	36.4	41.6	14.3	0.0	0.0	0.0	
Traumatic injury	18.0	0.0	0.0	0.0	0.0	0.0	
Cavernoma	0.0	0.0	42.9	0.0	25.0	0.0	
HS	0.0	0.0	0.0	66.7	0.0	61.5	
Cortical malformation	18.0	33.0	0.0	11.1	37.5	15.4	

Abbreviations: HS, hippocampal sclerosis; LF, left frontal; LT-mes, left temporal mesial; LT-neo, left temporal neocortical; RF, right frontal; RT-mes, right temporal mesial; RT-neo, right temporal neocortical; SD, standard deviation.

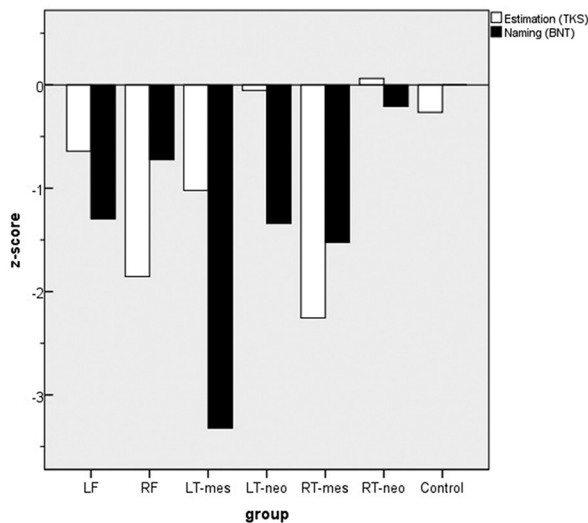


Fig. 1 Z-scores (means) for estimating performance and object naming. BNT, Boston naming test; Control, control group; LF, left frontal; LT-mes, left temporal mesial; LT-neo, left temporal neocortical; RF, right frontal; RT-mes, right temporal mesial; RT-neo, right temporal neocortical; TKS, Test zum Kognitiven Schätzen.

Table 3 Overview of means and standard deviations of correct answers in the BNT (Z-scores)

Group	M	SD	p-Value
LF	-1.3	2.0	0.04
RF	-0.7	1.7	0.18
LT-mes	-3.3	3.4	0.00
LT-neo	-1.3	2.1	0.03
RT-mes	-1.5	1.4	0.00
RT-neo	-0.2	1.0	0.61
Controls	0.0	1.0	

Abbreviations: BNT, Boston naming test; LF, left frontal; LT-mes, left temporal mesial; LT-neo, left temporal neocortical; M, mean score; *p*, significance level; RF, right frontal; RT-mes, right temporal mesial; RT-neo, right temporal neocortical; SD, standard deviation.

object naming deficit was found in RT-neo epilepsy, ► **Table 3** specifies mean scores and SD in the BNT for each group.

Relationship between Object Naming and Cognitive Estimation

Correlation coefficients between naming performance in the BNT and estimation performance in the TKS was examined separately for patients with epilepsy focus in the left (43 patients) and right (35 patients) hemispheres. The results showed no significant correlations between both functions for patients with left hemispheric focus ($r = 0.19$; $p = 0.22$) and right hemispheric focus ($r = 0.17$; $p = 0.33$). Thus, in both patient groups with left or right hemispheric lesions, there was no association between naming and estimation performance.

Discussion

The aim of this study was to determine whether there is a discrepancy between object naming and cognitive estimation in

patients with lesion-specific FLE and TLE. It was hypothesized that because of a distinct functional hemispheric specialization, naming deficits occur in patients with left hemispheric lesions, whereas estimation deficits occur in patients with right hemispheric lesions.

In this study, patients with LF, LT-neo, LT-mes, and TR-mes epilepsies showed deficits in object naming performance in comparison to a healthy control group. Deficits in confrontation naming performance are a common cognitive deficit in patients with lesions in the speech dominant left hemisphere.^{30,31} Furthermore, deficits in cognitive estimation could be detected in patients with RF- and RT-me foci. These findings support a right hemispheric specialization for cognitive estimation processes. A similar association was also found in studies investigating patients with extensive frontal lesions.^{1,3} In contrast to this study, these other studies did not apply to patients with focal epileptogenic lesions in the frontal and temporal lobes.

The relationship between cognitive estimation performance and hippocampal pathology (temporal mesial focus) highlights the special role of the right hippocampus for estimation processes. In this study, severe naming deficits were also detected in patients with RT-mes epilepsy. It seems that with right hippocampal pathology, there is a deterioration of both object naming and cognitive estimation performance. Thus, HS represents an entity that is associated with widespread functional disturbances, not only impairments in the recall of special properties³² but also deficits in other domains such as object naming and cognitive estimation.

Comparing patients with right hemispheric and left hemispheric foci, there was no correlation between object naming and estimation performance. Accordingly, in patients with epilepsy in the right or left hemisphere, object naming ability is relatively independent of cognitive estimation processes (and vice versa). For example, if a patient with an RF focus shows a severe deficit in one functional domain (e. g. cognitive estimation), a negative influence on the other domain (in this case object naming) is unlikely.

The results of this study indicate a functional dissociation between object naming and cognitive estimation in epilepsy patients. From a practical point of view, we suppose that usage of the TKS and the BNT in preoperative neuropsychological assessment of epilepsy patients can improve localization of epileptic focus. This approach may identify groups of patients with distinct neurobehavioral profiles that can be related to neuroimaging data and the underlying neurobiology.³³ Based on our results, cognitive estimation is relatively intact in patients with left frontal and left or right temporal neocortical lesions. Additionally, relatively good naming performance is evident in patients with RF and RT-neo localization of epilepsy. Therefore, it is reasonable that a standardized neuropsychological test battery combining visual object naming and cognitive tasks can effectively support localization of the epileptogenic focus.

Obviously, there are many factors involved in naming and cognitive estimation processes. Naming processes require rapid activation of semantic information that lead to a

precise specification of the corresponding lexical concept of the object. In contrast, cognitive estimation requires a relatively widespread array of semantic knowledge (e.g., physical properties of the objects) and problem-solving abilities (e.g., use of strategies, plausibility check). Overall, this involves a network of different brain areas (also in the parietal lobe) interacting with each other.

Our study has some limitations. First, the patient groups were relatively small and heterogeneous regarding the underlying pathology. Therefore, different pathologies were subsumed especially in patients with neocortical lesions. In contrast, the majority of patients with mesial temporal epilepsy were diagnosed with a relatively unique pathology (hippocampal sclerosis). A larger sample size as well as samples comparing specific pathologies (e.g., tumor, cavernoma, hippocampal sclerosis) could lead to more specific results. Specifically, a larger sample of patients with a frontal or temporal epileptic focus would provide more accurate mean values and avoid errors from testing a small number of possibly atypical samples.

The findings in this study should provide encouragement for further research. Future studies addressing specific neuropsychological functions in FLE and TLE regarding cognitive estimation, object naming, and other cognitive domains (e.g. material-specific memory deficits, other executive functions) will improve our understanding of the spectrum and diversity of cognitive deficits in epilepsy. The results of this study contribute to our understanding of the functional specialization of frontal and temporal lobes in both the hemispheres by demonstrating their specific role in object naming and estimation of physical and metrical properties.

Conclusions

This study shows a functional dissociation between cognitive estimation and object naming in patients with focal temporal and frontal lobe epilepsies. It is concluded that the individual cognitive profile is strongly influenced by the affected hemisphere and the involvement of mesial temporal structures (e.g., hippocampal sclerosis) or the frontal lobe. Focal epilepsies in the right (frontal localization, hippocampal sclerosis) and left (lateral-neocortical localization) hemispheres can be differentiated by specific estimation and object naming tests.

Funding

This research did not receive any specific grant from funding agencies in the public, commercial, or not-for-profit sectors. Declarations of interest: None.

Conflict of Interest

None.

References

- Smith ML, Milner B. Differential effects of frontal-lobe lesions on cognitive estimation and spatial memory. *Neuropsychologia* 1984;22(6):697–705
- Lewis PA, Miall RC. A right hemispheric prefrontal system for cognitive time measurement. *Behav Processes* 2006;71(2–3):226–234
- Morin C, Guigot J, Manai R, et al. Impairment in clock-time estimation following right hemisphere ischemic damage. *Brain Res Cogn Brain Res* 2005;22(2):305–307
- Tsujii T, Sakatani K, Masuda S, Akiyama T, Watanabe S. Evaluating the roles of the inferior frontal gyrus and superior parietal lobule in deductive reasoning: an rTMS study. *Neuroimage* 2011;58(2):640–646
- Evans JS. Dual-processing accounts of reasoning, judgment, and social cognition. *Annu Rev Psychol* 2008;59:255–278
- Osherson D, Perani D, Cappa S, Schnur T, Grassi F, Fazio F. Distinct brain loci in deductive versus probabilistic reasoning. *Neuropsychologia* 1998;36(4):369–376
- Upton D, Thompson PJ. General neuropsychological characteristics of frontal lobe epilepsy. *Epilepsy Res* 1996;23(2):169–177
- Maquet P, Lejeune H, Pouthas V, et al. Brain activation induced by estimation of duration: a PET study. *Neuroimage* 1996;3(2):119–126
- Woods AJ, Menneker M, Garcia-Rill E, et al. Bias in magnitude estimation following left hemisphere injury. *Neuropsychologia* 2006;44(8):1406–1412
- Rubia K, Schuri U, von Cramon DY, Poeppel E. Time estimation as a neuronal network property: a lesion study. *Neuroreport* 1997;8(5):1273–1276
- Wassermann EM, Blaxton TA, Hoffman EA, et al. Repetitive transcranial magnetic stimulation of the dominant hemisphere can disrupt visual naming in temporal lobe epilepsy patients. *Neuropsychologia* 1999;37(5):537–544
- Moore CJ, Price CJ. Three distinct ventral occipitotemporal regions for reading and object naming. *Neuroimage* 1999;10(2):181–192
- Oyegbile TO, Dow C, Jones J, et al. The nature and course of neuropsychological morbidity in chronic temporal lobe epilepsy. *Neurology* 2004;62(10):1736–1742
- Seidenberg M, Geary E, Hermann B. Investigating temporal lobe contribution to confrontation naming using MRI quantitative volumetrics. *J Int Neuropsychol Soc* 2005;11(4):358–366
- Bonelli SB, Powell R, Thompson PJ, et al. Hippocampal activation correlates with visual confrontation naming: fMRI findings in controls and patients with temporal lobe epilepsy. *Epilepsy Res* 2011;95(3):246–254
- Hermann BP, Perrine K, Chelune GJ, et al. Visual confrontation naming following left anterior temporal lobectomy: a comparison of surgical approaches. *Neuropsychology* 1999;13(1):3–9
- Davies KG, Bell BD, Bush AJ, Hermann BP, Dohan FC Jr, Jaap AS. Naming decline after left anterior temporal lobectomy correlates with pathological status of resected hippocampus. *Epilepsia* 1998;39(4):407–419
- Bell BD, Hermann BP, Woodard AR, et al. Object naming and semantic knowledge in temporal lobe epilepsy. *Neuropsychology* 2001;15(4):434–443
- Obler LK, Rykhlevskaia E, Schnyer D, et al. Bilateral brain regions associated with naming in older adults. *Brain Lang* 2010;113(3):113–123
- Damasio AR, Tranel D. Nouns and verbs are retrieved with differently distributed neural systems. *Proc Natl Acad Sci U S A* 1993;90(11):4957–4960
- Daniele A, Giustolisi L, Silveri MC, Colosimo C, Gainotti G. Evidence for a possible neuroanatomical basis for lexical processing of nouns and verbs. *Neuropsychologia* 1994;32(11):1325–1341
- Vihla M, Laine M, Salmelin R. Cortical dynamics of visual/semantic vs. phonological analysis in picture confrontation. *Neuroimage* 2006;33(2):732–738
- Tomaszewski Farias S, Harrington G, Broomand C, Seyal M. Differences in functional MR imaging activation patterns associated with confrontation naming and responsive naming. *Am J Neuroradiol* 2005;26(10):2492–2499

- 24 Springer JA, Binder JR, Hammeke TA, et al. Language dominance in neurologically normal and epilepsy subjects: a functional MRI study. *Brain* 1999;122(Pt 11):2033–2046
- 25 Liljeström M, Tarkiainen A, Parviainen T, et al. Perceiving and naming actions and objects. *Neuroimage* 2008;41(3):1132–1141
- 26 Abrahams S, Goldstein LH, Simmons A, et al. Functional magnetic resonance imaging of verbal fluency and confrontation naming using compressed image acquisition to permit overt responses. *Hum Brain Mapp* 2003;20(1):29–40
- 27 Brand M, Kalbe E, Kessler J. Test zum kognitiven Schätzen: TKS. Göttingen: Beltz Test; 2002:3–28
- 28 Kaplan E, Goodglass H, Weintraub S. Boston Naming Test. Philadelphia, PA: Lea & Febiger; 1983:1–4
- 29 Pedraza O, Sachs BC, Ferman TJ, Rush BK, Lucas JA. Difficulty and discrimination parameters of Boston naming test items in a consecutive clinical series. *Arch Clin Neuropsychol* 2011;26(5):434–444
- 30 Raymer AM, Foundas AL, Maher LM, et al. Cognitive neuropsychological analysis and neuroanatomic correlates in a case of acute anomia. *Brain Lang* 1997;58(1):137–156
- 31 Sawrie SM, Martin RC, Gilliam FG, et al. Visual confrontation naming and hippocampal function: a neural network study using quantitative (1)H magnetic resonance spectroscopy. *Brain* 2000;123(Pt 4):770–780
- 32 Smith ML, Milner B. Right hippocampal impairment in the recall of spatial location: encoding deficit or rapid forgetting? *Neuropsychologia* 1989;27(1):71–81
- 33 Hermann B, Loring DW, Wilson S. Paradigm shifts in the neuropsychology of epilepsy. *J Int Neuropsychol Soc* 2017; 23(9–10):791–805