"Post Traumatic Brain Abscess Mimicking as Pneumatocele": An Uncommon Presentation

Rahul Varshney[1] Nitin Bhakal[1] L.N. Gupta[1] Sharad Pandey[1] Rajesh Sharma[1]

[1]Department of Neurosurgery, PGIMER & Dr Ram Manohar Lohia Hospital, New Delhi, India

Address for correspondence Rahul Varshney, MS, MCh, Department of Neurosurgery, PGIMER & Dr Ram Manohar Lohia Hospital, Baba Kharak Singh Marg, New Delhi 110001, India (e-mail: rahul_varshney1@rediffmail.com).

Indian J Neurotrauma 2018;15:36–38

Abstract

Pneumatocele is a very rare complication that follows head injury. Pneumatocele can result due to a craniodural fistula, formed either after a fracture involving air sinuses, roof of middle ear, or depressed fracture of skull. Gas-containing brain abscess is a life-threatening condition, which requires immediate diagnosis and prompt therapeutic intervention. The predisposing factors include hematogenous spread, contiguous infection, and abnormal fistulous communication due to head injury. This is a rare case in which the patient had a history of head trauma due to road traffic accident with frontal contusion and small pneumocephalus, which was managed conservatively 2 years earlier followed by cerebrospinal fluid (CSF) rhinorrhea after 2 months, which was also managed by nonsurgical management. He presented with intractable seizures and features of raised intracranial pressure (ICP) with imaging suggestive of air-containing cavity in frontal region (pneumatocele). Intraoperatively, there was brain abscess with dural defect for which abscess was excised, and dural repair with exteriorization of frontal sinus was done.

Keywords
- ► pneumatocele
- ► brain abscess
- ► rhinorrhea
- ► craniodural fistula

Introduction

Post-traumatic pneumatocele is very rare presentation on imaging. It can occur when the air enters into the cranium via a fracture involving air sinuses or middle ear roof or depressed fracture of skull, which may lead to a craniodural fistula.[1] Source of infection in pneumatocele may be air sinuses or gas-producing organism.[2] We report a case of brain abscess presented as post-traumatic pneumatocele.

Case Report

A 26-year-old male patient presented to neurosurgical emergency with multiple episodes of generalized tonic-clonic seizures and headache for the past 10 days. The patient had a history of head trauma due to road traffic accident 2 years earlier with a history of loss of consciousness, seizures, and vomiting. Non-contrast computed tomography (NCCT) of the head at that time was suggestive of left frontal hemorrhagic contusion with pneumocephalus with fractured left frontal sinus (inner table). The patient was managed conservatively with antiepileptics and antibiotics and was discharged with no neurological deficit. The patient was again admitted after 2 months of trauma with complaint of cerebrospinal fluid (CSF) rhinorrhea with no meningeal signs, which was managed conservatively. Subsequently, the patient was discharged uneventfully. The patient had a history of intractable seizures, and he was on three antiepileptics (phenytoin, sodium valproate, and clobazam) (►**Figs. 1** and **2**).

The patient was planned for left frontal craniotomy with repair of dural rent and decompression of pneumatocele. However, intraoperatively after left frontal craniotomy, dural defect was identified from which gliotic brain was herniating and adhered to bone, adhered brain was separated, and there was evidence of thick yellowish (purulent) collection. Dura was opened, and we found large cavity filled with thick purulent collection in the left frontal region, which was corresponding to pneumatocele on imaging. Abscess cavity was excised completely and was sent for analysis and histopathology. The fractured fragments of air sinuses were removed

received
July 9, 2018
accepted
August 20, 2018
published online
October 3, 2018

Copyright ©2018 Neurotrauma Society of India

DOI https://doi.org/10.1055/s-0038-1673528.
ISSN 0973-0508.

This document was downloaded for personal use only. Unauthorized distribution is strictly prohibited.

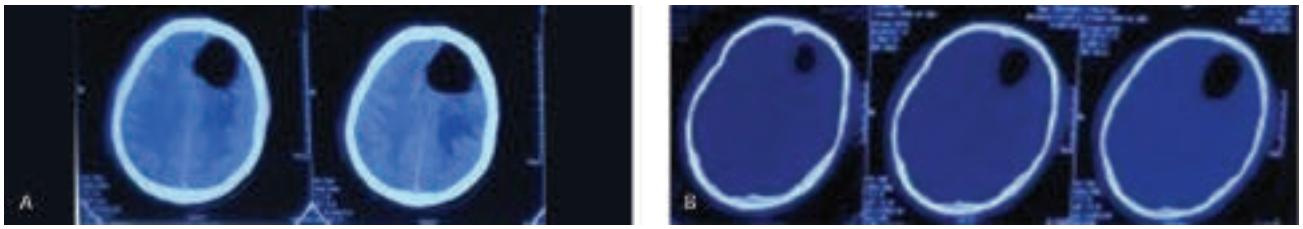

Fig. 1 NCCT head was done in April 2018 suggestive of left frontal sinus inner table fracture with 7 cm × 5 cm well-circumscribed hypodense lesion (HU = −1000-air) in the left frontal region with gliotic changes in the left frontal lobe; bone window was also suggestive of air in left frontal region. NCCT, non-contrast computed tomography.

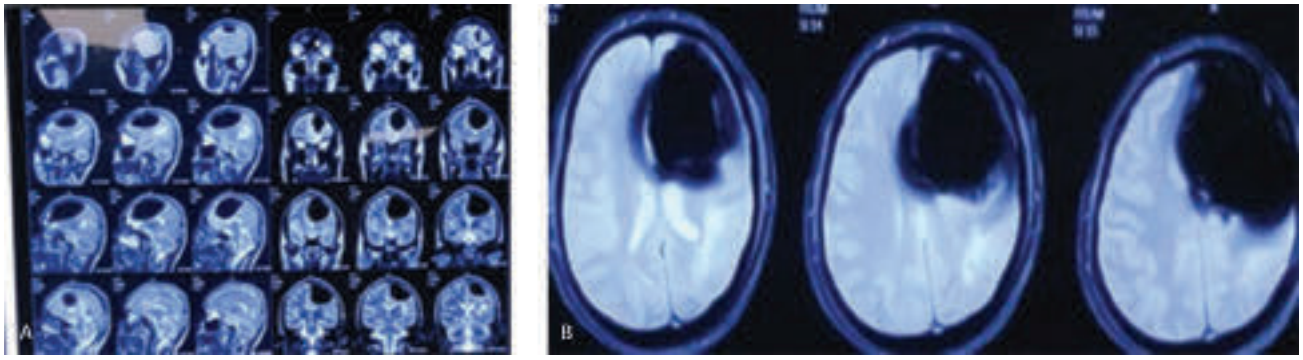

Fig. 2 MRI brain suggestive of 7.1 cm × 5.1 cm × 4.9 cm area of signal void on all sequences suggestive of pneumatocele with mild perifocal gliosis/edema in the left frontal lobe. Mass effect as effacement of sulcal spaces, midline shift of 7 mm toward the right side, compression of corpus callosum, and left lateral ventricle.

along with the sinus mucosa. The frontal sinus was exteriorized with pericranial graft, and the dual defect was repaired with inlay pericranial graft.

Postoperative period was uneventful, patient improved clinically gradually, and there was no CSF rhinorrhea. Postoperative NCCT of the head was suggestive of adequate decompression of abscess with mild perilesional edema with decrease in mass effect and midline shift. Postoperative period was uneventful, and headache was relieved. Seizures also improved. Intravenous (IV) antibiotics were administered in postoperative period, and the patient was discharged on oral antibiotics and antiepileptics.

Pus culture was sterile with no growth of organism, as patient was already on IV antibiotics (►**Fig. 3**).

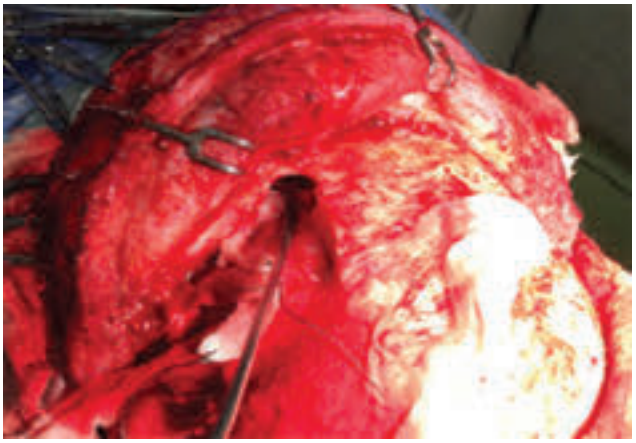

Fig. 3 Intraoperative picture showing bicoronal flap and left frontal craniotomy, with fractured inner table of left frontal sinus, dural defect in frontal region with gliotic brain and purulent collection coming from cavity in the left frontal region corresponding to intracranial pneumatocele on imaging.

Discussion

In an unintervened patient (non-iatrogenic), presence of intracranial gas or air is considered abnormal. This intracranial air is possible when a craniodural fistula develops.[1] It may happen as a ball valve mechanism, which allows air to enter but not exit the cranium, or as a CSF leak where air enters as fluid leaves the intracranial space.[3] Air in the intracranial spaces is diagnostic for a dural tear and for a potential CSF fistula somewhere in the intracranial cavity.

Pneumocephalus after intracranial surgery or as a result of any eroding infection or neoplasm is common. Other causes of pneumocephalus include gunshot injury,[4,5] frontal sinus osteoma,[6,7] intraventricular drainage,[8] spontaneous cure of intracerebral hematoma by drainage into middle ear and replacement of the hematoma by air,[9] and following manually operated ventilation with a mask.[10] Air in brain parenchyma following head injury involving the fracture of air sinuses could also be due to cortical laceration following impingement of fractured fragments of air sinuses into the brain parenchyma and air dissecting into the parenchyma and collecting into a cavity. Clinically, patients present with nonspecific symptoms such as headache, nausea, and vomiting.[11] Rare presentation can be frontal syndrome.[12] Immediately after trauma the site of CSF fistula is blocked due to edema

This document was downloaded for personal use only. Unauthorized distribution is strictly prohibited.

in the acute stage, so presentation with CSF rhinorrhea is late in a case of head injury. As the inflammation subsides, the edema resolves, and patient presents with CSF rhinorrhea days to weeks after the trauma. Diagnosis of pneumatocele can be done by plain X-ray, which may show an air fluid cavity or a collection of air inside the skull along with evidence of skull base fractures in post-traumatic cases. Computed tomography (CT) demonstrates the location of pneumatocele and may show associated air–fluid level, mass effect, and surrounding edema, and there may be rim enhancement of the cavity following contrast administration.[13] Imaging is required in these cases to rule out possibility of gas forming cerebral abscesses. Pneumatocele appears as a hypodense area on CT scan (–900 to –1000 HU) and hypointense in MRI in all sequences. MRI being more sensitive than CT can also demonstrates meningitis, which is one of the common complications of pneumocephalus. MRI is helpful for planning surgery and further management as it localizes and demonstrates the defect.

Prompt treatment of pneumatocele is necessary after diagnosis of the cause as it can lead to abscess formation by acquiring infection from the sinodural fistula.[1] Gas-containing brain abscess may result from glucose fermentation by gas-forming organisms or escape of air into the cranium via an abnormal communication between the exterior and the cranium. Following a surgery or head trauma, air can escape into the cranium through an abnormal fistulous communication which can also lead to formation of gas-containing abscess. Pneumocephalus is common in patients with basilar skull fracture or following surgery. However, to our knowledge, the incidence and causative pathogens of gas-containing abscess due to air entrance into the cranium following head trauma or surgery have never been studied. Frontal lobe is the most common location of abscess in patients with a history of basilar skull fracture or surgery involving the skull base. A rational explanation is contiguous infection from an abnormal communication between the exterior and the cranium due to previous neurosurgical insult. The management of gas-containing brain abscess remains a controversial issue. The presence of gas within the abscess cavity has been considered an indication for surgical excision. In the case of gas-containing abscess following recent penetrating head injury, it is essential to remove all bits of foreign material, bone chips, and necrotic tissue. For patients with a history of basilar skull fracture or surgery involving the skull base, craniotomy to excise the abscess and search for the potential fistulous communication through the cranium to prevent recurrent infection is considered. Craniotomy is performed to excise the gas-containing brain abscess as they can cause rapid clinical deterioration and even death.[14–16] Early diagnosis, appropriate antibiotic use, and meticulous surgical treatment are the only ways to obtain a favorable outcome.

Our patient had no features or history suggestive of infective pathology. Moreover, the history was prolonged with 2-year interval, and the patient had no complaint other than repetitive seizures, which had been controlled for the past 6 months with antiepileptic drugs. Previous imaging was not suggestive of any signs of brain abscess or likely formation of brain abscess. On searching the internet and PubMed, we could not find any radiological images with such an enormous amount of gas-filled space-occupying lesions. The preoperative MRI also suggested a pneumatocele with no perifocal edema. All these features made us to conclude it as a case of post-traumatic pneumatocele.

Conclusion

If pneumatocele is diagnosed on imaging, it should be treated promptly after diagnosis of cause as it can lead to abscess formation acquiring infection from the sinodural fistula.

Conflict of Interest

None.

References

1 Erahn Y, Karabiyikolu M, Mutluer S. Air in intracerebral haematoma. Journal of Neurosciences (Turkish) 1999;16:1–3
2 Su TM, Lan CM, Lee TH, Hsu SW. Gas-containing brain abscess: etiology, clinical characteristics, and outcome. Kaohsiung J Med Sci 2014;30(12):619–624
3 Orebaugh SL, Margolis JH. Post-traumatic intracerebral pneumatocele: case report. J Trauma 1990;30(12):1577–1580
4 Shoung HM, Sichez JP, Pertuiset B. The early prognosis of craniocerebral gunshot wounds in civilian practise as an aid to the choice of treatment. A series of 56 cases studied by the computerized tomography. Acta Neurochir (Wien) 1998;74(1-2):27–30
5 Portmann D, Herman D, Got M. [Pneumatocele caused by ballistic injury of the anterior stage of the skull base, a case report]. Rev Laryngol Otol Rhinol (Bord) 1990;111(3):239–243
6 Rappaport JM, Attia EL. Pneumocephalus in frontal sinus osteoma: a case report. J Otolaryngol 1994;23(6):430–436
7 Mendelsohn DB, Hertzanu Y, Friedman R. Frontal osteoma with spontaneous subdural and intracerebral pneumatocele. J Laryngol Otol 1984;98(5):543–545
8 Witcombe JB, Torrens MJ, Gye RS. Intracerebral pneumatocele: an unusual complication following intraventricular drainage in case of benign intracranial hypertension. Neuroradiology 1976;12(3):161–163
9 Bose B, Kraut W, Osterholm JL. Intracerebral hematoma: spontaneous cure by drainage into the middle ear. A case report. Neurosurgery 1982;10(1):103–104
10 Dacosta A, Billard JL, Gery P, Vermesch R, Bertrand M, Bertrand JC. Posttraumatic intracerebral pneumatocele after ventilation with a mask: case report. J Trauma 1994;36(2):255–257
11 Huang CF, Chou TY, Chang CK. Traumatic tension pneumocephalus—intracerebral pneumatocele: a case report. Gaoxiong Yi Xue Ke Xue Za Zhi 1992;8(2):113–116
12 Bayassi S. [Delayed post-traumatic intracerebral pneumatocele: a case report and literature review]. Neurol Neurochir Pol 1997;31(5):1047–1051
13 Mendelsohn DB, Hertzanu Y. Intracerebral pneumatoceles following facial trauma: CT findings. Radiology 1985;154(1):115–118
14 Cohen JE, Mierez R, Tsai EC. Postcraniotomy gas-containing brain abscess: a neurosurgical emergency. Case report. Surg Neurol 1999;51(5):568–570
15 Cho KT, Park BJ. Gas-forming brain abscess caused by Klebsiella pneumoniae. J Korean Neurosurg Soc 2008;44(6):382–384
16 Shih HI, Lee HC, Chuang CH, Ko WC. Fatal Klebsiella pneumoniae meningitis and emphysematous brain abscess after endoscopic variceal ligation in a patient with liver cirrhosis and diabetes mellitus. J Formos Med Assoc 2006;105(10):857–860

This document was downloaded for personal use only. Unauthorized distribution is strictly prohibited.