

Suspensionplasty using Anchors and Non-Absorbable Sutures for Rhizarthrosis

Plastia de suspensión usando usando anclajes y suturas no absorbibles para rizartrrosis

Samuel Ribak¹ Giovanna Colnago Antunes de Carvalho¹ Ricardo Kaempf de Oliveira^{2,3}

¹Hand Surgery Service, Pontifícia Universidade Católica de Campinas, Campinas, SP, Brazil

²Department of Hand Surgery, Hospital Infantil Santo Antônio da Santa Casa, Porto Alegre, RS, Brazil

³Hand Surgery Unit, Hospital Mãe de Deus, Porto Alegre, RS, Brazil

Address for correspondence Samuel Ribak, MD, PhD, Pontifícia Universidade Católica de Campinas (PUC-Campinas), Rua General Fernando Vasconcelos de Albuquerque, 775, Cotia (SP), 06711-020, Brazil (e-mail: ribaksamuel@yahoo.com.br).

Rev Iberam Cir Mano 2018;46:87–95.

Abstract

Objective To analyze the clinical and radiographic results of patients with rhizarthrosis who underwent surgical treatment for resection of the trapezium bone using a fixation system with anchors and a non-absorbable suture.

Methods Fifteen patients with a mean age of 60.26 years old were studied. Fourteen patients had type III rhizarthrosis and 1 had type II rhizarthrosis, according to the Eaton-Littler classification. Data on the professional activity, affected side, and hand dominance were collected and evaluated for the presence of pain, degree of joint movement of the radial abduction of the thumb, opposition, and palmar grip strength. The upper limb function was assessed using the Quick Disabilities of the Arm, Shoulder and Hand (DASH) questionnaire. The patients were subjected to pre and postoperative radiographic examinations, by which the scaphoid-first metacarpal height was measured using the oblique view of the hand. Suspensionplasty by fixation was then performed using a system of two 2.0 mm threaded bone anchors and a 2.0 mm Ethibond (Ethicon, Inc., Somerville, NJ, USA) suture wire. Finally, the trapezium bone was resected.

Results The mean follow-up duration was 21.50 ± 5.02 months. The patients showed a mean score of 1.6 in the final evaluation using the visual analog scale. The degree of joint movement of the abduction of the thumb was on average 61.67° postoperatively and 59.73° preoperatively. There was an improvement in thumb opposition and a significant improvement in the upper limb function, as assessed using the Quick DASH method. The scaphoid-first metacarpal height had a proximal migration of $\sim 50\%$ in the postoperative radiographs. The mean time to return to daily living activities was 20.7 days, 24.7 days to practical life activities, and 101.3 days to work activities. There was no correlation between the level of professional activity and the incidence of the disease.

Conclusions Trapeziectomy and suspensionplasty, using an anchorage system and a non-absorbable suture, shows a significant improvement in pain, opposition, and

Keywords

- ▶ Osteoarthritis
- ▶ trapezometacarpal joint
- ▶ trapeziectomy
- ▶ suspensionplasty
- ▶ anchorage

received
September 12, 2017
accepted
September 6, 2018
published online
November 1, 2018

DOI <https://doi.org/10.1055/s-0038-1675393>.
ISSN 1698-8396.

Copyright © 2018 Thieme Revinter
Publicações Ltda, Rio de Janeiro, Brazil

License terms



function of the affected upper limb, and is efficient for the surgical treatment of rhizarthrosis. It allows for a rapid return to daily living activities with a low risk for complications.

Resumen

Objetivo Analizar los resultados clínicos y radiográficos de pacientes con rizartrrosis sometidos a tratamiento quirúrgico para la resección del trapecio utilizando un sistema de fijación con anclajes y una sutura no reabsorbible.

Material y Método Se estudiaron 15 pacientes con una edad media de 60,26 años. Catorce pacientes tenían rizartrrosis tipo III y uno rizartrrosis tipo II, de acuerdo con la clasificación de Eaton-Littler. Los datos sobre la actividad profesional, el lado afectado y la dominancia de la mano se recogieron y se evaluaron en cuanto a la presencia de dolor, el grado de movimiento articular de la abducción radial del pulgar, la oposición y la fuerza de agarre. La función del miembro superior se evaluó mediante el cuestionario Quick DASH. Los pacientes fueron sometidos a exámenes radiográficos preoperatorios y postoperatorios, mediante los cuales se midió la altura entre el primer metacarpiano y el escafoides en la proyección oblicua de la mano. La plastia de suspensión se realizó mediante fijación usando un sistema de dos anclajes óseos roscados de 2,0 mm y un alambre de sutura Ethibond® de 2,0 mm (Ethicon INC, Somerville, Nueva Jersey). Finalmente, el hueso del trapecio fue resecado.

Resultados El tiempo medio de seguimiento fue $21,50 \pm 5,02$ meses. Los pacientes mostraron una puntuación media de 1,6 en la evaluación final usando la escala analógica visual. El grado de movimiento articular de la abducción del pulgar fue en promedio de 61.67° postoperatorio y de 59.73° preoperatorio. Hubo una mejora en la oposición del pulgar y una mejora significativa en la función del miembro superior, según se evaluó mediante el método Quick DASH. La altura entre el primer metacarpiano y el escafoides lugar tuvo una migración proximal de aproximadamente 50% en las radiografías postoperatorias. El tiempo promedio para regresar a las actividades de la vida diaria fue de 20,7 días, 24,7 días para las actividades de la vida práctica y 101,3 días para las actividades laborales. No hubo correlación entre el nivel de actividad profesional y la incidencia de la enfermedad.

Conclusiones La trapepectomía y la plastia en suspensión, utilizando un sistema de anclaje y una sutura no reabsorbible, muestran una mejoría significativa en el dolor, la oposición y la función de la extremidad superior afectada, y es eficiente para el tratamiento quirúrgico de la rizartrrosis. Permite un retorno rápido a las actividades de la vida diaria con bajo riesgo de complicaciones.

Palabras clave

- ▶ artrosis
- ▶ articulación traopermetacarpiana
- ▶ trapepectomía
- ▶ suspensoplastia
- ▶ anclaje

Introduction

Trapeziometacarpal osteoarthritis, or rhizarthrosis, is a common condition that primarily affects women aged between 50 and 70 years old with an insidious onset and is aggravated by significant hand use.¹ The symptoms of the disease include pain at the base of the thumb, decreased grip and pinch strength, as well as progressive incapacity to perform daily living and work activities.

The initial treatment is conservative. Surgical treatment may be indicated for cases that evolve with persistent painful and disabling conditions for > 6 months.^{2,3} The goal of the surgical treatment is to provide relief from pain and ensure a stable and mobile thumb.

In the early stages of the Eaton-Littler classification, the techniques used for reconstruction of the anterior oblique

ligament and metacarpal osteotomy are surgical options.^{4,5} In the most advanced stages of Eaton-Littler, namely III and IV, the techniques most described in the literature are trapeziectomy,⁶ arthrodesis,⁷ arthroplasty,^{8,9} and trapeziectomy associated with tenosuspension,^{10,11} most of them showing good results. What differentiates them are the incidence of complications, the period of immobilization, rehabilitation, and time to return to work.

Trapeziectomy eliminates the friction between the degenerated joints, relieving the pain. However, proximal migration of the first metacarpal is not prevented.¹² Trapeziectomy associated with tendon interposition and/or tenosuspension has gained popularity because it maintains an adequate space between the scaphoid and the base of the first metacarpal. However, the technique has the inconvenience of totally or partially disabling a tendon.¹³

Maintaining an adequate space between the first metacarpal and the scaphoid is important. Reducing the space may have implications, such as loss of function, pain, and loss of joint amplitude. Suspensionplasty refers to the use of any technique to maintain the first metacarpal anatomically aligned to the base of the second, thus reducing the space previously occupied by the trapezoid.¹⁴

The “hematoma distraction” suspensionplasty technique consists of maintaining the metacarpal height by fixating the first metacarpal to the second using Kirschner wires, which should remain there for approximately 4 weeks.¹⁵ The disadvantages of the technique are a long time of fixation, rigidity, and delay in the return of activities.

The so-called Tightrope (Arthrex, Inc. Naples, FL, USA) method, a device consisting of two stainless steel knobs and Fiberwire (Arthrex, Inc., Naples, FL, USA), can be an alternative to Kirschner wires. It is inserted at the base of the first metacarpal and the metadiaphyseal junction of the second metacarpal.¹⁶ Correct tensioning of the sutures maintains the metacarpal height, prevents proximal migration, and enables early rehabilitation.¹⁷ In our context, this device is expensive, making difficult its routine use.

The ideal surgical treatment would be using the suspensionplasty system, which has adequate stability and the advantage of early rehabilitation without performing a tendon transfer or using high-cost material. We hypothesize that using bone anchors and Ethibond (Ethicon, Inc., Somerville, NJ, USA) non-absorbable suture, which has a high tensional force, low tissue reaction, and allows the making of secure knots, may ensure the achievement of the desired result of suspensionplasty.

The present study aimed to analyze the clinical and radiographic results of patients with rhizarthrosis who underwent surgical treatment for resection of the trapezium bone and insertion of a fixation and suspension system with anchors and a high-strength non-absorbable wire.

Methods

This is a prospective study conducted after the approval of the Ethics and Research Committee of the Plataforma Brasil. The study sample consisted of 15 patients, 4 men (26.7%) and 11 women (73.3%), aged between 50 and 70 years old (mean age of 60.26 years old). (►Table 1) Seven patients had involvement of the dominant side.

Patients with surgical indication for rhizarthrosis in stages II and III of the Eaton-Littler classification were included.

Individuals who had previously undergone surgical treatment of diseases at the site and patients not eligible for surgical treatment were excluded from the present study.

According to the Eaton-Littler radiographic classification, 14 patients were in stage III, and one was in stage II.

The patients were evaluated in the pre and postoperative period for pain level using the visual analog scale (VAS), joint movement of the abduction of the thumb, level of opposition, and palmar grip strength.

The upper limb function was obtained using the Quick Disabilities of the Arm, Shoulder and Hand (DASH) questionnaire.

Table 1 Demographics of patients included in the study

Patient	Age	Gender	Side	Eaton E Littler	Activity
1	64	F	R	III	Moderate
2	64	F	L	III	Moderate
3	65	M	L	III	Heavy
4	65	M	R	III	Heavy
5	70	M	L	III	Moderate
6	63	F	L	II	Light
7	64	F	L	III	Light
8	50	M	R	III	Heavy
9	54	F	L	III	Heavy
10	56	F	R	III	Moderate
11	59	F	L	III	Heavy
12	62	F	R	III	Heavy
13	59	F	R	III	Moderate
14	59	F	L	III	Moderate
15	50	F	R	III	Moderate

The patients were subjected to radiographic examination of the hand in the anteroposterior (AP), oblique (OBL), and with their forearm kept hyperpronated (Roberts view).

In the AP view, the radiographic stage of the disease (Eaton-Littler) was determined, and the height of the trapezoidal space was measured.

In the postoperative period, lateral digital pinch strength, return to daily living (light personal tasks concerning self-care), to practical living (set of household tasks and intense daily living activities), and to work activities were evaluated.

Surgical Technique

First, the patient was positioned in the horizontal supine position, and brachial plexus block and limb exsanguination were performed. The procedure began with a curvilinear dorsal longitudinal incision along the trapezium-metacarpal joint (►Fig. 1). Once the subcutaneous tissue was dissected, the dorsal branch of the sensitive radial nerve and the deep branch of the radial artery were identified and protected. Subsequently, the trapezium-metacarpal joint was identified, the capsule was opened, and the trapezium was released. (►Fig. 2)

A second incision was made on the radial dorsal side of the hand, at the base of the second metacarpal, and the site was prepared for insertion of bone anchors (2.0 mm threaded wires) (►Fig. 3).

We used the radioscopy device to confirm the location and insertion of the first bone anchor, located at the transition between the base and the diaphysis of the second metacarpal (►Figs. 4 and 5) and with Ethibond (Ethicon, Inc., Somerville, NJ, USA) 2-0 suture threads.

The second anchor was inserted one centimeter distal to the first anchor. The stability and final positioning of the anchors were tested using the radioscopy device.

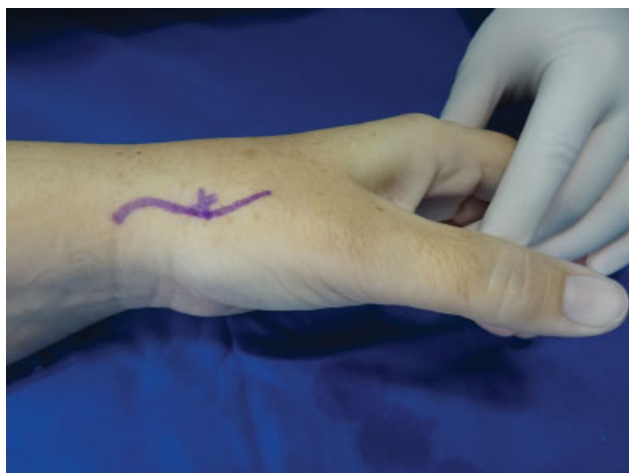

Fig. 1 Marking of the access route; The trapezium-metacarpal joint is located at the center (x).

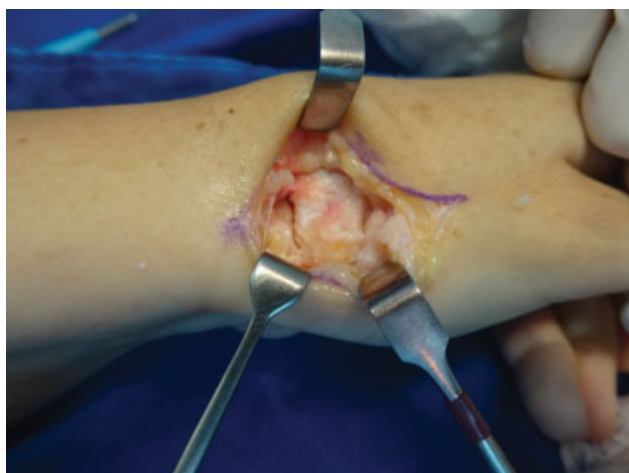

Fig. 2 Identification of the trapezium, trapezium-metacarpal joint (*), and scaphoid-trapezium (arrow).

Two parallel perforations with one centimeter between them were then made at the base of the first metacarpal. The Ethibond wire (Ethicon, Inc., Somerville, NJ, USA) of the

most distal anchor was passed from the second metacarpal to the first metacarpal via the distal orifice and returned through the proximal orifice so that a suture knot with appropriate tension could be created using the first anchor wire (►Fig. 6), with the suture knot being placed between the first and second metacarpals. In the initial cases, the suture knot was anchored on the lateral side of the first metacarpal. Thus, the suture was made without removing the trapezium (previously released), so that the height of the first metacarpal remained equal to that of the second metacarpal. The tension of this knot was enough to keep the first metacarpal anchored in the second knot because the trapezium was still in position. Subsequently, the trapezium was excised, and an image intensifier was used to determine whether the space between the scaphoid and the first metacarpal was maintained (►Fig. 7).

Appropriate tensioning of the suture maintains the first metacarpal in the anatomical position to the second metacarpal, which was confirmed in postoperative radiographs by the principle of suspensionplasty (►Fig. 8). This principle, as well as the technique described above, are represented in ►Fig. 9.

After suture by planes and dressing were provided, the limb was immobilized using a long-arm splint that included the thumb. One week postoperatively, the mobilization was removed, and the patient was referred to hand therapy. The guidance proceeded with early active mobilization with care.

Criteria for Evaluation of Results

- Pain evaluation using the visual analog pain scale.
- Evaluation of the degree of joint movement of the thumb: goniometric measure of abduction.
- Level of opposition according to the Kapandji method, which numerically evaluates the opposition of the thumb. The worst result is type 1 (in the proximal phalanx of the index), and the best result is type 9 (in the head of the fifth metacarpal).
- Palmar grip strength, calculated by the mean of three measurements, using the Jamar dynamometer (JLW Instruments, Chicago, IL, USA).

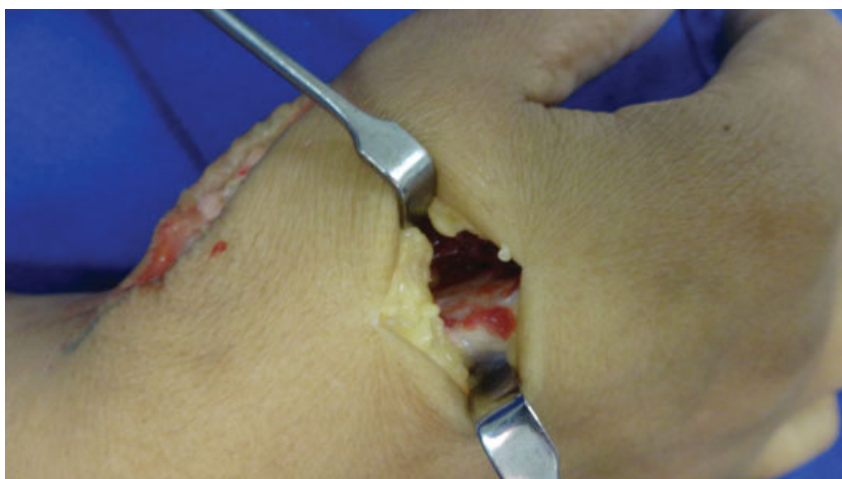

Fig. 3 Access and exposure of the base of the second metacarpal.

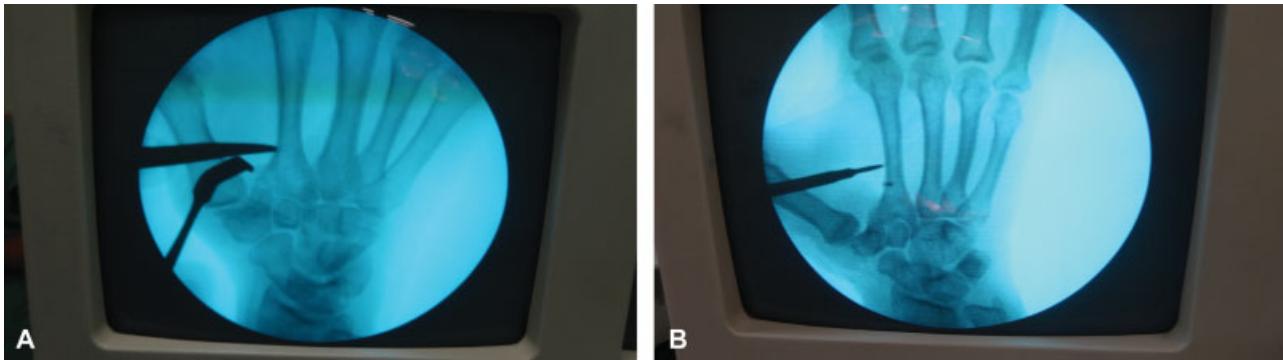


Fig. 4 View of the insertion site of the first anchor. B insertion site of the second anchor.

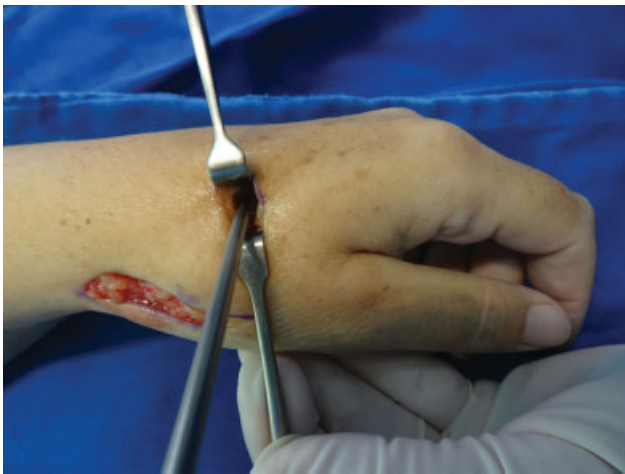

Fig. 5 Insertion of the bone anchor.

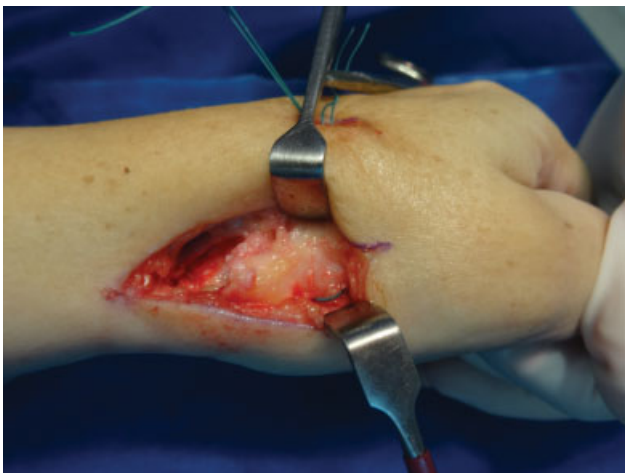


Fig. 6 View of the passage of the wire through the first metacarpal through two holes.

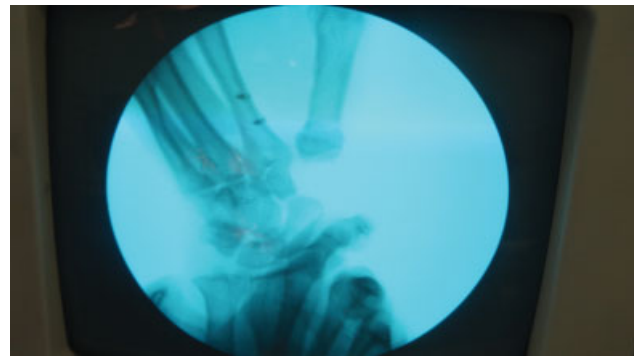


Fig. 7 Control image after trapezium removal.

- Radiological parameters to measure the remaining space after trapezium removal: measured in millimeters in the oblique view, considering the distance between the scaphoid at its point of greatest distal projection and the base of the first metacarpal at its point of greatest proximal projection, which is at the level of the joint with the trapezium bone.

- Functional results of the affected upper limb using the Quick DASH protocol, applied in the initial and final evaluation, with score 0 representing absence of functional disability and score 100 representing complete disability.
- Lateral pinch strength: The pinch performed between the thumb pulp and the radial side of the index finger was measured in kg/strength using a Pinch Gauge (North Coast Medical, Morgan Hill, USA).
- Subjective evaluation of the return to daily living activities (DLAs), to practical life activities (PLAs), and to work activities (WAs).

Statistics and Data Analysis

Data were collected using a standardized form and were filled in a Microsoft Excel 2010 (Microsoft Corporation, Redmond, WA, USA) spreadsheet.

A significance level of 0.05 (5%) was used in the present study.

We chose to use the Mann-Whitney test (non-parametric). This test is used to compare pairs of variables when the samples are independent, and the dataset has a small sample (less than 30 patients). The Wilcoxon test was also used to compare the operated side with the non-operated side postoperatively. We used the Kruskal-Wallis test to compare the activities and time of return.

Results

The mean ± standard deviation (SD) follow-up time was 21.50 ± 5.02 months.

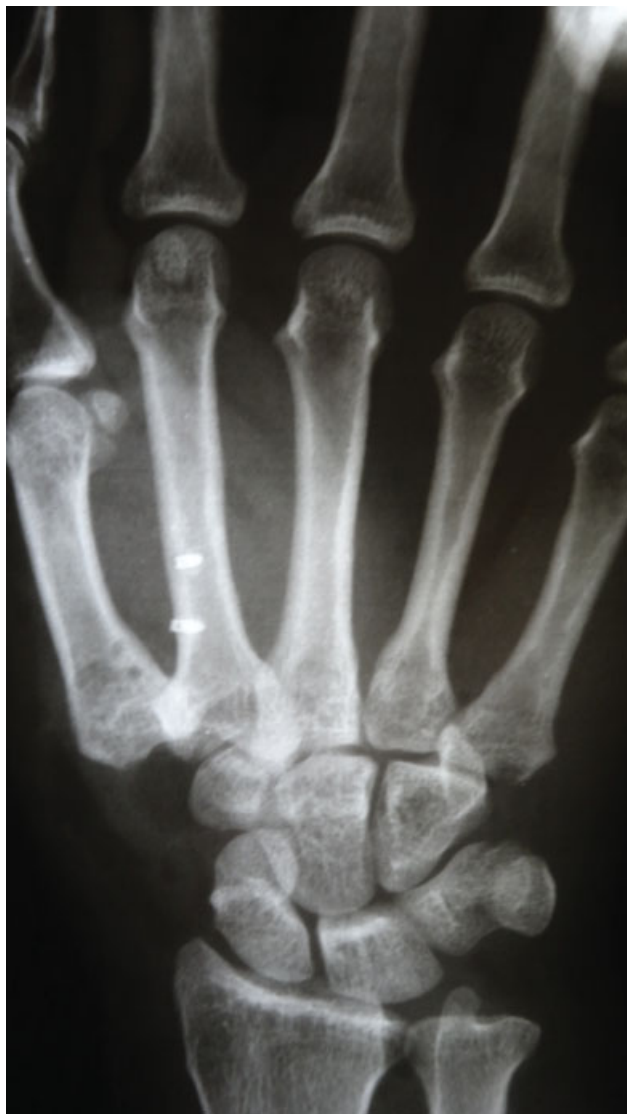

Fig. 8 Postoperative control showing the maintenance of the first metacarpal height.

Three of the 12 patients underwent bilateral operations.

The mean score of the patients using the visual analog pain scale was 1.6 points (0 to 10) postoperatively, while it was 7.3 in the preoperative period (►Table 2).

The mean degree of joint movement of the abduction of the thumb was 61.67° (40–85°) in the postoperative period and 59.73° (20–90°) in the preoperative period (►Table 3).

The mean level of thumb opposition in patients was type 7 in the preoperative period, and 7.87 in the postoperative period (►Table 3).

The final mean palmar grip strength was 21.85 kg postoperatively and 21.43 kg preoperatively (►Fig. 10) (►Table 3).

Concerning the scaphoid-first metacarpal height (EFMH) radiographic parameter, the results show a mean of 5.27 mm. Compared with the initial mean of 10.40 mm, it has a proximal migration of ~50% (►Table 3). Concerning function measurement (Quick DASH), the initial mean of 63.3 dropped to 21.6 postoperatively, evidencing functional improvement (►Table 4).

The final pinch strength on the lateral side was 4.7 kg and 6.1 kg on the contralateral side. The mean return to DLAs was 20.7 days, 24.7 days to the PLAs, and 101.3 days to the WAs. There was no significant difference between the time of return found for these three parameters and the different levels of professional activity (►Table 5). There was no correlation between the level of professional activity and the incidence of the disease (►Table 6).

Three patients (20%) had complications in an initial stage, reporting discomfort caused by the anchor knot. The anchor was removed 6 months postoperatively without impairing their activities. One patient (6.7%) had recurrent subluxation and hyperextension of the metacarpophalangeal joint and preferred to not undergo another operation, and 1 patient had a superficial infection of the surgical site, which was treated with oral antibiotics for 1 week. None of the patients experienced joint stiffness.

Discussion

Several techniques are described in the literature for the surgical treatment of rhizarthrosis. Among them are arthroplasty,^{17,18} arthrodesis,¹⁹ trapeziectomy with tendon interposition and ligament reconstruction³ or hematoma distraction,¹⁵ silicone implants, and suspensionplasty. Each of these techniques has advantages and disadvantages, but most have satisfactory final results.

Suspensionplasty with the use of TightRope (Arthrex, Inc., Naples, FL, USA) emerged as an alternative to Kirschner wires, and is used to maintain the scaphoid-first metacarpal height and thumb stability, thus enabling early mobility compared with the other cited techniques.²⁰ However, it requires a high-cost material with little availability. In this study, following the principle of suspensionplasty, bone anchors and Ethibond sutures were used as substitutes, which made the procedure more cost-effective, easily accessible, and feasible for most treatment centers.

Some complications from the use of the TightRope (Arthrex, Inc. Naples, FL, USA) technique are mentioned in the literature, such as metacarpal fracture and discomfort from surgical materials.²⁰ In our study, no case of discomfort with the anchors was observed. The discomfort that three patients experienced in response to the anchor node in the early stage of the present study was solved subsequently by changing the final position of the node to the space between the first and second metacarpal (►Fig. 8).

Yao et al¹⁶ demonstrated that both the Kirschner wire and the TightRope (Arthrex, Inc. Naples, FL, USA) have similar resistances to prevent the collapse of the trapezoidal space.

Gray et al¹⁵ assessed the isolated trapeziectomy technique and observed a reduction in the scaphoid-first metacarpal height from 10 mm to 2 mm after 88 months of follow-up in asymptomatic patients, which corresponds to a decrease of 77%. Sandvall et al,²¹ in turn, observed a 49% decrease in height in the group with ligament reconstruction and tendon interposition, and a 50% decrease in cases of hematoma distraction arthroplasty. In these cases, it is necessary to

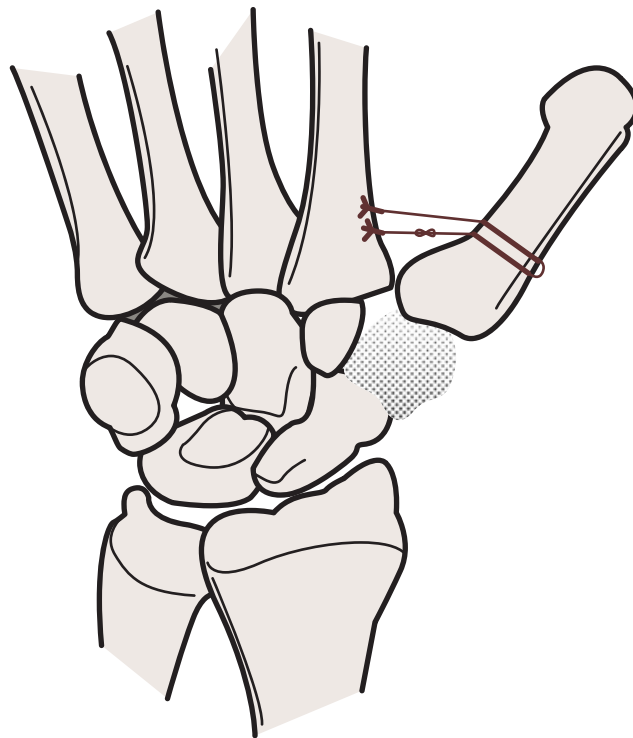


Fig. 9 Illustration of the suspensionplasty technique with non-absorbable suture and anchors.

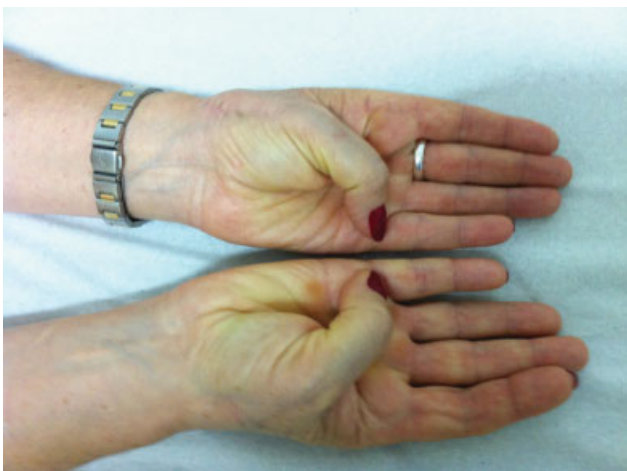


Fig. 10 Satisfactory results after 12 months; Right side incision (above) with good appearance and good functional result compared with the left side

maintain Kirschner wires (for 4 to 6 weeks). Garcia-Elias et al²² had a 27% (12–36%) trapezoidal space height decrease in addition to complications resulting from the use of Kirschner wires, and Wysocki²³ had a 24% proximal migration with the use of an interference screw.

Authors using techniques that consider the suspensionplasty principle reported a trapezoidal space decrease of 33¹⁶ and 25%.¹¹ In our study, we had a mean proximal migration of the first metacarpal of ~ 50% compared with the preoperative measurement, but there was no correlation with loss of function.

Table 2 Pre and postoperative pain assessment

Moment		Average	p-value
Pain	Preoperative	7.3	0.001*
	Postoperative	1.6	

* statistically significant data.

Table 3 Pre and postoperative measurements of the level of opposition, abduction, palmar grip, and scaphoid-first metacarpal height

Moment		Average	p-value
Opponency	Preoperative	7.00	0.046*
	Postoperative	7.87	
Radial abduction	Preoperative	59.73	0.230
	Postoperative	61.67	
Palmar prehension	Preoperative	21.43	0.834
	Postoperative	21.85	
First metacarpal height	Preoperative	10.40	0.001*
	Postoperative	5.27	

* statistically significant data.

Table 4 Comparison of pre and postoperative pain and function

Moment		Average	p-value
Quick DASH	Preoperative	63.3	0.001*
	Postoperative	21.6	

Abbreviation: DASH, disabilities of the arm, shoulder and hand.

* statistically significant data.

Table 5 Association between professional activities and return to daily living, practice, and labor activities

Professional activities		Average	p-value
Return to daily living	Light	15.5	0.633
	Moderate	19.4	
	Heavy	24.0	
Return to practice	Light	45.0	0.253
	Moderate	19.4	
	Heavy	24.0	
Return to labor activities	Light	105.0	0.111
	Moderate	57.5	
	Heavy	165.0	

Table 6 Professional activity versus incidence

Professional activity	n	%	p-value
Light	2	13.3%	0.046
Moderate	7	46.7%	Ref.
Heavy	6	40.0%	0.713

Divergent results are found in the literature regarding the evaluation parameters. Gangopadhyay et al¹³ observed an increase from 3.6 kg to 4.1 kg in the final evaluation of the lateral pinch after the isolated trapeziectomy was performed, and an increase in palmar grip strength from 14 kg to 20 kg, with 78% of the patients showing reduced pain. An increase from 19 kg to 23 kg in the postoperative palmar grip strength was observed as a result of the hematoma distraction technique,¹⁵ while the lateral pinch force remained unchanged. Eighty percent of the patients had complete pain relief. The level of opposition of the 22 patients was 20, but dropped to 9 in the postoperative period, when the Kapandji scale was used. Kochevar et al¹¹ observed an increase in pinch strength from 3.4 kg to 3.8 kg postoperatively and an increase in palmar grip strength from 13 kg to 14.8 kg after arthroplasty using the long abductor of the thumb. Sandvall et al²¹ compared the techniques of ligament reconstruction with tendon interposition and hematoma distraction and found, respectively, postoperative palmar grip strengths of 22.1 kg and 29.3 kg, and pinch strengths of 6.3 kg and 6.9 kg. Thirty-five percent of the patients were asymptomatic in the final evaluation.

Wysocki et al²³ performed suspensionplasty with an interference screw and observed an abduction of $56^\circ \pm 8^\circ$ on the operated side, and of $55^\circ \pm 8^\circ$ on the contralateral side, without statistical significance. The mean postoperative DASH was 15, and the visual pain scale was 1.1. Only the lateral pinches showed a significant difference compared with the contralateral limb.

Suspensionplasty using TightRope¹⁷ (Arthrex, Inc., Naples, FL, USA) had a mean Quick DASH of 10 ± 9 , lateral pinch strength of $86 \pm 39\%$ of the contralateral, and palmar

grip of $89 \pm 17\%$ of the contralateral. Yao et al²⁴ showed that favorable outcomes (improvement in range of motion and pain relief) remain over time by including a 5-year follow-up.

A study conducted in 2011¹² comparing isolated trapeziectomy and trapeziectomy with ligament reconstruction and tendon interposition showed that there was no significant difference in the forces of forceps and palmar grip, postoperative events, pain, and DASH between the two techniques.

In this study, the authors observed that suspensionplasty with anchors and Ethibond 2-0 wires was as effective as suspensionplasty using the Tightrope (Arthrex, Inc., Naples, FL, USA) device, but with reduced cost, wider accessibility, and minimal complications. The patients subjected to this technique had improved pain, level of opposition, abduction, and palmar grip strength. Moreover, they showed good results of function of the upper limb, regardless of the type of activity, whether moderate or heavy.

The low number of patients included in the sample was a limitation of the present study. However, results are encouraging and in line with several other case reports using different techniques for the treatment of rhizarthrosis, especially those using the Tightrope (Arthrex, Inc., Naples, FL, USA) system. The main advantage of the technique is that it allows a rapid return to daily living and work activities, thus reducing costs.

The favorable results suggest that the technique is efficient for the treatment of patients with rhizarthrosis who have a surgical indication. It could act as a substitute for the Tightrope (Arthrex, Inc., Naples, FL, USA) device, or even as the standard surgical treatment for rhizarthrosis.

Conclusions

The use of trapeziectomy and suspensionplasty using a fixation system with anchors and a non-absorbable suture results in significant improvement in pain, opposition, and function of the affected upper limb. Therefore, it is an efficient technique for the surgical treatment of rhizarthrosis.

It also allows for a rapid return to daily living activities with a low risk of complications.

Conflicts of Interest and Source of Funding

The authors report no conflicts of interest and no source of funding.

References

- Sodha S, Ring D, Zurakowski D, Jupiter JB. Prevalence of osteoarthritis of the trapeziometacarpal joint. *J Bone Joint Surg Am* 2005;87(12):2614-2618
- Berger AJ, Meals RA. Management of osteoarthritis of the thumb joints. *J Hand Surg Am* 2015;40(04):843-850
- Yao J, Park MJ. Early treatment of degenerative arthritis of the thumb carpometacarpal joint. *Hand Clin* 2008;24(03):251-261, v-vi
- Parker WL, Linscheid RL, Amadio PC. Long-term outcomes of first metacarpal extension osteotomy in the treatment of carpal-metacarpal osteoarthritis. *J Hand Surg Am* 2008;33(10):1737-1743

- 5 Vermeulen GM, Slijper H, Feitz R, Hovius SE, Moojen TM, Selles RW. Surgical management of primary thumb carpometacarpal osteoarthritis: a systematic review. *J Hand Surg Am* 2011;36(01):157–169
- 6 Gervis WH. Excision of the trapezium for osteoarthritis of the trapezio-metacarpal joint. *J Bone Joint Surg Br* 1949;31B(04):537–539, illust
- 7 Alberts KA, Engkvist O. Arthrodesis of the first carpometacarpal joint. 33 cases of arthrosis. *Acta Orthop Scand* 1989;60(03):258–260
- 8 Matullo KS, Ilyas A, Thoder JJ. CMC Arthroplasty of the Thumb: A Review. *Hand* 2007;2:232–239
- 9 Martin-Ferrero M. Ten-year long-term results of total joint arthroplasties with ARPE® implant in the treatment of trapezio-metacarpal osteoarthritis. *J Hand Surg Eur Vol* 2014;39(08):826–832
- 10 Vinycomb T, Crock J. Trapeziectomy with ligament reconstruction and tendon interposition: a minimum 10-year follow-up. *Hand Surg* 2013;18(03):365–368
- 11 Kochevar AJ, Adham CN, Adham MN, Angel MF, Walkinshaw MD. Thumb basal joint arthroplasty using abductor pollicis longus tendon: an average 5.5-year follow-up. *J Hand Surg Am* 2011;36(08):1326–1332
- 12 Li YK, White C, Ignacy TA, Thoma A. Comparison of trapeziectomy and trapeziectomy with ligament reconstruction and tendon interposition: a systematic literature review. *Plast Reconstr Surg* 2011;128(01):199–207
- 13 Gangopadhyay S, McKenna H, Burke FD, Davis TR. Five- to 18-year follow-up for treatment of trapeziometacarpal osteoarthritis: a prospective comparison of excision, tendon interposition, and ligament reconstruction and tendon interposition. *J Hand Surg Am* 2012;37(03):411–417
- 14 Yang SS, Weiland AJ. First metacarpal subsidence during pinch after ligament reconstruction and tendon interposition basal joint arthroplasty of the thumb. *J Hand Surg Am* 1998;23(05):879–883
- 15 Gray KV, Meals RA. Hematoma and distraction arthroplasty for thumb basal joint osteoarthritis: minimum 6.5-year follow-up evaluation. *J Hand Surg Am* 2007;32(01):23–29
- 16 Yao J, Zlotolow DA, Murdock R, Christian M. Suture button compared with K-wire fixation for maintenance of posttrapeziectomy space height in a cadaver model of lateral pinch. *J Hand Surg Am* 2010;35(12):2061–2065
- 17 Yao J, Song Y. Suture-button suspensionplasty for thumb carpometacarpal arthritis: a minimum 2-year follow-up. *J Hand Surg Am* 2013;38(06):1161–1165
- 18 Krukhaug Y, Lie SA, Havelin LI, Furnes O, Hove LM, Hallan G. The results of 479 thumb carpometacarpal joint replacements reported in the Norwegian Arthroplasty Register. *J Hand Surg Eur Vol* 2014;39(08):819–825
- 19 Vermeulen GM, Brink SM, Slijper H, et al. Trapeziometacarpal arthrodesis or trapeziectomy with ligament reconstruction in primary trapeziometacarpal osteoarthritis: a randomized controlled trial. *J Bone Joint Surg Am* 2014;96(09):726–733
- 20 Parry JA, Kakar S. Dual mini TightRope suspensionplasty for thumb basilar joint arthritis: a case series. *J Hand Surg Am* 2015;40(02):297–302
- 21 Sandvall BK, Cameron TE, Netscher DT, Epstein MJ, Staines KG, Petersen NJ. Basal joint osteoarthritis of the thumb: ligament reconstruction and tendon interposition versus hematoma distraction arthroplasty. *J Hand Surg Am* 2010;35(12):1968–1975
- 22 Garcia-Elias M, Tandiyo-Delgado FA. Modified technique for basilar thumb osteoarthritis. *J Hand Surg Am* 2014;39(02):362–367
- 23 Wysocki RW, Cohen MS, Shott S, Fernandez JJ. Thumb carpometacarpal suspension arthroplasty using interference screw fixation: surgical technique and clinical results. *J Hand Surg Am* 2010;35(06):913–920
- 24 Yao J, Cheah AE. Mean 5-Year Follow-up for Suture Button Suspensionplasty in the Treatment of Thumb Carpometacarpal Joint Osteoarthritis. *J Hand Surg Am* 2017;42(07):569.e1–569.e11