

Postoperative Management of Cleft Lip and Palate Surgery

Ullas Raghavan, MS (ENT), FRCS (ED & GLAS), FRCS (ORL-HNS)¹

Vishwas Vijayadev, MBBS, MS (ENT), DOHNS (ENG), ACU FELLOW (FPS), MIMSA²

Dipesh Rao, MBBS, BDS, MDS, FELLOW (CLPS), FELLOW AOCMF, FIBCSOMS³

Gautham Ullas, MBBS, BmedSci, MRCS (ENT)⁴

¹ENT, Doncaster Royal Infirmary, Doncaster, United Kingdom

²ENT HNS, RajaRajeswari Medical College and Hospital, Bangalore, Karnataka, India

³Department of Plastic and Maxillofacial Surgery, The Royal Children's Hospital, Melbourne, Victoria, Australia

⁴Department of Otorhinolaryngology, North Cumbria University Hospitals NHS Trust, Whitehaven, Cumbria, United Kingdom

Address for correspondence Vishwas Vijayadev, MBBS, MS (ENT), DOHNS (ENG), ACU FELLOW (FPS), MIMSA, Associate Professor, Department of ENT HNS, RajaRajeswari Medical College and Hospital, No.202, Kambipura, Mysore Road, Bangalore 560074, Karnataka, India (e-mail: dr.vishwaskv@gmail.com).

Facial Plast Surg 2018;34:605–611.

Abstract

Cleft lip and palatal clefts are one of the most common birth defects with a global incidence of 1 in 700 live births. The majority of these orofacial clefts are nonsyndromic. However, a general screening for syndromes and other organ anomalies should always be performed as their association with orofacial clefts cannot be overlooked. With the recent progress in the knowledge of cleft repair, the procedures to correct cleft lip and palate though complex, have been simplified to allow improvisation in outcome and to achieve even better finesse of surgical result. The procedural complications and the pursuit of having near perfect esthetics and functionality, make this deformity a recipient of multiple procedures. This ensures that the patient is under the care of the treating surgeon for long term and allows the surgeon to follow-up on the result, not only to provide care but also to intercept any deviation in the desired outcome. Postoperative care of cleft lip and palate surgery is largely underdiscussed and a set of fixed guidelines will help the treating surgeon to provide the most comprehensive care to the cleft patients. The authors review the practices followed at their hospitals—a high volume cleft and craniofacial care center, a tertiary care multispeciality teaching hospital, and a community teaching and training hospital. The commonly followed practices with suitable evidence in postoperative care of these patients are enlisted here.

Keywords

- ▶ cleft lip
- ▶ cleft palate
- ▶ postoperative care
- ▶ outcome
- ▶ guidelines

Cleft care and child development are synergistic entities and a cleft surgeon should possess intimate knowledge of the care of the pediatric population and the subtle signs and symptoms which may hitherto go unnoticed. Postoperative care for the cleft patient could be understood well, by detailing the types of procedures performed on them. The average cleft lip and palate patient with the cleft alveolus has three primary procedures scheduled for the correction of the cleft deformity:

1. Cheiloplasty.
2. Palatoplasty (–Figs. 1 and 2).

3. Alveolar bone grafting.

The secondary procedures that may be added on as additional requirement to improve function and cosmesis are as follows:

1. Lip revision to correct an outcome that is not completely satisfactory.
2. Velopharyngeal dysfunction correction → Secondary palatoplasty.
3. Orthognathic surgery for maxillary hypoplasia.

Issue Theme Postoperative Care in Facial Plastic Surgery; Guest Editor: Alwyn D'Souza, MBBS, FRCS Eng, FRCS (ORL-HNS), PGCertMedEd, EBFPRS

Copyright © 2018 by Thieme Medical Publishers, Inc., 333 Seventh Avenue, New York, NY 10001, USA. Tel: +1(212) 584-4662.

DOI <https://doi.org/10.1055/s-0038-1676381>. ISSN 0736-6825.

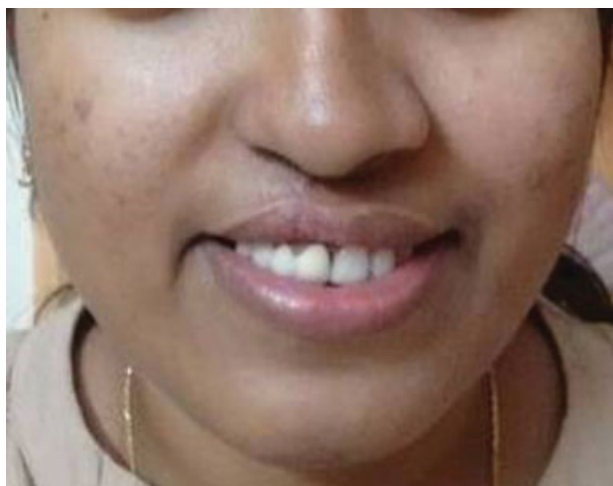

Fig. 1 A 20-year long-term follow-up of operated unilateral cleft lip.

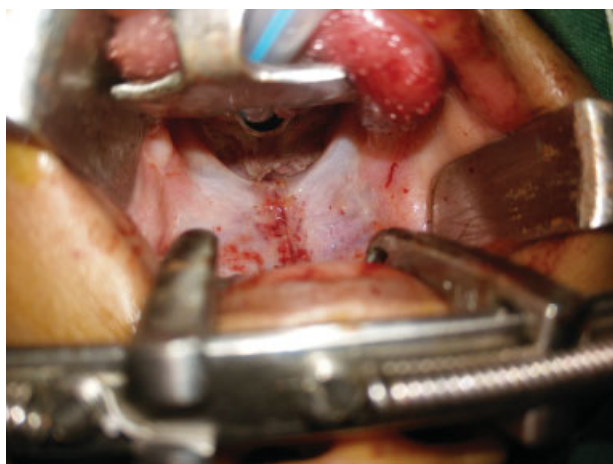


Fig. 2 Intraoperative photograph showing operated soft palate cleft with intervelar veloplasty.

4. Rhinoplasty for secondary cleft nose.
5. Velopharyngeal incompetence surgery.

Timing

There has been an evolving consensus on the age suitability of the tissues to undergo a change in shape, form, and function. The timing of the surgery has been a topic of debate ever since the protocols for cleft repair were laid down.¹ The proposal of doing the surgery early was disregarded purely from the anesthetic point of view and also most surgeons felt the paucity of tissue for a good repair made achieving a good outcome difficult. However, an important often neglected aspect in cleft lip and palate repair is the timing and protocol of the postoperative care. It has generally been regarded as within 3 months for a cleft lip repair and the period between 6 and 12 months for a cleft palate repair to give most desirable results. Factors such as medical condition of the infant, hematological parameters, and growth disturbances may minimally alter the surgical schedule.

General Postoperative Care in Cleft Lip and Palate Patients

The systemic need of the patient is the provisional nutritional imbalance that might be preexisting in the patient undergoing the surgery and the immediate requirement postoperatively. The surgical insult and the requirement of good healing make correction of the macro- or micronutrient imbalance prudent.

Types of Systemic Problems that Might Affect Cleft Lip and Palate Outcome

- **Macronutrient deficiency**
 - Malnutrition.
 - Protein deficiency.
- **Micronutrient**
 - Iron deficiency.
 - Vitamin deficiency (most importantly vitamin C).

Malnutrition

Most children having cleft lip or palate suffer from some form of malnutrition which may go unnoticed. Feeding has been one of the most primary concerns in managing a cleft lip and palate patients.^{2,3} The nature of the defect and the psychological trauma of having a cleft patient in the family, provides for an undernourished infant. The poor weight gain coupled with lower length/height percentile of the growing infant is a clear indicator of gross nutritional deficiency of the patient.⁴ This if not corrected before surgery should always be corrected after the surgery.⁵ The psychological burden of the cleft is immediately crossed once the surgery is complete and the motivated parents⁶ and family members do provide for rapid nutritional correction. The functional change of a repaired lip and palate also improve feeding by reducing nasal regurgitation.

Contrary to the earlier beliefs of not bottle feeding or breastfeeding the child after lip surgery (in cases of isolated cleft lip), the consensus in our set up is to start breast/bottle feeding immediately after the mandatory anesthetic fasting hours have passed. If the child is comfortable, there will be no untoward effect on the suture line as crying adds more tension on the closure line than suckling⁷ and a child that is used to a particular form of feeding generally appreciated going back to the same feeding pattern and is more comfortable.

The palate surgery patients, however, receive feeds through a spoon, pallada/paladai, or dropper as the conventional long nipple bottles used by cleft patients preoperatively can hurt the palate. However, conventional breastfeeding can be resumed after 4 hours of surgery for younger infants as the predominant nutritional source. The average age of the palate patient is also generally older thus making spoon feeds for soft diet an easier option (→ Fig. 3).

Malnutrition should be closely monitored and adequate calorie correction should be provided for an overall growth of the child and for a good wound healing. The role of a trained

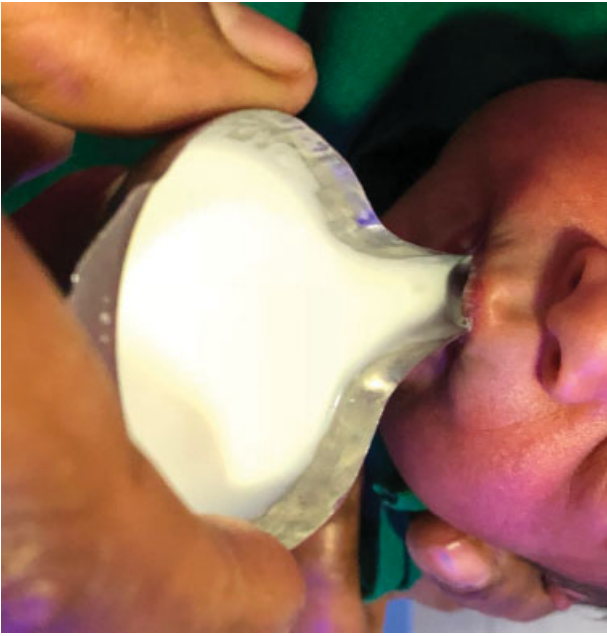

Fig. 3 Pallada feeding.

dietician or a pediatrician in provisioning of appropriate form, quality, and quantity of intake for the infant is crucial.

Protein Deficiency

A more specific type of malnutrition is protein deficiency. Characterized by change in skin or hair, color, and texture, stunted growth, lack of muscle mass, and edema, these patients require postoperative antibiotic cover as they are more prone to infections. The muscle bulk during cleft lip repair might generally be inadequate and this might lead to a compromised outcome attributed to tension on the closure line. The postoperative care should include meticulous surgical site management to ensure satisfactory wound healing. In infants with low protein levels, a high protein-based dietary charting is essential. However, in patients with protein energy malnutrition, serum albumin-based calculations for replenishment have been followed in the pediatric intensive care unit.

Iron Deficiency Anemia

Many centers have documented a strong association of anemia with cleft patients. Almost one-third of the cleft lip and palate patients will present with hemoglobin less than or equal to 10 g/dL. This has challenged many centers to lower the minimum required hemoglobin level to less than 8 g/dL and also simultaneously minimize the blood loss during the procedure.

The fact that children with cleft are rarely on breast milk make them more susceptible to iron deficiency. Hence, it would be necessary to add supplementation to all infants undergoing cleft lip and palate surgery with hemoglobin less than 12 g/dL. The ideal dosing for children between 6 and 12 months would be to prescribe hematinic syrup or drop formulations at the simple rate of 5 to 7 mg/kg body weight

on a 10-day course without causing much gastric discomfort. In older children, the requirement could be enhanced to 7 to 10 mg/kg body weight in oral iron supplements.

Vitamin C Deficiency

Breast milk is generally a low source of ascorbic acid, calciferols, and tocopherols for the growing infant. Vitamin C and other micronutrients play a very important role in wound healing and also determine the quality of the skin. If identified preoperatively, supplements should be initiated immediately and should continue in the postoperative period at least till the healing is complete.⁸

Ideally, a dosage range of between 100 and 300 mg of vitamin C supplements given for 30 days should be adequate in an infant aged between 6 and 12 months.

General Care

Infants not on breast milk and on breast milk substitutes require calcium and iron supplements for their normal growth and development. These should continue even after cleft repair till adequate oral intake with recommended daily allowance is established.

An institutional audit done 7 years back to review the postoperative healing helped us change from earlier practiced arm restraints to no restraints. This has significantly avoided patient discomfort and expenditure without altering the postoperative healing in all our patients. This has largely been the practice across many centers in the world.

A postoperative care nurse is assigned to each child until discharge following which a counseling session is held for the mother and the immediate caregiver on the art and science of feeding. Surprisingly, the onus of weight gain and growth spurt is entirely attributed to the preceding cleft surgery, and hence adequate follow-up sessions on feeding and catch-up growth would be helpful if practiced universally at all centers.

Handling Instructions

The role of personal hygiene is often missed in postoperative care. Every parent handling the child with cleft should be made to understand the basics of maintaining good hygiene. Instructions may need to be provided for even simple routines which could vary from washroom sanitation to utilizing clean utensils and garments for the child. A child is more susceptible to infections after surgery⁹ and the site of repair could also get infected if hygiene of the handler is neglected.

Hygiene Instructions

1. Hands washed thoroughly before feeding and touching the child.
2. Utensils washed before every use.
3. Cloth/garment to wipe the surgical site to be avoided.
4. Clean clothing ensured postoperatively, and blood soaked clothing from the surgical site replaced immediately.
5. Tissue wipes on wounds avoided.
6. Good breastfeeding hygiene.

Surgery-Related Postoperative Care in Cleft Lip and Palate Patients

1. Cleft lip repair (cheiloplasty):

a. Immediate care:

- i. Lip dressings: The lip should be gently cleaned with a wet Q tip bud/cotton pellet in the direction parallel to the scar to avoid serosanguineous crusting. A drop of clean water over an antibiotic soap can be used to clean the suture line by the caregiver at home. An antibiotic ointment should then be applied thrice daily over the sutured site for 2 weeks. The suture removal or trimming is done on the 6th to 7th postoperative day and mild sedation may be required for infants. Care should be taken to keep the sutured site moist at all times with the antibiotic ointment (–Fig. 4).
- ii. Avoidance of direct sun exposure: To ensure good wound healing and minimize scarring, the patient is advised to avoid exposure to harsh sunlight and dust.
- iii. Avoid direct trauma: The repaired lip is still vulnerable. Though the practice of restraints has been described in the past, the need for it does not seem to be completely prudent. Infants who have the tendency to scratch should be made to wear mittens.

However, especially in the hospital setting, care should be taken to check if the baby is secure on the bed at all times. The railings of the patient bed should be up and well cushioned. If a crib is available, all infants should be placed in them with adequate crib lining to avoid any injuries.

b. Delayed care:

- i. Scar management^{10,11}: The cutaneous scar of a cleft lip can never be completely eliminated. Based on the technique of repair, a characteristic scar always remains. The two most popular techniques in the world are Tennison–Randall and Millard's technique. The Tennison–Randall technique provides for an adequate length of the lip postsurgery; however, it creates horizontal scars on the cutaneous lip. On

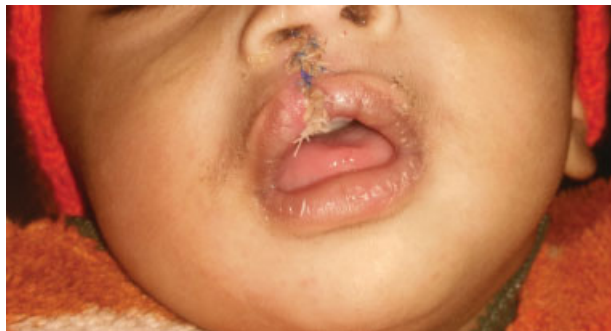

Fig. 4 Serosanguineous crusting on cleft lip suture site.

the other hand, the Millard's technique creates a simple uninterrupted vertical scar along the philtral column which contracts due to the lack of a break point in the scar. Both these scars need meticulous care¹² in the postoperative period.

Massaging the fresh scar is a practice that many centers advocate. Though the exact mechanism of how it helps reducing thick scarring is not known. It is believed to break the subdermal collagen fiber bonds, improve circulation, and in turn reduce the thickening of the scar.

Massaging should be initiated only after the surgical site has completely healed and all the sutures have fallen. In case of dehiscence of the wound, defer the massaging till healing is complete. The strokes for massage should start with gentle pressure of the thumb swiping down from the columella end of the scar to the vermilion. There should be very minimal blanching of the tissues during the initial healing period. The frequency of massage should be thrice a day for 8 to 10 minutes per session. The force of the massage can be gradually increased. A lubricating gel (vitamin E gel) or coconut oil can be used to massage the scar.¹³

- ii. Silicone gel application¹⁴: A proven adjuvant to massaging is silicone gel application. The gel could be applied immediately after completing the massage. Silicone gels act by occlusion and hydration. A thin film of silicone gel is generally adequate and care should be taken to clean the previous layer of gel before applying the next layer. The direction of gel application and massage should be unidirectional.

The benefit of a silicone gel can be seen in a scar not older than 2 years and should be applied for at least 6 months for optimal benefit.

- iii. Contracture management: Millard's repair has a higher rate of scar contracture. The modifications of the Millard's technique have eliminated the alar incision but the philtral column is where the contracture occurs and the patient generally ends up having a thick scar and short lip length with vermilion notching. Massaging the tissue ensures that the contracture is minimized and the scar is rendered more acceptable. Massaging an old scar of 6 months for a period of 6 months can surprisingly also reduce the amount of peaking related to scar contraction (–Figs. 5 and 6).
- iv. Steroid (triamcinolone injections)¹⁵: In cases of thick hypertrophic scar, a course of long-acting steroid 0.3 to 0.5 mL triamcinolone injection of 10 mg, 3 to 5 doses 6 weeks apart is recommended. The procedure of injecting steroid into the thickened scar is painful and can be managed by using surface anesthetic (EMLA – lidocaine and prilocaine topical). An insulin syringe is prepared with equal mixtures of lignocaine (2%) and bupivacaine

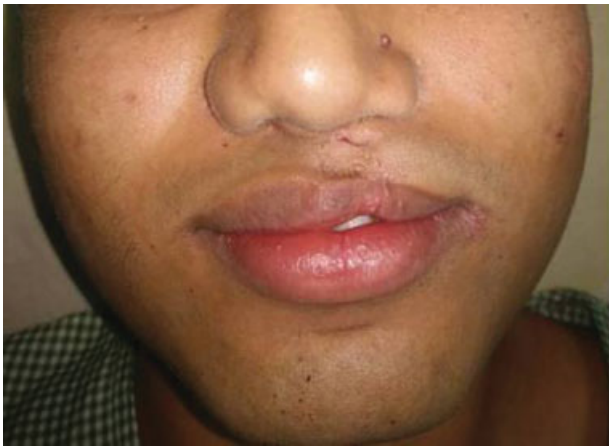

Fig. 5 Vermilion notching and contracture.

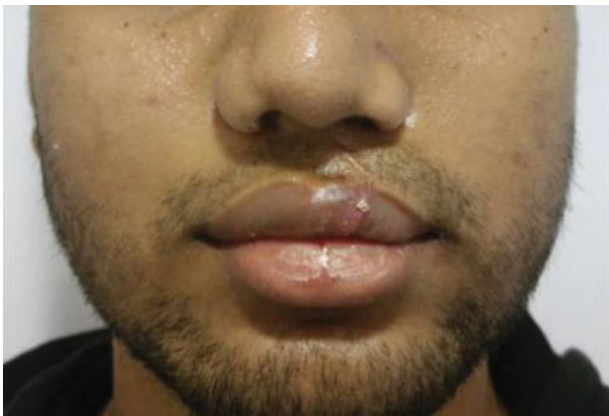

Fig. 6 Corrected scar and lip irregularity.

(0.25%). A second insulin needle is loaded with triamcinolone 10 mg preparation. Once the EMLA is applied and the surface anesthetized, the local anesthetic is injected to create a plane and also to provide analgesia. The second syringe with the steroid is now injected into the elevated scar tissue. Manipulation of the scar is avoided after the injection for 6 hours.

- v. In bilateral cleft lip surgery, the nasal airway is kept patent by introducing nasal stents for 3 days to allow the edema to settle down and avoid concentric healing at the nasal suture line.

2. Cleft palate repair (Palatoplasty):

a. Immediate care⁸:

- i. Positioning of the patient: The patient should always be nursed in a lateral or prone position after the surgery to prevent aspiration of the blood that might trickle down the lateral edges of the closed palate.
In cases of isolated cleft palate, there might already be an element of associated mandibular retrognathism and high anterior larynx. This may predispose the child to aspirate postoperatively. The relatively

narrowed airway from a newly formed soft palate and the tongue fall associated with mandibular retrognathism may warrant close observation and measures to immediately secure the airway in case of upper airway obstruction. In retrognathic patients, where the airway distress is anticipated, a tongue stitch could be placed intraoperatively to position the tongue anteriorly in the event of any respiratory distress¹⁶ until such time that the patient completely recovers from the effects of anesthesia. Alternately, a soft guedel airway may be placed to keep the airway patent without having to resort to painful restrictions of the tongue.

Another method of dealing with mandibular retrognathism and upper airway distress is the use of nasopharyngeal airway that can be secured to prevent the child from pulling it out.¹⁶ These can be removed once the child is comfortable and tolerating oral feeds well or on the next postoperative day.

- ii. Excessive salivation: The patients (parents) need be informed about excessive salivation that occurs after cleft palate surgery. The saliva tinged with blood may add to the apprehension of the patient caregiver since they would consider the entire volume to be blood. In an attempt to wipe/prevent bleeding, more damage could be done by either injuring or infecting the operated site, when using a cloth or gauze. The instruction ought to be clear that the patient or attender under no circumstances should try and manage what they might consider as bleeding. The best possible care at that point would be to keep the patient in a lateral position and ask the health care provider (doctor/nurse) to check for any bleeding.
- iii. Clear fluids and oral hygiene: The suture line tends to accumulate milk, semisolid food particles, and plaque. Encouraging the parents to give their infants large volumes of water, most importantly after any feed, would keep the suture line clean and hydrated.
Adult patients are advised to avoid rinsing or spitting vigorously for the first 24 hours, following which a mild medicated mouthwash would provide adequate oral hygiene and prevent accumulation of debris around the suture line (► Fig. 7).
- iv. Diet: The patients would generally be advised to eat a soft diet and avoid anything hard that may hurt or pierce the newly repaired cleft palate.¹⁷ The first 24 hours are crucial and special care would have to be taken to avoid intake of hot and spicy food or liquids. Foods with a sticky constituency are especially notorious for accumulating around the suture line¹⁸ and are best avoided.
- v. Avoid blowing/sneezing: Patients should be advised against blowing the nose violently for a minimum period of 1 week. Urges to sneeze or cough may be done with a fully open mouth to relieve the sudden

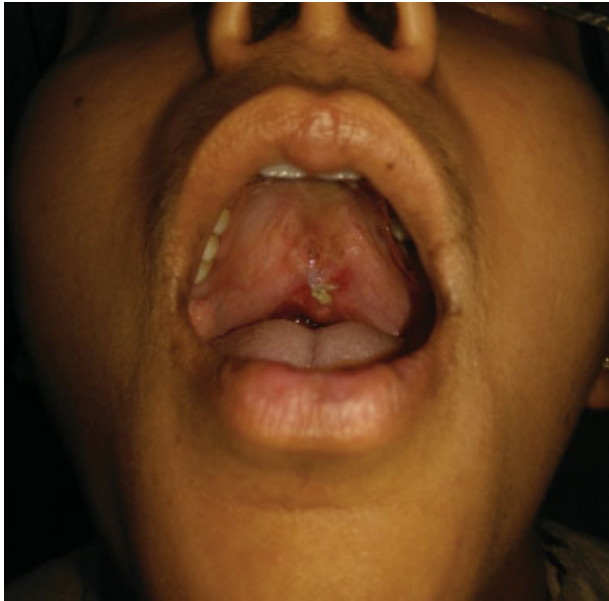

Fig. 7 Cleft palate suture line showing food debris.

rise in pressure. The chance of damage to the sutured fragile nasal layer although minimal, always exists.

3. Cleft alveolus bone grafting (secondary alveolar bone grafting):

- a. Recipient site: Care as for in cleft palate.
- b. Donor site: The most common site for bone graft harvest is the iliac crest or calvarial bone. The anterior iliac crest can provide up to 50 mL of cancellous bone and is the preferred site for harvest. If the operative techniques are carefully followed, the complications of cutaneous sensory disturbance or gait disturbance is avoided.¹⁹ Increasingly irradiated bone or bone cement is being utilized at various cleft centers to avoid donor site morbidity.

The general postoperative care for donor site would include pain management, avoidance of any direct trauma, and scar management.

- i. Pain management: Donor site pain is often the most common reason for longer hospital stay and poor ambulation of a cleft patient. Hence, pain management in the first 12 hours is crucial for improving the overall management of pain and also provides for faster recovery.

The pain management comprises of using pediatric Visual Analogue Scale (VAS) for ideal medication and dosing interval. Appropriate analgesics in the form of suppositories and transdermal patches may be preferred in children.

- Local anesthetics: The analgesia provided by long-acting local anesthetics has the major advantage of reducing pain in the first 12 hours significantly.²⁰ This has proved to reduce the overall VAS score of pain in the postoperative patients. Patients who receive long-acting local

anesthetics have faster ambulation and shorter hospital stay. A long-acting local anesthetic (1 mL/kg of 0.25% bupivacaine) would be ideal when injected into the site immediately after the surgery. A slow infusion through catheter of long-acting bupivacaine is also one of the treatment options for pain control.

Transverse abdominis plane blocks²¹ have an advantage over other methods by providing a longer pain control with the same local anesthetic bupivacaine when iliac crest cancellous bone is harvested. The drug is delivered through a 50- to 80-cm long needle and can be ultrasound-guided into the plane between the internal oblique and the transverse abdominis. It anesthetizes the peripheral nerves in the anterior abdominal wall (T6–L1). This provides for adequate pain relief and much lower VAS, thus improving ambulation and hospital stay.

- ii. Precautions to avoid direct trauma: The patients undergoing secondary bone grafting are generally in the age group of 8 to 10 years. The instructions for these children during postoperative care should be to avoid running and swimming for 4 weeks, and avoiding contact sports and cycling for 6 weeks.
- iii. Scar management: Albeit similar to lip repair, the tendency to form hypertrophic scar is higher for iliac crest harvest owing to constant friction with clothing and irritation and hence patients may be adequately consented.

4. Cleft orthognathic and distraction osteogenesis:

Unilateral or bilateral maxillary hypoplasia is a common stigma of cleft care. The correction of the skeletal discrepancy requires orthognathics or distraction. The postoperative care in these procedures is mainly to reduce the inflammation that occurs after a bony procedure²² and provide care to the recently fixed jaws. The initial care would involve ice packs, anti-inflammatory medications, soft diet, and a special care to avoid any contact sport. A course of oral antibiotics with anaerobic cover is mandatory for 7 days after the placement of a frame or distractor and is seen to drastically reduce the implant rejection rates. Routine oral hygiene may be practiced to prevent any implant infections.

In patients with distractors, care should be taken to avoid any damage to the distractor frame or using excessive activation forces that might change the bone response. A soft foam dressing may be used at night to avoid any inadvertent movements of the frame with precautions to avoid excessive night time movements with head or pillow restraints.

The distractor frame skin entry points should be coated with antibiotic ointments for a period of 2 weeks until the skin seals around the pins. Collateral injury from the frame to the patient or caregivers may be avoided by allowing soft plastic molds to cover the exposed metal ware.

5. Velopharyngeal incompetence closure:

Most patients who undergo velopharyngeal incompetence surgery are admitted to the surgical intensive care unit for the first 24 hours after surgery because of a perceived breathing difficulty on account of closure of the wide nasopharynx or for minimal chances of bleeding and aspiration.

The pharyngeal flaps can become sufficiently edematous due to the handling and hence a late intraoperative dose prior to extubation of intravenous dexamethasone may be helpful to prevent edema and breathing difficulty.

The care of these patients would be similar to the cleft palate patients along with a swallowing therapist support for 1 week to prevent nasal regurgitation from uncoordinated palatal movements.

Conclusion

The basic principles of postoperative care for patients with cleft lip and palate are although similar in many regards to other head neck procedures, but they are also unique since the procedures are performed in different age groups and for different types of tissues (soft to hard) simultaneously. A basic understanding of the procedures and the healing process helps provide timely support and care for patients undergoing cleft lip and palate procedures.

References

- Kobus K, Kobus-Zalesna K. Timing of cleft lip and palate repair. *Dev Period Med* 2014;18(01):79–83
- Clarren SK, Anderson B, Wolf LS. Feeding infants with cleft lip, cleft palate, or cleft lip and palate. *Cleft Palate J* 1987;24(03):244–249
- Kaye A, Thaete K, Snell A, Chesser C, Goldak C, Huff H. Initial nutritional assessment of infants with cleft lip and/or palate: interventions and return to birth weight. *Cleft Palate Craniofac J* 2017;54(02):127–136
- Pandya AN, Boorman JG. Failure to thrive in babies with cleft lip and palate. *Br J Plast Surg* 2001;54(06):471–475
- Gopinath VK, Muda WA. Assessment of growth and feeding practices in children with cleft lip and palate. *Southeast Asian J Trop Med Public Health* 2005;36(01):254–258
- Turner SR, Rumsey N, Sandy JR. Psychological aspects of cleft lip and palate. *Eur J Orthod* 1998;20(04):407–415
- Darzi MA, Chowdri NA, Bhat AN. Breast feeding or spoon feeding after cleft lip repair: a prospective, randomised study. *Br J Plast Surg* 1996;49(01):24–26
- Johnson HA. The immediate postoperative care of a child with cleft lip: time-proved suggestions. *Ann Plast Surg* 1979;2(05):430–433
- McHoney M, Eaton S, Pierro A. Metabolic response to surgery in infants and children. *Eur J Pediatr Surg* 2009;19(05):275–285
- O’Kane S. Wound remodelling and scarring. *J Wound Care* 2002;11(08):296–299
- Kim S, Choi TH, Liu W, Ogawa R, Suh JS, Mustoe TA. Update on scar management: guidelines for treating Asian patients. *Plast Reconstr Surg* 2013;132(06):1580–1589
- Giebler FR, Giebler EF. Creating invisible scars. *Int J Cosmet Surg Aesthetic Dermatol* 2002;4(02):107–110
- Studin JR, Inventor; SG Licensing Corp, assignee. Method and composition for the treatment of scars. United States patent: US 6337076; 2002 January 8
- Ahn ST, Monafo WW, Mustoe TA. Topical silicone gel: a new treatment for hypertrophic scars. *Surgery* 1989;106(04):781–786, discussion 786–787
- Kiil J. Keloids treated with topical injections of triamcinolone acetonide (kenalog). Immediate and long-term results. *Scand J Plast Reconstr Surg* 1977;11(02):169–172
- Evans AK, Rahbar R, Rogers GF, Mulliken JB, Volk MS. Robin sequence: a retrospective review of 115 patients. *Int J Pediatr Otorhinolaryngol* 2006;70(06):973–980
- Katzel EB, Basile P, Koltz PF, Marcus JR, Giroto JA. Current surgical practices in cleft care: cleft palate repair techniques and post-operative care. *Plast Reconstr Surg* 2009;124(03):899–906
- Duarte GA, Ramos RB, Cardoso MC. Feeding methods for children with cleft lip and/or palate: a systematic review. *Rev Bras Otorrinolaringol (Engl Ed)* 2016;82(05):602–609
- Beirne JC, Barry HJ, Brady FA, Morris VB. Donor site morbidity of the anterior iliac crest following cancellous bone harvest. *Int J Oral Maxillofac Surg* 1996;25(04):268–271
- Dashow JE, Lewis CW, Hopper RA, Gruss JS, Egbert MA. Bupivacaine administration and postoperative pain following anterior iliac crest bone graft for alveolar cleft repair. *Cleft Palate Craniofac J* 2009;46(02):173–178
- Petersen PL, Mathiesen O, Torup H, Dahl JB. The transversus abdominis plane block: a valuable option for postoperative analgesia? A topical review. *Acta Anaesthesiol Scand* 2010;54(05):529–535
- Cheung LK, Chua HD. A meta-analysis of cleft maxillary osteotomy and distraction osteogenesis. *Int J Oral Maxillofac Surg* 2006;35(01):14–24