Effect of Narcotic Analgesics on the Ultrastructure of the Eyeball (Experimental Study)

Uliana Pidvalna[1] Andriy Kost[2] Lesya Mateshuk-Vatseba[1]

[1] Department of Normal Anatomy, Danylo Halytsky Lviv National Medical University, Lviv, Lviv region, Ukraine
[2] Department of Clinical Laboratory Diagnostics, Danylo Halytsky Lviv National Medical University Lviv, Lviv region, Ukraine

Address for correspondence Uliana Pidvalna, MD, PhD, Department of Normal Anatomy, Danylo Halytsky Lviv National Medical University, Lviv, Lviv region, Ukraine 79000 (e-mail: uljaska.p@gmail.com).

J Morphol Sci 2018;35:251–254.

Abstract

Background The use of opioids among people of the young and working age has sharply increased in recent years simultaneously with the outbreak observed in the general population.

Objective To determine the trigger mechanism of the destructive effect of narcotic analgesics on the ultrastructural level of the vascular tunic of the eyeball. Methods: This experimental study was performed on 26 male rats aged 3.0 months and body weight 160–180 g with daily intramuscular injection of Nalbuphine hydrochloride during 4 weeks. The material for the study was represented by ultramicroscopic sections of the vascular tunic of the eyeball.

Results In comparison with the control group there was observed swelling of the cytoplasm and the nuclei of endotheliocytes, considerably narrowed lumens of the capillaries. Plasmolemma of endotheliocytes forms protrusions into the lumen of endotheliocytes forming microvilli. Changes of destructive nature took place in the elements of the smooth endoplasmic reticulum and mitochondrial complex. Signs that are characteristic of sclerosis were found in the surrounding connective tissue complex. In particular, lesions of endothelium and basement membrane of the elements of hemomicrocirculatory bloodstream, epithelium of the ciliary processes, cellular and non-cellular elements of the iris and the uvea proper have studied.

Conclusion The databased on the experimental model allow extrapolation the results obtained to humans. It is confirmed that the development of angiopathy is the trigger mechanism of the destructive effect of narcotic analgesics.

Keywords
- analgesics
- opioids
- capillaries
- endothelium
- animal experiment

Introduction

The number of individuals that have to use narcotic analgesics for the long periods time has been growing dynamically over the past decades.[1] This is often connected with the need to reduce the pain syndrome, especially in military surgery, oncology, traumatology, dentistry, palliative medicine.[2,3] However, this regularity is observed among the individuals of the young and working age that is not explained by the therapeutic purposes.[4,5] Opioid use in pregnancy has escalated dramatically in recent years, paralleling the epidemic observed in the general population.[6] According to various estimates from 165 to 315 million people aged 15–64 years worldwide used narcotic drugs in 2012 (UNODC 2013).[7] The importance of this issue is confirmed by the dynamic growth of the number of scientific works found in the Pubmed system. To combat the opioid epidemic, all health care providers need to take an active role.

Analysis of professional literature confirms topicality of the study of this problem by the considerable number of the

received
August 4, 2018
accepted
November 3, 2018

DOI https://doi.org/10.1055/s-0038-1676543.
ISSN 2177-0298.

Copyright © 2018 by Thieme Revinter Publicações Ltda, Rio de Janeiro, Brazil

License terms

research works dealing with the changes in the structure of organs and systems under the effect of narcotic agents.[8–11] However, the problem of morphological restructuring of the vascular tunic connected with the use of Nalbuphine hydrochloride still remains open.[10,12] The study of changes in the visual organ under the influence of the opioid during the experiment will allow extrapolating the data obtained to the humans.

As a matter of fact, electron microscopic study of the vascular tunic and its hemomicrocirculatory bloodstream components provides the possibility of identifying peculiarities of the structure regularities of qualitative-quantitative changes in the components of bloodstream and structural components of the vascular tunic of the eyeball under the effect of the opioid. The research of the vessels' structure, ultrastructure of their walls under the effect of various factors allows to study importance of the vascular factor in morphofunctional insufficiency of the internal organs.

Material and Methods

The study was performed on 16 mature white male rats aged 3.0 months and body weight 160–180 g. The experimental group consisted of 10 animals to which Nalbuphine hydrochloride (Rusanpharma LTD., India) was injected intramuscularly every day during 4 weeks (12.5 mg/kg). The control group consisted of 6 white rats to which saline solution (Indar, Kyiv, Ukraine) was injected.

The experiments were conducted in compliance with the provisions of the "Guide for the care and use of laboratory animals, 8th edition, 2011." Euthanasia was performed by way of overdosing intraperitoneal anesthesia using Thiopental sodium (Kyivmedpreparat, Kyiv, Ukraine). The research material was presented by ultrathin sections of the white rats' vascular tunic of the eyeball.

Electron microscopic study was conducted in compliance with generally adopted methods. Ultrathin sections were prepared with the aid of ultramicrotome UMTP-3 with the help of glass knives. Strips of the sections of silver or mellow lemon color were selected for the study. These sections were contrasted first in a 2% solution of uranyl acetate, and then in the solution of lead citrate. The study and photographing of the structures of the vascular tunic of the eyeball was conducted with the aid of UEMB-100 K microscope at acceleration speed 75 kV and magnification on the microscope screen × 4000–8000.

Results

Essential changes are observed in the capillaries' structure after 4 weeks of injecting the narcotic analgesic. In most of them, endotheliocytes are enlarged, with large nuclei of the changed form and a marginal location of chromatin, giant mitochondria, disorganized tissue around the capillaries.

Cytoplasm and endotheliocytes nuclei are swollen. As a consequence, the capillary lumen produces the picture of a "stellate fissure" due to the considerable narrowing of its lumen (►**Fig. 1**). Canals of Golgi's sac complex are dilated.

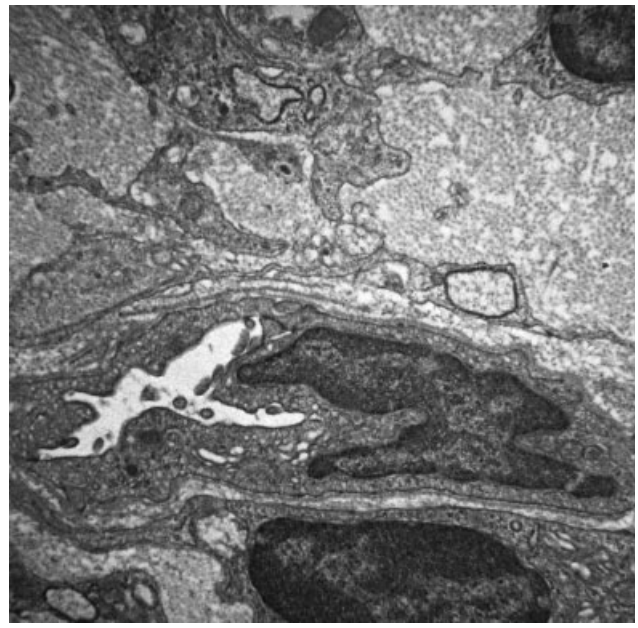

Fig. 1 Narrowing of the hemocapillary lumen of the white rat's vascular tunic of the eyeball after 4 weeks of Nalbuphine hydrochloride injections producing the picture of the "stellate fissure." Edema of the endotheliocytes nuclei and cytoplasm. Electron microphotograph (× 4000).

Electron-dense nuclei of endotheliocytes together with the surrounding cytoplasm protrude into the capillaries' lumen, acquire an excessively elongated form. For this reason anuclear areas of endotheliocytes are thinned, nucleoli are electron-dense. Basement membrane looses its distinct contour, pericytes occasionally delaminate from it. Plasmolemma forms protrusions into the capillaries' lumen.

Even more significant changes were found in the elements of the smooth endoplasmic reticulum, which is manifested by its expansion. The mitochondrial complex also reacts by way of discomplexation, fragmentation, homogenization and smoothing out of cristae, dissociation of their membranes.

The number of pinocytic vesicles of varying diameters that migrate into pericapillar surrounding connective tissue, promoting its swelling, is increased. As a consequence, the subendothelial zone is practically halved. At that the capillaries are plethoric with occasional hemorrhages observed. It is clear that lymphocytic infiltration appears in the process around the centers of hemorrhages. Basal layer is thickened, which creates a peculiar wall for the capillaries, practically burying them up in the connective tissue that is destructively changed.

Intercellular contacts between the endothelial cells are compacted, forming a picture of a peculiar "lock." Externally capillaries are closely enveloped by pericytes. In arterioles contacts between the smooth muscle and endothelial cells differ from the contact between the pericytes and endothelial cells in the capillaries. In arterioles processes of endotheliocytes are pointed toward the smooth muscle cells, as distinct from the capillaries, where the pericyte processes "strain" toward the endotheliocytes. Endothelial contacts are expanded, protrusions of endotheliocytes, edematic and fluffy basement membrane of arterioles (►**Fig. 2**).

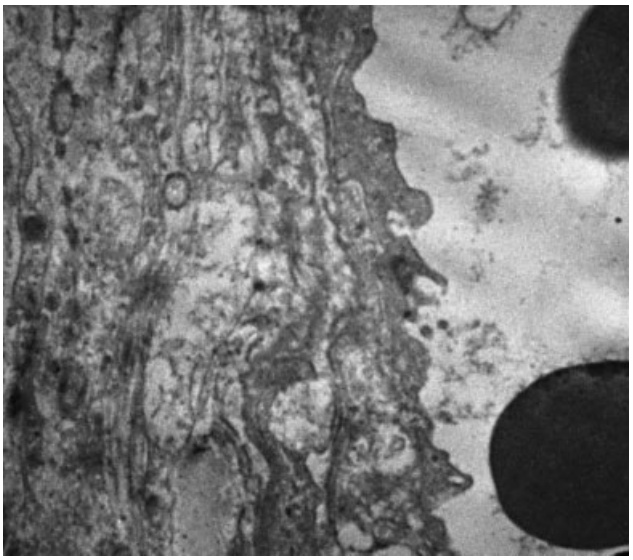

Fig. 2 Loose basement membrane and protrusion of the arteriole endotheliocyte cytoplasm of the white rat's vascular tunic of the eyeball after 4 weeks of Nalbuphine hydrochloride injections. Electron microphotograph (× 8000).

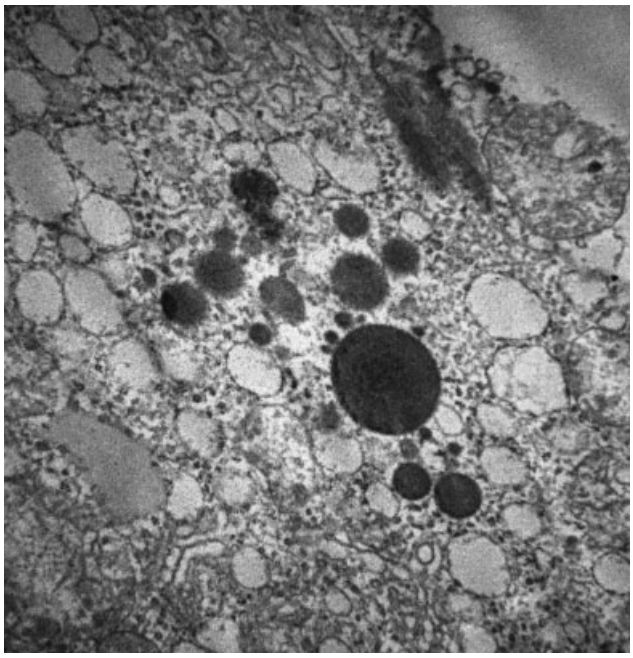

Fig. 3 Destructurized epitheliocyte of the white rat's eyeball ciliary process after 4 weeks of Nalbuphine hydrochloride injections with presence of electron-dense corpuscles and vacuoles. Electron microphotograph (× 8000).

Spaces between the smooth muscle cells are expanded, which testifies to the local dilatation. At the same time some muscle fibers are thickened and have areas of homogenization. Accumulation of lymphocytes and leukocytes can be observed in perivascular space. Hypertrophy of nuclei of separate cells is found occasionally. There are also found a perivascular edema, fibroblasts in the connective tissue complex of the ciliary body.

There have been found areas of disorganization and destructurization of epithelial cells of the ciliary processes. Epitheliocytes of ciliary processes have a clarified matrix with the loose basement membrane. Cytoplasm of epitheliocytes is swollen unevenly, contains fine acidophilic stippling. Nuclei of separate epitheliocytes are reduced in volume, pyknotic. Chromatin in their nuclei is condensed. Cytoplasm is found to contain vacuoles, numerous autophagolysosomes, pinocytic vesicles; mitochondria are swollen, hypertrophic (►**Fig. 3**). Cristae of mitochondria are destructively altered, matrix is clarified. Epitheliocytes were found with fragmented nuclei and nuclei in the state of karyorhexis. Vacuolized mitochondria in cytoplasm testify to the hydropic dystrophy of epithelium.

Nuclei of epitheliocytes contain no nucleoli. Pericellular edema, dilated intercellular spaces are observed. Intercellular contacts are loose. Cytoplasmic fragments penetrate into the lumen of the posterior chamber of the eye.

Areas with necrotic changes in the connective tissue matrix can be observed in the choroid and the iris. Dynamic increase of connective tissue is visualized with a characteristic dominance of collagen fiber bundles and destruction of smooth muscle elements of the iris. Myocytes of the iris and ciliary body acquire an elongated form. Quantity of heterochromatin is increased in their nuclei, mitochondria are clarified, elements of the Golgi complex and granular endoplasmic reticulum are dilated. Myofilaments are disorganized, lose their clear longitudial orientation. Basement membrane is edematic, loose, but integral. Collagen fibrils are loose. Nexuses dilated. Endomysium is swollen due to loosening of elastic and collagen fibers.

Binuclear cells surrounded by the dystrophically changed vacuolized cytoplasm with a large number of electron-dense corpuscles of various configuration were found.

Discussion

Undoubtedly, narcotic analgesics are needed in medical practice, especially surgical[13] and palliative purposes. However, over time our society faces paramedical aspects of the problem. In particular, this problem is acute among teenagers and young people of working age. It is estimated that 23% of individuals who use heroin develop opioid addiction. Drug overdose is the leading cause of accidental death in the US, with 52,404 lethal drug overdoses in 2015. Opioid addiction is driving this epidemic, with 20,101 overdose deaths related to prescription pain relievers, and 12,990 overdose deaths related to heroin in 2015.[14]

Changes of the pupil diameter under the effect of various narcotic analgesics have been described, taking into account pharmacological effect of narcotic analgesics. After morphine and codeine administration there was a 26% decrease in pupil diameter ($p < 0.001$). Over the course of the study period, pupil diameter gradually returned to baseline values. After administration of tramadol there were no significant changes in pupil diameter until 150 minute after administration, after which there was a significant reduction for the remainder of the study period ($p < 0.01$). The changes in pupil diameter may be explained in part by the

pharmacokinetic profiles of the opioids studied. Measurement of pupil diameter may have a place in monitoring the central effect of opioids.[15]

Combination of morphological and functional studies makes it possible to give a more complete picture and resolve the debatable problems regarding effect of the opioid on the structure of the eyeball vascular tunic, which creates the morphological basis for understanding pathogenesis and further search for the optimal methods of treatment of ophthalmological diseases of patients who have to use opioids for the long periods of time, as well that of the drug addicts.

Conclusion

Thus, with the aid of adequate techniques changes have been demonstrated on the ultrastructural level after 4 weeks of injections of the opioid analgesic, which extends our vision of the danger of a long-term use of narcotic substances.

In particular, we have studied lesions of the endothelium and basement membrane of the hemicirculatory bloodstream components, epithelium of ciliary processes, cellular and non-cellular elements of the iris and the choroid. The study showed swelling of cytoplasm and nuclei of the endotheliocytes, substantially narrowed lumen of the capillaries. Plasmolemma of endotheliocytes forms protrusions into the capillaries' lumen forming microvilli. Changes of destructive nature took place in the elements of the smooth endoplasmic reticulum and mitochondrial complex. The surrounding connective tissue complex shows the signs characteristic of sclerosis.

The data, based on the experimental model, allow to extrapolate the obtained results obtained to humans. It is confirmed that it is the development of angiopathy is the trigger mechanism of the destructive effect of narcotic analgesics.

Conflict of Interest
None.

Acknowledgments
None.

References

1 Bargagli AM, Davoli M, Minozzi S. 2007. A systematic review of observational studies on treatment of opioid dependence. Geneva: World Health Organization
2 Cornish R, Macleod J, Strang J, Vickerman P, Hickman M. Risk of death during and after opiate substitution treatment in primary care: prospective observational study in UK General Practice Research Database. BMJ 2010;341(341):c5475
3 Bailey CP, Connor M. Opioids: cellular mechanisms of tolerance and physical dependence. Curr Opin Pharmacol 2005;5(01): 60–68
4 Bird SM. Over 1200 drugs-related deaths and 190000 opiate-user-years of follow-up: relative risks by sex and age group. Addict Res Theory 2010;18:194–207
5 O'Connor G, McMahon G. Complications of heroin abuse. Eur J Emerg Med 2008;15(02):104–106
6 American College of Obstetricians and Gynecologists. 2017. [viewed on 10 April 2018]. Opioid use and opioid use disorder in pregnancy. Committee Opinion, no. 711, pp. 81–94. Available from: https: www.acog.org
7 Degenhardt L, Stockings E, Strang J, et al. 2016. Illicit Drug Dependence. In: Patel V, Chisholm D, Dua T, et al., editors. Mental, Neurological, and Substance Use Disorders: Disease Control Priorities, Third Edition (Volume 4). Washington (DC): The International Bank for Reconstruction and Development / The World Bank; 2016 Mar 14. Chapter 6. Available from: https://www.ncbi.nlm.nih.gov/books/NBK361953/doi: 10.1596/978-1-4648-0426-7_ch6
8 Popyk PM. Morphometric characteristic of changing of pancreas haemomicrocirculation under Nalbuphine influence. Actual Problem of Modern Medicine 2014;13(44):158–161
9 Logash M. The effect of nalbuphine administration on the rat liver ultrastructure. Indian J Basic Appl Med Res 2017;(06):305–312
10 Mateshuk-Vatseba L, Pidvalna U, Kost A. Peculiarities of vascular tunic microstructure of the white rat eyeball under the effect of opioid. Rom J Morphol Embryol 2015;56(03):1057–1062
11 Pokotylo PB. Changes of the rats cardiomyocytes mitochondrial apparatus on early stages of chronic opioip inflammation. The World Medicine Biology 2014;45:141–144
12 French DD, Margo CE, Harman LE. Substance use disorder and the risk of open-angle glaucoma. J Glaucoma 2011;20(07):452–457
13 Gong Y, Zhang Y, Tao S. Nalbuphine for analgesia after fracture surgery and its effect on circulating inflammatory factors. Exp Ther Med 2018;15(01):859–863
14 Rudd RA, Seth P, David F, Scholl L. Increases in Drug and Opioid-Involved Overdose Deaths - United States, 2010-2015. MMWR Morb Mortal Wkly Rep 2016;65(50-51):1445–1452
15 Knaggs RD, Crighton IM, Cobby TF, Fletcher AJ, Hobbs GJ. The pupillary effects of intravenous morphine, codeine, and tramadol in volunteers. Anesth Analg 2004;99(01):108–112