Published online: 2019-01-08

Epidermoid Cyst in the Cerebellopontine Angle: Technical Description Video

Marcus Vinicius de Morais[1] Romulo Almino de Alencar Arrais Mota[1] Thais Aparecida Marques[1] Rafael Duarte de Souza Loduca[1] Paulo Mácio de Porto Melo[1]

[1] Department of Neurosurgery, Hospital Militar de Área de São Paulo, São Paulo, Brazil

J Neurol Surg B 2019;80(suppl S3):S325–S326.

Address for correspondence Marcus Vinicius de Morais, MD, Department of Neurosurgery, Hospital Militar de Área de São Paulo, Rua Vergueiro, 4241 Apto 91, CEP 04101-300, São Paulo, SP, Brazil (e-mail: moraisneuro@gmail.com).

Abstract

Objectives To describe the operative technique for treatment of epidermoid cysts in the cerebellopontine angle (CPA).

Design The present video is a case report.

Setting Patient is positioned in three-quarters prone. Retrosigmoid approach should be made under neurological monitoring and with neuronavegation to help achieve maximal safe resection. The skin incision is vertical, slightly curved, 5 mm medial to the mastoid notch. Craniectomy is superiorly limited by the transverse sinus and laterally limited by the sigmoid sinus. A **C**-shaped durotomy is made with its base protecting the sigmoid sinus. The lesion is removed in piecemeal fashion (►**Fig. 1**). The neurological monitoring helps.

Results The patient was discharged 2 days later without neurological deficits.

Conclusions The surgical treatment associated with neurological monitoring and neuronavegation is a safe procedure to treat epidermoid cysts in the CPA.

The link to the video can be found at: https://youtu.be/sEuFyq9c2sw.

Keywords
- ► epidermoid cyst
- ► cerebellopontine angle lesion
- ► cerebellopontine angle microsurgery
- ► epidermoid cyst surgery

Conflict of Interest
None to disclose.

www.thieme.com/skullbasevideos

www.thieme.com/jnlsbvideos

received
June 1, 2018
accepted after revision
November 11, 2018
published online
January 8, 2019

DOI https://doi.org/10.1055/s-0038-1676997.
ISSN 2193-6331.

© 2019 Georg Thieme Verlag KG Stuttgart · New York

License terms

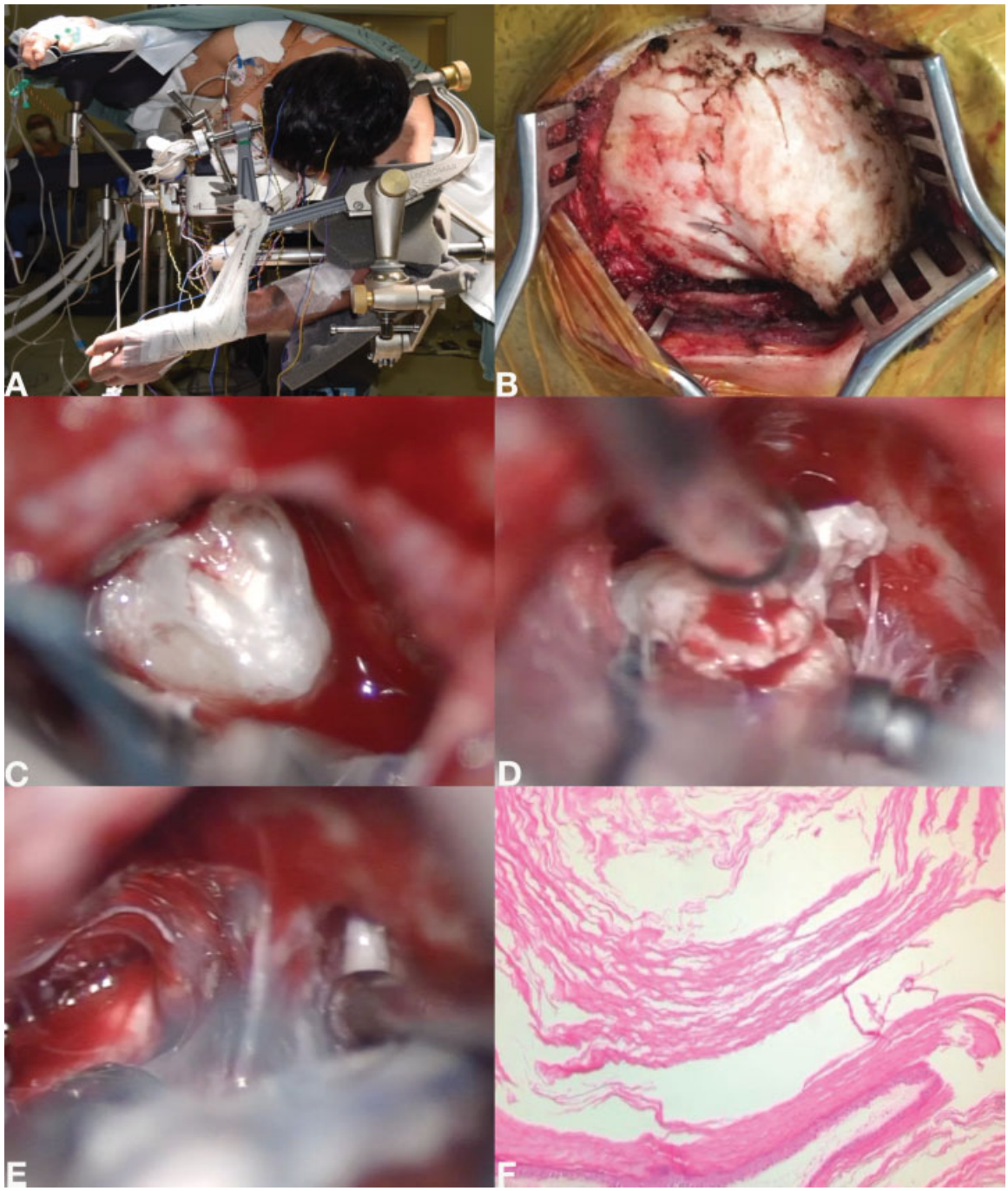

Fig. 1 Intraoperative images. (**A**) Patient position, (**B**) asterion exposure, (**C**) epidermoid cyst identification, (**D**) lesion removal in piecemeal fashion, (**E**) intraoperative neurological monitoring, (**F**) anatomopathological study confirming the diagnosis.