

# Current State of Neuromodulation for Constipation and Fecal Incontinence in Children: A Systematic Review

Roberta Iacona<sup>1</sup> Lisa Ramage<sup>2</sup> Georgina Malakounides<sup>1</sup>

<sup>1</sup>Department of Paediatric Surgery, Addenbrooke's Hospital, Cambridge, United Kingdom

<sup>2</sup>Department of Colorectal Surgery, Chelsea and Westminster Hospital NHS Foundation Trust, London, United Kingdom

**Address for correspondence** Roberta Iacona, MBBS, MD, Department of Paediatric Surgery, Addenbrooke's Hospital, Hills Road, Cambridge CB2 2QQ, United Kingdom (e-mail: roberta.iacona@yahoo.com).

Eur J Pediatr Surg 2019;29:495–503.

## Abstract

**Background** Neuromodulation is the application of electrical stimulation on nerve fibers to modulate the neuronal activity. Its use for chronic constipation and fecal incontinence has increased in popularity over the past few years. Invasive and noninvasive techniques are currently available. We reviewed the current literature on the application of the neuromodulation techniques in the management of chronic constipation and fecal incontinence in children.

**Materials and Methods** A search of Healthcare Database Advanced Search, Embase, Medline, and Cochrane database was performed in accordance with PRISMA guideline. Terms used in the search included neuromodulation, nerve stimulation, fecal/fecal incontinence, incontinence, constipation, children, and pediatric/pediatric.

**Results** Two-hundred forty-one papers were screened. Fourteen papers were included for the systematic review: seven were selected for the ISNM (implantable sacral nerve modulation) technique, one for the transcutaneous tibial nerve stimulation), one for the transcutaneous sacral nerve modulation), and five for the transcutaneous interferential sacral nerve stimulation. Results showed an overall improvement in constipation symptoms in 79 to 85.7% of patients, resolution of symptoms in 40%, reduced use of ACE stoma/transanal irrigation system in 12.5 to 38.4%, and improvement in incontinence symptoms in 75%. High complication rate was reported (17–50%) in the ISNM group. No complications were reported in the non-invasive group.

**Conclusion** Neuromodulation is a promising tool in the management of constipation refractory to medical treatment and fecal incontinence in children. Noninvasive techniques provide good results with no complications. A longer term follow-up will provide more information regarding patient compliance and sustainability of benefits of these new techniques.

## Keywords

- ▶ neuromodulation
- ▶ fecal incontinence
- ▶ chronic constipation
- ▶ pediatric

## Introduction

Chronic constipation and soiling refractory to medical treatment is a common referral to pediatric surgeons and gastroenterologists. Patients mostly have an underlying diagnosis

of chronic idiopathic constipation, but other patient groups include those with congenital colorectal conditions (Hirschsprung's and anorectal malformations) and neuropathic bowel (spina bifida, sacrococcygeal teratomas). Treatment options have evolved over time and the plethora of

received  
September 24, 2018  
accepted after revision  
December 5, 2018  
published online  
January 16, 2019

© 2019 Georg Thieme Verlag KG  
Stuttgart · New York

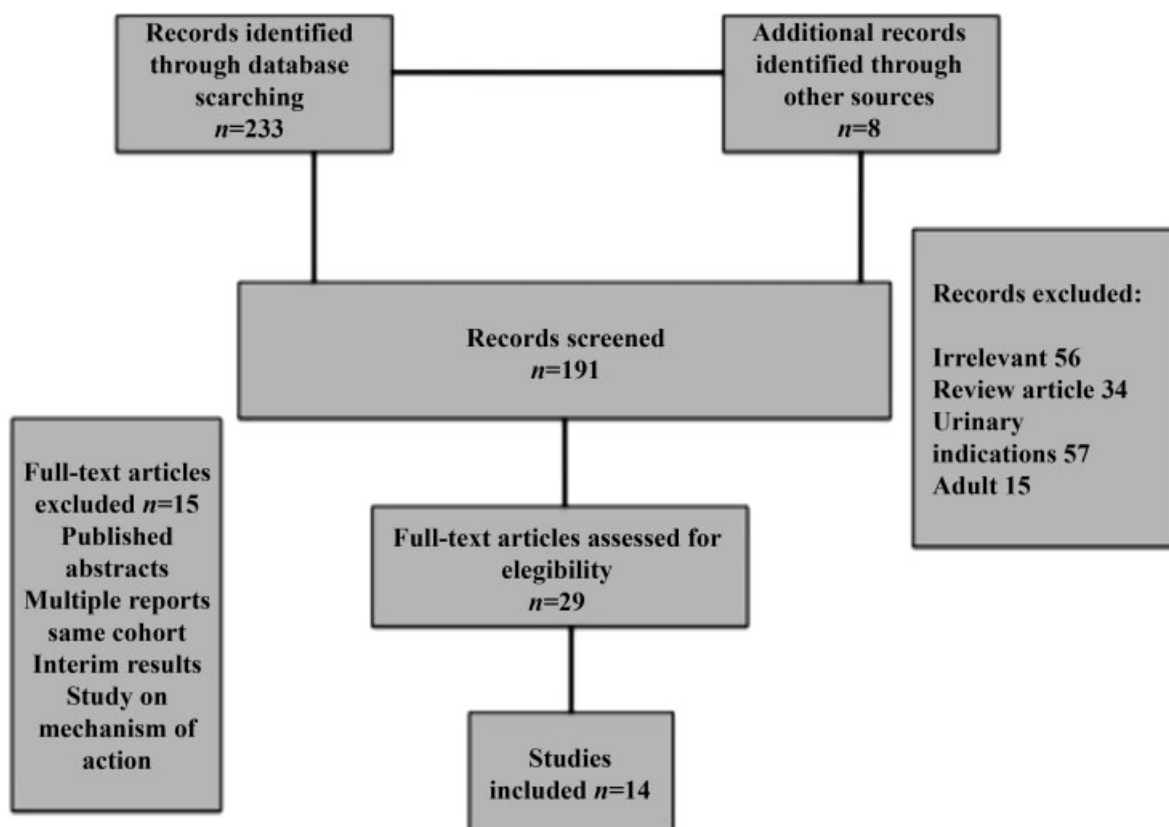
DOI <https://doi.org/10.1055/s-0038-1677485>.  
ISSN 0939-7248.

approaches over the years reflects how difficult this can be to manage, with a combination of substantial health, economic, and emotional burdens. Surgical approaches have included anal sphincter procedures (dilatations, myectomies, intrasphincteric botulinum toxin), colonic resections, colonic pull-throughs, and long-term colostomies. In more recent years, colonic washouts have overall become the mainstay surgical approach with the introduction of the antegrade continence enema (ACE) stoma by Patrick Malone et al published in the *Lancet* in 1990.<sup>1</sup> Initial experience was promising. The prerequisite has been appropriate patient selection often failing for children with psychological or behavioral difficulties meaning they are unable to engage with the process. National Institute for Health and Care Excellence (NICE) published guidelines in 2015 supporting the ACE stoma as the surgical option of choice for constipation refractory to medical management.<sup>2</sup> However, in more recent years, there has been a national and international move away from the ACE stoma and toward transanal irrigation as an alternative means of colonic washout. Patrick Malone himself published his experience of transanal irrigation in the *Journal of Pediatric Urology* in 2014<sup>3</sup> where he describes how transanal irrigation avoided the need for the formation of an ACE stoma in 24 out of 25 patients. Recent NICE guidelines from 2017, including opinions from the British Association of Pediatric Surgeons UK Pediatric Colorectal group, advocate the use of transanal irrigation. There are, however, patients who do not engage with this process due to its use of the transanal route.

It can be considered invasive—some do not find it psychologically acceptable or some with behavioral challenges are not appropriate candidates. Another option that is increasing its popularity is neuromodulation. Neuromodulation and electroneurostimulation are two terms used in literature to define the use of electrical nerve stimulation in different clinical fields, such as neurology, cardiology, urology, and gastroenterology. There are different invasive and noninvasive modalities available: implantable or transcutaneous sacral nerve stimulators, percutaneous or transcutaneous posterior tibial nerve stimulators, or interferential (IF) therapy. It has become established practice in adult services with NICE guidelines published in 2004 on the use of sacral neuromodulation for fecal incontinence and its use has been well documented for the treatment of adult bladder-bowel dysfunction. We performed a systematic review of published literature of the use of neuromodulation in children for constipation and soiling refractory to medical treatment.

## Materials and Methods

We used the following database: Healthcare database advanced search, Embase, Medline, and Cochrane. The systematic review was undertaken in accordance with the PRISMA guidelines.<sup>4</sup> Further records were identified through citation titles and references. Two researchers performed the search and data extraction independently. The used terms were



**Fig. 1** Diagram: PRISMA flow chart.

neuromodulation, nerve stimulation, faecal/fecal incontinence, incontinence, constipation, children, and pediatric/pediatric. A total of 233 records were identified through database searching; 8 additional records were identified through other sources. One-hundred ninety-one papers records were screened, 162 were excluded. Twenty-nine full-text articles were assessed for eligibility. Fourteen papers were examined as matching the searching criteria, selected and analyzed. Criteria for exclusion of the papers were duplicate papers, irrelevant, review, urinary indication for neuromodulation, adult population, multiple reports on the same cohort, and studies only on mechanism of action (►Fig. 1). Due to the heterogeneity of the data, it was not possible to perform any statistical analysis.

**Inclusion criteria:** All of the published studies up to July 2018 and reporting the use of the neuromodulation technique, either invasive and noninvasive, for the treatment of fecal incontinence and/or constipation in children were evaluated.

**Report eligibility:** No exclusion was made based upon the study size or publication language. Published abstracts were excluded as they lacked enough information. In publications from the same center, the last chronologically published series was used in the data analysis to avoid duplication of data. At least one chosen outcome measure (baseline and post intervention) had to be mentioned.

**Participants:** No exclusion was made based upon the study center or patients regarding sex, ethnicity, or etiology of fecal incontinence and/or constipation. The outcomes of interest included patient reported complaints, fecal incontinence, score, quality of life score, anorectal physiology results, and adverse outcomes.

Age was limited to the pediatric population. Excluded any studies reporting on the use of combined new therapies -neuromodulation and studies including concomitant intervention, such as biofeedback.

## Results—Model of Studies

Overall, 14 studies were selected and were matching the search criteria. Four-hundred twenty-eight patients received neuromodulation therapy for chronic constipation/fecal incontinence. Seven papers were selected for the implantable sacral neuromodulation (ISNM), one paper for the transcutaneous posterior tibial nerve stimulation (TPTNS), one for the transcutaneous sacral nerve modulation, and five papers for the use of transcutaneous interferential sacral nerve stimulation (TISNS). Population size and model of the study are described in ►Table 1.

### Results: Invasive Neuromodulation Technique—ISNM

Seven papers were found in the published literature, four prospective studies, one randomized multicenter crossover trial, and two retrospective studies on children were published from 2010 until 2017. A total of 280 patients received the ISNS treatment. The age range was from 6 to 20 years and available in all the papers evaluated. Two-hundred two were female. The diagnoses were mainly represented by intractable chronic constipation (Rome III criteria),<sup>5</sup> neurogenic bowel and bladder, anorectal malformations, and Hirschsprung's disease (see ►Table 2).

Exclusion criteria were age less than 5 years, local risk for implantation, failure to detect the S3 root, anatomical/neurological anomalies (spina bifida, in patients unable to walk), complex bladder/pelvic reconstruction, previous large bowel surgery, irritable bowel syndrome, and psychological comorbidities. Indications to the ISNM were functional constipation (5/6 studies), dysfunctional elimination syndrome (DES) (1/6 studies), and fecal incontinence (2/6 studies).

Baseline evaluation of patients was reported heterogeneously within the different papers; clinical examination,

**Table 1** Model of studies

Authors	Year	Type of technique	Type of study	Number of patients
Haddad et al <sup>10</sup>	2010	ISNM	Randomized crossover study	33
van Wunnick et al <sup>6</sup>	2012	ISNM	Retrospective study	13
Dwyer et al <sup>7</sup>	2014	ISNM	Retrospective study	105
Sulkowski et al <sup>11</sup>	2015	ISNM	Prospective study	29
van der Wilt et al <sup>12</sup>	2016	ISNM	Prospective study	30
Lu et al <sup>8</sup>	2017	ISNM	Retrospective study	45
Lu et al <sup>8</sup>	2017	ISNM	Prospective study	25
Lecompte et al <sup>13</sup>	2015	TPTNS	Prospective study	8
Veiga et al <sup>15</sup>	2013	TSNM	Prospective study	14
Yik et al <sup>21</sup>	2011	TISNS	Randomized controlled trial	46
Kajbafzadeh et al <sup>18</sup>	2012	TISNS	Randomized controlled trial	30
Yik et al <sup>22</sup>	2012	TISNS	Prospective study	32
Yik et al <sup>23</sup>	2016	TISNS	Pilot study	10
Singh et al <sup>24</sup>	2017	TISNS	Pilot study	8

Abbreviations: ISNM, implantable sacral nerve stimulation; TISNS, transcutaneous interferential electrical stimulation; TPTNS, transcutaneous posterior tibial nerve stimulation; TSNM, transcutaneous sacral nerve stimulation.

**Table 2** Invasive neuromodulation results

Authors	Diagnosis	Preimplant results	Follow-up results	Follow-up	Complications (%)
Haddad et al 2010 <sup>10</sup>	Neuropathic bowel and bladder: 76% Anorectal malformations: 15%	ND	ND	ND	18
van Wunnick et al 2012 <sup>6</sup>	Functional constipation: 100%	Defecation frequency per week: 1.5 Cleveland Clinic Constipation: 20.9 –Abdominal pain (1–5): 4.8 –Straining (1–5): 4.2 –Incomplete evacuation: 4.5	Defecation frequency per week: 4.8 Cleveland Clinic Constipation: 9.4 –Abdominal pain: 3.0 –Straining: 2.2 –Incomplete evacuation: 3.0	12 months	23
Dwyer et al 2014 <sup>7</sup>	Functional constipation: 100%	ND	Improvement in incontinence: 86% Resolution of incontinence: 40% Improvement of constipation: 78% Resolution of constipation: 47%	31 months	36
Sulkowski et al 2015 <sup>11</sup>	Functional constipation: 65.5% Hirschsprung's disease: 3.4% Syrinx: 3.4% Anorectal malformations: 27.6% Tethered cord: 3.4% Myelomeningocele: 3.4%	FIQL scale: –Lifestyle: 3.0 –Coping/behavior: 2.8 Depression/self-perception: 3.3 –Embarrassment: 3.0 FISI: 15 PaedsQL GI symptom scale: 13 Vancouver DES Symptom score: 17	FIQL scale: –Lifestyle: 3.8 –Coping/behavior: 3.8 Depression/Self-perception: 4.1 –Embarrassment: 3.7 FISI: 18 PaedsQL GI symptom scale: 8 Vancouver DES Symptom score: 10	17.7 weeks	55
van der Wilt et al 2016 <sup>12</sup>	Functional constipation: 100%	Defecation frequency per week: 1.9 Wexner score: 18.6 Abdominal pain score: 3.62	Defecation frequency per week: 5.8 Wexner score: 8.2 Abdominal pain score: 1.53	12 months	50
Di Lorenzo et al 2017	Functional constipation: 64% Anorectal malformations: 24% Tethered cord: 8% Hirschsprung's disease: 4%	Defecation < 3 times per week: 18% Fecal incontinence: 72% Abdominal pain: 68% GSS: 59.7% FIQL scale: –Lifestyle: 3.0 –Coping/behavior: 2.8 –Depression/Self-perception: 2.8 –Embarrassment: 3.0 FISI: 32.5	Defecation < 3 times per week: 14% Fecal incontinence: 20% Abdominal pain: 41% GSS: 80.6 FIQL scale: –Lifestyle: 3.9 –Coping/behavior: 3.7 –Depression/Self-perception: 3.3 –Embarrassment: 3.3 FISI: 30.0	24 months	24
Janssens et al 2017	Functional constipation: 100%	Defecation frequency per week: 1.7 Abdominal pain score: 15.5 Cleveland Clinic Constipation Score: 17.9	Defecation frequency per week: 5.5 Abdominal pain score: 8.4 Cleveland Clinic Constipation Score: 8.9	48 months	53

Abbreviations: DES, dysfunctional elimination syndrome; FIQL, Fecal Incontinence Quality of Life; FISI, Fecal Incontinence Severity Index; ND, not discussed in the paper; Paeds QL GSS, Pediatric Quality of Life Gastrointestinal Symptom Scale; ISNM, implantable sacral nerve stimulation.

3 weeks bowel and bladder diary compilation, defecation frequency, urodynamic study, anorectal manometry, defecography, colonic transit time, and spinal magnetic resonance imaging (MRI) were used. The following symptoms assessment score/scale were used: Vancouver DES Symptoms Scale, Cleveland Clinic Constipation Score (CCCS), and Jorge–Wexner

Score. The life quality tests used were FIQL (Fecal Incontinence Quality of Life Score), Paeds QL GSS (Pediatric Quality of Life Gastrointestinal Symptom Scale), FISI (Fecal Incontinence Severity Index), and parents satisfaction questionnaire.

All the published studies reported a two-stage technique of implant for ISNM, as previously described.<sup>6–12</sup> The first stage is

the diagnostic stage for which two possible options are available: temporary wire or tined lead. Following the testing period of generally 2 to 3 weeks, patients received the definitive implant in which the implantable stimulator was implanted. The correct placement was confirmed by observing motor and/or sensory responses such as pelvic floor contraction, great toe flexion, and/or anal or vaginal region paresthesia.<sup>6</sup> In all the studies, a testing needle was used to identify the correct sacral foramen (Bellow's contraction). The device used was Medtronic Interstim (model 3058/3057/3093/38889/3625/3531). Criteria for definitive implant were more than 50% improvement in the baseline symptoms<sup>7</sup> and more than three time increase in defecation frequency per week.<sup>8,9</sup> Haddad et al<sup>10</sup> in their crossover study divided the patients as responders or nonresponders regarding the fecal performance; the response was defined as resolution of fecal soiling with no need for pads or a decrease of more than 50% in the numbers of leaks or soiling episodes. Overall, a positive response rate was more than 75%, indicating that neuromodulation was more effective than conservative treatment of fecal incontinence. van Wunnick et al<sup>6</sup> in 2012 reported an improvement in defecation frequency and a significant decrease in abdominal pain in all of the patients and a persistency of the improvement in symptoms at 6 months and 12 months follow-up. Dwyer et al<sup>7</sup> reported constipation as improved in 79% and resolved in 40%. Sulkowski et al<sup>11</sup> showed in their results that nearly all patients (93.1%) suffered from gastrointestinal (GI) complaints, 65% had urinary symptoms, and 58.6% reported both GI and urinary complaints. The 72.4% of their cohort did not report any pain at the implant site. After SNM placement, 46.2% of the patients stopped the use of the ACE and the 38.4% reduced the use of the ACE. The 37.5% of the cohort decreased the need for enema use. Patients with a background of ARMs improved in all measures but only achieved statistical significance for the embarrassment questions of the FIQL scale. van der Wilt et al<sup>12</sup> reported an improvement in defecational frequency from 1.96 times per week to 5.8 times. The Wexner score decreased from 18.6 at the baseline to 8.2 at the follow-up (22 months). Measured outcomes such as the abdominal pain score or the straining improved and incomplete defecation also decreased. Lu et al<sup>8</sup> reported an increase in the defecation frequency from 18 to 14% of cohort, decrease in the fecal incontinence from 72 to 20%, the urinary incontinence from 56 to 20%, and the abdominal pain from 68 to 41%. Janssen et al<sup>9</sup> reported an increase in the defecation frequency from 1.7 per week to 5.5 times per week, and the abdominal pain per 3 weeks decreased from 15.5 to 8.4% and the CCCS from 17.9 to 8.9. The follow-up was from a minimum of 12 months to 48 months.

Overall 106/280 (38%) patients who underwent ISNM experienced a postimplant complication. Seventy-two percent 76/106 patients required one or more surgical procedure for either removal or repositioning of the device. Complications were represented by need for revision of the device due to lead migration, faulty device connection, and dislocation of the device, pain at the pocket site, battery depletion, and local infection. The rate of complications was reported in all of the papers and it was in between 17.2 and 50%.

### Noninvasive Neuromodulation Techniques

Transcutaneous tibial nerve stimulation, transcutaneous sacral nerve stimulation (TSNS), and transcutaneous IF electrical stimulation.

#### Transcutaneous Electrical Posterior Tibial Nerve Stimulation

Only one paper was found in the published literature regarding the use of transcutaneous posterior tibial nerve stimulation in the treatment of fecal incontinence in the pediatric population.

Lecompte<sup>13</sup> et al published in 2015 their prospective pilot study performed on 8 children: 3 girls and 5 boys. The mean age was 11.75 years (10–13 years) and the diagnoses were sacrococcygeal teratoma (1/8), anorectal malformations (4/8), Hirschsprung's disease (1/8), medullary lipoma with tethered spinal cord (1/8), and Chiari's malformation (1/8). The outcome measurements were evaluated at baseline and the Jorge-Wexner scale for fecal incontinence was used.<sup>14</sup>

Baseline evaluation of the patients included anorectal manometry and urodynamic study.

All of the patients suffered from fecal incontinence and some had also associated urinary incontinence. All were previously treated for 2 years using medications (anticholinergics), transit regulators, colonic washouts, abdominal and perineal rehabilitation, and psychological support.

The technique used for the posterior tibial nerve stimulation consisted of the application of one autoadhesive electrode (positive) 3 to 4 cm above the medial malleolus and the second electrode (negative) underneath the same malleolus of the same leg. Both electrodes were then connected to an external electrical stimulation device (Urostim) set on a low frequency current (10 Hz) with an intensity that was adjusted until the flexion of the big toe was achieved. The intensity used was reported as 10 and 25 mA. The stimulation regime consisted of 20 minutes home sessions, with parental applications of the electrodes. The treatment duration was 6 months, with control at 2 and 6 months. The PTNS was applied over 9 months (7–14 months).

Lecompte et al<sup>13</sup> reported a significant improvement in the mean Jorge-Wexner score between pre-PTNS and at 6 months follow-up from 12.25 to 3.125 ( $p = 0.02$ ). The patients with ARMs showed a better response than the patients with a background of Hirschsprung's disease (ARMs score 0/1; Hirschsprung's disease score 7). At 6 months follow-up, only one patient out of eight was able to stop the transanal irrigation. None of the eight patients reported any side effects from the stimulation itself.

#### Transcutaneous Sacral Nerve Stimulation

Our literature search identified one paper that met our criteria for transcutaneous stimulation of the sacral nerve in children for the treatment/management of constipation. This paper was a prospective pilot study published in 2013 by Veiga et al.<sup>15</sup>

In this published study, 14 children (9 girls and 5 boys) with symptoms of lower urinary tract dysfunction (LUTD) and associated constipation received the parasacral TSNS.



Their median age was 7 (5–11 years). All of the children presented LUTD: 10 had overactive bladder (71.4%) and 4 had voiding dysfunction (28.6%). Inclusion criteria were the presence of chronic constipation defined as per Rome III Criteria<sup>5</sup> and when they presented at least two of the six symptoms for more than 2 months.

Patients with neurological anomalies, genetic syndromes, and anatomical alteration of the lower urinary tract were excluded. None of the patients was treated for constipation before they were enrolled for this study.

Baseline evaluation before starting the treatment included physical examination including rectal exam and neurological examination, evaluation of symptoms according to Rome III Criteria, and Bristol Stool Visual Scale.<sup>5</sup> The same authors described the technique used for the parasacral transcutaneous stimulation, in 2010:<sup>16</sup> two self-adhesive 3.5 cm electrodes were placed side of S2 and S4. The transcutaneous sacral nerve stimulation was performed three times a week, for 20 minutes sessions; the 961 Duplex Uro, Quark device was used.

In their results, Veiga et al reported that after the treatment 85.7% of the children's constipation symptoms had improved according to the Rome III criteria. No significant change was noted based on the Bristol Stool Chart<sup>17</sup> however, the abdominal pain improved before and after the treatment (see results in [Table 3](#)).

No complications were reported following this study. No long-term follow-up was available.

### Transcutaneous Interferential Electrical Stimulation

Five papers published from 2009 until today were selected for our review: two randomized control trials, one prospective study, and two pilot studies. Three of these studies come from the same group, though the patient groups were

different. Three of the selected studies were home-therapy TISNS. As previously stated, we excluded mixed techniques studies such as contemporary use of behavioral therapy or physical exercises and IF therapy. A total of 126 patients received the TISNS treatment for chronic constipation. The range of ages was 3 to 18 years and was available in all the papers. The diagnoses were mainly represented by slow transit chronic constipation (proved by nuclear transit time study, NTS) and neurogenic bowel due to myelomeningocele. All of the studies reported baseline assessment of the patients with bowel diary, complete physical examination, anorectal manometry, defecation frequency, NTS, and Paeds QL 4.0 questionnaire. Inclusion criteria for IF therapy were age 8 to 18 years, Kajbafzadeh et al<sup>18</sup> reported a minimum age of 3 years, slow transit constipation proved at nuclear transit study, at least 2 years history of chronic constipation defined according to the Rome II Criteria,<sup>19</sup> or to the Paris Consensus on childhood Constipation terminology,<sup>20</sup> with a minimum period of 8 weeks and at least the presence of two of the following symptoms: defecation frequency less than 3 times per week, fecal incontinence more than 3 times per week, large stools passage, palpable abdominal mass, and pain at defecation. Exclusion criteria, when reported, were normal colonic transit time proved at a recent NTS, metabolic or hormonal causes, Hirschsprung's disease, anorectal malformations, surgical procedures that resulted in discontinuity of the GI tract, skin sensitivity, V-P shunt, pacemakers, intellectual disability and inability to fill the diary or the questionnaire, previous TISNS treatment for constipation.

The technique used for TINSN was described in all of the four papers. Four self-adhesive electrodes were positioned to obtain the quadripolar stimulation. Two electrodes were placed on the anterior abdominal wall below the costal margin and two electrodes were positioned on the back at different levels according to the authors (T9-L2, T12-L4, L4-L5 or S2-S4). A different positioning of the electrodes was reported in one paper. The type of device used was the same for Yik Yi et al.<sup>21–23</sup> (IFN 4160, Fuji Dynamics Ltd. Hong Kong), while Kajbafzadeh et al<sup>18</sup> reported the use of a different type of device (126 DS double-channel Tavanbakhsh Novin, Teheran, Iran). The type of current delivered was 4 kHz in all of the studies, with a beat frequency adjusted of 80 to 150 Hz/ 5 to 25 Hz/4080 to 4160 Hz.

The regime used was of session of 20 minutes three times a week, when not home delivered by parents.

Overall all of the studies reported an improvement in symptoms reported as defecation frequency, soiling episodes, abdominal pain and, when evaluated, in terms of manometry results (see [Table 4](#)).

Singh et al<sup>24</sup> also described in their results the effects during the interferential therapy (see [Table 4](#)). Their results showed a reduction in laxative use from pre-TISNS to post-TISNS period, though these results were not statistically significant. In their paper, they also mention the reduced need of ACE stoma washout during TISNS therapy. No complications have been reported in all of the studies considered.

**Table 3** Transcutaneous sacral nerve stimulation: Results

	Before treatment, n (%)	After treatment, n (%)	p-Value
Rome III criteria			
< 2 defecations/week	2 (14.3)	2 (14.3)	1
> 1 fecal incontinence/week	7(50)	1 (7.1)	0.031
Stool retention	6 (42.9)	0 (0)	0.001
Pain or force	9 (64.3)	5 (37.5)	0.21
Fecal mass	11 (78.8)	1 (7.1)	0.002
Large stools	7 (50)	3 (21.4)	0.21
Bristol stool visual scale			
Constipation	4 (28.6)	1 (7.1)	0.25
Normal	10 (71.4)	13 (78.6)	ND
Visual analogue scale			
0–5	6 (42.9)	11 (78.6)	0.063
6–10	8 (57.1)	3 (21.4)	ND

**Table 4** Transcutaneous interferential sacral nerve stimulation—Results

Author	Results at baseline at initial assessment	Results at last follow-up	Follow-up months
Yik et al 2011 <sup>21</sup>	ND	NUGM 88% UGD 40%	2
Kajbafzadeh 2012 <sup>18</sup>	Defecation frequency per week: 2.5 +/- 1.1 Form of stools: 1.8 +/- 4.1 Pain at defecation: 35 +/- 4.8 NBD score: 11.95 +/- 2.7 Sphincter pressure: 47 +/- 20 RAIR: 49.5 +/- 12.2	Defecation frequency per week: 4.7 +/- 2.3 Form of stools: 2.6 +/- 5.9 Pain at defecation: 20 +/- 41 NBD score: 7.1 +/- 2.7 Sphincter pressure: 25 +/- 1 RAIR: 35 +/- 12	6
Yik et al 2012 <sup>22</sup>	Defecation frequency per week: 4.4 +/- 3.9 Soiling: 5.0 +/- 6.4 Abdominal pain: 1.6 +/- 2.1	Defecation frequency per week: 5.3 +/- 3.9 Soiling: 2.9 +/- 4.5 Abdominal pain: 0.9 +/- 1.1	3–6
Yik et al 2016 <sup>23</sup>	Defecation frequency per week: 0.9 +/- 0.8 Soiling: 5.9 +/- 1.9 d/w Abdominal pain: 1.20 +/- 1.1 d/w VAS score: 1.5 +/- 1.2	Defecation frequency per week: 3.2 +/- 2.3 Soiling: 1.9 +/- 2.0 d/w Abdominal pain: 0.2 +/- 0.4 VAS score: 4.4 +/- 2.6	3
Singh et al 2017 <sup>24</sup>	Spontaneous bowel movement per month: 14 PQL: 81 Abdominal pain days per month: 4	Spontaneous bowel movement per month: 18.5 PQL: 88.6 Abdominal pain days per month: 2	1

Abbreviations: NBD, neurogenic bowel dysfunction score; ND, not discussed in the paper; NUGM, normal upper GI motility; PQL, pediatric quality of life; RAIR, rectoanal inhibitory reflex; UGD, upper gastrointestinal dysmotility; VAS score, visual analogue scale score.

## Discussion

Neuromodulation is a term used to define the application of electrical stimulation on nerves fibers to modulate the neuronal activity. The possible mechanism of action of the neuromodulation on chronic constipation and fecal incontinence is still unclear. The electrical stimulation acts on the nerve fibers and on the cells characterized by the presence of ion channels on their cellular membranes. The electrical stimulation seems to be responsible for the activation of the membrane channels allowing the current flow between the extracellular fluid and the cytoplasm.<sup>25</sup>

Sacral neuromodulation was first used in the management of pelvic floor disorders and urology. It was the observation that these patients were experiencing an improvement in the fecal incontinence that sparked further interest toward the possible application of neuromodulation for bowel disorders.<sup>26–29</sup>

Different techniques of neuromodulation are currently available. The electrical stimulation of the sacral nerve (sacral neuromodulation [SNM]) can be obtained either with invasive techniques (placement of electrodes through the sacral foramen) or noninvasive (transcutaneous stimulation). This stimulation potentially has an effect on large bowel peristalsis even in patients with spinal cord injuries.<sup>30,31</sup> The studies selected on invasive SNS; all suggest that SNS is effective in children with constipation refractory to medical management and that the benefits were sustained with the longest reported follow-up of 2 years. Di Lorenzo et al published a 2 years follow-up study, reporting in their data the improvement in fecal incontinence with a 68% of successful response and the 24% of their patients reducing the use of laxatives or ACE. The same study highlighted though that a quarter of their population experienced complications requiring further surgery. Looking through the literature, the

complication rate following ISNS (as shown in [Table 2](#)) is in between 17 and 53% and the reoperation rate was in between 11 and 50%. Another crucial argument may be that the implanted device could interfere with the follow-up of patients affected by medullary/spinal conditions requiring MRI. In the presence of the implanted stimulator, it will be likely for the MRI not be performed in view of the metal components of the stimulator.

The PTNS is a technique that has been used either as transcutaneous or percutaneous since 1983, in adults for the treatment of urinary incontinence, chronic pelvic pain, sexual dysfunction, and fecal incontinence.<sup>32</sup> Its mechanism of action remains unclear, but it has been postulated that the stimulation of the posterior tibial nerve could stimulate the pudendal nerve via afferents fibers, leading to contraction of striated pelvic floor fibers, activation of detrusor inhibitory reflex, and initiation of better transit time.<sup>33,34</sup> The only study presenting the use of PTNS in the pediatric population was published in 2015 by Lecompte et al. They reported an improvement of more than 75% in fecal leaks and an important decrease in Jorge–Wexner and Schurch et al score for urinary incontinence, suggesting that the percutaneous stimulation of the posterior tibial nerve might be considered as a valid tool in the management of fecal incontinence and urinary leaks in pediatrics. The follow-up, however, was only 6 months.

Several noninvasive techniques have been developed and used for the treatment of fecal incontinence and constipation.

The use of IF therapy for the management of childhood constipation was introduced in 2005 in Melbourne when Janet Chase, a physiotherapist with a continence interest, noted how it caused diarrhea when used for urinary incontinence. She performed a pilot study on the application of IF for chronic constipation in children and published the first paper on its use in 2005.<sup>35</sup> The study included eight children with chronic

constipation and soiling for a minimum of 4 years who had not responded to medical and behavioral treatment. The protocol used was the application of IF for 30 minutes 3x/week in clinic. The study reported a significant increase in defecation (6/8) and decrease in soiling (7%) with a reported sensation of urge to stool. Following the first experience with the pilot study, the Australian group continued to use IF on children with chronic constipation and performed a randomized controlled trial published in 2009.<sup>36</sup> The study involved 26 patients, randomized to real or placebo treatment for 1 month plus a further 1 month of real treatment for all of the patients. The study showed a colonic nuclear transit significantly faster in the real treatment group  $p < 0.0001$  with no significant change in placebo group. In 2011, the same authors published the long-term outcome follow on study.<sup>37</sup> Thirty patients were considered with a mean follow-up of 3.5 years. There was clinical improvement in two-thirds of children lasting more than 2 years in one third. A further pilot study was performed demonstrating IF therapy could be performed by families at home.<sup>38</sup> The mechanism of action of IF current therapy in GI disorder is not completely understood. Several possible hypotheses have been suggested to try to explain how the cutaneous application of IF therapy can have effects on bowel activity and how this effect persists for some months after the stimulation ceases. It is postulated that an IF current may influence the neuroplasticity of the enteric nerves, inducing structural intrinsic or synaptic changes leading to altered neuronal function. IF current also seems responsible of increased colonic activity, but evidence has not been found on this regard. It seems, however, that IF stimulation exerts its effects via electrically stimulating excitable cells such as the interstitial cells of Cajal, which produce slow wave activity in the bowel responsible for peristalsis, or that it directly stimulates the nerves of the enteric nervous system. It has also been suggested that due to the positioning of the posterior electrodes, very close to the spinal cord, this could evoke and influence the autonomic nervous system either through the afferent or efferent pathways. Also, a possible hormonal component has been considered as playing some role in the effect of the IF therapy on the bowel.<sup>36–42</sup> The studies that we have considered for this review all showed how the spontaneous bowel movements increased during the treatment and were maintained at the follow-up; however, this was at a maximum of 6 months. Considered outcomes such as pain score and manometry parameters also improved.<sup>19</sup>

By the evaluation of the published literature, it appears that neuromodulation is a promising tool in the treatment of fecal incontinence and constipation in children. Newer techniques, especially the noninvasive neuromodulation techniques (such as the IF therapy), seem to be promising, appealing due to their noninvasive nature and home applicability and complication free. Limitations of this systematic review included the heterogeneity of patient population and the length of the follow-up. Patients population was found to be heterogeneous; children affected by congenital anomalies (Hirschsprung's disease, anorectal malformations and spinal defects) and children presented with functional constipation underwent neuromodulation therapy and their outcomes were reported together. This did not allow us to have a clear vision of the results on these specific

types of congenital anomalies. Children underwent previous surgery for correction of congenital anomalies should be accurately evaluated to exclude any complication related to the previous surgery prior to be considered suitable candidate for neuromodulation.

Using neuromodulation in anorectal malformations patient with a mislocated anus would be inappropriate. Neuromodulation enhances the current anatomy, and if this is not properly reconstructed, then an accurate revision of the possible surgical complications would be required prior to considering neuromodulation therapy.

The length of the follow-up was limited. It is important to consider how a longer term follow-up will be able to provide more information regarding the compliance of the patient, proposed duration of therapy and the sustainability of benefit of the neuromodulation after it is discontinued. It also seems important to highlight that the majority of the published papers on the use of IF therapy have been published from the experience of a single center. Probably in the future, by the evaluation of other centers experience, it will be easier to have a better understanding on the results and the outcomes of IF therapy applications.

It will be then possible to consider neuromodulation as an established therapy for the management of constipation and fecal incontinence refractory to medical management. In our center, we plan a pilot study on the use of IF therapy in children with chronic constipation/fecal incontinence refractory to medical management as a potential step below transanal irrigation in their pyramid of care.

## Conclusion

By the evaluation of the published literature, we can conclude that neuromodulation is a promising tool in the treatment of fecal incontinence and constipation in children. The reported results, from both invasive and noninvasive techniques, are encouraging in terms of improvement in constipation symptoms including defecation frequency and abdominal pain, reflecting also an improved quality of life for both children and their families. The incontinence symptoms seem also to benefit from neuromodulation therapy. There are, however, a high rate of complications following the ISNS when compared with the noninvasive techniques. The longer-term benefits and sustainability of the benefits of noninvasive techniques remain unanswered and would require further evaluation to consider it as an established therapy for the management of constipation refractory to treatment and fecal incontinence.

## Conflict of Interest

None declared.

## References

- 1 Malone PS, Ransley PG, Kiely EM. Preliminary report: the antegrade continence enema. *Lancet* 1990;336(8725):1217–1218
- 2 NICE. Constipation in children and young people. Diagnosis and management of idiopathic childhood constipation in primary and secondary care. 2015. Available at: <https://www.nice.org.uk/Guidance/CG99>. Accessed December 24, 2018



- 3 Corbett P, Denny A, Dick K, Malone PS, Griffin S, Stanton MP. Peristeen integrated transanal irrigation system successfully treats faecal incontinence in children. *J Pediatr Urol* 2014;10(02):219–222
- 4 Moher D, Liberati A, Tetzlaff J, Altman DG; PRISMA Group. Preferred reporting items for systematic reviews and meta-analyses: the PRISMA statement. *Ann Intern Med* 2009;151(04):264–269
- 5 Shih DQ, Kwan LY. All roads lead to Rome: update on Rome III Criteria and new treatment options. *Gastroenterol Rep (Oxf)* 2007;1(02):56–65
- 6 van Wunnik BP, Peeters B, Govaert B, Nieman FH, Benninga MA, Baeten CG. Sacral neuromodulation therapy: a promising treatment for adolescents with refractory functional constipation. *Dis Colon Rectum* 2012;55(03):278–285
- 7 Dwyer ME, Vandersteen DR, Hollatz P, Reinberg YE. Sacral neuromodulation for the dysfunctional elimination syndrome: a 10-year single-center experience with 105 consecutive children. *Urology* 2014;84(04):911–917
- 8 Lu PL, Koppen IJN, Orsagh-Yentis DK, et al. Sacral nerve stimulation for constipation and fecal incontinence in children: long-term outcomes, patient benefit, and parent satisfaction. *Neurogastroenterol Motil* 2018;30(02). Doi: 10.1111/nmo.13184
- 9 Janssen PTJ, Meyer YM, Van Kuijk SMJ, et al. Long-term outcome of intractable constipation treated by sacral neuromodulation: a comparison between children and adults. *Colorectal Dis* 2018;20(02):134–143
- 10 Haddad M, Besson R, Aubert D, et al. Sacral neuromodulation in children with urinary and fecal incontinence: a multicenter, open label, randomized, crossover study. *J Urol* 2010;184(02):696–701
- 11 Sulkowski JP, Nacion KM, Deans KJ, et al. Sacral nerve stimulation: a promising therapy for fecal and urinary incontinence and constipation in children. *J Pediatr Surg* 2015;50(10):1644–1647
- 12 van der Wilt AA, van Wunnik BP, Sturkenboom R, et al. Sacral neuromodulation in children and adolescents with chronic constipation refractory to conservative treatment. *Int J Colorectal Dis* 2016;31(08):1459–1466
- 13 Lecompte JF, Hery G, Guys JM, Louis-Borrione C. Evaluation of transcutaneous electrical posterior tibial nerve stimulation for the treatment of fecal and urinary leaks in children: preliminary results. *J Pediatr Surg* 2015;50(04):630–633
- 14 Jorge JM, Wexner SD. Etiology and management of fecal incontinence. *Dis Colon Rectum* 1993;36(01):77–97
- 15 Veiga ML, Lordêlo P, Farias T, Barroso U Jr. Evaluation of constipation after parasacral transcutaneous electrical nerve stimulation in children with lower urinary tract dysfunction—a pilot study. *J Pediatr Urol* 2013;9(05):622–626
- 16 Lordêlo P, Teles A, Veiga ML, Correia LC, Barroso U Jr. Transcutaneous electrical nerve stimulation in children with overactive bladder: a randomized clinical trial. *J Urol* 2010;184(02):683–689
- 17 Lewis SJ, Heaton KW. Stool form scale as a useful guide to intestinal transit time. *Scand J Gastroenterol* 1997;32(09):920–924
- 18 Kajbafzadeh AM, Sharifi-Rad L, Nejat F, Kajbafzadeh M, Talaei HR. Transcutaneous interferential electrical stimulation for management of neurogenic bowel dysfunction in children with myelomeningocele. *Int J Colorectal Dis* 2012;27(04):453–458
- 19 Osatakul S, Puetpaiboon A. Use of Rome II versus Rome III criteria for diagnosis of functional constipation in young children. *Pediatr Int* 2014;56(01):83–88
- 20 Benninga M, Candy DC, Catto-Smith AG, et al. The Paris Consensus on childhood constipation terminology (PACCT) group. *J Pediatr Gastroenterol Nutr* 2005;40(03):273–275
- 21 Yik YI, Clarke MCC, Catto-Smith AG, et al. Slow-transit constipation with concurrent upper gastrointestinal dysmotility and its response to transcutaneous electrical stimulation. *Pediatr Surg Int* 2011;27(07):705–711
- 22 Yik YI, Ismail KA, Hutson JM, Southwell BR. Home transcutaneous electrical stimulation to treat children with slow-transit constipation. *J Pediatr Surg* 2012;47(06):1285–1290
- 23 Yik YI, Stathopoulos L, Hutson JM, Southwell BR. Home transcutaneous electrical stimulation therapy to treat children with anorectal retention: a pilot study. *Neuromodulation* 2016;19(05):515–521
- 24 Singh H, Uhlmann J, Khatun M, Connor F. Lumbosacral transcutaneous electrical stimulation in children with slow transit constipation: A pilot case series. *J Hepatol Gastroenterol* 2017;2(01):1–6
- 25 van Wunnik BP, Baeten CGMI, Southwell BR. Neuromodulation for constipation: sacral and transcutaneous stimulation. *Best Pract Res Clin Gastroenterol* 2011;25(01):181–191
- 26 Oerlemans DJ, van Kerrebroeck PE. Sacral nerve stimulation for neuromodulation of the lower urinary tract. *NeuroUrol Urodyn* 2008;27(01):28–33
- 27 Mayer RD, Howard FM. Sacral nerve stimulation: neuromodulation for voiding dysfunction and pain. *Neurotherapeutics* 2008;5(01):107–113
- 28 Matzel KE, Stadelmaier U, Hohenfellner M, Gall FP. Electrical stimulation of sacral spinal nerves for treatment of faecal incontinence. *Lancet* 1995;346(8983):1124–1127
- 29 Leroi AM, Parc Y, Lehur PA, et al; Study Group. Efficacy of sacral nerve stimulation for fecal incontinence: results of a multicenter double-blind crossover study. *Ann Surg* 2005;242(05):662–669
- 30 Binnie NR, Smith AN, Creasey GH, Edmond P. Constipation associated with chronic spinal cord injury: the effect of pelvic parasympathetic stimulation by the Brindley stimulator. *Paraplegia* 1991;29(07):463–469
- 31 Varma JS, Binnie N, Smith AN, Creasey GH, Edmond P. Differential effects of sacral anterior root stimulation on anal sphincter and colorectal motility in spinally injured man. *Br J Surg* 1986;73(06):478–482
- 32 Biemans JM, van Balken MR. Efficacy and effectiveness of percutaneous tibial nerve stimulation in the treatment of pelvic organ disorders: a systematic review. *Neuromodulation* 2013;16(01):25–33
- 33 Queralto M, Portier G, Cabarrot PH, et al. Preliminary results of peripheral transcutaneous neuromodulation in the treatment of idiopathic fecal incontinence. *Int J Colorectal Dis* 2006;21(07):670–672
- 34 Amarenco G, Ismael SS, Even-Schneider A, et al. Urodynamic effect of acute transcutaneous posterior tibial nerve stimulation in overactive bladder. *J Urol* 2003;169(06):2210–2215
- 35 Chase J, Robertson VJ, Southwell B, Hutson J, Gibb S. Pilot study using transcutaneous electrical stimulation (interferential current) to treat chronic treatment-resistant constipation and soiling in children. *J Gastroenterol Hepatol* 2005;20(07):1054–1061
- 36 Clarke MC, Chase JW, Gibb S, et al. Decreased colonic transit time after transcutaneous interferential electrical stimulation in children with slow transit constipation. *J Pediatr Surg* 2009;44(02):408–412
- 37 Leong LC, Yik YI, Catto-Smith AG, Robertson VJ, Hutson JM, Southwell BR. Long-term effects of transabdominal electrical stimulation in treating children with slow-transit constipation. *J Pediatr Surg* 2011;46(12):2309–2312
- 38 Ismail KA, Chase J, Gibb S, et al. Daily transabdominal electrical stimulation at home increased defecation in children with slow-transit constipation: a pilot study. *J Pediatr Surg* 2009;44(12):2388–2392
- 39 Moore JS, Gibson PR, Burgell RE. Neuromodulation via interferential electrical stimulation as a novel therapy in gastrointestinal motility disorders. *J Neurogastroenterol Motil* 2018;24(01):19–29
- 40 Southwell BR, Yik YI, Tan A, et al. Transcutaneous electrical stimulation over the belly in slow-transit constipation. In: Nunez R, Fabbro MA, eds. *Constipation in children: diagnosis and treatment*. Happaase: Nova Science Publishers Inc.; 2013
- 41 Brierley SM, Linden DR. Neuroplasticity and dysfunction after gastrointestinal inflammation. *Nat Rev Gastroenterol Hepatol* 2014;11(10):611–627
- 42 Van Poppel H, Ketelaer P, Van DeWeerd A. Interferential therapy for detrusor hyperreflexia in multiple sclerosis. *Urology* 1985;25(06):607–612