Published online: 2019-04-09

Practical Aspects and Avoidance of Complications in Microendoscopic Spine Surgeries: A Review

Yad Ram Yadav[1] Angelo Lucano[2] Shailendra Ratre[1] Vijay Singh Parihar[1]

[1] Department of Neurosurgery, NSCB Medical College and Hospital, Jabalpur, Madhya Pradesh, India
[2] Department of Neurosurgery, Hospital S. Croce and Carle Cuneo, Carle Cuneo, Italy

Address for correspondence Yad Ram Yadav, Department of Neurosurgery, NSCB Medical College and Hospital, 105 Nehru Nagar Opposite Medical College, Jabalpur, MP 482003 India (e-mail: yadavyr@yahoo.co.in).

J Neurol Surg A 2019;80:291–301.

Abstract

Introduction Although the indications for endoscopic procedures have increased in recent times, there are also some limitations. This review discusses the practical points to prevent and treat complications in microendoscopic spine surgery.

Material and Methods A literature search was conducted for the relevant articles after a topic search on PubMed, Google Scholar, and Medline. The review is based on the experience of 1,574 spinal endoscopic procedures performed by the senior author.

Results Advantages of endoscopic surgery include better visualization, panoramic vision, and the ability to work around corners. Limitations with endoscopic procedures include proximal blind areas, obstruction in instrument handling due to a narrow corridor, disorientation, frequent lens fogging, loss of depth perception, and difficulty in achieving hemostasis, leading to complications and longer operative time during the learning curve.

Conclusion Surgeons need to learn endoscopic skills in addition to microsurgical ones to perform microendoscopic procedures properly. Attending live workshops, watching operative videos, visiting various departments, watching an experienced and accomplished endoscopic surgeon, proper case selection, a multidisciplinary team approach, practicing on models, hands-on cadaveric workshops, laboratory training, and simulators can improve results and shorten the learning curve.

Keywords
- complication
- endoscopic surgical procedure
- minimal invasive
- procedure
- neuroendoscopy
- training program

Introduction

The indications for endoscopic surgeries have increased for various cranial and spinal problems such as atlantoaxial dislocation,[1] lumbar disk,[2–4] colloid cyst,[5] cerebellopontine angle epidermoid,[6] Arnold-Chiari malformation,[7] craniopharyngioma,[8] hydrocephalus,[9] deep-seated brain tumors,[10] trigeminal neuralgia and hemifacial spasm,[11,12] and arachnoid cyst.[13] Endoscopic techniques have many advantages such as good visualization, a panoramic view, and minimal invasiveness leading to less pain and early return to work. Although microendoscopic spine techniques have many advantages, there are also some obstacles that should be recognized and avoided for developing good endoscopic skills and reducing complications.[14–18]

This article discusses the practical aspects of microendoscopic techniques and reviews ways to avoid complications in spine surgeries. We also suggest how to manage complications based on the personal experience of 1,574 endoscopic spinal procedures (►**Table 1**) performed by the senior author and a review of relevant literature. Topic search was conducted on PubMed, Google Scholar, and Medline using terms

received
May 24, 2018
accepted after revision
November 19, 2018
published online
April 9, 2019

© 2019 Georg Thieme Verlag KG Stuttgart · New York

DOI https://doi.org/10.1055/s-0039-1677825.
ISSN 2193-6315.

This document was downloaded for personal use only. Unauthorized distribution is strictly prohibited.

Table 1 Surgical spinal procedures and related complications or problems

Endoscopic spine surgeries	Complications or problems during surgery, no. of patients (%)
Lumbar disk ($n = 970$)	Minor dural punctures: 12 (1.2) Facet injury: 5 (0.5) Postoperative diskitis: 5 (0.5) Recurrence: 4 (0.4) Persistent paresthesia: 3 (0.3) Root prolapse: 2 (0.2) Root injury: 2 (0.2) Conversion to open surgery: 2 (0.2)
Lumbar canal stenosis ($n = 87$)	Minor dural punctures: 5 (5.7) Persistent paresthesia: 3 (3.4) Facet injury: 2 (2.3) Root prolapse: 1 (1.1) Postoperative diskitis: 1 (1.1) Root injury: 1 (1.1)
Intradural extramedullary spine tumor ($n = 42$)	CSF leak: 1 (2.4) Difficulty in dural repair: all patients (100)
Anterior partial corpectomy for cervical myelopathy ($n = 27$)	Bleeding from epidural vessels: 7 (25.6) Blind area and difficulty in bimanual dissection in limited space: 27 (100)
Transcervical approach for atlantoaxial dislocation ($n = 23$)	Difficulty due to oblique angle: 3 (13.0)
Transoral approach for atlantoaxial dislocation ($n = 68$)	CSF leak: 1 (1.5)
Anterior approach for cervical disk ($n = 222$)	Minor bleeding from epidural vessels: 16 (7.2) Transient difficulty in swallowing: 2 (0.9) Incomplete decompression: 2 (0.9) Esophageal injury: 1 (0.5) Temporary C5 root paresis: 1 (0.5) Temporary hoarseness of voice: 1 (0.5)
Posterior cervical approach for multilevel compression ($n = 91$)	Minor bleedings from epidural vessels: 5 (5.5) Minor dural tear: 2 (5.5) C5 root injury: 2 (5.5)
Arnold-Chiari malformation withor without syringomyelia ($n = 31$)	CSF leak: 1 (3.2) Hydrocephalus: 1 (3.2)
Posterior cervical approach for facet hypertrophy ($n = 13$)	Minor bleeding: 2 (15.4)

Abbreviation: CSF, cerebrospinal fluid.

"neuroendoscopy," "complications and neuroendoscopy," "neuroendoscopy and complication avoidance," "complication avoidance and endoscopy," "endoscopic neurosurgery," and "minimally invasive neurosurgery." Full texts of the relevant articles were analyzed after study of the abstracts and/or topics.

General Principles in Microendoscopic Spine Surgery

The abdomen should be free to avoid venous bleeding. Light cable, suction tube, and camera cable should be properly tied so they do not come into the field during the surgery.[16] The endoscope can be damaged due to poor handling during surgery or by a running drill that can be avoided by shielding it with a sheath. The endoscope should be held from the eyepiece side. The endoscope can be damaged by lifting it from the tip side, especially when it is attached to a camera. The endoscope should be stationed at the corner and as far away as possible from the surgical target to avoid an obstruction in instrument manipulation. The endoscope should be retracted when an instrument is introduced to avoid accidental injury to the structures.[17] The side rail of the table, where the endoscope holder is attached, should not be loose.[17] Instruments should fit properly in the working channel of the endoscopic system.

The tissue to be removed should be moved to the sides (cranial, caudal, medial, or lateral).[17] It should not be pulled toward the endoscope tip to avoid soiling of the lens tip and blinding of vital structures (such as nerve, vessel, dura mater, etc.) in the bed of the tissue.[17]

Proper Endoscopic Instruments

There should be a proper selection of instruments. A slender instrument with a single limb is better because it occupies less space.[15,17,18] Proper functioning of the instruments should be checked (e.g., scissor should open smoothly without any jerking) before surgery.[15,17] Instrument tip should be slightly curved to allow better visualization.[15,17,18] Round shaft instruments are preferred rather than flat ones.[17,18] Instruments with a precision grip are preferred compared with a power grip for better control in microendoscopic surgery.[16–18] Straight instruments are preferred to a bayonet shape.[17,18] The proper length of an instrument (preferably as short a length as possible) is better for precision.[16] Dual-use instruments that, for example, can perform suction and coagulation, or suction and irrigation, or drilling and irrigation simultaneously can be very helpful in difficult situations like working in a narrow space.[17,18]

Bimanual Dissection

Bimanual surgical techniques are better than one-handed procedures. Bimanual dissection makes tissue dissection, retraction, drilling, achieving hemostasis, and cutting easier. These bimanual techniques are hard to achieve in some situations such as when the surgeon is holding the endoscope or when there is only one working channel in the endoscopic set.[15,17,18] The surgeon can use an endoscope holder or ask the assistant to hold the endoscope to circumvent this limitation.

Proper Adjustment of the Operative Table Height and Use of a Platform

Although height adjustment is possible in most tables, use of a platform can be complementary.[16–18] Proper height adjustment

This document was downloaded for personal use only. Unauthorized distribution is strictly prohibited.

allows surgery to be performed without shoulder abduction that can cause fatigue and physiologic tremors during surgery.[16–18] Use of a platform or a lower position of the table also allows observation of the operative area and permits introduction of the instrument in the blind area when an endoscope holder is used.[17]

Differences between Endoscopic and Microsurgical Techniques

Endoscopy has advantages such as better illumination, small incision, and improved visualization, especially in the corners; however, there are some difficulties associated with it compared with microscopy.[15] Straight instruments are preferred in endoscopic technique compared with the bayonet shape in a microscopic one.[17] There may be an obstruction in instrument manipulation when the endoscope is placed at the center. In such situations, the surgical field is kept in the corner in the endoscopic procedure, whereas it is in the center in microscopic surgery.[17] There is a need to create extra space to station an endoscope in an already limited surgical space in microendoscopic surgery, whereas in microscopic surgery, the whole space is available for manipulation of the instrument.[17] Other limitations of endoscopic surgery compared with microscopic ones include a blind area (space proximal to lens tip) and a possibility of disorientation due to accidental rotation of the camera.[15–17] The surgeon should learn to overcome these difficulties for a better clinical outcome in endoscopic procedures.

Magnification

High magnification is preferred in most endoscopic surgeries for better visualization.[16,17] Lower magnification is required for an overview of anatomy and orientation.[16] This can be achieved by using the zoom function or by moving the scope away from the area of interest. The anatomy should be identified first by inspecting the surrounding structures (medial, lateral, anterior, and posterior relations) before starting the procedure. Proper knowledge of anatomy is very important because most of the time only a small portion of a structure is seen.[15] Neuronavigation facility[15,16] could be useful, especially when the landmarks are not properly visualized, such as in a repeat surgery.

Orientation and Position of the Camera

Camera orientation should be checked by anterior, posterior, and side-to-side movements before the procedure.[15,16] Camera head (buttons) should be toward the monitor so the image orientation is the same as seen in open surgery.[17] The camera can rotate during surgery causing disorientation and should be checked frequently for proper orientation throughout the surgery.

Straight versus Triangular Arrangement

Visualization of the surgical target and instruments is good when there is a triangular arrangement.[15–17] Distal instrument or surgical tissue is not seen when there is a straight arrangement, which can be avoided by some sideways movement of the instrument and/or the endoscope (►**Fig. 1**).[17] There can be many such situations during the surgery. We use two examples to explain the practical utility of this point. The distal limb of the biopsy forceps (the limb away from the endoscope) and the surgical target tissue are not visualized when these are in a straight line (►**Fig. 2**). Rotation of the forceps allows good visualization of both the limbs and the target tissue (►**Fig. 2**).[16] Likewise, the cutting part of the foot plate of the Kerrison punch (►**Fig. 3a**) and the part of the lamina (►**Fig. 3c**) are not visualized if these three structures —cutting part of foot plate (A), the part of the foot plate attached to the shaft of the Kerrison punch (B), and the lamina (C)—are in a straight line (►**Fig. 3**, lower image).

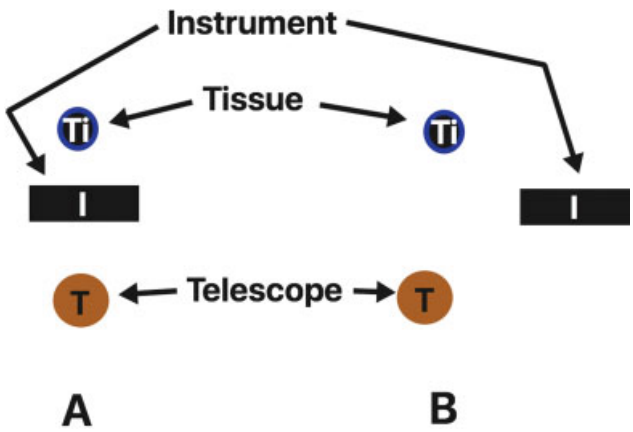

Fig. 1 (**a**) Distal tissue is not seen when there is a straight arrangement. (**b**) Some movement of the instrument and/or an endoscope allows good visualization for the instrument and the tissue.

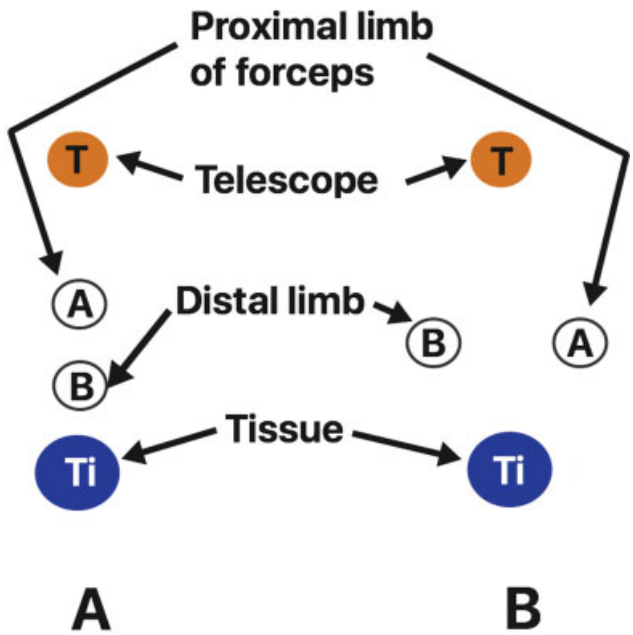

Fig. 2 (**a**) The distal limb of the forceps and the tissue are not seen due to the straight arrangement. (**b**) Rotation of the forceps allows good visualization of both the limbs and the target tissue.

This document was downloaded for personal use only. Unauthorized distribution is strictly prohibited.

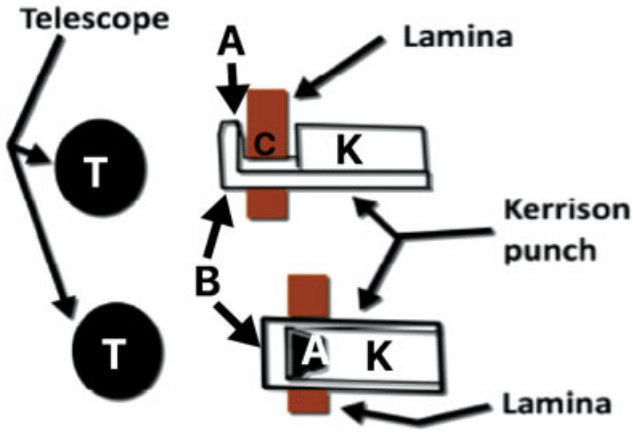

Fig. 3 The foot plate of the Kerrison punch has two parts: (A) free end and (B) part attached to the shaft. The arrangement shown at the top allows good visualization of both parts of the punch and the lamina. Rotation of punch as shown at the bottom does not permit visualization of the free end (a part: cutting part of the Kerrison punch) and the part of the lamina (C) due to the straight line arrangement.

Rotation of the Kerrison punch allows good visualization of the biting part and the lamina (►**Fig. 3**, upper image).

Proper Planning of the Size and Site of an Incision

Proper size of the incision should be planned at the beginning of the surgery.[17] A large incision has a disadvantage in spine endoscopic surgery, especially when performed without an endoscope holder.[17] Proper size of an incision keeps the system snugly fit and stable even when it is unsupported, and it also helps reduce oozing by the tamponade effect of the tubular retractor.[17] The site of an incision should be planned properly.[17] The trajectory should be in such a way that the angle of approach is perpendicular to the surgical target. If there is excessive angulation, soft tissues tend to protrude inside the retractor causing difficulty in surgery. The second option (microscope) should be ready if it is difficult to perform endoscopic surgery.[17]

Proper Position of the Endoscope

Proper position of the endoscope is essential to prevent obstruction in the instrument movements.[15] The endoscope needs to be placed as far away as possible and at the corner of the operative field to prevent obstruction in instrument handling.[15,17] It is desirable to make a triangular arrangement between the scope, the surgical target, and the instrument, as explained earlier.[15] When a straight arrangement cannot be avoided (in a narrow and deep space) (►**Figs. 4** and **5**), such as in partial corpectomy for cervical myelopathy,[19] the distal instrument is not visualized. In such a situation the distally intended instrument (suction in the top line of ►**Fig. 5**) cannot be introduced due to nonvisualization caused by the presence of the Kerrison punch between the endoscope and the suction. In such settings, the distal instrument (suction) should be introduced first (middle line of ►**Fig. 5**), should consciously be kept at that depth in the blind area, and followed by an introduction of the Kerrison punch in between the suction and the endoscope (►**Fig. 5** the bottom line). Using this trick, one can continue to remove bone in the oozing field even when all three instruments are in a straight line (►**Fig. 5**). As another option, the endoscope can be placed in the center and the instruments (the Kerrison punch and the suction) can be passed from either side of the scope (►**Fig. 6**).

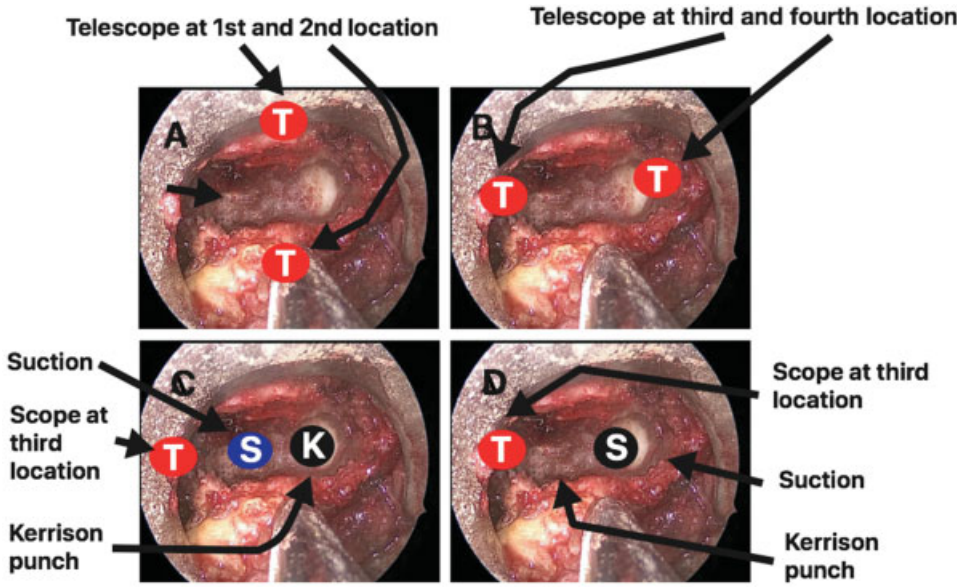

Fig. 4 Visualization at the bottom of the partial corpectomy is not possible when the endoscope is in the first or second locations (A). It is better when an endoscope is placed at the third or fourth positions (B). It is not possible to introduce the Kerrison punch (K) due to nonvisualization when suction (S) is already placed between the endoscope (T) and the punch (C). Suction (S) should first be introduced at a more distal site in the operative field, and the Kerrison punch should be advanced after that (D).

This document was downloaded for personal use only. Unauthorized distribution is strictly prohibited.

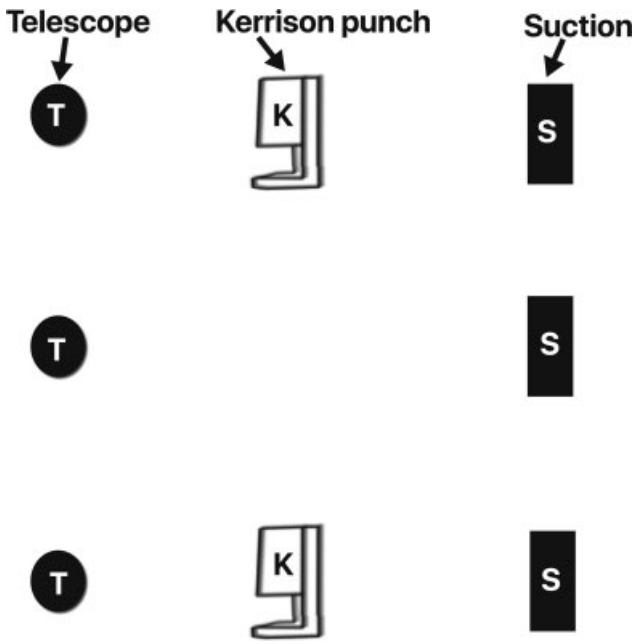

Fig. 5 Suction (S) could not be introduced due to nonvisualization when the Kerrison punch (K) is between the endoscope (T) and the suction (top line). In such a situation, the suction should be introduced first and placed at a distal location under proper visualization (middle line), followed by the introduction of the Kerrison punch between the suction and the endoscope (bottom line). The surgeon should consciously keep the suction at that depth in the blind area.

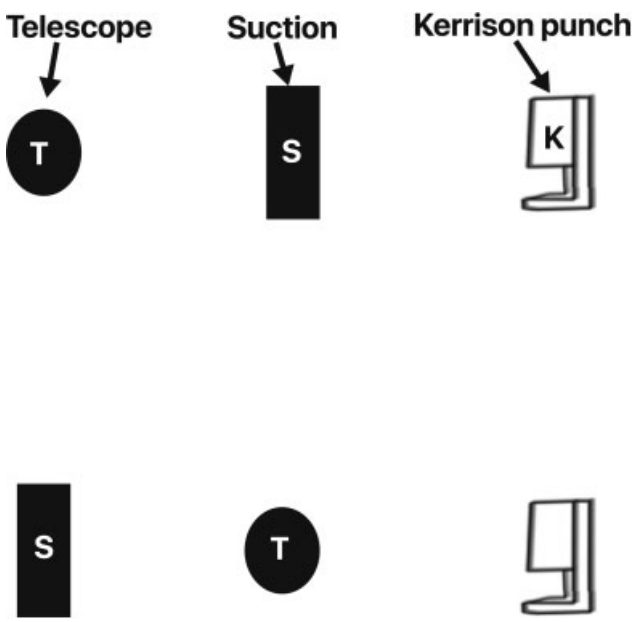

Fig. 6 The distal instrument (Kerrison punch [K]) will not be visualized when suction (S) is placed between the punch and the endoscope (top line). The endoscope (T) should be placed in the center so that both the Kerrison punch and suction can be well visualized (bottom line).

Hand Support

Hands should be properly supported during surgery for good precision.[15] An unsupported hand can increase physiologic tremors and could give rise to fatigue, especially during a long surgery.[15–17] Routine hand support devices used in microsurgery may not be suitable for microendoscopic operations. Gentle hand support on the endoscopic sheath or surrounding structures can be a great help.[15,17]

Use of Precision Grip and Avoidance of Power Grip

Precision grip is preferred over power grip in endoscopic surgery.[16,17] There is no hand support in a power grip, and there is involvement of long muscles and multiple joints that results in less precision.[17] Precision grip permits hand support and use of intrinsic muscles of the thumb and index finger that helps in controlled movements during the surgery.[16,17] It is reasonable to have a power grip in a Kerrison punch because the desired function of this instrument needs power. But some instruments are poorly designed, unfortunately, and they are too long for a power grip design, for example, fine scissors. If the power grip is unavoidable, the precision grip should be added with the other hand.[16–18,20] A quiet hand technique should be used where the ulnar side of the hand is well supported.[18] The muscles of the arm should be quiet with the least number of motor units of thumb and index finger in use.[18]

Poor Visualization during Microendoscopic Surgery and How to Overcome This Limitation

Poor vision in endoscopic surgery could be due to lens staining by blood, bone dust, fluid, or any tissue (►**Table 2**).[15,16] For example, high humidity in the air medium, a damaged endoscope, and an out-of-focus camera can be responsible for poor image quality.[17] Povidone-iodine scrub and Savlon (GlaxoSmithKline, Mumbai, India) are very effective anti-fogging agents. The lens tip can be cleaned by the mechanical method or by using various commercially available lens cleaners that clean the endoscope tip quickly without causing any interruption in the procedure. The Clearvision II system from Karl Storz (Tuttlingen, Germany) and InstaClear lens cleaner from Olympus are a few examples. The lens cleaner sheath attached on the endoscope can be easily autoclaved. Saline irrigation and removal of liquid drops from the lens tip by the suction is also an effective manual cleaning technique. An improper connection from the endoscope to the monitor may be responsible for poor image quality.[17] The endoscope should be directed toward the area of interest. For example, if the surgical field is toward the cranial side of the operative field, the endoscope should be angulated cranially.[17]

The sword-fighting effect (the instrument is pointing in one direction and the endoscope in the opposite direction) can lead to poor image quality and instrument collision and should be avoided.[17] The straight arrangement of the endoscope, instruments, and the target tissue should be avoided as explained earlier.[15]

Unwanted tissue in front of the endoscope lens can impair proper visualization. Slight withdrawal of the endoscope away from the obstructive tissue, retraction or removal of the obstructing tissue, suctioning of humid air, and proper focusing can improve visualization.[15,17]

This document was downloaded for personal use only. Unauthorized distribution is strictly prohibited.

Table 2 Causes of poor visualization and steps to improve it

Causes of poor visualization	How to improve visualization
Blood, bone dust, drop of fluid, and tissue staining the lens tip	1. Anti-fogging agents, commercially available lens cleaner, or manual irrigation by saline and suction 2. Bone dust staining of lens can be avoided by keeping endoscope as far away as possible, using comparatively larger size endoscope and by zooming 3. Intermittent irrigation in between the short period of drilling
Improper connection from endoscope to the monitor and damaged lens	Proper connection; protect endoscope by sheath
Endoscope out of focus	Proper focusing
Unwanted tissue in front of the endoscope lens	Remove or retract tissue; move endoscope
Excessive moisture content in the air medium	Suction of humid air
Straight arrangement	Triangular arrangement
Endoscope in wrong (opposite) direction	Direction of the endoscope toward the object
Difficulty in visualization of the instrument tip	Use angled-tip instrument or introduce instrument at some angle
Pulling tissue toward the endoscope	Move tissue to the side (cranial, caudal, medial, or lateral). Do not pull toward the endoscope
Disorientation due to the camera rotation during the surgery	Keep checking the orientation during the surgery
Bleeding	1. Prevent bleeding 2. Avoid large and vascular lesions 3. Working in air media is better for visualization of bleeding point and for cauterization

Frequent soiling of the lens tip can be partly prevented by using a comparatively larger diameter endoscope with a longer focal length. A large-diameter endoscope with a longer focal length (10-mm diameter endoscope with 5-cm focal length) can permit placement of the endoscope away from the drilling site, for example in the transoral removal of the odontoid process.[17] Intermittent irrigation in between the short periods of drilling and using lower revolutions (~ 50,000 RPM) can be helpful in avoiding lens soiling.[17]

Limited Space for Instrument Manipulation

Instrument manipulations can be difficult because some space is utilized by the endoscope in an already narrow area.[18] The endoscope itself can obstruct instrument handling in microendoscopic surgery (►**Table 3**).[21] Utilization of slender shaft instruments is better because such devices occupy less space.[13,15,16] Instrument handling during surgery can be difficult when the endoscope is close to the surgical target.[15] The endoscope and instruments should be

Table 3 Various causes of instrument obstructions and steps to overcome limitations

Various causes of instrument obstructions	Steps to overcome limitations
Endoscope tip or side can obstruct: endoscope too close to the target in the anteroposterior direction (depth)	Keep endoscope as far away as possible; zoom for better visualization
Endoscope in center of the field	Endoscope placement at corner; use angled endoscope
Sword effect (direction of endoscope and instrument in opposite side)	Endoscope and instruments should be angulated in same direction
Thick and straight instruments	Slender and angled-tip instruments
Requirement of more number of instruments such as in cases of bleeding	Two functions can be incorporated into one instrument such as suction and bipolar coagulation, suction and irrigation, drilling and irrigation
Limited space	Use slender and single-shaft instruments
If nothing works: unable to bring instrument at the surgical target	Use angled-tip instruments Withdraw endoscope, take instrument to the desired place, and then move endoscope toward the object slowly

This document was downloaded for personal use only. Unauthorized distribution is strictly prohibited.

pointed in the same direction to avoid sword fighting, which will help use the limited space adequately.

Suturing is difficult in microendoscopy due to the narrow space, and to circumvent this, a rotation maneuver can be performed.[20] It is sometimes difficult to introduce the instrument in a limited space even after stationing an endoscope at the corner of an operative corridor and also after keeping the endoscope as far away as possible from the surgical target. In such a situation, the instrument should be advanced first toward the required target, and then the endoscope should follow in the available space.[17] The angled-tip instrument is better to reach to the extreme corner of the operative field as compared with the straight tip tool.[17]

Endoscopic Blind Spot

Although there are advantages such as better visualization and panoramic view in endoscopic surgery, it also has a limitation due to an inability to see the pathway proximal to the endoscope tip.[15] There is a danger that the instruments or the side of the endoscope can damage structures in the blind area (►**Table 4**).[15] Endoscopic surgeons should train themselves to remove an endoscope with the insertion of each new instrument.[17] This problem can be handled by visualization of the instrument directly by the naked eye in the blind area until it appears in the endoscopic view.[13,15,21]

Control of Bleeding

Control of bleeding can be a challenge, especially in a fluid media in which small amounts of blood can disturb proper visualization.[17] It is better to use the tamponade effect to control bleeding, using gentle pressure on the hemorrhagic point by the instrument that is already there in the field and avoiding removal of the existing tool and bringing the cautery forceps.[15] Copious irrigation and intermittent blocking of irrigation fluid allows visualization of the bleeding point and helps achieve hemostasis.[15] Liquid media can be converted into air media (by suctioning of fluid) if it is difficult to see a bleeding point.[17] Visualization of a bleeding point and cauterization of the vessel is comparatively easy in air media. Application of cotton patties can stop bleeding. If nothing works, the endoscope could be taken out, and brisk bleeding can be controlled by a microscope[20] or an exoscope, especially when a tubular retractor is used.

Prevention of Dural Tear

There is an increased risk of a dural tear and cerebrospinal fluid leak while addressing the contralateral compression in severe spinal canal stenosis (►**Table 5**).[15,21,22] Proper case selection helps prevent the dural injury, especially during the initial learning curve, and by keeping the ligamentum flavum intact until all bony work is finished.[22,23] Both 45- and 90-degree Kerrison punches should be used for removal of the cranial and caudal lamina, respectively.[17] Using an eggshell drilling technique is preferred for lamina,[17] and then the thinned-out lamina can be removed.[21] Proper drilling technique should be used. Drilling should be parallel to or away from the dura mater.[18] Use of a dural guard in a drill or bone shaver can avoid injury to the dura mater. Utilization of Abgel (Sri Gopal Krishna Labs Pvt. Ltd., Mumbai, India) or bone wax (no cotton patties) between the lamina and dura helps avoid injury to the dura mater during the drilling.[17]

Stepwise surgery for removal of the lamina by the Kerrison punch should be performed. Steps should involve (1) separation of the dura and nibbling of a small part of the bone, (2) partial retraction of the tip of the Kerrison punch, and (3) final removal of the nibbled piece of the bone (►**Fig. 7**). But if the nibbled bone is removed in a single stroke, the dura may be caught and get injured.

Bone or ligament should be removed under good visualization with the help of a rotation technique. Pulling of the part of the bone or ligament toward the lens tip is not desirable because it prevents proper visualization of the underlying dura that may have been caught in the Kerrison punch bite.[17]

Excision of the opposite-side protruded lumbar disk tissue from the contralateral side can cause dural injury. The protruded disk fragment should be pushed in the disk space (using a 90-degree angled instrument under the dura mater) that can then be removed from the ipsilateral side.[17]

Dural Repair

Dural suturing in a limited area is a formidable task in endoscopic surgery. Rotation of the needle holder is preferred

Table 4 Causes of endoscopic blind spot and nonvisualization

Causes of nonvisualization	Steps to overcome this limitation
Endoscopic blind spot: The pathway between the skin and the endoscope tip is not visualized	• Remove the endoscope with the insertion of each new instrument and follow instrument into the field under direct endoscopic visualization • Visualize instrument directly by the naked eye in the operative field; intermittently look at monitor and the instrument when it is present in the blind area • Avoid side movement, especially when endoscope has passed through a narrow opening
Distal object is not visualized when endoscope and the other objects are in a straight line	• Move endoscope or object/instrument in such a way that the arrangement becomes triangular • Keep endoscope in between the instrument and the surgical target

This document was downloaded for personal use only. Unauthorized distribution is strictly prohibited.

Table 5 Other difficulties along with steps to prevent them

Limitations	Steps to prevent complications
CSF leak: More common in severe canal stenosis, large central or extruded disk, dealing with opposite-side pathology	• Simple case selection in the beginning • Keep ligamentum flavum intact until all bony work is finished • Use 45-degree Kerrison punch for cranial and 90 degrees for caudal work • Partially retract Kerrison punch and hold proximal part of nibbled bone or ligament • Drill away from dura matter or parallel to it • Dura guard, bone shaver • Eggshell drilling technique • Patties, Abgel, bone wax between bone and the dura • Hold bone or ligament under proper visualization using rotation technique of the Kerrison punch
Difficulties in drilling: Frequent soiling of the lens by bone dust or fluid	• Intermittent irrigation in between the short period of drilling and using lower revolutions • Keeping suction near drill • Using comparatively large-diameter endoscope with longer focal length
Causes of steep learning curve: • Control of bleeding • Blind area • Unique endoscopic skills • Two-dimensional vision • More operative time • Limited space control	• Simple case selection in the beginning of the learning curve • Practice on models • Multidisciplinary team approach • Cadaveric dissection • Live operative workshop • Laboratory training • Simulators

over a linear movement because of the constrained space.[20,22] The first knot can be preplaced at the end of the suture to avoid wasting time tying the knot.[22] A loop for suturing can be performed inside the endoscopic field with the help of a needle holder and the suction tip. The loop can also be made outside, which can be carried inside the endoscopic field with the help of the needle holder.[17] Although a specialized endoscopic suturing tool such as the Covidien endo-suturing instrument is available, it is not suitable in the present form in neurosurgery due to its big size.

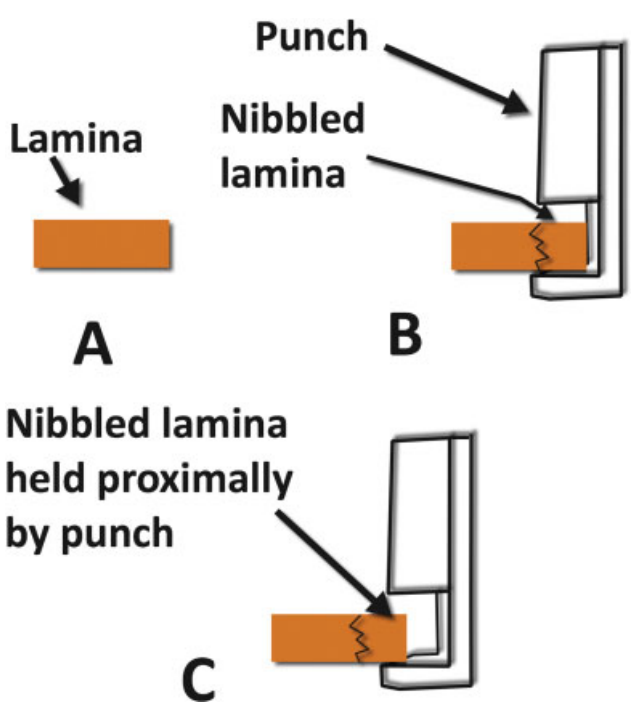

Fig. 7 Steps for removal of the lamina by the Kerrison punch. (A, B) The piece of bone is disconnected from the rest of the lamina. The nibbled piece should be released from the Kerrison punch. (C) Punch should be slightly withdrawn, and then the detached piece should be held from a proximal site and removed.

Drilling

Proper drilling techniques were mentioned earlier. A gentle paintbrush technique should be used without any force. The drill should be removed only when it is fully stopped to prevent injury to the vital structures and the scope.[17]

Learning Curve

Endoscopic surgeries are associated with a steep learning curve.[13,18,21] The views of endoscopic images are often different, leading to confusion when compared with the microscopic technique, especially during the evolution from microscopic to endoscopic procedures. The surgeon needs to acquire special endoscopic skills for the transition from the microscopic procedure to endoscopic ones (►**Table 5**).[15–17] The endoscopic surgeon needs to overcome many obstacles (two-dimensional visualization, more operative time, control of bleeding, difficulty in instrument manipulation in a limited space, problems associated with the blind area, etc.) to perform effective endoscopic surgeries.[15–17]

The learning curve of the transforaminal approach is steep but easy to achieve, whereas for the interlaminar approach it is flat but hard to master.[24] There is usually more operative time, higher technical failures, and increased recurrences in the early part of the learning curve in the endoscopic transforaminal approach.[25] A learning curve of ~ 72 cases was needed to reach 90% good/excellent results in the Morgenstern et al series.[26] The surgeons' training level is an important factor for clinical

This document was downloaded for personal use only. Unauthorized distribution is strictly prohibited.

success in the endoscopic technique. Better clinical results are observed from a well-trained surgeon.[27] Jhala et al observed more technical problems and complications (durotomy or nerve injury) during the first 25 cases of 100 patients.[28] Dural tear ($n = 6$ cases [12%]), facet injury ($n = 2$ cases [4%]), root injury ($n = 1$ case [2%]), and conversion to open surgery ($n = 1$ case [2%]) were more frequent in the initial 50 patients in the Yadav et al series, whereas there was only one dural tear and no facet or root injury in the last 350 cases.[2]

In another study, the learning curve of microendoscopic technique in lumbar canal stenosis was analyzed for a single surgeon.[29] Operative time reduced gradually, and the blood loss was stabilized after 30 surgeries. However, intraoperative complications were observed even after attaining mastery of this technique.[29] In the Kim et al study, the operative time plateaued after 20 and 19 cases for ligament flavum and lamina resection, respectively.[30] In other research, 25 to 30 cases were needed to reach the learning curve in microendoscopic diskectomy (MED).[31] Even during this initial learning period, MED was a safe procedure.[31]

A steady state of the learning curve with respect to operation time was achieved after 40 operations for surgeon 1 and after 16 surgeries for surgeon 2 in the Joswig et al series.[32] Although complications did not negatively affect the long-term outcome in patients who underwent surgery before or after the learning phase, guidance under an experienced surgeon reduced the learning curve.[32] The higher rate of conversions, complications, recurrent lumbar disk herniations, and a steep learning curve should be considered before a surgeon takes up endoscopic spine surgery.[32]

The learning curve can be shortened by using a multidisciplinary team approach, simple case selection in the beginning,[33] cadaveric dissections, practice on models, laboratory training, simulators, and attending live operative workshops.[15,17] The development of a formal program and a peer-review board for endoscopic spine surgery is advisable to achieve the minimum standard and technical skills.[34]

Complications

Overall complications were 3.6% and 13.8% in lumbar disk surgery and lumbar canal stenosis, respectively, in our series. Complications varied from 3.6% to 21% in various series in lumbar disk surgery.[28,31,35] Complications in the MED group (8.1%) were comparable with microdiskectomy (9.8%).[31] The rate of complications, length of hospital stay, return to daily activities, and overall patient satisfaction were comparable in MED and conventional diskectomy in the study by Anichini et al.[36] Overall, 21% of patients developed complications (a significant number were minor ones) in the Jhala et al series. This included open conversion (1%) for suspected root damage, perioperative facet damage (5%), minor dural punctures (7%), recurrence requiring reoperation (3%), persistent paresthesia (1%), and postoperative diskitis (4%).[28] Overall complications were 12.5% in the Kim et al series that included dural tear ($n = 3$ cases [6.2%]), conversion to open surgery ($n = 1$ [2.1%]), and a requirement for transforaminal lumbar interbody fusion after the procedure ($n = 2$ [4.2%]).[35] Surgical indication and experience of the surgeon were crucial factors in determining the ultimate outcome.[36] We suggest a timely conversion to the microscopic procedure to prevent and treat complications especially during the initial learning curve.

Recurrence Rates

Rate of recurrent/residual compression is the most debated topic, and the results are extremely variable. It related to the selection of cases, level of training of the surgeon, and publication bias in the Anichini et al series.[36] The rate of recurrence/residual was higher in MED, compared with the open technique in the initial part of the learning curve.[36] Although the recurrence rate varied from 0.4% to 10% in various series, it was between 2% and 10% in most of the reported series.[36] There were four recurrences (0.4%) in MED in our series. In another large series, two recurrences (0.5%) were observed of 400 treated patients.[2] There were four cases (4%) of recurrence in the Jhala et al series.[28] Of these, three patients (3%) required a reoperation.

On the contrary, a 10% recurrence was reported in 344 patients in the Matsumoto et al series.[37] Kulkarni et al[38] and Sencer et al[39] reported 1.5% and 5% recurrences of a total of 188 and 163 patients, respectively. Joswig et al reported a high recurrence rate of 28% in MED, which they hypothesized was due to the younger age of the patients and longer follow-up.[32] Hsu et al reported a total of 10.5% recurrence or residual disk (recurrent disk in 2/57 cases [3.5%]) and a residual disk in 4 of 57 cases (7%).[24] Choi et al compared transforaminal and interlaminar endoscopic diskectomy and found the recurrence rate to be 3.3% in the former and 6.7% in the latter, although the patient selection was different between them.[40] After attaining adequate experience, most of the microendoscopic series reported comparable recurrence rates with the open ones.[36]

Publication Bias

Publication bias in this review may have occurred if the original literature was compromised by biased publications.[41] Studies are more likely to be published if they have positive findings and can collect more citations for the journal. Publication bias may occur due to poor study design, inconsistency in reporting, and imprecision.[42]

Training in Endoscopic Surgery

Good endoscopic training is needed to prevent complications and for a better clinical outcome. In the beginning, simple cases should be selected to prevent complications.[43] There is usually less opportunity for a young neurosurgeon to get trained in endoscopy during routine operative hours.[17] The surgeon should spend more time in laboratories for training. Learning by cadaveric dissection is best but difficult due to a shortage of cadavers. Models and simulators[44–46] can be good alternatives for training, but these are often very costly. Indigenous and inexpensive models can be used for developing skills like dissection, hand-eye coordination, cutting,

This document was downloaded for personal use only. Unauthorized distribution is strictly prohibited.

and suturing in a limited space.[47,48] Surgical gloves, papaya, silastic tubes, capsicum, low-cost commercially available camera and a LED light source, and a popsicle stick for lamina simulation can be used for endoscopic training.[47] The surgeon can practice endoscopy using simple and inexpensive models.[47] A 0- and 30-degree endoscopic view can be obtained by angulating the camera for training.[48] An exoscope system (video telescopic operating monitor) can also be used as a bridge for learning endoscopy.[49]

Conclusion

The surgeon needs to learn endoscopic skills in addition to the microsurgical ones to prevent complications and for good outcomes. The complications are more in the initial part of the learning curve that can be shortened by attending live workshops, understanding endoscopic anatomy, proper case selection, practicing on cadavers or models, and watching operative videos and experienced surgeons. Timely conversion to the alternative procedure is better to prevent complications, especially during the initial learning curve.

Conflict of Interest
None declared.

References

1 Yadav YR, Madhariya SN, Parihar VS, Namdev H, Bhatele PR. Endoscopic transoral excision of odontoid process in irreducible atlantoaxial dislocation: our experience of 34 patients. J Neurol Surg A Cent Eur Neurosurg 2013;74(03):162–167
2 Yadav YR, Parihar V, Namdev H, Agarwal M, Bhatele PR. Endoscopic interlaminar management of lumbar disc disease. J Neurol Surg A Cent Eur Neurosurg 2013;74(02):77–81
3 Eun SS, Lee SH, Erken HY. Transforaminal percutaneous endoscopic lumbar diskectomy for downmigrated disk herniations: lever-up, rotate, and tilt technique. J Neurol Surg A Cent Eur Neurosurg 2018;79(02):163–168
4 Choi KC, Lee JH, Kim JS, Lee DC, Park CK. Combination of transforaminal and interlaminar percutaneous endoscopic lumbar diskectomy for extensive down-migrated disk herniation. J Neurol Surg A Cent Eur Neurosurg 2018;79(01):60–65
5 Yadav YR, Parihar V, Pande S, Namdev H. Endoscopic management of colloid cysts. J Neurol Surg A Cent Eur Neurosurg 2014;75(05): 376–380
6 Hu Z, Guan F, Kang T, et al. Whole course neuroendoscopic resection of cerebellopontine angle epidermoid cysts. J Neurol Surg A Cent Eur Neurosurg 2016;77(05):381–388
7 Ratre S, Yadav N, Yadav YR, Parihar VS, Bajaj J, Kher Y. Endoscopic management of Arnold-Chiari malformation type 1 with or without syringomyelia. J Neurol Surg A Cent Eur Neurosurg 2018;79 (01):45–51
8 Cagnazzo F, Zoli M, Mazzatenta D, Gompel JJV. Endoscopic and microscopic transsphenoidal surgery of craniopharyngiomas: a systematic review of surgical outcomes over two decades. J Neurol Surg A Cent Eur Neurosurg 2018;79(03):247–256
9 Marx S, El Damaty A, Manwaring J, et al. Endoscopic third ventriculostomy before posterior fossa tumor surgery in adult patients. J Neurol Surg A Cent Eur Neurosurg 2018;79(02):123–129
10 Jackson C, Gallia GL, Chaichana KL. Minimally invasive biopsies of deep-seated brain lesions using tubular retractors under exoscopic visualization. J Neurol Surg A Cent Eur Neurosurg 2017;78 (06):588–594
11 Komatsu F, Imai M, Hirayama A, et al. Endoscopic microvascular decompression with transposition for trigeminal neuralgia and hemifacial spasm: technical note. J Neurol Surg A Cent Eur Neurosurg 2017;78(03):291–295
12 Dubey A, Yadav N, Ratre S, Parihar VS, Yadav YR. Full endoscopic vascular decompression in trigeminal neuralgia: experience of 230 patients. World Neurosurg 2018;113:e612–e617
13 Idris Z, Tan YC, Kandasamy R, Ghani RI, Abdullah JM. Transfrontal transaqueductal, transtrigonal, and suboccipital infratentorial supracerebellar endoscopic fenestration of posterior fossa arachnoid cysts: three surgical cases. J Neurol Surg A Cent Eur Neurosurg 2017;78(02):210–215
14 Chowdhry SA, Cohen AR. Intraventricular neuroendoscopy: complication avoidance and management. World Neurosurg 2013;79 (2, Suppl):15.e1–15.e10
15 Yadav YR, Parihar V, Kher Y. Complication avoidance and its management in endoscopic neurosurgery. Neurol India 2013;61 (03):217–225
16 Yadav YR, Parihar VS, Ratre S, Kher Y. Avoiding complications in endoscopic third ventriculostomy. J Neurol Surg A Cent Eur Neurosurg 2015;76(06):483–494
17 Yadav YR, Bajaj J, Parihar V, Ratre S, Pateriya A. Practical aspects of neuroendoscopic techniques and complication avoidance: a systematic review. Turk Neurosurg 2018;28(03):329–340
18 Yadav YR, Parihar V, Ratre S, Kher Y, Iqbal M. Microneurosurgical skills training. J Neurol Surg A Cent Eur Neurosurg 2016;77(02):146–154
19 Yadav YR, Ratre S, Parihar V, Dubey A, Dubey MN. Endoscopic partial corpectomy using anterior decompression for cervical myelopathy. Neurol India 2018;66(02):444–451
20 Yadav YR, Parihar V, Ratre S, Kher Y. Endoscopic anterior decompression in cervical disc disease. Neurol India 2014;62(04):417–422
21 Yadav YR, Parihar V, Agarwal M, Sherekar S, Bhatele P. Endoscopic vascular decompression of the trigeminal nerve. Minim Invasive Neurosurg 2011;54(03):110–114
22 Parihar VS, Yadav N, Yadav YR, Ratre S, Bajaj J, Kher Y. Endoscopic management of spinal intradural extra-medullary tumors. J Neurol Surg A Cent Eur Neurosurg 2017;78(03):219–226
23 Yadav YR, Parihar V, Ratre S, Kher Y, Bhatele PR. Endoscopic decompression of cervical spondylotic myelopathy using posterior approach. Neurol India 2014;62(06):640–645
24 Hsu HT, Chang SJ, Yang SS, Chai CL. Learning curve of full-endoscopic lumbar discectomy. Eur Spine J 2013;22(04):727–733
25 Ahn SS, Kim SH, Kim DW. Learning curve of percutaneous endoscopic lumbar discectomy based on the period (early vs. late) and technique (in-and-out vs. in-and-out-and-in): a retrospective comparative study. J Korean Neurosurg Soc 2015;58(06):539–546
26 Morgenstern R, Morgenstern C, Yeung AT. The learning curve in foraminal endoscopic discectomy: experience needed to achieve a 90% success rate. SAS J 2007;1(03):100–107
27 Wang H, Huang B, Li C, et al. Learning curve for percutaneous endoscopic lumbar discectomy depending on the surgeon's training level of minimally invasive spine surgery. Clin Neurol Neurosurg 2013;115(10):1987–1991
28 Jhala A, Mistry M. Endoscopic lumbar discectomy: experience of first 100 cases. Indian J Orthop 2010;44(02):184–190
29 Nomura K, Yoshida M. Assessment of the learning curve for microendoscopic decompression surgery for lumbar spinal canal stenosis through an analysis of 480 cases involving a single surgeon. Global Spine J 2017;7(01):54–58
30 Kim E-H, Sihn D-H, Cha J-S, Jae Y-B. Factors affecting learning curve in endoscopic lumbar discectomy using interlaminar approach. J Korean Soc Spine Surg 2006;13(04):311–318
31 Martín-Láez R, Martínez-Agüeros JA, Suárez-Fernández D, Montiaga-Núñez F, Vázquez-Barquero A. Complications of endoscopic microdiscectomy using the EASYGO! system: is there any difference with conventional discectomy during the learning-curve period? Acta Neurochir (Wien) 2012;154(06):1023–1032

This document was downloaded for personal use only. Unauthorized distribution is strictly prohibited.

32 Joswig H, Richter H, Haile SR, Hildebrandt G, Fournier JY. Introducing interlaminar full-endoscopic lumbar diskectomy: a critical analysis of complications, recurrence rates, and outcome in view of two spinal surgeons' learning curves. J Neurol Surg A Cent Eur Neurosurg 2016;77(05):406–415
33 Yeung AT, Roberts A, Shin P, Rivers E, Paterson A. Suggestions for a practical and progressive approach to endoscopic spine surgery training and privileges. J Spine 2018;7:414
34 Yadav YR, Yadav N, Parihar V, Kher Y, Ratre S. Endoscopic posterior decompression of lumbar canal stenosis. Indian J Neurosurg 2013;2:124–130
35 Kim HS, Paudel B, Jang JS, et al. Percutaneous full endoscopic bilateral lumbar decompression of spinal stenosis through uniportal-contralateral approach: techniques and preliminary results. World Neurosurg 2017;103:201–209
36 Anichini G, Landi A, Caporlingua F, et al. Lumbar endoscopic microdiscectomy: where are we now? an updated literature review focused on clinical outcome, complcations, and rate of recurrence. BioMed Res Int 2015;2015:417801
37 Matsumoto M, Watanabe K, Hosogane N, et al. Recurrence of lumbar disc herniation after microendoscopic discectomy. J Neurol Surg A Cent Eur Neurosurg 2013;74(04):222–227
38 Kulkarni AG, Bassi A, Dhruv A. Microendoscopic lumbar discectomy: technique and results of 188 cases. Indian J Orthop 2014;48 (01):81–87
39 Sencer A, Yorukoglu AG, Akcakaya MO, et al. Fully endoscopic interlaminar and transforaminal lumbar discectomy: short-term clinical results of 163 surgically treated patients. World Neurosurg 2014;82(05):884–890
40 Choi KC, Kim JS, Ryu KS, Kang BU, Ahn Y, Lee SH. Percutaneous endoscopic lumbar discectomy for L5-S1 disc herniation: transforaminal versus interlaminar approach. Pain Physician 2013;16 (06):547–556
41 Phan K, Mobbs RJ. Systematic reviews and meta-analyses in spine surgery, neurosurgery and orthopedics: guidelines for the surgeon scientist. J Spine Surg 2015;1(01):19–27
42 Park Y, Seok S-O, Lee S-B, Ha J-W. Minimally invasive lumbar spinal fusion is more effective than open fusion: a meta-analysis. Yonsei Med J 2018;59(04):524–538
43 Dewanngan NK, Yadav YR, Parihar VS, Ratre S, Kher Y, Bhatele P. Extent of decompression of lumbar spinal canal after endoscopic surgery. J Neurol Surg A Cent Eur Neurosurg 2017;78(06): 541–547
44 Indo M, Tsutsumi K, Shin M. The practice of knots untying technique using a 10-0 nylon suture and gauze to cope with technical difficulties of microvascular anastomosis. World Neurosurg 2011;75(01):87–89
45 Gasco J, Patel A, Luciano C, et al. A novel virtual reality simulation for hemostasis in a brain surgical cavity: perceived utility for visuomotor skills in current and aspiring neurosurgery residents. World Neurosurg 2013;80(06):732–737
46 Choudhury N, Gélinas-Phaneuf N, Delorme S, Del Maestro R. Fundamentals of neurosurgery: virtual reality tasks for training and evaluation of technical skills. World Neurosurg 2013;80(05): e9–e19
47 Bajaj J, Yadav YR, Pateriya A, Parihar V, Ratre S, Dubey A. Indigenous inexpensive practice models for skill development in neuroendoscopy. J Neurosci Rural Pract 2017;8(02):170–173
48 Espinoza DL, González Carranza V, Chico-Ponce de León F, Martinez AM. PsT1: A low-cost optical simulator for psycho- motor skills training in neuroendoscopy. World Neurosurg 2015;83(06): 1074–1079
49 Parihar V, Yadav YR, Kher Y, Ratre S, Sethi A, Sharma D. Learning neuroendoscopy with an exoscope system (video telescopic operating monitor): early clinical results. Asian J Neurosurg 2016;11 (04):421–426

This document was downloaded for personal use only. Unauthorized distribution is strictly prohibited.