

# Effect of Albendazole Treatment in an Experimental Model of Neurocysticercosis-Induced Hydrocephalus

## *Efeito do tratamento com albendazol num modelo experimental de hidrocefalia induzida por neurocisticercose*

Marcelo Ortolani Fogaroli<sup>1</sup> Marcelo Augusto Chiantelli Oliveira<sup>1</sup> Pedro Tadao Hamamoto Filho<sup>1</sup>  
 Marcelo Padovani de Toledo Moraes<sup>1</sup> Luiz Carlos Vulcano<sup>1</sup> Rodrigo Bazan<sup>1</sup> Marco Antônio Zanini<sup>1</sup>  
 Agnès Fleury<sup>2</sup>

<sup>1</sup>Department of Neurology, Psychology and Psychiatry, Universidade Estadual Paulista (UNESP), Botucatu, SP, Brazil

<sup>2</sup>Universidad Nacional Autónoma de México (UNAM), Ciudad de México, Mexico

Address for correspondence Pedro Tadao Hamamoto Filho, MD, MSc, Departamento de Neurologia, Psicologia e Psiquiatria, Universidade Estadual Paulista (UNESP), Campus Botucatu, Distrito Rubião Jr, S/N, 18618686, Botucatu, SP, Brazil (e-mail: pthamamotof@hotmail.com).

Arq Bras Neurocir 2019;38:25–30.

### Abstract

Hydrocephalus is a major concern in neurocysticercosis (NCC), and its management is more challenging than that of hydrocephalus caused by other etiologies. Even though albendazole is a well-established drug for the treatment of NCC, the death of the parasites may worsen the clinical symptoms and eventually, deteriorate the course of hydrocephalus. The aim of this study was to analyze the effects of treatment with albendazole on the course of hydrocephalus as well as on animal behavior in a rat model of NCC-induced hydrocephalus in order to verify whether the course of hydrocephalus and the animal behavior were changed. Ventricle volumes before and after treatment showed a slight but non-statistically significant difference (168.11 mm<sup>3</sup> versus 184.98 mm<sup>3</sup>,  $p = 0.45$ ). The distribution and location of the cysts were unaffected. In addition, the behavioral patterns before and after the treatment were not significantly different, as assessed by the open field test. On histologic assessment, mononuclear leukocyte infiltration was present in diverse sites, such as the perivascular and peri-ependymal regions, choroid plexus, and meningeal membranes. A positive correlation was found between the degree of ventricle enlargement and tissue damage. Further studies with long-term comparisons are required.

### Keywords

- ▶ hydrocephalus
- ▶ neurocysticercosis
- ▶ albendazole
- ▶ experimental design

### Resumo

A hidrocefalia é uma das principais complicações da neurocisticercose (NCC), e seu manejo pode ser mais desafiador do que outras forma de hidrocefalia. Apesar de o albendazol ser uma droga bem estabelecida para o tratamento da NCC, a morte do parasitas pode agravar os sintomas clínicos e, eventualmente, deteriorar o curso de hidrocefalia. O objetivo deste estudo foi analisar os efeitos do tratamento com albendazol no curso da hidrocefalia, bem como no comportamento animal em um

received  
 July 6, 2018  
 accepted  
 January 8, 2019  
 published online  
 February 21, 2019

DOI <https://doi.org/10.1055/s-0039-1678561>.  
 ISSN 0103-5355.

Copyright © 2019 by Thieme Revinter Publicações Ltda, Rio de Janeiro, Brazil

License terms



**Palavras-chave**

- ▶ hidrocefalia
- ▶ neurocisticercose
- ▶ albendazol
- ▶ desenho experimental

modelo de hidrocefalia induzida por NCC em ratos. Na análise do volumes ventricular antes e depois do tratamento, houve uma diferença leve, mas não estatisticamente significativa (168,11 mm<sup>3</sup> versus 184,98 mm<sup>3</sup>,  $p = 0,45$ ). A distribuição e localização dos cistos não foram afetadas.

Além disso, os padrões comportamentais antes e após o tratamento também não foram significativamente diferentes. A avaliação histológica mostrou infiltração leucocitária mononuclear em diversos sítios, como nas regiões perivascular e periependimária, plexo coróide e meninges. Uma correlação positiva foi encontrada entre o grau de aumento do ventrículo e dano tecidual. Mais estudos com comparações de longo prazo são necessários para melhor compreensão da possível deterioração clínica da hidrocefalia por NCC quando do tratamento clínico.

**Introduction**

Neurocysticercosis (NCC) is the most common parasitic disease of the central nervous system (CNS) worldwide.<sup>1,2</sup> Although it is potentially eradicable, it remains endemic in developing countries, and migratory flows have reintroduced the disease in Europe and the USA.<sup>3,4</sup>

Neurocysticercosis is a pleomorphic disease because *Taenia solium* cysts may lodge anywhere in the CNS and the parasite-host interaction is highly heterogeneous.<sup>5</sup> The extraparenchymal form of NCC has a more aggressive course because cysts in the cerebrospinal fluid (CSF) compartments can elicit an intense inflammatory reaction, leading to vasculitis, hydrocephalus, and increased intracranial pressure.<sup>6,7</sup>

Hydrocephalus is a major concern in extraparenchymal NCC, as patients with NCC-induced hydrocephalus have higher rates of morbidity and mortality. The management of NCC-related hydrocephalus is also more challenging than that of hydrocephalus of other etiologies because of the higher rates of shunt malfunction, infection, and the need for reoperation.<sup>8–11</sup>

Albendazole is a well-established drug for the treatment of neurocysticercosis. Although some controversy regarding the safety of albendazole in the treatment of extraparenchymal NCC has arisen in the last decades, albendazole remains the drug of choice even for giant extraparenchymal cysts with a mass effect. However, caution in the use of albendazole is needed because the drug accelerates the death of the parasites in the CSF compartments, worsening the clinical symptoms and eventually deteriorating the course of hydrocephalus.<sup>12,13</sup>

The pathophysiologic mechanisms of NCC-induced hydrocephalus are not fully understood, although experimental models have helped solve some questions regarding leukocyte infiltration and inflammatory reactions—mainly for the parenchymal form of the disease.<sup>14–19</sup> Recently, we developed an experimental model of NCC-induced hydrocephalus that reproduces magnetic resonance imaging (MRI) and histologic findings of human NCC.<sup>20</sup> In the present study, we aimed to analyze the effects of albendazole treatment in a rat model of NCC with concomitant hydrocephalus to evalu-

ate the correlation between the course of hydrocephalus and animal behavior.

**Methods****Animals**

The Institutional Animal Care and Use Committee analyzed and approved the project. The animals were handled according to ethical guidelines and current legislation. Eighteen adult Wistar rats weighing ~ 150 g were used. The rats were kept in rooms with controlled humidity and temperature (21°C) under a regular light cycle of 12/12 hours. Food and water were available *ad libitum*.

**Sample size**

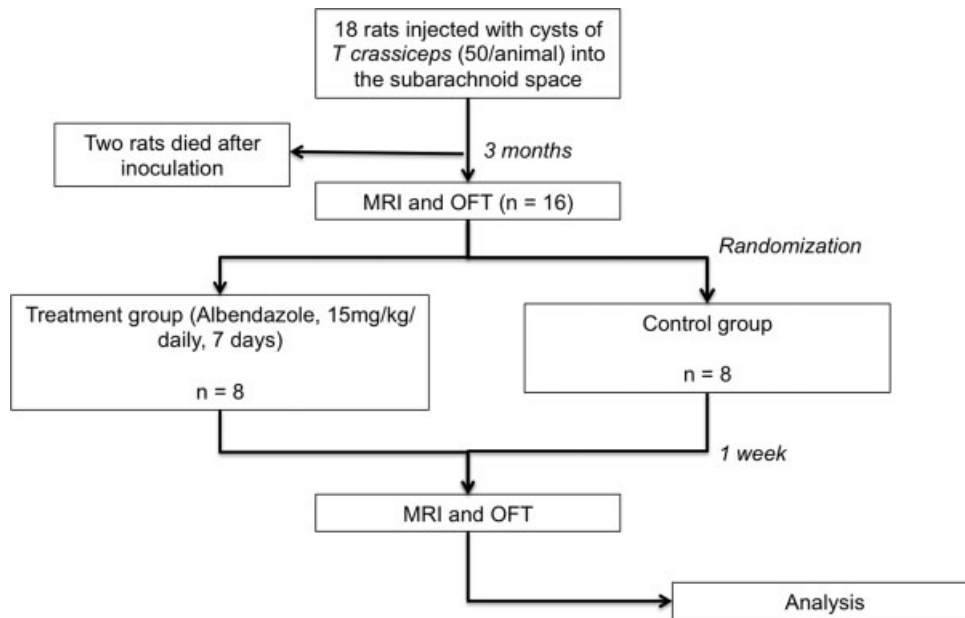
According to previous studies, five animals are sufficient to determine statistical differences between groups in ventricle volume. Assuming a mortality rate of 30% immediately after the inoculation procedure and during the observational period, we used 9 animals for each group (18 in total). This sample size was estimated assuming a random sample with type I and II errors of 0.05 and 0.02, respectively, and a normal distribution of ventricle volumes without potential confounding factors.

**Experimental Design**

Eighteen rats weighing **150–200 g** were inoculated with 50 cysts of *Taenia crassiceps* (a *T. solium* analog cestode). Two animals died immediately after the inoculation. Thus, 16 rats were kept for observation. Three months after the inoculation, the rats underwent MRI and the open field test (OFT) to evaluate behavior patterns. The rats were then randomly divided into two groups: treatment with albendazole and no treatment (control group). One week after the treatment, the animals again underwent MRI and the OFT, and were euthanized for histologic assessment. ▶ **Fig. 1** shows a flowchart of the experimental design.

**Parasites and Inoculation**

The methods for the maintenance and inoculation of *T. crassiceps* have been described previously.<sup>21</sup> Briefly, after general intraperitoneal anesthesia with ketamine and



**Fig. 1** Flowchart of the experimental design.

xylazine, the rats were inoculated with 50 metacestodes of *T. crassiceps*, each one, removed from the peritoneal cavities of infected mice, into the subarachnoid space (cisterna magna).

### MRI

An MRI was performed using a 0.25 Tesla equipment, model Vet-MR (Esaote, Genoa, Italy). Improved visualization of ventricles and cysts was achieved using a T2-weighted gradient-echo sequence (0.6 mm thickness; T<sub>eco</sub> 5 ms; T repetition 10 ms). An experienced team analyzed the MRI findings focusing on cyst distribution. Volumetric analysis was performed using the ITK-SNAP software, version 3.0.0 (Penn Image Computing and Science Laboratory, Pennsylvania, USA).

### Open Field Test

We used a wood chamber of 72 × 72 cm gridded with 9 equally sized squares (18 × 18 cm). Rats were placed in the chamber, and their behavior was recorded using a GoPro digital camera for 5 minutes. The records were analyzed by two independent observers registering the number of crossed lines, center time, stretch attend posture, and defecation. When the disagreement between the observers was lower than 10%, we used the higher value. When the disagreement was higher than 10%, the observers reexamined the record together to determine a final consensus value.

### Histologic Assessment

After the second OFT, the animals were euthanized with an overdose of pentobarbital for encephalon removal. We used heart perfusion with, and overnight immersion in, 10% neutral-buffered formalin for brain fixation. The next day, slices were cut at the level of the optic chiasm, dehydrated in increasing concentrations of alcohol, diafanized in xylene, and embedded in paraffin. The paraffin blocks were cut into

3- $\mu$ m sections, and the sections were stained with hematoxylin-eosin. For histological assessment, we used the criteria of Matos-Silva for experimental encephalitis, focusing on meningeal, perivascular, ependymal, and choroid plexus leukocyte infiltration, periventricular gliosis and edema, choroid plexus edema, ependymitis and ependymal destruction and hyperemia. These parameters were graded semi-quantitatively (absent: 0 points, light: 1 point, moderate: 2 points, and severe: 3 points). The total score of tissue damage was the sum of the scores of each parameter.

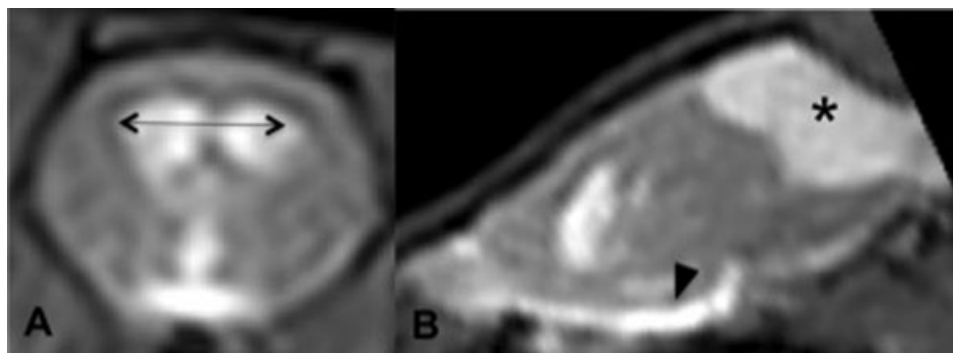
### Statistical Analysis

The BioEstat 5.3 software (BioEstat Software, Belém, PA, Brazil) was used to assess the normal distribution of variables (Shapiro-Wilk test), differences between pre and post-treatment ventricle size (t-test), correlation between OFT results and ventricle size (Pearson correlation), and correlation between histologic grades and ventricle size (Spearman correlation). Statistical significance was set at  $p = 0.05$ .

### Results

Of the 16 inoculated rats, nine developed hydrocephalus (the cutoff value for a normal ventricle volume was 5.0 mm<sup>3</sup>). **Fig. 2** shows an example of a hydrocephalic animal with cysts in the CSF compartments. Eight of these nine hydrocephalic animals were in the treatment group at randomization. Because the groups were not comparable, we excluded the control group from the ventricle and behavioral analyses, and focused our assessment on pre- and post- treatment differences.

Ventricle volumes before and after treatment showed a slight but non-significant difference (168.11 mm<sup>3</sup> versus 184.98 mm<sup>3</sup>,  $p = 0.45$ ). The distribution and location of cysts did not change, except in one animal that had no cysts within



**Fig. 2** Magnetic resonance imaging showed hydrocephalus with ventricular enlargement (A, arrow) and cysts in the basal cistern (B, arrowhead) and in the cisterna magna (B, asterisk) in a *T. crassiceps*-inoculated mouse.

the basal cisterns pre-treatment but showed cysts after treatment. The results are summarized in **Table 1**.

Regarding the behavioral pattern in the OFT, we found no differences before and after treatment (line crossing:  $p = 0.73$ ; center time:  $p = 0.35$ ; stretch attend posture:  $p = 0.73$ ; defecation:  $p = 0.45$ ). In addition, no correlation was found between the ventricle volume and OFT pattern variations ( $p > 0.05$ ).

On histologic assessment, we were able to verify the occurrence of mononuclear leukocyte infiltration in diverse sites, such as the perivascular and peri-ependymal region, choroid plexus, and meningeal membranes (**Fig. 3**). To determine whether ventricle volume was associated with the histologic damage score, we considered all 16 animals and found a positive correlation (rho coefficient = 0.53;  $p = 0.04$ ).

### Discussion

Neurocysticercosis is a pleomorphic disease, and the full understanding of its pathophysiologic mechanisms is hindered by the heterogeneity of the parasite-host interaction and by the interference of drugs commonly employed to treat NCC in clinical practice, such as cysticidic and corticoste-

roids.<sup>22</sup> For this reason, many investigators have attempted to establish experimental models of the disease.<sup>23</sup>

The use of albendazole for extraparenchymal NCC remained controversial for some time; however, it is currently well-accepted and recommended.<sup>24</sup> Nevertheless, the risk of exacerbation of symptoms, notably deterioration of hydrocephalus, should be always borne in mind when prescribing albendazole.<sup>25,26</sup> We aimed to examine whether the use of albendazole in an experimental model of extraparenchymal NCC could reproduce this potential adverse effect.

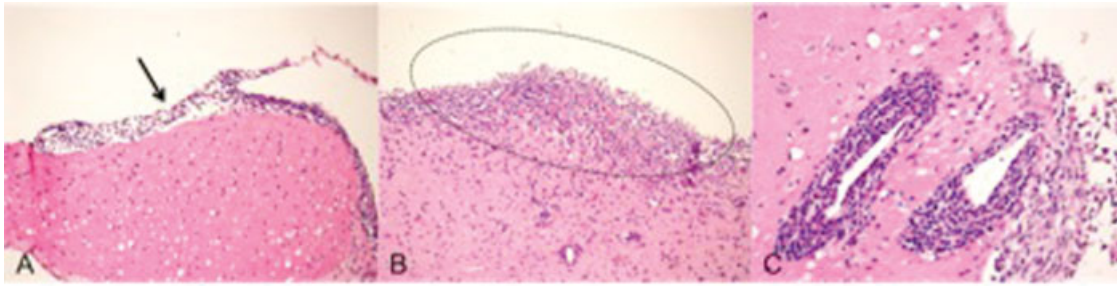
We found that neither the hydrocephalus nor behavioral patterns changed significantly in the short term after the albendazole treatment. However, we cannot state that albendazole was a safe drug in our experimental model since the drug was not effective either, as the cysts remained visible in the CSF spaces in the MRI analyses. Thus, the drug was not sufficiently effective to completely eliminate the parasite in the short term.

Similarly, in clinical practice, the analysis of a subgroup from a large randomized controlled trial did not show increased rates of disappearance of extraparenchymal cysts in patients even 12 months after albendazole treatment.<sup>27</sup> In fact, few controlled trials of medical treatment for

**Table 1** Ventricle volume of each animal in the treatment group before and after the treatment, and the distribution of cysts in the main cerebrospinal fluid (CSF) compartments

Animal	Pretreatment					Posttreatment				
	Ventricle volume (mm <sup>3</sup> ) *	Cisterna magna	Brain convexity	Basal cisterns	Intra-ventricular	Ventricle volume (mm <sup>3</sup> ) *	Cisterna magna	Brain convexity	Basal cisterns	Intra-ventricular
1	107.20	Yes	No	Yes	No	26.25	Yes	No	Yes	No
2	46.35	Yes	Yes	No	No	43.53	Yes	Yes	Yes	Yes
3	291.70	Yes	No	Yes	Yes	324.0	Yes	No	Yes	Yes
4	68.08	No	No	Yes	No	88.17	No	No	Yes	No
5	177.10	No	No	No	No	165.4	No	No	No	No
6	17.80	No	No	Yes	No	29.81	No	No	Yes	No
7	69.34	Yes	No	Yes	No	101.20	Yes	No	Yes	No
8	567.30	Yes	No	Yes	No	701.50	Yes	No	Yes	No

\*The mean ventricle volume before and after treatment was 168.11vmm<sup>3</sup> (±183.46) and 184.98vmm<sup>3</sup> (±230.58), respectively. This difference did not reach statistical significance ( $p = 0.45$ ). Only animal #2 showed a difference in the presence of cysts in the basal cisterns pre and posttreatment.



**Fig. 3** Histologic assessment showed meningeal mononuclear leukocyte infiltration (A, arrow), a pattern of chronic ependymitis (B, dotted lines), and intense perivascular leukocyte mononuclear infiltration (C).

extraparenchymal NCC have been published, and most of the current knowledge is based on case series.<sup>28</sup> Experimental models can contribute to filling this evidence gap.

In addition, albendazole dosage should also be considered. Góngora-Rivera et al (2006) proposed that a higher dose (30 mg/kg/day) would be more effective for larger cysts in subarachnoid and intraventricular cysticercosis.<sup>29</sup> The concomitant use of steroids is also recommended to reduce inflammatory reactions.<sup>30</sup> To date, we have observed inflammatory cells in different analyzed brain regions, and we believe that future experiments using steroids may be useful to demonstrate the reduction of inflammation.

Finally, the present study adds new information on the experimental model of NCC-induced hydrocephalus. We have previously observed inflammation, edema, gliosis, and ependymal destruction in this model. In the present study, we were able to demonstrate that the degree of hydrocephalus was associated with the severity of tissue lesions.

Some limitations must be pointed out. First, we observed high heterogeneity of the disease between the control and treatment groups. Future studies should only use animals with verified hydrocephalus for randomization. Second, it is not clear whether the parasite mass-effect or the inflammation was more important in the development of hydrocephalus. Demonstrating that hydrocephalus can occur even with the parasites destroyed will guide the understanding of the role of inflammation in this model of extraparenchymal NCC.

## Conclusion

In the short term, albendazole did not deteriorate the course of hydrocephalus and behavioral patterns in a model of neurocysticercosis-induced hydrocephalus.

### Conflicts of Interest

The authors have no conflicts of interest to declare.

## References

- Martins-Melo FR, Ramos AN Jr, Cavalcanti MG, Alencar CH, Heukelbach J. Neurocysticercosis-related mortality in Brazil, 2000-2011: Epidemiology of a neglected neurologic cause of death. *Acta Trop* 2016;153:128-136
- Singh BB, Khatkar MS, Gill JPS, Dhand NK. Estimation of the health and economic burden of neurocysticercosis in India. *Acta Trop* 2017;165:161-169
- Fabiani S, Bruschi F. Neurocysticercosis in Europe: Still a public health concern not only for imported cases. *Acta Trop* 2013;128(01):18-26
- O'Neal SE, Flecker RH, O'Neal SE. Hospitalization frequency and charges for neurocysticercosis, United States, 2003-2012. *Emerg Infect Dis* 2015;21(06):969-976
- Marcin Sierra M, Arroyo M, Cadena Torres M, et al. Extraparenchymal neurocysticercosis: Demographic, clinicoradiological, and inflammatory features. *PLoS Negl Trop Dis* 2017;11(06):e0005646
- Fleury A, Carrillo-Mezo R, Flisser A, Sciuotto E, Corona T. Subarachnoid basal neurocysticercosis: a focus on the most severe form of the disease. *Expert Rev Anti Infect Ther* 2011;9(01):123-133
- Bazan R, Hamamoto Filho PT, Luvizutto GJ, et al. Clinical symptoms, imaging features and cyst distribution in the cerebrospinal fluid compartments in patients with extraparenchymal neurocysticercosis. *PLoS Negl Trop Dis* 2016;10(11):e0005115
- Kelley R, Duong DH, Locke GE. Characteristics of ventricular shunt malfunctions among patients with neurocysticercosis. *Neurosurgery* 2002;50(04):757-761, discussion 761-762
- Colli BO, Carlotti CG Jr, Assirati JA Jr, Machado HR, Valença M, Amato MCM. Surgical treatment of neurocysticercosis: long-term results and prognostic factors. *Neurosurg Focus* 2002;12:1-13
- Agapejev S, Pouza AF, Bazan R, Faleiros ATS. [Clinical and evolutive aspects of hydrocephalus in neurocysticercosis]. *Arq Neuropsiquiatr* 2007;65(3A):674-680
- Paiva ALC, Araujo JLV, Ferraz VR, et al. Surgical treatment of neurocysticercosis. Retrospective cohort study and an illustrative case report. *Sao Paulo Med J* 2017;135(02):146-149
- Garcia HH, Nash TE, Del Brutto OH. Clinical symptoms, diagnosis, and treatment of neurocysticercosis. *Lancet Neurol* 2014;13(12):1202-1215
- Del Brutto OH. Clinical management of neurocysticercosis. *Expert Rev Neurother* 2014;14(04):389-396
- Alvarez JI, Mishra BB, Gundra UM, Mishra PK, Teale JM. Mesocostoides corti intracranial infection as a murine model for neurocysticercosis. *Parasitology* 2010;137(03):359-372
- Matos-Silva H, Reciputti BP, Paula EC, et al. Experimental encephalitis caused by *Taenia crassiceps* cysticerci in mice. *Arq Neuropsiquiatr* 2012;70(04):287-292
- Fleury A, Trejo A, Cisneros H, et al. *Taenia solium*: development of an experimental model of porcine neurocysticercosis. *PLoS Negl Trop Dis* 2015;9(08):e0003980
- Verastegui MR, Mejia A, Clark T, et al. Novel rat model for neurocysticercosis using *Taenia solium*. *Am J Pathol* 2015;185(08):2259-2268
- Milhomem AC, Souza AJS, Silva HM, et al. Histopathologic aspects of experimental cysticercosis and in situ cytokines profile in C57BL/6 mice. *Arq Neuropsiquiatr* 2018;76(05):339-345

- 19 Alroy KA, Arroyo G, Gilman RH, et al. Carotid *T solium* oncosphere infection: a novel porcine neurocysticercosis model. *Am J Trop Hyg* 2018
- 20 Hamamoto Filho PT, Fabro AT, Rodrigues MV, et al. *Taenia crassiceps* injection into the subarachnoid space of rats simulates radiological and morphological features of racemose neurocysticercosis. *Childs Nerv Syst* 2017;33(01):119–123
- 21 Hamamoto Filho PT, Zanini MA, Botta FP, et al. Development of an experimental model of neurocysticercosis-induced hydrocephalus. Pilot study. *Acta Cir Bras* 2015;30(12):819–823
- 22 Agapejev S. Neurocysticercosis: the enigmatic disease. *Cent Nerv Syst Agents Med Chem* 2011;11(04):261–284
- 23 Arora N, Tripathi S, Kumar P, Mondal P, Mishra A, Prasad A. Recent advancements and new perspectives in animal models for Neurocysticercosis immunopathogenesis. *Parasite Immunol* 2017;39(07):e12439
- 24 White AC Jr, Coyle CM, Rajshekhar V, et al. Diagnosis and Treatment of Neurocysticercosis: 2017 Clinical Practice Guidelines by the Infectious Diseases Society of America (IDSA) and the American Society of Tropical Medicine and Hygiene (ASTMH). *Clin Infect Dis* 2018;66(08):1159–1163
- 25 Garcia HH, Gonzalez AE, Gilman RH. Cysticercosis of the central nervous system: how should it be managed? *Curr Opin Infect Dis* 2011;24(05):423–427
- 26 Garcia HH, Gonzales I, Lescano AG, et al; Cysticercosis Working Group in Peru. Efficacy of combined antiparasitic therapy with praziquantel and albendazole for neurocysticercosis: a double-blind, randomised controlled trial. *Lancet Infect Dis* 2014;14(08):687–695
- 27 Carpio A, Kelvin EA, Bagiella E, et al; Ecuadorian Neurocysticercosis Group. Effects of albendazole treatment on neurocysticercosis: a randomised controlled trial. *J Neurol Neurosurg Psychiatry* 2008;79(09):1050–1055
- 28 García HH, Evans CAW, Nash TE, et al. Current consensus guidelines for treatment of neurocysticercosis. *Clin Microbiol Rev* 2002;15(04):747–756
- 29 Göngora-Rivera F, Soto-Hernández JL, González Esquivel D, et al. Albendazole trial at 15 or 30 mg/kg/day for subarachnoid and intraventricular cysticercosis. *Neurology* 2006;66(03):436–438
- 30 Mahale RR, Mehta A, Rangasetty S. Extraparenchymal (racemose) neurocysticercosis and its multitude manifestations: a comprehensive review. *J Clin Neurol* 2015;11(03):203–211

**Erratum:** The name of author Pedro Tadao Hamamoto Filho has been corrected as per Erratum published. DOI of the Erratum is 10.1055/s-0039-1683954.