

# Trigeminal Neuralgia Caused by Cerebellopontine Angle Tumors: Surgical Series

## Neuralgia trigeminal causada por tumor do ângulo pontocerebelar: série de casos cirúrgicos

Lucas Crociati Meguins<sup>1</sup> Thayanna Bentes Lemanski Lopes Rodrigues<sup>1</sup> Ricardo Lourenço Caramanti<sup>1</sup>  
 Carlos Eduardo Dale Aglio Rocha<sup>1</sup> Matheus Rodrigo Laurenti<sup>1</sup> Mario José Góes<sup>1</sup>  
 Dionei Freitas de Moraes<sup>1</sup> Waldir Antonio Tognola<sup>1</sup>

<sup>1</sup>Division of Neurosurgery, Department of Neurological Sciences, Hospital de Base, Faculdade de Medicina de São José do Rio Preto, São José do Rio Preto, SP, Brazil

Address for correspondence Thayanna Bentes Lemanski Lopes Rodrigues, MD, Divisão de Neurocirurgia, Departamento de Ciências Neurológicas, Faculdade de Medicina de São José do Rio Preto, Av. Brigadeiro Faria Lima, 5544, São José do Rio Preto, 15090-000. São José do Rio Preto, SP, Brazil (e-mail: thaylemanski@hotmail.com).

Arq Bras Neurocir 2019;38:20–24.

### Abstract

**Introduction** Cerebellopontine angle (CPA) tumors represent an important cause of persistent and refractory trigeminal neuralgia (TN). It is believed that ~ between 1 and 9.9% of the cases of patients presenting with TN painful manifestation are caused by space-occupying lesions.

**Objective** The objective of the present study is to describe the clinical and surgical experience of the operative management of patients presenting with secondary type TN associated with CPA tumors.

**Method** An observational investigation was conducted with data collection from patients with secondary type TN associated with CPA tumors who were treated with surgical resection of the space-occupying lesion and decompression of the trigeminal nerve from January 2013 to November 2016 in 2 different centers in the western region of the state of São Paulo, Brazil.

**Results** We operated on 11 consecutive cases in which TN was associated with CPA during the period of analysis. Seven (63.6%) patients were female, and 4 (36.4%) were male. Seven (63.6%) patients presented with right-side symptoms, and 4 (36.4%) presented with left-side symptoms. After 2 years of follow-up, we observed that 8 (72.7%) patients showed a complete improvement of the symptoms, with an excellent outcome, and that 3 (27.3%) patients showed an incomplete improvement, with a good outcome. No patient reported partial improvement or poor outcome after the follow-up. There was no operative mortality.

**Conclusion** Cerebellopontine angle tumors represent an important cause of TN and must be included in the differential diagnosis of patients presenting with refractory and persistent symptoms. Surgical treatment with total resection of the expansive lesion and effective decompression of the trigeminal nerve are essential steps to control the symptoms.

### Keywords

- ▶ trigeminal neuralgia
- ▶ cerebellopontine angle tumors

received  
 November 19, 2018  
 accepted  
 January 8, 2019

DOI <https://doi.org/10.1055/s-0039-1678593>.  
 ISSN 0103-5355.

Copyright © 2019 by Thieme Revinter Publicações Ltda, Rio de Janeiro, Brazil

License terms



**Resumo**

**Introdução** Os tumores de ângulo pontocerebelar (APC) representam uma importante causa de neuralgia do nervo trigêmeo (NT) persistente e refratária. Cerca de 1 a 9,9% dos casos de pacientes com manifestação dolorosa do trigêmeo são causados por lesões expansivas.

**Objetivo** O objetivo do presente estudo é descrever a experiência clínica e cirúrgica do tratamento de pacientes que apresentam tipo secundário de NT associada a tumores de APC.

**Método** Foi realizada uma investigação observacional com coleta de dados de pacientes com NT secundária associada a tumor de APC tratados com ressecção cirúrgica de lesão expansiva e descompressão do nervo trigêmeo entre janeiro de 2013 e novembro de 2016, em 2 diferentes centros da região oeste do estado de São Paulo, Brasil.

**Resultados** Foram abordados 11 casos consecutivos nos quais NT foi associada a tumores de APC durante o período de análise. Sete (63,6%) pacientes eram do sexo feminino, e 4 (36,4%) do sexo masculino. Sete (63,6%) pacientes apresentaram sintomas no lado direito, e 4 (36,4%) apresentaram sintomas no lado esquerdo. Após 2 anos de seguimento, 8 (72,7%) pacientes apresentaram melhora completa dos sintomas com excelente resultado, e 3 (27,3%) pacientes apresentaram melhora incompleta com boa evolução. Não houve mortalidade operatória.

**Conclusão** Os tumores de APC representam uma importante causa de NT e devem ser incluídos no diagnóstico diferencial de pacientes com sintomas refratários e persistentes. O tratamento cirúrgico com ressecção total da lesão expansiva e descompressão efetiva do nervo trigêmeo são etapas essenciais para o controle dos sintomas.

**Palavras-chave**

- ▶ neuralgia trigeminal
- ▶ tumor do ângulo pontocerebelar

**Introduction**

Although the classical type of trigeminal neuralgia (TN) is the most common symptom of neurovascular conflict, some patients have the secondary type of TN, in which space-occupying lesions are responsible for the symptoms.<sup>1-3</sup> It is believed that ~ between 1 and 9.9% of the cases of patients presenting with TN painful manifestation are caused by cerebellopontine angle (CPA) tumors.<sup>4</sup> Meningiomas, schwannomas, and heman-gioblastomas are extremely common posterior fossa tumors that may cause TN by directly compressing the trigeminal nerve or by being close to vascular structures around the nerve entry zone.<sup>5-7</sup>

The aim of the present study is to describe the clinical and surgical experience of the operative management of patients presenting with the secondary type of TN associated with CPA tumors.

**Method****Delineation of the Study**

An observational investigation was conducted with data collection from patients with the secondary type of TN associated with CPA tumors who were treated with surgical resection of the space-occupying lesion and decompression of the trigeminal nerve from January 2013 to November 2016 in 2 different centers in the western region of the state of São Paulo, Brazil. Clinical data were obtained retrospectively from the records and files of the patients. For all of the patients with the diagnosis of TN and radiological evidence of

CPA tumor on magnetic resonance imaging (MRI), the following data were collected: gender, age at surgery, side of pain, type of the conflict/compression, type and number of medications used.

**Presurgical Evaluation**

An MRI of the brain was obtained from all of the patients with TN associated with CPA according to a specific protocol using a 1.5 Tesla MRI Scanner (Philips, Amsterdam, Netherlands) at the department of neuroradiology at our institution. All of the MRIs were analyzed by an experienced neuroradiologist who confirmed the visual radiological diagnosis of space-occupying lesion. High-resolution MRIs were performed to view the CPA anatomy of the patients and to exclude the presence of any additional neurovascular conflict.

**Surgical Technique**

The surgical approach was similar for all of the patients, and all of the procedures were performed by neurosurgeons experienced in microvascular decompression (MVD) surgery for TN. The surgery was performed under general anesthesia with a flexible spiral tracheal tube to allow the flexion of the neck while securing the airways. All of the patients were placed in the lateral position with the head supported with a three-pin Mayfield head fixation. A 5- to 7-cm curvilinear incision was made obliquely inside the hairline at the upper retromastoid area. A 1.5- to 2-cm diameter keyhole bone opening or small craniectomy or craniotomy was performed using a 4- and 4-mm extra-coarse power Diamond drill

system, EM 100-A Midas Rex Legend EHS, manufactured by Medtronic Powered Surgical Solutions - Memphis, TN, USA. The keyhole was located at the inner corner of the transverse sinus and the sigmoid sinus. Before the dural opening, precise hemostasis was accomplished with bone wax, Surgicel (Ethicon Inc., Bridgewater, NJ, USA) and cautery. The mastoid air cells were sealed with bone wax. The dura was opened in an inverted-T fashion, and small dural flaps were stitched to make a maximal dural opening (5 to 10 mm). The cerebrospinal fluid (CSF) was gradually aspirated and, under the operating microscope, an infratentorial lateral supra-cerebellar dissection was advanced to expose the petrosal vein (one to three bridging veins). Sufficient arachnoid dissection was performed around the petrosal veins and caudally to carefully expose the facial nerve and any offending vessels around the neural structures from proximal to distal. The space-occupying lesions were easily identified in all of the cases, and a circumferential dissection was initially performed whenever possible in order to carefully identify all of the neural and vascular structures before the debulking/resection of the tumor. Any additional compressing arterial loops or venous contacts were carefully dissected and mobilized off of the nerve root. A nonabsorbable material was interposed between the any vessel and the entry zone of the trigeminal nerve. Cerebellar retraction was judiciously used when necessary. A meticulous hemostasis and cleanup of the operating field was often achieved. Watertight dural closure with or without fascial graft was performed, and the cranioplasty was completed whenever possible. Cutaneous layers were routinely closed.

#### Outcome Assessment and Follow-Up

A 2-year follow-up investigation was performed in all of the patients included in the present study. The patients were clinically reassessed at 6, 12 and 24 months after the surgery, regarding the subjective improvement in the preoperative facial pain. They were included in 3 different groups according to the percentage of amelioration of pain, as follows: excellent

—complete improvement (> 90%); good—incomplete improvement (75–90%); and poor—partial improvement (< 75%).

#### Ethical Statement

The ethical committee of our institution analyzed the project and approved the performance of our investigations. All of the patients have given their informed consent for participation in the research study. The present study complied with the Declarations of Helsinki and Nuremberg. Informed consent for surgery was acquired from all of the patients.

#### Statistical Analysis

The data collected from all of the patients were organized in tables. The data are expressed as the means  $\pm$  the standard deviation (SD) for parametric variables, and as the median values for nonparametric variables. A normal distribution to sample collected data was assumed. The statistical analyses and the review of the numerical results obtained in the present investigation were performed by a mathematical team, and a *p*-value < 0.05 was considered statistically significant.

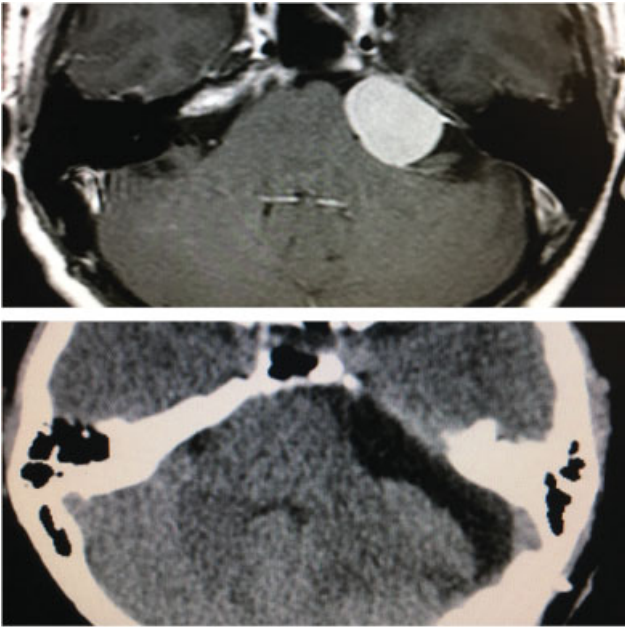
#### Results

We have operated on 11 consecutive cases in which TN was associated with a CPA tumor during the period of analysis. Seven (63.6%) patients were female, and 4 (36.4%) were male. Age distribution and duration of the symptoms are presented in ► **Table 1**. Seven (63.6%) patients presented with right-side symptoms, and 4 (36.4%) patients presented with left-side symptoms. After 2 years of follow-up, we observed that 8 (72.7%) patients showed a complete improvement of the symptoms, with an excellent outcome, and that 3 (27.3%) patients showed an incomplete improvement, with a good outcome. No patient reported partial improvement or poor outcome after the follow-up. There was no operative mortality. One (9.09%) patient presented with CSF leak, which was surgically treated on the 7<sup>th</sup> postoperative day, and 2 (18.2%) patients presented with temporary facial palsy.

**Table 1** Clinical details of patients with trigeminal neuralgia and cerebellopontine angle tumors

Patient	Age (years old)	Gender	Duration of the symptoms (months)	Side	Outcome	Complication	Tumor
1	63	Female	24	Right	Excellent	–	Meningioma
2	59	Female	36	Right	Good	–	Meningioma
3	67	Female	18	Left	Excellent	CSF leak	Meningioma
4	61	Male	33	Right	Excellent	–	Meningioma
5	64	Female	27	Right	Excellent	–	Meningioma
6	52	Male	31	Left	Good	Facial palsy	Schwannoma
7	47	Male	19	Left	Excellent	–	Schwannoma
8	61	Female	42	Right	Good	Facial palsy	Schwannoma
9	49	Male	18	Left	Excellent	–	Schwannoma
10	33	Female	14	Right	Excellent	–	Hemangioblastoma
11	37	Female	16	Right	Excellent	–	Hemangioblastoma

Abbreviations: CSF, cerebrospinal fluid.

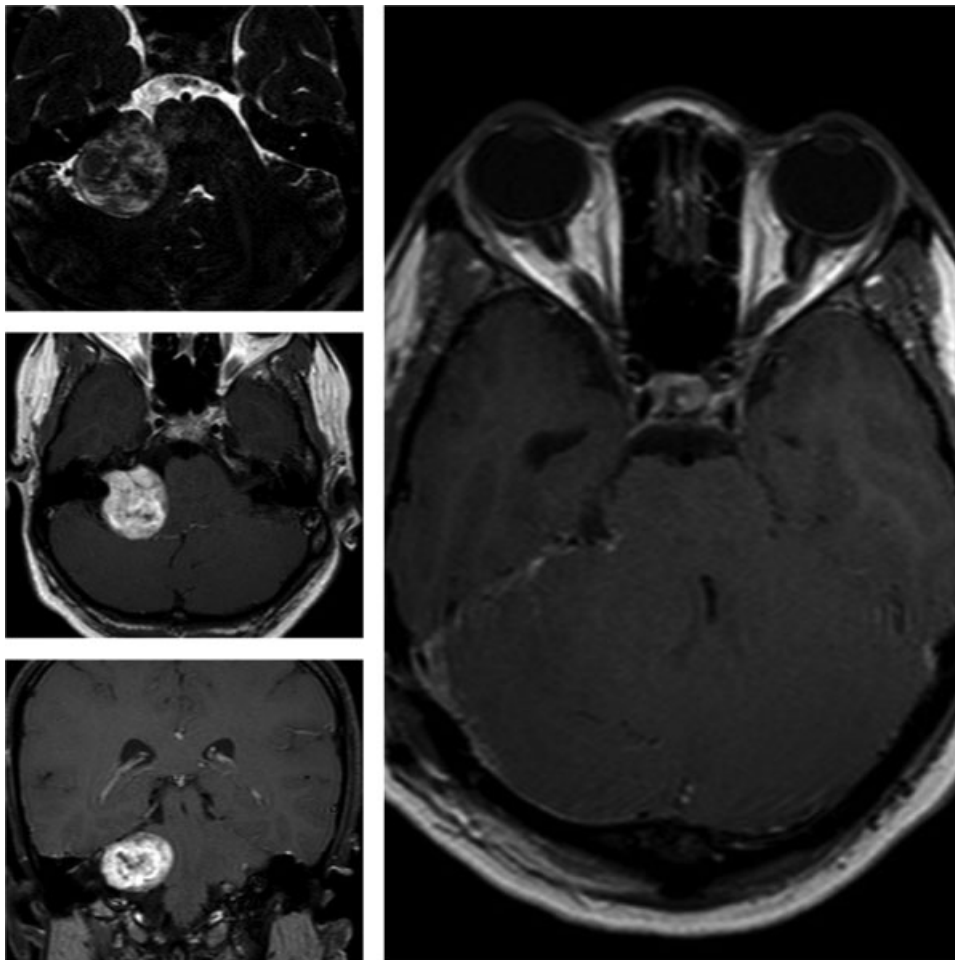


**Fig. 1** Cerebellopontine angle tumor meningioma compressing the trigeminal nerve. Postoperative computed tomography.

## Discussion

Several types of pathologies occur in the posterior fossa, and the specific diagnosis relies on the location of the lesion, on the age of the patient, on the associated clinical history, including signs, symptoms and duration, and on imaging studies.<sup>8-11</sup> Painful manifestation of posterior fossa tumors compressing the TN is a frequent manifestation of expansive lesions occupying the CPA.<sup>9-12</sup> It is believed that ~ between 1 and 9.9% of the cases of patients presenting with trigeminal painful manifestations are caused by CPA tumors, including meningiomas, schwannomas, and hemangioblastomas.<sup>4-7</sup> In the present study, we describe our clinical and surgical experience treating patients with TN secondary to posterior fossa tumors located at the CPA.

Vestibular schwannomas and meningiomas are the 2 most frequent lesions of the CPA and account for ~ between 85 and 90% of all of the posterior fossa tumors.<sup>5</sup> **Figure 1** and **2** exemplifies CPA tumor meningioma and a large vestibular schwannoma, respectively. Liu et al (2017) found CPA meningiomas as the most common causes of tumor-induced TN, accounting for 45.7% of the patients with symptomatic TN in this study.<sup>7</sup> According to the authors, meningiomas tended to displace the nerve with or without vascular compression on



**Fig. 2** Large vestibular schwannoma compressing the trigeminal nerve. Postoperative magnetic resonance imaging.

the entry zone.<sup>7</sup> In our investigation, meningiomas were also found as the most frequent posterior fossa tumors associated with TN, accounting for 45.5% of the patients with symptomatic TN. In accordance with previous publications, we have verified that tumor removal produces > 95% of symptom control in most patients.<sup>7,13,14</sup>

Large vestibular schwannomas are also described as potentially expansive lesions associated with TN that usually present no symptom improvement after stereotactic radiosurgery.<sup>15</sup> Neff et al (2017) showed that 16% of the patients with large vestibular schwannomas present with TN, and that the removal of the tumor alleviated pain in 70% of the cases.<sup>15</sup> Twenty-five percent of the patients did not show any change in the intensity of the neuralgia after the operation.<sup>15</sup> In the present study, we have observed that an excellent outcome regarding pain relief was achieved in 50% of the patients. Postoperative facial palsy was directly related with limitations in the control of the symptoms, as observed by others.<sup>7,15</sup>

Hemangioblastomas are tumors less frequently associated with TN.<sup>7</sup> They represent < 1% of the cases in some series.<sup>7</sup> However, tumor resection is usually associated with few complications and satisfactory symptom control.<sup>7</sup> In our investigation, we could operate on two young women with short symptom duration, resulting in an excellent control of the neuralgia after the surgery. Also, no complication related to the procedure was noted.

Complications associated with tumor removal to treat TN due to compressive symptoms are not rare. Liu et al (2017) described CSF leak, hearing disturbances, facial palsy, facial numbness, and oculomotor paralysis as possible complications when trying to decompress the trigeminal nerve from expansive lesions.<sup>7</sup> In the present study, we observed 1 (9.1%) case of CSF leak, which was treated with reoperation, and 2 (18.2%) cases of temporary facial palsy in large vestibular schwannomas. All of the patients with schwannomas included in the present investigation were preoperatively deaf, and their hearing status did not change after the surgery. There was no operative mortality.

## Conclusion

Cerebellopontine angle tumors represent an important cause of TN and must be included in the differential diagnosis of patients presenting refractory and persistent symptoms. Surgical treatment with total resection of the expansive lesion and effective decompression of the trigeminal nerve are essential steps to control the symptoms.

## Conflicts of Interest

The authors have no conflicts of interest to declare.

## References

- Ishi Y, Asaoka K, Sugiyama T, et al. Case Report: Trigeminal Neuralgia Caused by a Minute Meningioma with Hyperostosed Suprameatal Tubercle. *Case Rep Neurol* 2015;7(02):167-172
- Tan LA, Gerard CS, Ahuja SK, Moftakhar R. Retrosigmoid approach for resection of cerebellopontine angle meningioma and decompression of the trigeminal nerve. *Neurosurg Focus* 2014;36(1, Suppl):1
- Gopalakrishnan CV, Ansari KA, Nair S, Menon G. Long term outcome in surgically treated posterior fossa epidermoids. *Clin Neurol Neurosurg* 2014;117:93-99
- Shulev Y, Trashin A, Gordienko K. Secondary trigeminal neuralgia in cerebellopontine angle tumors. *Skull Base* 2011;21(05):287-294
- Niwant P, Motwani M, Naik S. Atypical Trigeminal Neuralgia Secondary to Meningioma. *Case Rep Dent* 2015;2015:462569
- Marinelli JP, Van Gompel JJ, Link MJ, Carlson ML. Microvascular Decompression for Treatment of Trigeminal Neuralgia in Patient with Facial Nerve Schwannoma. *World Neurosurg* 2018;113:142-145
- Liu P, Liao C, Zhong W, Yang M, Li S, Zhang W. Symptomatic Trigeminal Neuralgia Caused by Cerebellopontine Angle Tumors. *J Craniofac Surg* 2017;28(03):e256-e258
- Persad AR, Khormi YH, van Landeghem F, Chow MM. Unusual case of hemangioblastoma of the cerebellopontine angle. *Surg Neurol Int* 2017;8:264
- Hentschel MA, Kunst HPM, Rovers MM, Steens SCA. Diagnostic accuracy of high-resolution T2-weighted MRI vs contrast-enhanced T1-weighted MRI to screen for cerebellopontine angle lesions in symptomatic patients. *Clin Otolaryngol* 2018;43(03):805-811
- Kai M, Yongjie L. Clinical Features and Surgical Management of Cerebellopontine Angle Cholesteatoma That Presented as Trigeminal Neuralgia. *World Neurosurg* 2018;115:e7-e12
- Dutta G, Singh D, Saran RK, Singh H, Srivastava AK, Jagetia A. Cerebellopontine Angle Anaplastic Ganglioglioma Masquerading as Vestibular Schwannoma: Unusual Entity. *World Neurosurg* 2018;117:221-224
- Grigoryan YA, Onopchenko CV. Persistent trigeminal neuralgia after removal of contralateral posterior cranial fossa tumor. Report of two cases. *Surg Neurol* 1999;52(01):56-60, discussion 60-61
- Gerganov VM, Giordano M, Eloff E, Osamah A, Amir S, Madjid S. Operative management of patients with radiosurgery-related trigeminal neuralgia: analysis of the surgical morbidity and pain outcome. *Clin Neurol Neurosurg* 2014;122:23-28
- Noma N, Hayashi M, Kitahara I, et al. Painful Trigeminal Neuropathy Attributed to a Space-occupying Lesion Presenting as a Toothache: A Report of 4 Cases. *J Endod* 2017;43(07):1201-1206
- Neff BA, Carlson ML, O'Byrne MM, Van Gompel JJ, Driscoll CLW, Link MJ. Trigeminal neuralgia and neuropathy in large sporadic vestibular schwannomas. *J Neurosurg* 2017;127(05):992-999